

Endothelial cell study in a case of Werner's syndrome undergoing phacoemulsification and Yttrium-Aluminum-Garnet laser capsulotomy

Vasudha Kemmanu, Somshekar Nagappa¹,
Kaushik Hegde, Naresh K Yadav², Bhujang K Shetty³

Werner's syndrome (WS) is a rare autosomal recessive disorder with multisystem manifestations of premature aging from the second decade of life. Cataract is one of the features of WS. Cataract surgery is complicated with postoperative wound dehiscence and bullous keratopathy when the surgery is done by intracapsular or conventional extracapsular method. We report the short-term result of phacoemulsification and Neodymium Yttrium-Aluminum-Garnet laser (Nd YAG) capsulotomy in a case of WS with bilateral cataracts. Postoperatively and post capsulotomy, there was no change in the endothelial cell morphology. There was an 8.6% decrease in endothelial cell count at the end of 15 months postoperatively and 11 months post YAG capsulotomy. This decrease is within the acceptable range of cell loss after phacoemulsification and YAG capsulotomy. To the best of our knowledge, this is the first reported case of YAG laser capsulotomy in WS.

Key words: Endothelial cell count, phacoemulsification, Werner's syndrome, Yttrium-Aluminum-Garnet capsulotomy

Werner's syndrome (WS) is a rare autosomal recessive disorder presenting with multisystem manifestations of premature aging from second decade of life.^[1] A typical ocular feature of WS is juvenile cataract,^[2] which appears in the 2nd–3rd decade of life. We report a case of WS with bilateral cataract who underwent phacoemulsification and Neodymium Yttrium-Aluminum-Garnet laser (Nd YAG) capsulotomy.

Case Report

A 28-year-old female born out of a second-degree

consanguineous marriage presented with a gradual onset of decrease in vision in both eyes for 5 years. The patient was alright till the age of 10 years, when she developed skin changes, failure to gain weight, and had oligomenorrhea and irregular menses. She was on treatment for diabetes mellitus, high lipid profile and hypothyroidism, which developed as a consequence of radiotherapy for thyroid enlargement. She was diagnosed as WS and referred for cataract surgery.

On systemic examination, she had a short stature (134 cm), weighed 25 kg, looked emaciated, had gray, sparse scalp hair, bird-like facies, hoarse voice, thinned, hyperpigmented skin and lean arms and legs [Fig. 1a and b].

On ophthalmic examination, best corrected visual acuity was 20/60, N12 in the right eye (RE) and counting fingers 6 ft, N36 in the left eye (LE). Slit-lamp examination showed nuclear sclerosis grade 2 in the RE and total cataract in the LE. Fundus in the RE appeared normal and LE showed attached retina on ultrasonography. She underwent a clear corneal phacoemulsification with hydrophilic foldable intraocular lens (IOL) implantation in the LE under peribulbar anesthesia.

Sodium hyaluronate 1.4% was used to protect the endothelium. Intraoperatively, a thick posterior capsular calcified plaque was noticed which could not be removed by peeling with a 26 G needle. Primary posterior capsulotomy (PPC) was avoided for the fear of inducing cystoid macular edema (CME). After IOL implantation, the corneal tunnel and side ports were closed with 10/0 nylon suture. Subconjunctival steroids were avoided at the end of surgery. Postoperatively, the patient was started on ketorolac tromethamine ophthalmic solution 0.4% four times daily and gatifloxacin eye drops 0.3% four times daily. The patient was started on a weak steroid (fluorometholone eye drops) twice daily for a week on the 4th postoperative day because of the increased anterior chamber reaction. On subsequent visits, the eye was quiet. At 1 month, the best corrected visual acuity was 20/40 N12. Decrease in vision was attributed to the posterior capsular plaque [Fig. 2a]. Meanwhile, cataract in the RE progressed to total cataract. She was operated in the RE 6 months after the first cataract surgery with similar precautions. Postoperative best corrected visual acuity was 20/30, N6 in RE. YAG capsulotomy was done 4 months from the date of surgery in LE [Fig. 2b]. Best corrected visual acuity improved to 20/20 N6 after capsulotomy [Table 1].

Discussion

WS was first described by Otto Werner in 1904. About 1300 cases have been reported around the world from 1916 to 2002, including about 1000 Japanese patients.^[3] The International Registry of WS (www.wernersyndrome.org) uses the above findings [Table 2] to establish a "definite," "probable," or "possible" diagnosis. A definitive diagnosis requires all the cardinal signs and two signs from "other signs". Our patient had all the cardinal signs and two others (diabetes mellitus, hoarse voice), thus satisfying the criteria for a definitive diagnosis.

Cataract is one of the typical ocular manifestations of WS.^[2] Cataract surgery in WS may be complicated by wound dehiscence or corneal endothelial decompensation.^[4] Corneal decompensation occurred in 8 of the 18 eyes of patients with WS after cataract surgery when surgery was done by intracapsular

Access this article online	
Quick Response Code:	Website: www.ijjo.in
	DOI: 10.4103/0301-4738.103802

Departments of Pediatric Ophthalmology and Strabismus, ¹Cornea & Refractive Surgery, ²Vitreous Retina, and ³Cataract Services, Narayana Nethralaya, Bangalore, India

Correspondence to: Dr. Vasudha Kemmanu, Department of Pediatric Ophthalmology and Strabismus, Narayana Nethralaya, Super Specialty Eye Hospital and Post Graduate Institute of Ophthalmology, 121/C, Chord Road, Rajajinagar, 1st 'R' Block, Bangalore - 560 010, India. E-mail: vasudhanaresh@yahoo.co.in

Manuscript received: 12.03.10; Revision accepted: 12.07.10

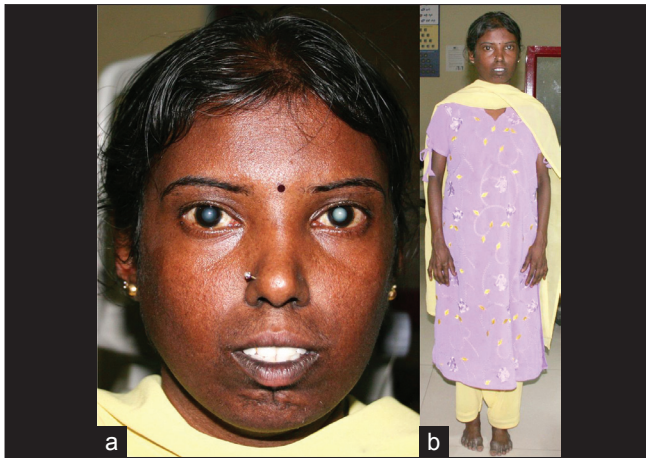

Figure 1: (a) External photograph of a 28-year-old patient with WS with bilateral cataracts, emaciated look, gray sparse scalp hair, a bird-like facies, thin hyperpigmented skin; (b) external photograph showing short stature and lean arms and legs

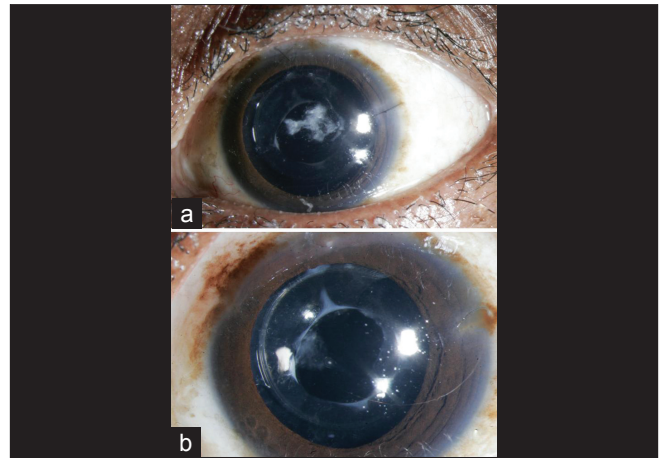


Figure 2: (a) Slit-lamp photograph of the LE showing pseudophakia with posterior capsular plaque; (b) slit-lamp photograph of the LE showing pseudophakia after YAG laser capsulotomy

Table 1: Preoperative, postoperative and post YAG capsulotomy endothelial cell counts

	Preoperative		Postoperative		Pre YAG capsulotomy		Post YAG capsulotomy	
	RE	LE	RE (at the end of 2 months)	LE (at the end of 4 months)	RE	LE	RE	LE (at the end of 4 months)
Endothelial cell count	2183 cells/mm ²	2016 cells/mm ²	2073 cells/mm ² (5.0% decrease)*	1875 cells/mm ² (7% decrease) [†]	NA [§]	1875 cells/mm ²	NA [§]	1866 cells/mm ² (0.48% decrease)

*The endothelial cell count in the RE was 2023 cells/mm² at the last follow-up (9 months from surgery) amounting to a 7.3% decrease, [†]Endothelial cell count in the LE was 1842 cells/mm² at the last follow-up (15 months after surgery) amounting to an 8.6% decrease, [§]Not applicable

Table 2: Showing clinical features of WS

Criteria for diagnosis*	
Cardinal signs	Other signs
1. Bilateral cataracts	1. Type 2 diabetes mellitus
2. Tight/atrophic/hyperpigmented skin	2. Hypogonadism
3. "Bird-like" facies	3. Osteoporosis
4. Short stature	4. Radiographic evidence of osteosclerosis of distal phalanges of fingers and/ or toes
5. Premature graying and/ or thinning of hair	5. Soft tissue calcification
6. Parental consanguinity	6. Evidence of premature atherosclerosis
	7. Neoplasm
	8. Abnormal voice (high-pitched, squeaky, or hoarse)
	9. Flat feet

*According to the International Registry of WS (www.wernersyndrome.org)

or conventional extracapsular surgery.^[2] Decreased endothelial function in WS is due to prematurely aged cornea. The

more recent studies in which cataract surgery was done by phacoemulsification show that it can be done safely without an increased rate of complications.^[5] In this patient, cataract surgery was done by phacoemulsification with the following precautions: (1) small incision size of 2.8 mm; (2) liberal use of sodium hyaluronate 1.4% to protect the corneal endothelium; (3) closure of the corneal tunnel and side ports using 10/0 nylon suture to prevent wound dehiscence (impaired wound healing is a feature of WS);^[6] (4) weak steroids were used postoperatively so as not to suppress fibroblast proliferation. Decreased fibroblast proliferation rate has been proved by cell culture in WS^[2] and could be the cause for impaired wound healing. Endothelial count in LE, 4 months post surgery, showed a 7% (141 cells/mm²) reduction and, in RE, 2 months post surgery, showed a 5% (110 cells/mm²) reduction which falls within the normal range. Studies report endothelial cell loss rates from 4% to 15% after phacoemulsification by experienced surgeons.^[7]

Posterior capsular plaque can be managed by a PPC.^[8] PPC was avoided as the incidence of CME after PPC was higher than without it.^[9] CME has been stated as one of the complications of cataract surgery in WS.^[2] YAG capsulotomy was done in LE, 4 months after surgery. A study carried out by Allan R. Slomovic gives a cell loss of 2.3% after YAG capsulotomy.^[10] In our patient, the cell count showed a 0.48% (9 cells/mm²)

reduction, 4 months after YAG capsulotomy. There was no change in the morphology of the cells. In case of WS with an already compromised cornea, we expected the cell loss to be more than the expected.

The last follow-up 15 months postoperatively in the LE and 9 months postoperatively in the RE showed an 8.6% (174 cells/mm²) decrease in cells in LE and 7.3% (160 cells/mm²) decrease in RE, which is within the normal range of cell loss. We conclude that short-term results after cataract surgery and YAG capsulotomy were excellent with modern microsurgical techniques in a patient with WS. Through this case, we want to highlight that WS should be kept in mind when operating on any patient with features of premature aging and special precautions should be taken when doing the cataract surgery.

Acknowledgement

The author would like to thank the patient for providing consent to use her photograph in this article.

References

1. Rosenthal G, Assa V, Monos T, Biedner B, Lifshitz T, Zirkin H, *et al.* Werner's syndrome. *Br J Ophthalmol* 1996;80:576-7.
2. Ruprecht KW. Ophthalmological aspects in patients with Werner's syndrome. *Arch Gerontol Geriatr* 1989;9:263-70.
3. Yamamoto K, Imakiire A, Miyagawa N, Kasahara T. A report of two cases of Werner's syndrome and review of the literature. *J Orthop Surg* 2003;11:224-33.
4. Moghimi S, Soleimani M, Soltani R. UBM study in spontaneous bleb formation and blebitis after cataract surgery in Werner syndrome. *Eye (Lond)* 2009;23:1481-3.
5. Kocabora MS, Kürkçüoğlu AR, Engin G, Yilmazlı C, Arslan O. Cataract surgery by phacoemulsification in Werner's syndrome. *J Fr Ophtalmol* 2000;23:1012-5.
6. Wollina U, Gruner M, Koch A, Köstler E, Hubl W, Hanson NB, *et al.* Topical PDGF BB results in limited healing in a patient with Werners syndrome and chronic leg ulcers. *J Wound Care* 2004;13:415-6.
7. Brien PD, Fitzpatrick P, Kilmartin DJ, Beatty S. Risk factors for endothelial cell loss after phacoemulsification surgery by a junior resident. *J Cataract Refract Surg* 2004;30:839-43.
8. Peng Q, Hennig A, Vasavada AR, Apple DJ. Posterior capsular plaque: A common feature of cataract surgery in developing world. *Am J Ophthalmol* 1998;125:621-6.
9. Kraff MC, Sanders DR, Jampol LM, Lieberman HL. Effect of primary capsulotomy with extracapsular surgery on the incidence of pseudophakic cystoid macular edema. *Am J Ophthalmol* 1984;98:166-70.
10. Slomovic AR, Parrish RK 2nd, Forster RK, Cubillas A. Neodymium-YAG laser posterior capsulotomy. Central corneal endothelial cell density. *Arch Ophthalmol* 1986;104:536-8.

Cite this article as: Kemmanu V, Nagappa S, Hegde K, Yadav NK, Shetty BK. Endothelial cell study in a case of *Werner's syndrome* undergoing phacoemulsification and Yttrium-Aluminum-Garnet laser capsulotomy. *Indian J Ophthalmol* 2012;60:570-2.

Source of Support: Nil. **Conflict of Interest:** None declared.