

## CASE REPORT

# Case report: Bilateral simple Syndactyly in a toddler with maternal exposure to cabergoline

Shima Afshar<sup>1</sup> | Mohammad Abbasinazari<sup>1</sup> | Behnam Darvishi<sup>2</sup> | Shadi Ziaie<sup>1</sup> | Hadi Esmaily<sup>1</sup> 

<sup>1</sup>Department of Clinical Pharmacy, School of Pharmacy, Shahid Beheshti University of Medical Sciences, Tehran, Iran

<sup>2</sup>Department of Orthopedics, Rasoul Akram Hospital, Iran University of Medical Sciences, Tehran, Iran

## Correspondence

Hadi Esmaily, Department of Clinical Pharmacy, School of Pharmacy, Shahid Beheshti University of Medical Sciences, Tehran, Iran.  
Email: [Esmaily\\_hadi@sbmu.ac.ir](mailto:Esmaily_hadi@sbmu.ac.ir)

## Funding information

None

## Abstract

Cabergoline is routinely prescribed in the management of prolactin excreting adenomas and is associated with low risk of congenital malformations and teratogenicity. Here, we reported the case of a bilateral simple syndactyly in a toddler with maternal exposure to cabergoline during the pregnancy. This association has not been previously described before.

## KEYWORDS

cabergoline, malformation, pregnancy, Syndactyly

## 1 | INTRODUCTION

Prolactin-excreting adenomas (prolactinoma) are among the most frequently occurring pituitary tumors of women in the reproductive age.<sup>1</sup> As a cause, hyperprolactinemia can affect the hypothalamic-pituitary-ovarian axis at multiple stages, which is in charge of about one-third of whole female infertility cases.<sup>2</sup> Despite difficulties in confirmation of hyperprolactinemia, it is predicted that about 15% of women with anovulation and 43% of them with anovulation and galactorrhea suffer from hyperprolactinemia.<sup>3</sup> Although appropriate treatment can reinstate reproductivity, management of prolactinomas during pregnancy is still challenging. Bromocriptine is a drug used in management of idiopathic or tumoral hyperprolactinemia, which safety has been demonstrated in multiple studies.<sup>4-8</sup> Nevertheless, with introduction of cabergoline (a long-acting agonist of the dopaminergic

system) in early 90's, bromocriptine was eventually replaced and preserved as an alternative option in management of hyperprolactinemia due to a lower efficacy and worse profile of adverse effects, especially, gastrointestinal related ones.<sup>9,10</sup>

So far, a number of studies have examined the safety profile of cabergoline administration in management of prolactinomas during gestation period.<sup>11-14</sup> In most of these studies, cabergoline was reported to be well tolerated by mothers and safe in normal age pregnancies, not introducing serious adverse effects, remarkable malformations or teratogenicity up to the end of the follow-up period.<sup>15</sup> Despite this, based on European Registry of Congenital Anomalies and Twins (EUROCAT) and Latin-American Collaborative Study of Congenital Malformations (ECLAMC), major abnormalities occur in 2.2% and 2.66% (excluding Chile) or 2.88% (including Chile) of pregnant women exposed to cabergoline

This is an open access article under the terms of the [Creative Commons Attribution-NonCommercial-NoDerivs](https://creativecommons.org/licenses/by-nc-nd/4.0/) License, which permits use and distribution in any medium, provided the original work is properly cited, the use is non-commercial and no modifications or adaptations are made.

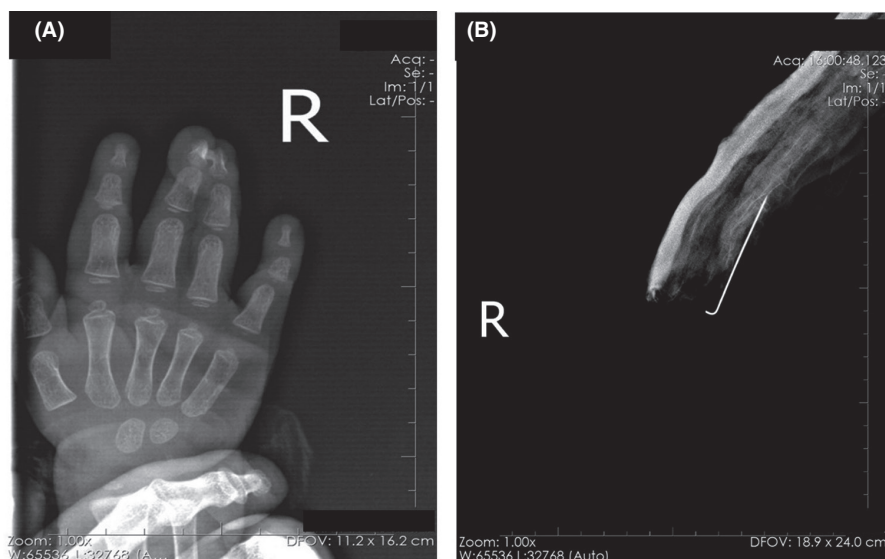
© 2022 The Authors. *Clinical Case Reports* published by John Wiley & Sons Ltd.

during gestation period, respectively.<sup>16</sup> Consistently, examining 49 newborn infants from women receiving cabergoline therapy, occurrence of one major and one minor malformations was confirmed by Ricci et al.<sup>12</sup> Similarly, 2 major and 5 minor malformations was spotted by Robert et al. upon the examination of 148 newborn infants born out of mothers treated by cabergoline during pregnancy.

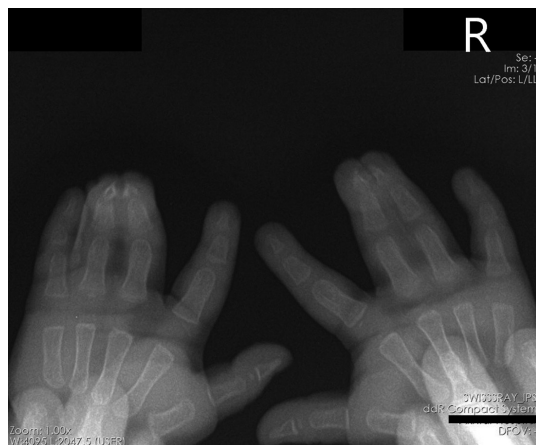Syndactyly, composed of Greek *Syn* (meaning together) and *Dactylos* (meaning digit), refers to an abnormal condition of digits formation in which nearby fingers and/or toes are netted owing to an impaired separation step during limb development. Although the informally reported prevalence rate is estimated to be about 10–40 cases per 10,000 births, globally speaking, syndactyly occurs in about 3–10 cases from a total of 10,000 newborns. Excluding environmental predisposing factors and exposure to certain medicines or toxins in utero, Syndactyly is generally a shared feature of more than 300 hereditary syndromic malformations inherited genetic disorder and can be classified according to a range of characteristics associated with the developmental deformity, some of which include anatomical, descriptive, embryological, genetic and clinical approaches.<sup>17</sup> In this context, a range of combinations may occur through which the nearby fingers and/or toes will be fused or remain webbed together. Moreover, they can be unilateral or bilateral, and symmetrical or asymmetrical. The condition can become even more complex considering that a single patient can exhibit asymmetrical phenotypes in the upper and lower, and right and left limbs. Finally, syndactyly can be observed as cutaneous or bony, partial or complete, affecting merely phalanges or further expanding to metacarpal/metacarpal or carpal/tarsal locations.<sup>18</sup>

## 2 | CASE REPORT

A 24-month-old male toddler was referred to the pediatric orthopedic clinic with chief compliance of webbed ring and middle fingers (third and fourth digits) of both hands, which was extended past the distal interphalangeal joint without incidence of synonychia (Figure 1A). X-ray radiography images obtained from upper limb extremities did not specify any remarkable fusions in bones (Figure 1A and B), specifying extend of the complication limited to the soft tissue. In further examinations, no remarkable shortening in netted digits was observed and the range of motility at related joints (i.e., metacarpophalangeal, proximal and distal interphalangeal) was intact. During general examination, no specific syndromic features were diagnosed and no syndactyly was specified in lower limbs. Inspection of the feet and contralateral hand were also ordinary. Based on these findings, syndactyly was diagnosed as a complete simple bilateral cutaneous syndactyly since the whole proximodistal length of the adjacent third and fourth metacarpals and phalanges were attached; appeared alike and in the same region on both hands; and no fusion of bones or abnormal extra bone formation was occurred (Figure 2). The toddler was born out of a non-consanguineous marriage and delivery had been occurred at term. Additionally, no familial history of congenital malformations was spotted upon the investigation of the toddler parent's phylogenetic tree. Speculation of his mother's past medical history did not specify any unintentional exposure to cytotoxic agents, toxins, biomolecules, or habitual cigarette smoking or alcohol consumption and genetic studies confirmed normal male karyotype at 550 band level: 46, XY with standard chromosome morphology in the toddler. Curious about the underlying reason for the event, we examined previous medical statements of the mother and found that she



**FIGURE 1** Radiographic images from the Right hand. (A, B) Skin syndactyly of the third and fourth fingers together with fusion of the bone is evident



**FIGURE 2** Radiographic image from both hands, confirming a complex bilateral and symmetrical syndactyly in the neonate

had been previously diagnosed as a case of pituitary macroadenoma and was prescribed cabergoline 0.5 mg orally twice a week by an endocrinologist for 6 months including the first trimester of the pregnancy. Since cabergoline has been reported to be associated with gestational abnormalities in previous studies and case reports and there were no other important underlying chronic disorders, deleterious habitual behaviors, or serious medical consumptions (limited to famotidine and ondansetron tablets prescription), it is greatly concludable that the exposure to cabergoline during the first trimester may be the main etiology underlying development of syndactyly in the male toddler of the present study.

### 3 | DISCUSSION

As mentioned before, dopamine agonists are the golden standard for treating prolactinomas during gestation period while cabergoline, in comparison to bromocriptine, is associated with a lower abortion risks and congenital malformations. Few reports in association with cabergoline-induced congenital malformations have been reported in literature. In an observational, retrospective, multicenter study performed by Stalldecker et al., 103 pregnancies were studied in 90 women with hyperprolactinemia, which were all treated with cabergoline at the time of conception. The duration of cabergoline therapy prior to the confirmation of pregnancy ranged between 1–120 months and administered doses ranged between 0.125 up to 5 mg/week. While fetal exposure to cabergoline ranged between 3 to 25 weeks, 96.9% of the pregnant women were exposed to cabergoline during the first trimester and the rest were exposed until the end of the second trimester. The authors reported that among one hundred and three studied cases,

seven (7.2%) had spontaneous abortion, eight (8.8%) had preterm deliveries and one (6.8%) had gestational age-associated low weight. Importantly, three major abnormalities including 1 case of Down syndrome and 2 cases of umbilical and inguinal hernia were recorded in newborn infants.<sup>16</sup> Similarly, although no statistically significant differences were reported between the incidence rate of neonatal malformations in 100 cases of pregnancies initiated at the time of cabergoline consumption, one case of congenital deafness as a consequence of bilateral vestibular aqueducts dilation, one case of right thumb absence due to lack of bone and muscle formation, and one case with left uretero-hydronephrosis was reported by Lebbe et al.<sup>19</sup> Consequently, development of neonatal malformations in patients receiving cabergoline during conception is not unconceivable.

Among the studies describing neonatal abnormalities associated with administration of cabergoline, none has reported syndactyly of the third and fourth fingers (with adhesion of distal interphalangeal joints) so far. Syndactyly is considered to be a failure in the process of the separation of growing digits during the organogenesis phase, which becomes immediately under attention at the birth time as a result of being an explicit limb phenotype.<sup>17</sup> In this disorder, feet are more frequently involved compared to hands and the prevalence rate in male is up to two times more than females. Importantly, syndactyly is a shared characteristic of about more than 300 hereditary syndromic malformations (OMIM), which is frequently used for confirmation of these statements (e.g., F-syndrome, Apert syndrome, Seathre–Chotzen syndrome).<sup>20</sup> Therefore, syndactyly is basically a genetic disorder and is inherited from parents. Considering the familial history of the parents of the 2-year-old toddler of the present study, no cases of syndactyly were reported, and parents were not relatives too. Moreover, the mother of the case presented herein, was a well-nourished one without any history of smoking and drinking, who did the labor in 38 weeks of gestational age. Consequently, occurrence of syndactyly in present case may be strongly associated with the medications prescribed for mother, which comprised of 4 mg ondansetron per oral (PO) thrice daily before each meal, 20 mg famotidine twice daily and 0.5 mg cabergoline once a week during the first trimester of the gestation. Other over the counter supplementary medications including iron, iodine, folic acid, and calcium supplements were also consumed by the mother, which were ignored in overall consideration due to the high safety profile of this medications. Similarly, since no skeletal abnormalities have been reported with famotidine<sup>21</sup> and ondansetron<sup>22</sup> at prescribed doses during pregnancy, cabergoline may be in large part responsible

for development of syndactyly observed in the 2-year-old toddler of the present report.

## 4 | CONCLUSION

The case of the present study was a toddler with developed bilateral simple complete syndactyly whose mother was diagnosed with hyper prolactinoma and prescribed cabergoline during the first trimester of the gestation time. Overall, cases including the one reported in present study, highlight the teratogenic potential of cabergoline prescription as the first choice of treatment in hyper prolactinoma during pregnancy in contrast to the globally accepted impression, which implies that cabergoline is safe to be administered during pregnancy. Hence, based on results represented in this case report, first, it is extremely suggested to preserve cabergoline prescription only for urgent cases during pregnancy and second, further studies are highly required for confirmation of teratogenic potential of cabergoline and safety of its administration during pregnancy.

## ACKNOWLEDGMENTS

None.

## CONFLICT OF INTEREST

The authors hereby declare that there exists no known competing interests or individual relationships, which may have influenced the findings presented in this manuscript.

## AUTHOR CONTRIBUTIONS

SA take role in gathering data, writing the original draft and writing the revised format of the manuscript; MA and BD involved in writing the revised format of the manuscript and editing the original one, as well as supervising the project; SZ took role in gathering data and writing the original draft of the manuscript. HE involved in conceptualization, investigation, writing and editing of the manuscript and supervision.

## ETHICAL APPROVAL

None.

## CONSENT

Written informed consents were obtained from patients for publishing this report according to the journal's patient consent policy.

## DATA AVAILABILITY STATEMENT

Data sharing is not applicable to this article as no new data were created or analyzed in this study.

## ORCID

Hadi Esmaily  <https://orcid.org/0000-0001-6915-6028>

## REFERENCES

- Melmed S, Braunstein GD, Chang JR, Becker DP. Pituitary tumors secreting growth hormone and prolactin. *Ann Intern Med.* 1986;105(2):238-253.
- Kredentser JV, Hoskins CF, Scott JZ. Hyperprolactinemia—a significant factor in female infertility. *Am J Obstet Gynecol.* 1981;139(3):264-267.
- Greer ME, Moraczewski T, Rakoff JS. Prevalence of hyperprolactinemia in anovulatory women. *Obstet Gynecol.* 1980;56(1):65-69.
- Mah PM, Webster J, editors. Hyperprolactinemia: etiology, diagnosis, and management. Seminars in reproductive medicine; 2002: Copyright© 2002 by Thieme Medical Publishers, Inc., 333 Seventh Avenue, New.
- Molitch ME. Medical treatment of prolactinomas. *Endocrinol Metab Clin North Am.* 1999;28(1):143-169.
- Turkalj I, Braun P, Krupp P. Surveillance of bromocriptine in pregnancy. *JAMA.* 1982;247(11):1589-1591.
- Molitch ME. Management of prolactinomas during pregnancy. *J Reprod Med.* 1999;44(12 suppl):1121-1126.
- Gillam MP, Molitch ME, Lombardi G, Colao A. Advances in the treatment of prolactinomas. *Endocr Rev.* 2006;27(5):485-534.
- Ferrari C, Mattei A, Melis GB, et al. Cabergoline: long-acting oral treatment of hyperprolactinemic disorders. *J Clin Endocrinol Metab.* 1989;68(6):1201-1206.
- Ciccarelli E, Giusti M, Miola C, et al. Effectiveness and tolerability of long term treatment with cabergoline, a new long-lasting ergoline derivative, in hyperprolactinemic patients. *J Clin Endocrinol Metab.* 1989;69(4):725-728.
- Colao A, Abs R, Bárcena DG, Chanson P, Paulus W, Kleinberg DL. Pregnancy outcomes following cabergoline treatment: extended results from a 12-year observational study. *Clin Endocrinol.* 2008;68(1):66-71.
- Ricci E, Parazzini F, Motta T, et al. Pregnancy outcome after cabergoline treatment in early weeks of gestation. *Reprod Toxicol.* 2002;16(6):791-793.
- Robert E, Musatti L, Piscitelli G, Ferrari CI. Pregnancy outcome after treatment with the ergot derivative, cabergoline. *Reprod Toxicol.* 1996;10(4):333-337.
- Ono M, Miki N, Amano K, et al. Individualized high-dose cabergoline therapy for hyperprolactinemic infertility in women with micro-and macroprolactinomas. *J Clin Endocrinol Metab.* 2010;95(6):2672-2679.
- Gillam MP, Fideleff H, Boquete HR, Molitch ME. Prolactin excess: treatment and toxicity. *Pediatr Endocrinol Rev.* 2004;2:108-114.
- Stalldecker G, Mallea-Gil MS, Guitelman M, et al. Effects of cabergoline on pregnancy and embryo-fetal development: retrospective study on 103 pregnancies and a review of the literature. *Pituitary.* 2010;13(4):345-350.
- Malik S. Syndactyly: phenotypes, genetics and current classification. *Eur J Hum Genet.* 2012;20(8):817-824.
- Temtam SA. The genetics of hand malformations: updated. *Congenit Anom.* 1985;25:73-92. doi:10.1111/j.1741-4520.1985.tb00636.x
- Lebbe M, Hubinont C, Bernard P, Maiter D. Outcome of 100 pregnancies initiated under treatment with

- cabergoline in hyperprolactinaemic women. *Clin Endocrinol*. 2010;73(2):236-242.
20. Ahmed H, Akbari H, Emami A, Akbari MR. Genetic overview of syndactyly and polydactyly. *Plast Reconstruct Surg Global Open*. 2017;5(11):e1549.
  21. Garbis H, Elefant E, Diav-Citrin O, et al. Pregnancy outcome after exposure to ranitidine and other H2-blockers: a collaborative study of the European Network of Teratology Information Services. *Reprod Toxicol*. 2005;19(4):453-458.
  22. Danielsson B, Wikner BN, Källén B. Use of ondansetron during pregnancy and congenital malformations in the infant. *Reprod Toxicol*. 2014;50:134-137.

**How to cite this article:** Afshar S, Abbasinazari M, Darvishi B, Ziaie S, Esmaily H. Case report: Bilateral simple Syndactyly in a toddler with maternal exposure to cabergoline. *Clin Case Rep*. 2022;10:e05795. doi:[10.1002/ccr3.5795](https://doi.org/10.1002/ccr3.5795)