

Use of anteriolateral wall of maxilla for reconstruction of orbital floor fracture: A clinical study

Department of Oral and Maxillofacial Surgery, Rishiraj Dental College, Bhopal, Madhya Pradesh, 'Sharad Pawar Dental College, Wardha, Nagpur, Maharashtra, India

Anshul Rai, Abhay Datarkar¹

ABSTRACT

Purpose: The aim of the present study was to assess the utility of anterolateral wall of maxilla as a bone graft to reconstruct the continuity of orbital floor. **Materials and Methods:** This study was carried out at Datarkar Institute of Maxillofacial Surgery, Pratap Nagar, Nagpur. Out of five patients selected, three were male and two were female. All the patients had intact anterolateral wall of maxilla on contralateral side. In all the patients the reduction of the zygomatic complex fracture was done by Keen's approach. The fractures were stabilized by miniplates. From the contralateral sides, bone graft of 1.5 × 2 cm size was harvested from which were intact in all the patients. All the patients were reviewed at regular interval, initially once every week for 1 month, followed by once in every month for next 6 months postoperatively. **Results:** Five patients with orbital floor defects of medium size average 1.16 cm size (range 0.8-1.5 cm) were grafted by using autogenous bone graft harvested from anterolateral wall of maxilla. All the patients were successfully reconstructed with restoration of the orbital wall continuity. We have not come across any complications like infection, exposure, and extrusion of the graft. Only one patient did not show much improvement in enophthalmos where the size of the defect was large. **Conclusions:** The use of harvested bone graft from the anterolateral wall of the maxilla is better option for the reconstruction of orbital floor defects.

Key words: Anetriolateral wall of maxilla, autogenous graft, orbital floor reconstruction

Address for correspondence:
Dr. Anshul Rai,
118, Reveira Towne, Near Mata
Mandir, Bhopal - 462 001,
Madhya Pradesh, India.
E-mail: anshulrai007@yahoo.co.in

INTRODUCTION

Trauma to the orbit can result in considerable deformity of the face, but can also result in impairment of the vision. Such kind of trauma may occur in various blunt injuries due to road traffic accidents (RTAs), assault, and sport activity. A true blowout fracture of the orbit involves only the floor of the orbit without involvement of orbital rim or any other associated facial bones. It can also be found in association with multiple facial injuries.^[1] Significant complications can occur as a result of these orbital

injuries such as enophthalmos, persistent diplopia, vertical dystopia, and restriction of globe movements.

The goal of surgical repair of orbital fractures is to restore the traumatized wall to prevent herniation of the contents of the globe into the maxillary sinus, as it causes undesirable fat atrophy, disturbance in the ocular motility, and related complication.^[2] Various autogenous, alloplastic, and allogenic materials have been tried to reconstruct the orbital floor with varying rate of success.

This study was conducted to use an alternative source of autogenous bone graft, with the specific aim to see the efficacy of anterolateral wall maxilla in orbital floor reconstruction. The aim of this paper is to present an alternative source of bone for use in grafting orbital floor defects. We are presenting management of orbital floor fracture compounded with zygomatico-maxillary complex fracture using anterolateral wall of maxilla as bone graft and mini plates for fixation of facial fracture.

Access this article online	
Quick Response Code: 	Website: www.njms.in
	DOI: 10.4103/0975-5950.127646

SUBJECTS AND METHODS

This study was carried out at Datarkar Institute of Maxillofacial Surgery, Pratap Nagar, Nagpur. Informed consent has been taken from all the patients after explaining the advantages and disadvantages of orbital floor reconstruction. Total of five patients reported with history of RTA having facial fractures associated with orbital wall disruption were included in the study. Ethical approval was taken before study planning. Out of five patients selected, three were male and two were female having varied presentation of facial asymmetry, diplopia, decreased extraocular movements, and enophthalmous. All the patients had intact anteriolateral wall of maxilla on contralateral side. Patients were preoperatively examined clinically and evaluated by computed tomography (CT) scan to see the size of the defect [Figure 1]. Forced duction taste was performed to check restricted eyeball movement.

Subciliary incision was used to address orbital rim and floor of orbit. Careful dissection was carried out and

the defect in the floor was visualized. In all the patients the reduction of the zygomatic complex fracture was done by Keen's approach. The fractures were stabilized by miniplates. From the contralateral sides [Figure 2], bone graft [Figure 3] of 1.5×2 cm size was harvested from which were intact in all the patients. Periorbital tissue herniating in the maxillary sinus was disengaged from bony defect and the harvested graft was adapted to the orbital floor [Figure 4]. Closure done in layers after achieving hemostasis. Postoperative recovery was uneventful. Immediate improvement in the facial asymmetry, diplopia, and enophthalmous was observed. All the patients were reviewed at regular interval, initially once every week for 1 month, followed by once in every month for next 6 months postoperatively.

RESULTS

Five patients [Table 1] with orbital floor defects of medium size average 1.16 cm size (range 0.8-1.5 cm) were grafted by using autogenous bone graft harvested

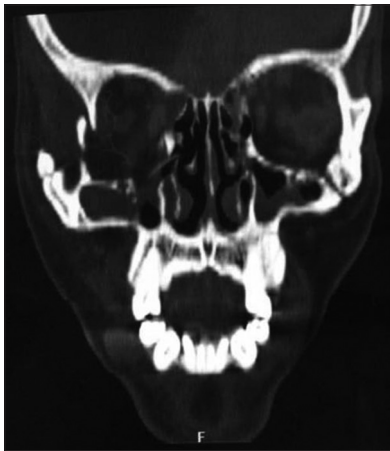

Figure 1: Preoperative computed tomography (CT) showing orbital floor fracture with herniation of contents

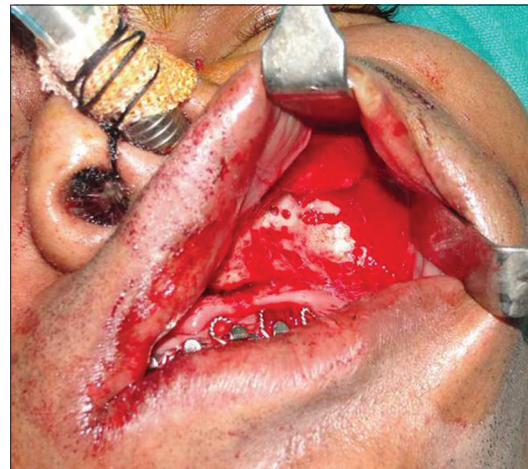


Figure 2: Photograph showing donor site

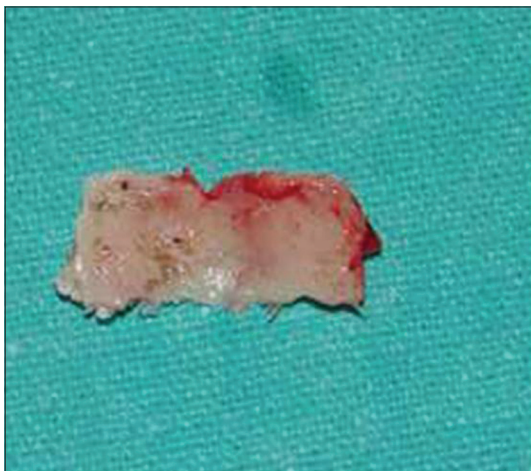

Figure 3: Photograph showing harvested anteriolateral wall of maxilla

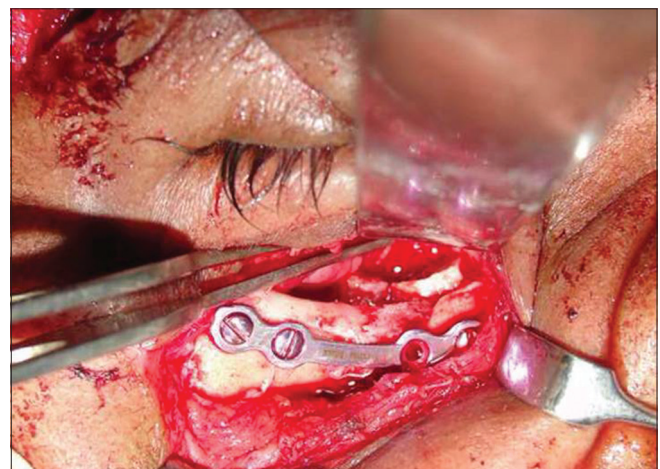


Figure 4: Photograph showing graft placed at orbital floor

Table 1: Pre- and postoperative findings

Name	Age/sex	Preoperative finding			Size of defect, mean (0.8-1.5 cm)	Postoperative finding		
		Facial asymmetry	Diplopia	Enophthalmus		Facial asymmetry	Diplopia	Enophthalmus
AM	25/M	+	+	+	1 cm	-	-	-
DP	36/M	-	-	+	1.2 cm	-	-	-
SN	22/F	+	-	-	0.8 cm	-	-	-
PC	18/F	-	+	+	1.3 cm	-	-	-
VR	28/M	+	+	+	1.5 cm	-	-	+

+: Present, -: Absent, M: Male, F: Female

from anterolateral wall of maxilla. The average follow-up in this study was 6 months (range 5-0 months). All the patients were successfully reconstructed with restoration of the orbital wall continuity. We have not come across any complications like infection, exposure, and extrusion of the graft. The postoperative CT scan showed good consolidation [Figure 5] of the graft maintaining the continuity of the orbital floor. The patients suffering from diplopia also showed significant improvement postoperatively. Only one patient did not show much improvement in enophthalmous where the size of the defect was large.

DISCUSSION

The outcome of repair of orbital floor fracture depends upon proper diagnosis, timing of surgery, appropriate surgical approach, and selection of suitable graft.

Unrepaired orbital wall defects after facial fractures can result in enophthalmous and diplopia because of increased orbital volume, herniation of orbital contents, and atrophy of herniated fat and muscle. Therefore, reconstruction of orbital floor is necessary procedure.^[3]

The timing for orbital floor fracture repair is controversial. Proper surgical timing is a paramount for producing good results, and most of the authors advocate early repair as late treatment would lead to fat atrophy and fibrosis of supporting ligaments.^[4] This may limit the surgeon's ability to completely correct the enophthalmous as well as the position of the globe.^[5]

The basic objective of reconstruction of orbital defect is to restore orbital volume, function, and esthetics.^[6] Orbital floor reconstruction has been achieved using a wide variety of materials which includes cartilage and fascia homograft (autogenous bone graft (Converse, *et al.*, 1961), and alloplastic materials (Borghouts and Otto, *et al.*, 1978). Autogenous graft is a well-established and relatively successful method of repairing orbital defects.^[7] Very few cases of use of anterolateral wall of maxilla as a bone graft for reconstruction of orbital defects has been reported in the literature.

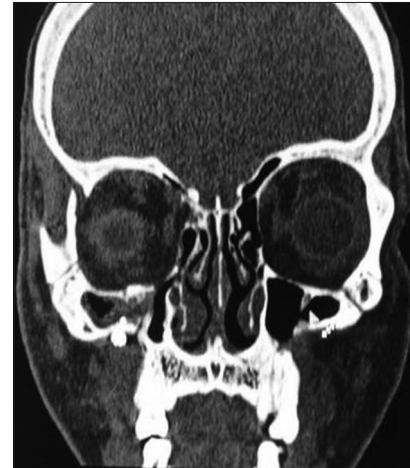

Figure 5: Postoperative CT showing consolidated bone graft at orbital floor

The use of anterolateral wall of maxilla is an easy quicker method of harvesting bone graft. The procedure is done intraorally without any extraoral scar and no donor site morbidity. About 2 × 3 cm of the graft can be harvested which is sufficient for smaller to moderate size defects. Harvesting of the graft is associated with minimal complication and most common amongst them is perforation in maxillary sinus, which subsequently heals uneventfully. Bleeding from the nose is expected during initial 10 days of surgery which itself is collected blood in the antrum after harvesting bone graft.

In the present study it was also observed that the contour of anterolateral wall of maxilla exactly fits the anatomic contour of orbital floor. Several authors reported that membranous bone grafts maintain their volume to a greater extent compared with endochondral bone grafts.^[8-10] The reason for that could be bone grafts of membranous origin have higher cortical bone quality than those of endochondral origin. Moreover, some other authors observed that cortical bone grafts will maintain their volume better than cancellous bone grafts, independent of embryogenic origin.^[11,12]

Zins and Whitaker^[10] found that membranous bone grafts maintain their volume better than endochondral bone grafts when grafted on the rabbit snout. They hypothesized that this was because of the embryologic origin of the bone graft. Using a similar animal model,

they found that membranous bone grafts maintained their volume better than endochondral grafts, and they explained this phenomenon by earlier graft revascularization.

In addition to differences in embryologic origin, endochondral and membranous bone grafts also differ in their micro architecture. Membranous bone tends to have a thicker cortex and a denser, thinner cancellous layer than endochondral bone. Several authors have theorized that a difference in micro architecture is the basis for the differential resorption of bone grafts.^[13-15] This technique provides a readily accessible, easily harvested source of bone for grafting orbital floor defects.

Patient acceptability is very good and ease of intraoral surgery reduces the operating time, postoperative morbidity at donor site is minimal. The graft can be harvested in those patients where contralateral side is normal.

CONCLUSION

The use of harvested bone graft from the anterolateral wall of the maxilla is better option for the reconstruction of orbital floor defects. The clinical and radiographic observations showed a very low rate of bone resorption and significant improvement in diplopia and correction of continuity of orbital floor defect. Therefore, on the basis of this study, authors feel that the membranous origin of the bone from anterolateral wall of maxilla is a good source for reconstruction of moderate size orbital floor defects.

REFERENCES

1. Lerman S. Blowout fracture of the orbit -Diagnosis and treatment. Br J Ophthalmol 1970;54:90-8.
2. Kraus M, Gatot A, Fliss DM. Repair of traumatic inferior orbital wall defects with nasoseptal cartilage. J Oral Maxillofac Surg 1989;5:1397-400.
3. Manson PN, Clifford CM, Su CT, Iliff NT, Morgan R. Mechanism of global support and post traumatic enophthalmos: I The anatomy of the ligament sling and its relation to intramuscular cone orbital fat. Plast Reconstr Surg 1986;77:193-202.
4. Hawes MJ, Dortzbach RK. Surgery on orbital floor fractures. Influence of time of repair and fracture size. Ophthalmology 1983;90:1066-70.
5. Kellman RM, Bersani T. Delayed and secondary repair of post traumatic enophthalmos and orbital deformities. Facial Plast Surg Clin North Am 2002;10:311-23.
6. Cole P, Boyed V, Banerji S, Hollier LH Jr. Comprehensive management of orbital fractures. Plast Reconstr Surg 2007;120:57-63S.
7. Girdler NM, Hosseini M. Orbital floor reconstruction with autogenous bone harvested from the mandibular lingual cortex. Br J Oral Maxillofac Surg 1992;30:36-8.
8. Ilankovan V, Jackson IT. Experience in the use of calvarial bone grafts in orbital reconstruction. Br J Oral Maxillofac Surg 1992;30:92-6.
9. Gosain AK, Song L, Capel CC, Corrao MA, Lim TH. Biomechanical and histological alternation of facial recipient bone after reconstruction with autogenous bone grafts and alloplastic implants: A 1-year study. Plast Reconstr Surg 1998;101:1561-71.
10. Zins JE, Whitaker LA. Membranous versus endochondral bone. Implications for craniofacial reconstruction. Plast Reconstr Surg 1983;72:778-85.
11. Copeland M, Meisner J. Maxillary antral bone grafts for repair of orbital fractures. J Craniofac Surg 1991;2:18-21.
12. Gruss JS. Naso-ethmoid-orbital fractures: Classification and role of primary bone grafting. Plast Reconstr Surg 1985;75:303-17.
13. Hardesty RA, Marsh JL. Craniofacial onlay bone grafting: A prospective evaluation of graft morphology, orientation and embryonic origin. Plast Reconstr Surg 1990;85:5-14.
14. Ozaki W, Buchman SR. Volume maintenance of onlay bone grafts in the craniofacial skeleton: Microarchitecture versus embryologic origin. Plast Reconstr Surg 1998;102:291-9.
15. Chen NT, Glowacki J, Bucky LP, Hong HZ, Kim WK, Yaremchuk MJ. The role of revascularization and resorption on endurance of craniofacial onlay bone grafts in the rabbit. Plast Reconstr Surg 1994;93:714-22.

How to cite this article: Rai A, Datarkar A. Use of anteriolateral wall of maxilla for reconstruction of orbital floor fracture: A clinical study. Natl J Maxillofac Surg 2013;4:173-6.

Source of Support: Nil. **Conflict of Interest:** None declared.