

Good outcome after delayed surgery for orbitocranial non-missile penetrating brain injury

Alessandro Caporlingua, Federico Caporlingua, Jacopo Lenzi

Department of Neurology and Psychiatry, Neurosurgery, "Sapienza" University of Rome, Rome, Italy

ABSTRACT

Nonmissile orbitocranial penetrating brain injuries are uncommonly dealt with in a civilian context. Surgical management is controversial, due to the lack of widely accepted guidelines. A 52-year-old man was hit in his left eye by a metallic foreign body (FB). Head computed tomography (CT) scan showed a left subcortical parietal FB with a considerable hemorrhagic trail originating from the left orbital roof. Surgical treatment was staged; an exenteratio oculi and a left parietal craniotomy to extract the FB under intraoperative CT guidance were performed at post trauma day third and sixth, respectively. A postoperative infectious complication was treated conservatively. The patient retained a right hemiparesis (3/5) and was transferred to rehabilitation in good clinical conditions at day 49th. He had suspended antiepileptic therapy at that time. A case-by-case tailored approach is mandatory to achieve the best outcome in such a heterogeneous nosological entity. Case reporting is crucial to further understand its mechanism and dynamics.

Key words: Brain abscess, foreign body, intracranial, orbitocranial, penetrating brain injury

Introduction

Nonmissile penetrating orbitocranial brain injury is rare among civilians.^[1-3] We present the case of a right-handed 52-year-old man hit by a piece of iron thread with a left transorbital frontoparietal lobe trajectory. The most recent guidelines are drawn from the experience matured with missile foreign bodies (FBs) injuries frequently encountered in war scenarios.^[2,4] We provide the description of a rare case and discuss the rationale standing behind our conduct regarding the timing of surgery, surgical technique, and drug prophylaxis.

Case Report

A 52-year-old man was hit to his left eye by an unknown FB losing consciousness while tending to his grass field. On physical examination, wound inspection confirmed a left ocular globe entry point. No exit wound was found. Admission

head computed tomography (CT) scan [Figure 1] showed a 4 cm hyperdense thin elongated FB located into the frontal and parietal lobes. On neurologic examination, the patient opened his right eye on verbal stimulus, attempted to verbalize and followed simple orders with his right hemisoma. The left ocular globe presented a large laceration; thus, the eye was not viable. The sight was conserved with his right eye. Prophylaxis with ampicilline-sulbactam and valproate, respectively, was started. On day third, the patient underwent a left orbital globe excision surgery. An ocular expander was secondarily placed in preparation for an ocular prosthesis. On day sixth, a parasagittal left parietal craniotomy was performed under intraoperative neuronavigation. A parasagittal corticectomy allowed extracting a 4-cm long piece of iron thread [Figure 2]. Head CT scan on a postoperative day third showed no surgical complications [Figure 3]. On day 12, a brain magnetic resonance imaging was performed upon deterioration of neurologic conditions. Contrast enhanced sequences showed considerable frontotemporoparietal edema and enhancement of the entire trail that was strongly in favor of an infective complication,

Access this article online	
Quick Response Code:	Website: www.asianjns.org
	DOI: 10.4103/1793-5482.179641

Address for correspondence:

Dr. Federico Caporlingua, Via del Policlinico 155,
00161 Rome, Italy.
E-mail: capor51@gmail.com

This is an open access article distributed under the terms of the Creative Commons Attribution-NonCommercial-ShareAlike 3.0 License, which allows others to remix, tweak, and build upon the work non-commercially, as long as the author is credited and the new creations are licensed under the identical terms.

For reprints contact: reprints@medknow.com

How to cite this article: Caporlingua A, Caporlingua F, Lenzi J. Good outcome after delayed surgery for orbitocranial non-missile penetrating brain injury. Asian J Neurosurg 2016;11:309.

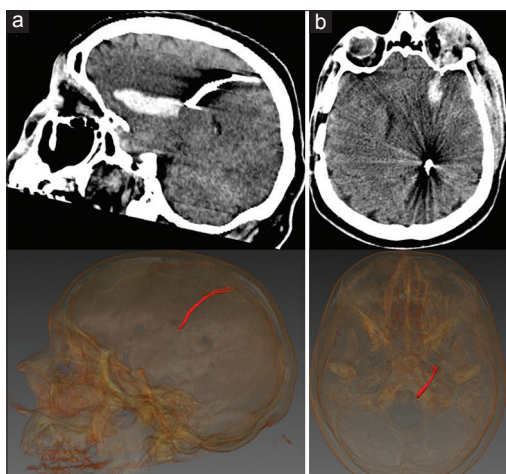


Figure 1: Admission head computed tomography scan, (a) sagittal and (b) axial cuts with three-dimensional reconstructions, showing a hyperdense thin elongated 4-cm long foreign body penetrated through the left orbit in the intracranial space leaving a considerable frontoparietal hemorrhagic trail. Note, a preexisting right frontotemporal craniotomy performed 10 years prior to present to clip a right middle cerebral artery unruptured aneurysm

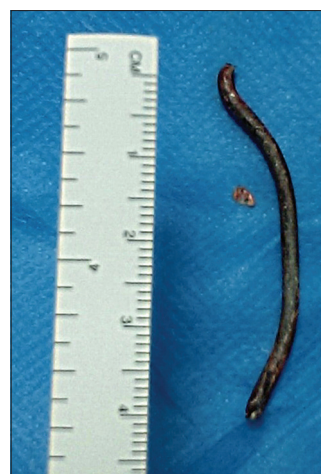

Figure 2: A 4-cm long piece of iron thread was extracted through a left parasagittal parietal craniotomy

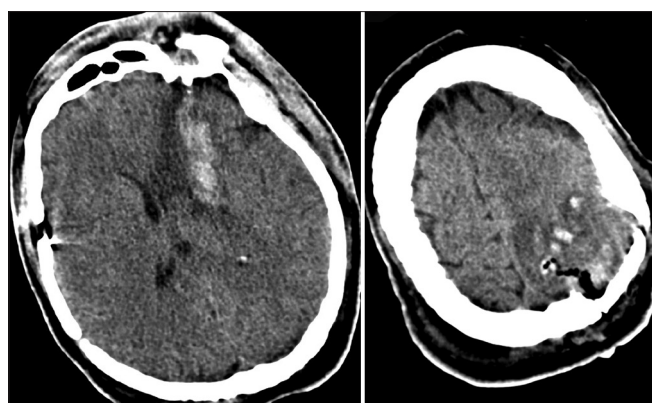


Figure 3: Postoperative day 3 control head computed tomography scan. Extraction of the foreign body was achieved with 5.5 × 5.5 cm parasagittal parietal craniotomy. Note multiple subcentimetric hemorrhagic foci of the operative field. On the right, an axial cut showing stability of the preexisting hemorrhagic trail left by the foreign body

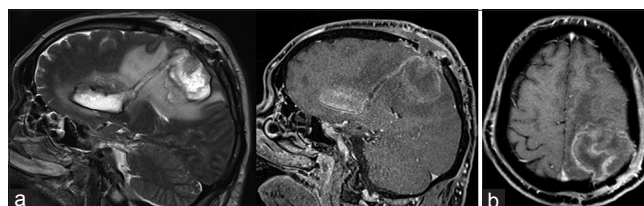


Figure 4: Postoperative day 12 brain magnetic resonance imaging performed upon neurologic deterioration. (a) Sagittal T2 cut showing foreign body frontoparietal trajectory; (b) gadolinium sagittal and axial cuts showing postcontrastographic enhancement strongly suggesting an on-going infectious complication

without signs of brain herniation [Figure 4]. Antibiotic therapy with meropenem and linezolid was started suspending ampicilline-sulbactam. During the following days, neurologic conditions progressively ameliorated until postoperative day thirtieth when the patient was transferred to our neurology department. He was discharged at day 49th to a rehabilitation clinic. At that time, the patient was on a wheelchair, alert, responsive and able to speak [Figure 5]. He had a right hemiparesis (3/5). After 6 months, the patient walked alone with the aid of a can and had a slight dysarthria [Figure 6].

Discussion

Nonmissile penetrating brain injuries are exceedingly rare in a civilian setting.^[3] Most often resulting from violence,

accidents or suicide attempts, they are deemed far better than high velocity penetrating brain injury.^[2] Taking into consideration orbit anatomy, the chance of an FB traveling at low velocities to be deviated toward the neurovascular structures are not negligible. In our case, the FB pierced the orbital roof, suggesting that either its trajectory started from the ground level or that the patient instinctively extended the head thus exposing the orbital roof during trauma.^[1] Moreover, the hemorrhagic trail started from the base of the frontal lobe, not involving the middle line or major vascular trunks and not causing a subarachnoid hemorrhage. Given the absence of risk factors for major vascular injuries,^[5] we decided not to perform a CT angiography.

Broad-spectrum antibiotic therapy should be instituted as soon as possible in patient benefit index (PBI) patients.^[2] Large retrospective series of civilian PBI reported a prevalence of one to five percent of infectious complications under broad-spectrum antibiotic therapy.^[6,7] Despite that, the role of prophylactic antibiotics has been questioned.^[8] Therapy with ampicilline-sulbactam was administered since patient's admission and later substituted with meropenem and linezolid when facing the evidence of cerebral abscess. We judged unnecessary to perform additional surgical procedure as the

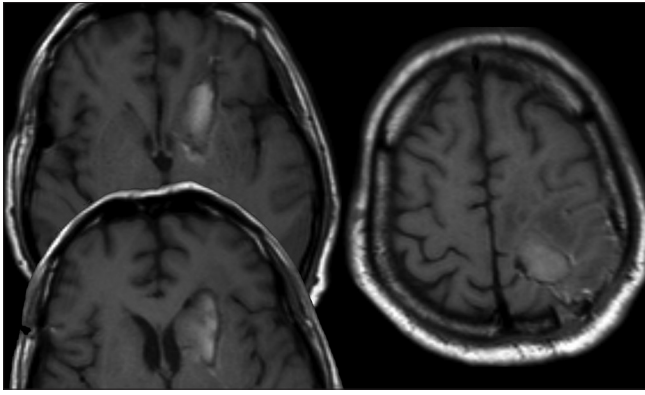


Figure 5: Brain magnetic resonance imaging at discharge. T1-weighted axial cuts

patient responded positively to pharmacological measures alone.

The severity of the PBI (Glasgow Coma Scale) seems to influence the likely of post traumatic epilepsy,^[2,9] whose prevalence may get to 30–50% including both early and delayed forms.^[9] Our patient received valproate from post trauma day 1; anticonvulsant therapy was discontinued after an electroencephalographic study conducted at 1 month from discharge. Interestingly enough, Chibbaro *et al.*^[1] reported no epileptic complications during 13-year follow-up in 18 nonmissile orbitocranial PBI; none of the patients received prophylactic anticonvulsant treatment.

Surgical removal of FB should be performed within 12 h from the trauma to minimize the risk of infectious complications.^[2] Nevertheless, debris removal in eloquent areas distant from the entry point exposes patients to a worse outcome.^[2,10,11] In these cases, primary treatment should focus on intracranial hypertension prevention. However, ultra-early FB extraction surgery may pose some issues as FB extraction may trigger hardly manageable bleeding, especially when an involvement of major arterial trunks is suspected. The decision to delay FB surgical extraction was taken in an effort to avoid the need of a large hemispheric craniectomy, whose indication would have been mandatory in the acute setting when operating on a so-called “angry brain”. We presumed that a craniectomy would have surely had a positive repercussion on intracranial pressure, but at the same time, we feared the eventuality of an uncontrollable hemorrhage starting from the FB deep trail triggered by the sudden surgically-induced pressure gradient modification. Moreover, by reducing the extension of the operative field to a localized craniotomy, we hoped to reduce the risk of an infective complication, which would have had spread to the entire left hemisphere if a large hemispheric craniectomy was performed in the first place. By any mean, conservative treatment allowed postponing surgery until a small craniotomy was deemed feasible.^[12]



Figure 6: The patient at 6-month follow-up

To achieve the smallest possible craniotomy, the surgeons were guided by the intraoperative neuronavigation.

Despite the head CT scan showed an orbital roof fracture with frontobasal dural defect, the patient did not suffer from CSF leakage. The risk of developing CSF leakage is actually low.^[7] We decided not to take any surgical prophylactic measure toward the osseous and dural defect, a decision consistent with third authors’ opinion on the subject.^[13]

PBI management is controversial, and most of the currently available guidelines and recommendations have been drawn from a noncivilian context and involves, for the most part, missile PBI. We obtained a good outcome avoiding ultra-early decompressive surgery given the clinico-radiological setting, and waiting until the surgical access allowing FB extraction could have been reduced to a minimum.

Declaration of patient consent

The authors certify that they have obtained all appropriate patient consent forms. In the form the patient(s) has/have given his/her/their consent for his/her/their images and other clinical information to be reported in the journal. The patients understand that their names and initials will not be published and due efforts will be made to conceal their identity, but anonymity cannot be guaranteed.

Financial support and sponsorship

Nil.

Conflicts of interest

There are no conflicts of interest.

References

1. Chibbaro S, Tacconi L. Orbito-cranial injuries caused by penetrating non-missile foreign bodies. Experience with eighteen patients. *Acta Neurochir (Wien)* 2006;148:937-41.
2. Management of penetrating brain injury. *J Trauma* 2011;4:395-402.
3. Abdoli A, Amirjamshidi A. Work-related penetrating head trauma

- caused by industrial grinder tool. Arch Iran Med 2009;12:496-8.
4. Part 1: Guidelines for the management of penetrating brain injury. Introduction and methodology. J Trauma 2001;51 2 Suppl: S3-6.
 5. Bodanapally UK, Saksobhavit N, Shanmuganathan K, Aarabi B, Roy AK. Arterial injuries after penetrating brain injury in civilians: Risk factors on admission head computed tomography. J Neurosurg 2015;122:219-26.
 6. Antibiotic prophylaxis for penetrating brain injury. J Trauma 2001;51 2 Suppl: S34-40.
 7. Amirjamshidi A, Abbassioun K, Roosbeh H. Air-gun pellet injuries to the head and neck. Surg Neurol 1997;47:331-8.
 8. Jimenez CM, Polo J, España JA. Risk factors for intracranial infection secondary to penetrating craniocerebral gunshot wounds in civilian practice. World Neurosurg 2013;79:749-55.
 9. Antiseizure prophylaxis for penetrating brain injury. J Trauma 2001;51 2 Suppl: S41-3.
 10. Amirjamshidi A, Ghasvini AR, Alimohammadi M, Abbassioun K. Attempting homicide by inserting sewing needle into the brain report of 6 cases and review of literature. Surg Neurol 2009;72:635-41.
 11. Amirjamshidi A. Attempting homicide by inserting sewing needles into the brain. Neurosurgery 2013;72:E143-4.
 12. Amirjamshidi A, Abbassioun K, Rahmat H. Minimal debridement or simple wound closure as the only surgical treatment in war victims with low-velocity penetrating head injuries. Indications and management protocol based upon more than 8 years follow-up of 99 cases from Iran-Iraq conflict. Surg Neurol 2003;60:105-10.
 13. Schreckinger M, Orringer D, Thompson BG, La Marca F, Sagher O. Transorbital penetrating injury: Case series, review of the literature, and proposed management algorithm. J Neurosurg 2011;114:53-61.