

The earliest timing of ultrasound in screening for developmental dysplasia of the hips

Si Heng Sharon Tan, Keng Lin Wong, Andrew Kean Seng Lim, James HoiPo Hui

Department of Orthopaedic Surgery, University Orthopaedic, Hand and Reconstructive Microsurgery Cluster, National University Health System (NUHS), Singapore

ORIGINAL ARTICLE

<https://doi.org/10.14366/usg.18075>
pISSN: 2288-5919 • eISSN: 2288-5943
Ultrasonography 2019;38:321-326

Purpose: The current study aimed to evaluate the results of ultrasound screening for developmental dysplasia of the hips (DDH) done at various weeks of life, to determine the earliest time that ultrasound screening can be performed reliably.

Methods: In this 17-year cohort study, all neonates who underwent ultrasound screening prior to the 12th week of life with subsequent follow-up radiography done at 1 year of life were included. The ultrasound images were evaluated according to the Graf classification, Harcke's dynamic ultrasound screening method, and Terjesen's femoral head coverage method. The radiographic images were evaluated according to the acetabular index and the femoral head position. The accuracy and correlation between the ultrasound findings from various weeks of life with the radiographic findings at 1 year of life were evaluated.

Results: A total of 348 neonates were included in the study, of whom 92 had abnormal ultrasound findings and 42 had abnormal radiographic findings at 1 year. Significant differences were identified between the findings of ultrasound screening examinations performed prior to the fourth week of life (day 21 and before) and the radiographic findings at 1 year of life ($P < 0.05$). In contrast, no significant differences were identified when ultrasound screening was performed between the fourth and 12th weeks of life (day 22 and beyond) ($P > 0.05$). The accuracy of ultrasound screening was 79.2% or higher when performed during or after the fourth week of life (day 22 and beyond).

Conclusion: The earliest that ultrasound screening for DDH can be performed reliably is during the fourth week of life (day 22 and beyond).

Keywords: Hip dysplasia; Screening; Imaging; Ultrasonography; Radiography

Received: December 7, 2018

Revised: February 27, 2019

Accepted: March 3, 2019

Correspondence to:

Si Heng Sharon Tan, MBBS, MRCS,
Department of Orthopaedic Surgery,
National University Health System, 1E
Kent Ridge Road, NUHS Tower Block
Level 11, 119074, Singapore

Tel. +65-67795555

E-mail: sharon_sh_tan@nuhs.edu.sg

This is an Open Access article distributed under the terms of the Creative Commons Attribution Non-Commercial License (<http://creativecommons.org/licenses/by-nc/4.0/>) which permits unrestricted non-commercial use, distribution, and reproduction in any medium, provided the original work is properly cited.

Copyright © 2019 Korean Society of
Ultrasonography in Medicine (KSUM)

Introduction

Developmental dysplasia of the hip (DDH) is a common paediatric orthopaedic condition [1]. It represents a broad spectrum of conditions, ranging from congenital dislocation of the hips to occult acetabular dysplasia [1–3]. Left untreated, DDH can lead to long-term morbidities, including chronic pain, gait abnormalities, and degenerative arthritis [1,4]. Conversely, early diagnosis and management of DDH can potentially avert these morbidities [1,4,5].



How to cite this article:

Tan SHS, Wong KL, Lim AKS, Hui JH. The earliest timing of ultrasound in screening for developmental dysplasia of the hips. Ultrasonography. 2019 Oct;38(4):321-326.

Neonatal screening for DDH has therefore been widely accepted and practised worldwide [1,4,5]. However, the timing of ultrasound screening as part of the neonatal screening programme for DDH remains an ongoing topic of debate [6–9]. Ultrasound screenings that are performed too early can lead to a high incidence of false-positive or false-negative results, resulting in unnecessary anxiety, follow-up examinations, and financial burden [7,8]. In contrast, ultrasound screenings that are performed too late can result in delayed treatment, increasing the need for more invasive management, such as surgery, as well as imposing a financial burden [7,8]. Despite the extensive literature available on ultrasound screening for DDH, no consensus exists regarding the ideal timing for ultrasound screening to be performed [8].

The current study therefore aimed to evaluate the results of ultrasound screening done at various weeks of life, with the goal of determining the earliest time that ultrasound screening can be performed reliably. The hypothesis was that the fourth week of life would be the earliest time that ultrasound screening could be performed reliably, and that ultrasound screening performed prior to the fourth week of life would correlate poorly with the eventual presence or absence of DDH.

Materials and Methods

This study was performed in accordance with the ethical standards established by the institution's research committee. A waiver of consent was obtained for the 17-year retrospective study.

In this 17-year retrospective cohort study, all neonates who underwent ultrasound screening prior to the 12th week of life with a subsequent follow-up radiograph done at 1 year of life were included. Patients with other concomitant hip abnormalities were excluded. Patients who received treatment prior to the radiographs performed at 1 year of life were also excluded to minimise the confounding factor of treatment effect.

All neonates born at our institution were assessed for risk factors and examined clinically at birth. Patients with suspected DDH due to either a positive clinical examination or the presence of risk factors were scheduled for bilateral hip ultrasound and a repeat clinical examination prior to the 12th week of life, followed by eventual radiography and a clinical examination at 1 year of life. A positive clinical examination was defined as a positive Barlow test, a positive Ortolani test, or the presence of clicking hips. The risk factors included female sex, post-term birth, high birth weight, high birth length, macrocephaly, breech presentation, twins, firstborn status, oligohydramnios, torticollis, congenital talipes equinovarus, or a positive family history. These factors were assessed by a neonatologist and confirmed by a paediatric orthopaedic surgeon.

A fellowship-trained musculoskeletal radiologist blinded to the study's purpose reviewed the ultrasound and radiographic images. The ultrasound images were evaluated according to Graf's method, Harcke's method of dynamic ultrasound screening, and Terjesen's method of evaluation for femoral head coverage [10]. The ultrasound findings were considered abnormal if they were classified as abnormal for any of these three parameters. For the Graf classification, the alpha and beta angles, which are quantitative indicators of the bony and cartilaginous acetabular roofs, were evaluated [11]. Hips with an alpha angle more than 60° and beta angles less than 55° were classified as Graf type 1 hips, and therefore considered to be normal [11]. In contrast, hips with an alpha angle less than 50° or beta angles more than 77° were classified as Graf type 2C and beyond, and were therefore considered to be abnormal [11]. Patients with Graf type 2A hips, which are hips with alpha angles between 50° and 60° and beta angles between 55° and 77° , were considered to have immature hips, and the eventual classification of whether the hips were considered to be normal or abnormal (i.e., with DDH) was dependent on the 2 other parameters reviewed [11]. In Harcke's dynamic ultrasound screening method, frontal and transverse images were obtained both at rest and in stress [12]. The hips were then classified as normal, subluxated, or dislocated according to the views [12]. Hips that were classified as subluxated or dislocated were considered abnormal [12]. In Terjesen's method, femoral head coverage was calculated as the percentage of coverage of the cartilaginous femoral head by the acetabular bony roof [13]. A femoral head coverage of 50% or more was considered normal, while a femoral head coverage of less than 50% was considered abnormal [13].

The radiographic images were evaluated according to the acetabular index, as well as the position of the femoral head. The radiographic findings were considered abnormal if they were classified as abnormal according to either of the parameters. The acetabular index was measured as the angle formed by the horizontal line connecting the bilateral triradiate cartilages and the line along the acetabular roof. An acetabular index of more than 28° at 1 year of life was considered dysplastic, according to the study conducted by Tonnis [14]. Acetabular index values of less than or equal to 28° were therefore considered normal, while acetabular index values of more than 28° were considered abnormal. The Hilgenreiner, Perkin, and Shenton lines were used to assess the position of the femoral head. The Hilgenreiner line is a horizontal line connecting the bilateral triradiate cartilages. The Perkin line runs perpendicular to the Hilgenreiner line intersecting the most lateral aspect of the acetabular roof. The Shenton line is drawn along the inferior border of the superior pubic ramus and along the inferomedial border of the neck of the femur. The position

of the femoral head was considered normal if it was inferomedial to the Hilgenreiner and Perkin lines, and if the Shenton line was in continuity. In contrast, the position of the femoral head was considered abnormal if it was not inferomedial to the Hilgenreiner and Perkin lines, or if the Shenton line was not in continuity.

SPSS version 23.0 (IBM Corp., Armonk, NY, USA) was used for the statistical analysis. The McNemar exact test was performed to evaluate the correlations between the ultrasound findings obtained at the various weeks of life with the radiographic findings obtained at 1 year of life. P-values of <0.05 were considered to indicate statistical significance. The accuracy of the ultrasound screening was also calculated and reported, along with 95% confidence intervals.

Results

A total of 348 neonates were included in the study, of whom 92 had

abnormal ultrasound findings and 42 had abnormal radiographic findings at 1 year.

Forty-four patients had ultrasound performed in the first week of life (days 0–7), 52 patients had ultrasound performed in the second week of life (days 8–14), 16 patients had ultrasound performed in the third week of life (days 15–21), 36 patients had ultrasound performed in the fourth week of life (days 22–28), 32 patients had ultrasound performed in the fifth week of life (days 29–35), 36 patients had ultrasound performed in the sixth week of life (days 36–42), 40 patients had ultrasound performed in the seventh week of life (days 43–49), 24 patients had ultrasound performed in the eighth week of life (days 50–56), 20 patients had ultrasound performed in the ninth week of life (days 57–64) and 48 patients had ultrasound performed in the 10th week of life and beyond (days 65 and beyond).

Table 1 and Fig. 1 detail the number and percentage of patients

Table 1. Accuracy and correlation of ultrasound screening at various weeks of life with radiographic findings at 1 year of life

Timing of ultrasound (wk)	Ultrasound (positive/negative)	Radiograph (positive/negative)	McNemar's test (P-value)	Accuracy (95% CI)
First	22/22	6/38	<0.001	54.6 (38.9–69.6)
Second	20/32	6/46	<0.001	73.1 (59.0–84.4)
Third	6/10	0/16	0.041	62.5 (35.4–84.8)
Fourth	6/30	2/34	0.134	88.9 (73.9–96.9)
Fifth	6/26	6/26	0.999	100.0 (89.1–100.0)
Sixth	6/30	4/32	0.480	94.4 (81.3–99.3)
Seventh	12/28	8/32	0.134	90.0 (76.3–97.2)
Eighth	2/22	0/24	0.480	91.7 (73.0–99.0)
Ninth	4/16	4/16	0.999	100.0 (83.2–100.0)
Tenth	8/40	6/42	0.752	79.2 (65.0–89.5)

CI, confidence interval.

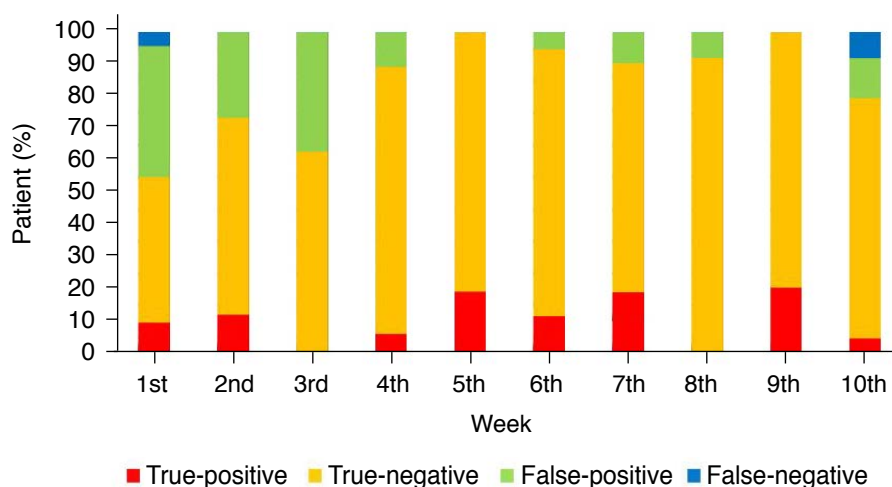


Fig. 1. The correlation and accuracy of the ultrasound screening at the various weeks of life.

with positive and negative ultrasound screening findings at various weeks of life, as well as their correlations with the radiographic findings at 1 year of life. Significant differences were observed between the findings of ultrasound screening examinations performed prior to the fourth week of life (day 21 and before) and the radiographic findings at 1 year of life ($P < 0.001$, $P < 0.001$, and $P = 0.041$ for weeks 1, 2, and 3, respectively) (Table 1). In contrast, no significant differences were identified between the ultrasound and radiographic findings when the ultrasound screening examinations were performed between the fourth and 12th week of life (day 22 and beyond) ($P = 0.134$, $P = 0.999$, $P = 0.480$, $P = 0.134$, $P = 0.480$, $P = 0.999$, and $P = 0.752$ for weeks 4, 5, 6, 7, 8, 9, and 10, respectively) (Table 1). This is largely attributed to the high rate of false-positive cases in the first 3 weeks of life (Fig. 1). Similarly, the accuracy of ultrasound screening was 79.2% and above when performed during or after the fourth week of life (day 22 and beyond), as compared to 73.1% and below when performed prior to the fourth week of life (day 21 and before) (Table 1).

Discussion

The principal finding of this study is that the earliest that ultrasound screening for DDH can be performed reliably is during the fourth week of life (day 22 and beyond). Prior to that, findings from ultrasound screening correlated poorly with radiographic findings at 1 year of life. The accuracy of ultrasound screening when performed during or after the fourth week of life was 79.2% and above.

This finding is in accordance with the only two other studies that were published regarding the timing of ultrasound screening for DDH [7,8]. Gokharman et al. [7] compared the results of ultrasound screening at the fourth week of life to those at the 12th week of life, and found that ultrasound screening findings at the fourth week of life could successfully predict ultrasound findings at the 12th week of life. Similarly to our study, they found that ultrasound screening at the eighth week of life was more successful in predicting the results at the 12th week of life than ultrasound screening at the fourth week of life [7]. These results are similar to those published by Lussier et al. [8], who compared ultrasound screening before 28 days and after 28 days, and found that ultrasound screening after 28 days improved specificity and accuracy in terms of correlation with the final management outcome, which was either discharge from hip screening or referral to the paediatric orthopaedic clinic. Both studies thus identified a similar timeline to that of the current study, which found that the earliest that ultrasound screening for DDH can be performed reliably is during the fourth week of life (days 22–28) [7,8].

However, the findings from the current study advance knowledge

in several additional ways compared to the other existing studies [7,8]. Firstly, the current study is the first to analyse the results of ultrasound screening weekly from birth to identify the earliest possible time that ultrasound screening can be performed reliably for DDH. Gokharman et al. [7] chose the fourth and eighth weeks of life as the timepoints for their study because of the observation from their clinical practice that most of ultrasound examinations performed earlier took place during the first 6–8 weeks of life. Similarly, Lussier et al. [8] chose the threshold of 28 days for their study because most screenings at their institutions were performed either in the first week of life or after 28 days of life. Both studies were then unable to give a precise timepoint for the earliest timing that ultrasound screening could be reliably performed, since their comparison groups included patients from a wide range of timepoints before versus after the fourth week or 28 days of life [7,8]. In contrast, the current study analysed the results of ultrasound screening weekly from birth, thereby allowing the identification of what may be slightly earlier timing for ultrasound screening to be performed reliably—at day 22 and beyond, in contrast to day 28 and beyond [8].

Secondly, the current study is also the only study that has included aspects of the ultrasound evaluation of DDH other than the Graf classification for evaluation of the accuracy of ultrasound screening for DDH. These included Harcke's method of dynamic ultrasound screening and Terjesen's method of evaluation for femoral head coverage [10,12,13]. Both methods have been proven in the literature to be reliable and accurate methods used for ultrasound screening for DDH, and in fact, some studies comparing these two methods and the Graf classification have shown that Harcke's and Terjesen's methods could improve the accuracy of ultrasound screening when performed in conjunction with the Graf classification [15,16]. These methods should therefore be included in practice, as well as in studies, as part of ultrasound screening for DDH.

Lastly, another unique aspect of this study is that it is the only study that has compared ultrasound screening results with long-term outcomes at 1 year. In contrast, Gokharman et al. [7] used 12th-week ultrasound results and Lussier et al. [8] used the final management outcome, which was either discharge from hip screening or referral to the paediatric orthopaedic clinic, as their outcome measures. A longer-term outcome measure is useful for the study of DDH because it is well known that abnormal ultrasound findings of DDH can resolve spontaneously with maturation [17,18].

However, this study similarly faces several limitations. Firstly, despite having 348 patients, the sample size of this study is smaller than that of the two other studies that have been published on this issue. This may have been due to the use of a longer-term outcome measure than was the case in the other studies, as well as

a lower number of patients at our institution. Secondly, subdividing the patients into the various weeks of life in which the ultrasound screening was performed further reduced the number of patients in each subgroup, thereby decreasing the power of the statistical analysis. However, based on the results of the current study, it is the hope of the authors that further larger-scale studies will be performed to validate the results of this study, thereby allowing future patients to benefit from earlier reliable ultrasound screening for DDH, reducing the risks of morbidity associated with delayed management of DDH. Thirdly, due to the small sample size, a multivariate analysis was not performed to explore whether the effects of the risk factors could have affected the earliest timing of reliable ultrasound screenings; however, this could be further analysed in future larger-scale studies. Lastly, the study excluded patients who received treatment prior to the radiographs performed at 1 year of life, in order to minimise the confounding factor of treatment effect. However, this could pose a potential risk of selection bias. Nonetheless, the patients who receive treatment are often those with severe hip dysplasia with obvious ultrasonographic abnormalities. The focus of the current study was to analyse whether ultrasonographic findings evaluated in the first 12th weeks of life could reliably predict the detection abnormalities on radiographs at 1 year of age. These patients were then not the main focus of the study, as they would usually receive prompt treatment and close follow-up, and therefore, would not fall through the gaps of the screening system.

In conclusion, this study identified that the earliest time that ultrasound screening for DDH could be performed reliably is during the fourth week of life (day 22 and beyond). Prior to that, findings from ultrasound screening correlated poorly with radiographic findings at 1 year of life. The accuracy of ultrasound screening when performed during or after the fourth week of life was 79.2% and above.

ORCID: Si Heng Sharon Tan: <https://orcid.org/0000-0003-0075-7890>; Keng Lin Wong: <https://orcid.org/0000-0002-2100-8269>

Author Contributions

Conceptualization: Tan SHS, Lim AKS, Hui JH. Data acquisition: Tan SHS, Wong KL. Data analysis or interpretation: Tan SHS. Drafting of the manuscript: Tan SHS, Wong KL, Lim AKS, Hui JH. Approval of the final version of the manuscript: all authors.

Conflict of Interest

No potential conflict of interest relevant to this article was reported.

References

1. Tan SH, Wong KL, Hui JH. Incorporating risk factors in the development of the screening programme for developmental dysplasia of the hips. *J Pediatr Orthop B* 2019;28:111-114.
2. Bracken J, Tran T, Ditchfield M. Developmental dysplasia of the hip: controversies and current concepts. *J Paediatr Child Health* 2012;48:963-972.
3. Osarumwense D, Popple D, Kershaw IF, Kershaw CJ, Furlong AJ. What follow-up is required for children with a family history of developmental dysplasia of the hip? *J Pediatr Orthop B* 2007;16:399-402.
4. Guler O, Seker A, Mutlu S, Cerci MH, Komur B, Mahirogullari M. Results of a universal ultrasonographic hip screening program at a single institution. *Acta Orthop Traumatol Turc* 2016;50:42-48.
5. Kwong KS, Huang X, Cheng JC, Evans JH. New technique for early screening of developmental dysplasia of the hip: pilot study. *J Pediatr Orthop* 2003;23:347-351.
6. Pillai A, Joseph J, McAuley A, Bramley D. Diagnostic accuracy of static graf technique of ultrasound evaluation of infant hips for developmental dysplasia. *Arch Orthop Trauma Surg* 2011;131:53-58.
7. Gokharman FD, Aydin S, Fatihoglu E, Ergun E, Kosar PN. Optimizing the time for developmental dysplasia of the hip screening: earlier or later? *Ultrasound Q* 2019;35:130-135.
8. Lussier EC, Sun YT, Chen HW, Chang TY, Chang CH. Ultrasound screening for developmental dysplasia of the hip after 4 weeks increases exam accuracy and decreases follow-up visits. *Pediatr Neonatol* 2019;60:270-277.
9. Theodore Harcke H. Hip ultrasonography in clinical practice. *Pediatr Radiol* 2017;47:1155-1159.
10. Omeroglu H. Use of ultrasonography in developmental dysplasia of the hip. *J Child Orthop* 2014;8:105-113.
11. Graf R. Hip sonography: 20 years experience and results. *Hip Int* 2007;17 Suppl 5:S8-S14.
12. Harcke HT, Clarke NM, Lee MS, Borns PF, MacEwen GD. Examination of the infant hip with real-time ultrasonography. *J Ultrasound Med* 1984;3:131-137.
13. Terjesen T. Ultrasound as the primary imaging method in the diagnosis of hip dysplasia in children aged < 2 years. *J Pediatr Orthop B* 1996;5:123-128.
14. Tonnis D. Normal values of the hip joint for the evaluation of X-rays in children and adults. *Clin Orthop Relat Res* 1976;(119):39-47.
15. Kosar P, Ergun E, Unlubay D, Kosar U. Comparison of morphologic and dynamic US methods in examination of the newborn hip. *Diagn Interv Radiol* 2009;15:284-289.
16. Czubak J, Kotwicki T, Ponitek T, Skrzypek H. Ultrasound measurements of the newborn hip: comparison of two methods in 657 newborns. *Acta Orthop Scand* 1998;69:21-24.

17. Synder M, Harcke HT, Domzalski M. Role of ultrasound in the diagnosis and management of developmental dysplasia of the hip: an international perspective. *Orthop Clin North Am* 2006;37:141-147.
18. Bialik V, Bialik GM, Wiener F. Prevention of overtreatment of neonatal hip dysplasia by the use of ultrasonography. *J Pediatr Orthop B* 1998;7:39-42.