



ORIGINAL RESEARCH

# Cardiopulmonary Outcomes After the Nuss Procedure in Pectus Excavatum

Dawn E. Jaroszewski , MD, MBA; Juan M. Farina , MD; Michael B. Gotway, MD; Joshua D. Stearns, MD; Michelle A. Peterson, MSN, AGACNP-BC; Venkata S. K. K. Pulivarthi, MD; Peter Bostoros, MBBS; Ahmad S. Abdelrazek, MBBS; Ashwini Gotimukul, MBBS; David S. Majdalany, MD; Courtney M. Wheatley-Guy , MD, PhD; Reza Arsanjani , MD

**BACKGROUND:** Pectus excavatum is the most common chest wall deformity. There is still controversy about cardiopulmonary limitations of this disease and benefits of surgical repair. This study evaluates the impact of pectus excavatum on the cardiopulmonary function of adult patients before and after a modified minimally invasive repair.

**METHODS AND RESULTS:** In this retrospective cohort study, an electronic database was used to identify consecutive adult (aged  $\geq 18$  years) patients who underwent cardiopulmonary exercise testing before and after primary pectus excavatum repair at Mayo Clinic Arizona from 2011 to 2020. In total, 392 patients underwent preoperative cardiopulmonary exercise testing; abnormal oxygen consumption results were present in 68% of patients. Among them, 130 patients (68% men, mean age,  $32.4 \pm 10.0$  years) had post-repair evaluations. Post-repair tests were performed immediately before bar removal with a mean time between repair and post-repair testing of  $3.4 \pm 0.7$  years (range, 2.5–7.0). A significant improvement in cardiopulmonary outcomes ( $P < 0.001$  for all the comparisons) was seen in the post-repair evaluations, including an increase in maximum, and predicted rate of oxygen consumption, oxygen pulse, oxygen consumption at anaerobic threshold, and maximal ventilation. In a subanalysis of 39 patients who also underwent intraoperative transesophageal echocardiography at repair and at bar removal, a significant increase in right ventricle stroke volume was found ( $P < 0.001$ ).

**CONCLUSIONS:** Consistent improvements in cardiopulmonary function were seen for pectus excavatum adult patients undergoing surgery. These results strongly support the existence of adverse cardiopulmonary consequences from this disease as well as the benefits of surgical repair.

**Key Words:** cardiothoracic surgery ■ echocardiography ■ exercise testing ■ pectus excavatum

See Editorial by Kar et al.

**P**ectus excavatum (PE) is the most common congenital chest wall deformity with symptoms affecting patients at different ages.<sup>1</sup> In many cases, symptoms including dyspnea, tachycardia, dizziness, and chest pain manifest during exertion and exercise.<sup>2</sup> Some evidence suggests that symptoms may progress as the patient ages.<sup>3</sup> Adverse cardiopulmonary effects of PE may be underestimated by many physicians, in part because of the contradictory findings of previously published data.<sup>2,4,5</sup>

Patients frequently report subjective symptom resolution and improvement in exercise tolerance following surgical repair.<sup>6,7</sup> However, there are few objective and consistent publications documenting improvement in cardiopulmonary function following surgical repair, especially on the ability to exercise.<sup>2,4,5</sup> The existing literature is inconclusive, hampered by small, statistically underpowered patient cohorts, short- versus long-term results, rest versus exercise studies, and inconsistent testing measures.<sup>2,4</sup>

Correspondence to: Dawn E. Jaroszewski, MD, MBA, Department of Cardiovascular and Thoracic Surgery, Mayo Clinic Arizona, 5777 East Mayo Boulevard, Phoenix, AZ 85054. E-mail: jaroszewski.dawn@mayo.edu

Supplemental Material is available at <https://www.ahajournals.org/doi/suppl/10.1161/JAHA.121.022149>

For Sources of Funding and Disclosures, see page 8.

© 2022 The Authors. Published on behalf of the American Heart Association, Inc., by Wiley. This is an open access article under the terms of the Creative Commons Attribution-NonCommercial-NoDerivs License, which permits use and distribution in any medium, provided the original work is properly cited, the use is non-commercial and no modifications or adaptations are made.

JAHA is available at: [www.ahajournals.org/journal/jaha](http://www.ahajournals.org/journal/jaha)

## CLINICAL PERSPECTIVE

### What Is New?

- This study demonstrates that external cardiac compression from the pectus excavatum deformity can cause negative cardiopulmonary consequences.
- More than two thirds of adult patients studied showed abnormal cardiopulmonary function before undergoing surgical repair.
- A consistent improvement in cardiopulmonary outcomes was demonstrated after the minimally invasive repair of pectus excavatum.

### What Are the Clinical Implications?

- Pectus excavatum is not merely a cosmetic disorder and symptomatic patients should be thoroughly evaluated to assess cardiopulmonary deficits associated with the cardiac compression.
- When cardiopulmonary implications are suspected or detected, surgical correction should be considered to provide functional benefits.

## Nonstandard Abbreviations and Acronyms

<b>CPET</b>	cardiopulmonary exercise testing
<b>HI</b>	Haller index
<b>MIRPE</b>	minimally invasive repair of pectus excavatum
<b>PE</b>	pectus excavatum
<b>TEE</b>	transesophageal echocardiography
<b>VO<sub>2</sub> max</b>	maximum rate of oxygen consumption

Cardiopulmonary exercise testing (CPET) is an established clinical tool for evaluating exercise capacity and provides assessment of the integrative exercise responses involving the pulmonary, cardiovascular, and skeletal muscle systems.<sup>8</sup> Data documenting improvement in CPET outcomes in the pediatric PE population after surgery are compelling<sup>9,10</sup>; however, it is unclear if adult patients would equally benefit from surgery.<sup>11,12</sup>

Our previous studies using intraoperative transeophageal echocardiogram (TEE) showed significant and immediate improvements in anatomic and functional cardiac parameters following pectus repair (including right and left ventricular dimensions, stroke volume, and speckle tracking strain).<sup>13,14</sup> This study was performed as a next step to evaluate the effects of PE on cardiopulmonary function and exercise in adult patients, and to assess whether a minimally invasive “Nuss” surgical repair (MIRPE) offers significant benefit.

## METHODS

### Study Design, Data Sources, and Population

A retrospective cohort study was designed including patients identified in an electronic database at a single institution (Mayo Clinic, Phoenix, AZ). Consecutive adult patients (aged  $\geq 18$  years) with PE who underwent MIRPE between January 1, 2011 and December 31, 2020 and who underwent pre- and postoperative CPET performed at our institution were included. Patients with only preoperative CPET were used to identify the prevalence and severity of PE-related cardiopulmonary compromise. Exclusion criteria included patients undergoing revision surgery rather than primary repair; patients with additional conditions other than PE (pulmonary, cardiovascular, and musculoskeletal diseases) that could affect CPET results; patients with CPET evaluations performed with non-standardized protocols or at other institutions; or patients who experienced postoperative complications that could affect cardiopulmonary function.

Electronic medical records were used to collect baseline demographic characteristics, pre-, intra-, and postoperative testing, surgical information, and postoperative complications. Pre- and postoperative CPET outcomes were compared. Prespecified subgroup analysis of changes in the percentage of predicted maximum rate of oxygen consumption (VO<sub>2</sub> max) was stratified according to demographic characteristics, anatomical PE indices as assessed by cross sectional imaging, and cardiopulmonary basal parameters. Institutional review board approved retrospective review of patients’ medical charts and studies as well as the waiver of informed consent. The data that support the findings of this study are available from the corresponding author upon reasonable request.

### Surgical Procedure

Surgical correction of PE was performed using a modified minimally invasive “Nuss” procedure as previously described.<sup>15</sup> The indications for surgical repair included Haller index (HI)  $\geq 3.25$ ; Correction index  $\geq 20\%$ ; significant or progressing cardiopulmonary symptoms, and/or evidence for right heart compression.<sup>15–17</sup> Intrathoracic pectus bars were recommended for removal 3 to 3.5 years following surgery.<sup>15</sup>

### Cardiopulmonary Exercise Testing

The predicted values for CPET parameters were based on age, sex, height, and weight. Both CPET and surgery were performed at a single institution/surgeon (D.E.J.). Cardiopulmonary tests were performed with

the same equipment and identical protocols during the entire study period.

Incremental exercise tests were performed using a calibrated electromagnetically upright cycle (Corival, Lode, Groningen, The Netherlands) with a non-invasive, photo-acoustic gas-rebreathing analyzer (Ultima Series, MGC Diagnostics Corporation, Saint Paul, MN). Surface electrocardiography, blood pressure measurements, pulse oximetric signals, and end-tidal CO<sub>2</sub> tracing were monitored during the entire study. A standardized 1-minute step protocol at 25 W/min was used. The participants were asked to pedal at a steady pace of 60 rpm. Maximal incremental exercise was performed until exhaustion. Peak exercise was defined as the highest work level reached during the incremental exercise test. CPET results were defined as abnormal (VO<sub>2</sub> max <80% of predicted) or normal (VO<sub>2</sub> max ≥80% of predicted).

### Before and After Correction TEE Image Analysis

When available, intraoperative TEE image analysis was performed. Digital images stored on the institutional server were retrieved and displayed in an image viewer (FUJIFILM, Indianapolis, IN). Measurements were made using electronic calipers. For 2-dimensional images and for Doppler, an average of 2 measurements was used. All patients were in sinus rhythm and all measurements were performed by a single experienced observer (J.M.F.). Right ventricular stroke volume was assessed by pulsed-wave Doppler of the right ventricle outflow tract in the deep transgastric view with as parallel alignment to right ventricle outflow tract as possible. Velocity time integral and right ventricle outflow tract diameter were used to measure right ventricle stroke volume at the time of MIRPE (before sternal elevation) and at the time of bar removal.

### Statistical Analysis

Statistical comparison between preoperative and postoperative results was performed using Student paired *t*-test for continuous variables and McNemar test for categorical variables comparison. Statistical comparison between baseline results of patients with and without postoperative tests was done using independent sample *t*-test for continuous variables and  $\chi^2$  for categorical variables. To determine or evaluate the association between independent variables (baseline computed tomography and magnetic resonance imaging findings) and the dependent variable (improvement in VO<sub>2</sub> max outcomes, with a binary variable created to indicate whether or not there was an improvement in the percentage of predicted VO<sub>2</sub> max) binary logistic regression was performed.

Statistical analyses were conducted using IBM SPSS Statistics, version 25.0 (IBM Corporation, Armonk, NY). Data were presented as mean±SD for continuous variables and frequencies and percentages for categorical variables; *P* values of <0.05 were considered statistically significant for all analyses.

## RESULTS

### Study Participants

A total of 392 patients underwent preoperative CPET at our institution; baseline characteristics and preoperative CPET results are depicted in Table 1. A high proportion of patients (68%) had abnormal preoperative VO<sub>2</sub> max results.

Among patients with a preoperative CPET, 130 (68% men, mean HI 4.7±2.5, mean Correction index 36.7±13.8%) underwent postoperative CPET and were included in the cohort. Postoperative tests were performed at evaluations immediately before bar removal procedure. In this cohort group, preoperative symptoms included dyspnea (96%), difficulty keeping up with peers (84%), palpitations (72%), and syncopal episodes (4%). A large proportion of patients (91%) noted progression of symptoms as they aged. Mean time between MIRPE and post-repair CPET was 3.4±0.7 years (range, 2.5–7.0). Two bars were placed in 69% of patients and 3 bars in 31%.

Among cases not completing a postoperative test, 184 patients (184/262, 70.2%) did not undergo the bar removal procedure by the end of the study period and 78 patients (78/262, 29.8%) underwent a bar removal procedure during the study period but declined to undergo a postoperative CPET evaluation because of personal reasons that included costs, timing constraints, scheduling conflicts, and insurance issues. Comparison of preoperative CPETs results between patients who underwent a postoperative CPET and those who did not can be found in Table S1.

### Comparison Between CPET Outcomes Before and After Surgical Repair

A significant postoperative improvement in all CPET parameters was noted (Table 2), including an increase (*P*<0.001 for all the comparisons) in the relative VO<sub>2</sub> max, absolute VO<sub>2</sub> max, O<sub>2</sub> pulse, VO<sub>2</sub> at anaerobic threshold, and maximal ventilation. Forty patients (31%) had normal VO<sub>2</sub> max values preoperatively, whereas 76 postoperative patients (58%) showed normal VO<sub>2</sub> max values (*P*<0.001 for the comparison). Both in preoperative and postoperative tests mean respiratory exchange ratio was >1.15 (Table 2). A significant improvement in the percentage of predicted VO<sub>2</sub> max value was found

**Table 1. Baseline Characteristics and Cardiopulmonary Exercise Testing Results of 392 Patients Undergoing Preoperative Cardiopulmonary Evaluation**

	n=392
Sex, n (%)	
Men	267 (68.1%)
Women	125 (31.9%)
Age, y	31.0±9.8
Height, cm	178.4±8.9
Weight, kg	72.5±26.1
Body mass index, kg/m <sup>2</sup>	22.7±8.5
Anatomical parameters	
Haller index	4.6±2.2
Correction index (%)	35.4±14.1
Preoperative CPET	
Estimated METS	9.2±1.8
Actual METS	7.6±1.8
Work, W	167.9±45.8
Work (W per kg body weight)	2.3±0.6
RER	1.2±0.1
DBP at rest, mm Hg	80.4±10.3
DBP at peak exercise, mm Hg	83.5±12.0
SBP at rest, mm Hg	121.5±14.5
SBP at peak exercise, mm Hg	163.6±25.9
Heart rate at rest, bpm	90.4±15.2
Maximum heart rate, bpm	161.6±16.1
VE/VCO <sub>2</sub> slope	27.6±4.9
VO <sub>2</sub> max	
Relative VO <sub>2</sub> max, mL/kg per min	26.5±6.2
Relative VO <sub>2</sub> max/predicted, %	73.6±15.8
% of patients with abnormal VO <sub>2</sub> max results	67.9%
O <sub>2</sub> pulse	
O <sub>2</sub> pulse, mL/beat	11.7±3.5
O <sub>2</sub> pulse/predicted, %	86.0±17.3
% of patients with O <sub>2</sub> pulse values <80% of predicted	34.4%
Anaerobic threshold	
VO <sub>2</sub> at anaerobic threshold, mL/kg per min	15.8±5.0
Peak ventilation	
VE BTPS, L/min	67.2±19.5
VE BTPS/predicted, %	43.4±14.0

CPET indicates cardiopulmonary exercise testing; DBP, diastolic blood pressure; RER, respiratory exchange ratio; SBP, systolic blood pressure; VE BTPS, ventilation at body temperature ambient pressure, saturated; VE/VCO<sub>2</sub> slope, slope of the relationship between ventilation and carbon dioxide output from start of exercise until the respiratory compensation point is reached; VO<sub>2</sub> max, maximum rate of oxygen consumption; and W, Watts.

across all prespecified subgroups, including patients with pre-operative normal VO<sub>2</sub> max values and HI ≤3.25 (Table 3).

## TEE Evaluation Before and After Correction in a Subgroup of Patients

Thirty-nine patients had intraoperative TEE imaging available for both MIRPE and bar removal and were included in a subanalysis of CPET results and TEE findings (Figure). Mean time between intraoperative TEE performed at the time of MIRPE and during bar removal was 3.4±0.6 years (range, 2.8–5.5). In this subanalysis the significant improvement in postoperative CPET outcomes was supported by a significant increase in right ventricle velocity time integral and stroke volume at the time of bar removal when compared with presurgical assessment (Table 4).

## Association Between Baseline Characteristics and CPET Results

The association between cardiopulmonary outcomes and baseline anatomical indices as assessed by cross-sectional imaging was investigated. Inspiratory imaging was performed in all the patients, with end-expiratory imaging available in 85 (65%) of the 130 patients in the cohort. No significant association ( $P>0.05$  for all associations) was found in a univariate analysis between the improvement in VO<sub>2</sub> max and anatomical variables (HI, Correction index, sternal tilt, or cardiac compression index) (Table 5).

## DISCUSSION

Opinions differ on whether patients with PE suffer cardiopulmonary limitations.<sup>2,4,5</sup> This controversy affects referral of patients for evaluation to centers experienced with this disease and impacts the ability to obtain insurance coverage for surgical correction. The National Health Service, the publicly funded healthcare system of the United Kingdom, has recently made the decision that treatment for PE will no longer be funded,<sup>18</sup> adversely impacting the quality of life for patients suffering cardiopulmonary limitations.<sup>6,19–21</sup>

The debate about whether surgical PE repair provides cardiopulmonary improvement remains unsettled owing to the limitations of previous work in this area, including small underpowered studies showing contradictory results and the use of heterogeneous diagnostic methods and outcomes to determine the presence of cardiopulmonary deficits.<sup>2,4</sup> Our previous studies examining >160 patients who underwent intraoperative TEE showed significant and immediate improvements in anatomic and functional cardiac parameters following repair.<sup>13,14</sup> The TEE improvement in adults aged >30 years was also striking with a >65% increase in right ventricular output seen following surgical PE correction.<sup>3</sup> Others have reported similar positive outcomes by TEE, and improvement in cardiac

**Table 2. Cardiopulmonary Exercise Testing Results Comparison Before and After Pectus Excavatum Repair (n=130)**

Variable	Preoperative CPET	Postoperative CPET	P value (95% CI for the difference)
Demographics			
Age, y	32.4±10.0	35.5±14.2	
Weight, kg	72.8±15.4	75.3±15.4	<0.001 (1.3 to 3.5)
Body mass index, kg/m <sup>2</sup>	22.5±3.6	23.0±3.5	0.002 (0.2 to 0.9)
Maximum workload			
Estimated METS	9.4±1.5	9.7±1.7	0.032 (0.02 to 0.50)
Actual METS	7.4±1.7	8.1±2.0	<0.001 (0.5 to 1.0)
Work, W	174.5±44.8	185.2±44.1	<0.001 (5.9 to 15.5)
Work (W per kg body weight)	2.4±0.5	2.5±0.5	0.040 (0.0 to 0.1)
Heart rate at rest, bpm	90.8±13.9	83.4±15.3	<0.001 (4.8 to 10.0)
Maximum heart rate, bpm	161.6±15.4	164.7±14.3	0.013 (0.6 to 5.4)
RER	1.22±0.1	1.24±0.1	0.029 (0.0 to 0.1)
DBP at rest, mm Hg	82.1±10.7	78.9±8.8	0.003 (1.1 to 5.4)
DBP at peak exercise, mm Hg	84.4±11.9	83.8±11.7	0.600 (−2.8 to 1.7)
SBP at rest, mm Hg	124.9±14.7	123.6±13.6	0.376 (−4.4 to 1.6)
SBP at peak exercise, mm Hg	164.5±26.2	180.6±26.7	<0.001 (11.7 to 20.3)
VE/CO <sub>2</sub> slope	27.0±5.2	26.1±3.5	0.075 (−1.9 to 0.1)
VO <sub>2</sub> max			
Relative VO <sub>2</sub> max, mL/kg per min	25.9±6.0	28.5±7.0	<0.001 (1.6 to 3.5)
Relative VO <sub>2</sub> max/predicted (%)	72.8±15.4	84.2±20.6	<0.001 (8.6 to 14.1)
Absolute VO <sub>2</sub> max, L/min	1.9±0.6	2.1±0.6	<0.001 (0.2 to 0.3)
Normal VO <sub>2</sub> max values (n)	30.8% (40)	58.5% (76)	<0.001
O <sub>2</sub> pulse			
O <sub>2</sub> pulse, mL/beat	11.7±3.6	12.9±3.7	<0.001 (0.8 to 1.6)
O <sub>2</sub> pulse/predicted, %	84.5±16.9	94.3±21.4	<0.001 (6.9 to 12.6)
Anaerobic threshold			
VO <sub>2</sub> at anaerobic threshold, mL/kg per min	14.6±4.3	16.9±6.4	<0.001 (1.2 to 3.3)
Maximal ventilation			
VE BTSP, L/min	67.5±18.8	73.3±17.7	<0.001 (3.1 to 8.4)
VE BTSP/predicted, %	39.2±9.8	48.7±12.4	<0.001 (7.6 to 11.5)

DBP indicates diastolic blood pressure; METS, metabolic equivalents; RER, respiratory exchange ratio; SBP, systolic blood pressure; VE BTSP, ventilation at body temperature ambient pressure, saturated; VE/VCO<sub>2</sub> slope, slope of the relationship between ventilation and carbon dioxide output from start of exercise until the respiratory compensation point if reached; and VO<sub>2</sub> max, maximum rate of oxygen consumption.

magnetic resonance imaging functional parameters has also been reported 1 year after PE repair.<sup>22,23</sup> Nevertheless, validation of anatomical and functional imaging parameters using direct physiological assessment, such as CPET, is important. This study was performed to take the next step in documenting gains in exercise function following surgical PE correction.

CPET is an established diagnostic test capable of determining exercise capacity and providing information about pulmonary and cardiovascular systems function. Therefore, it is an appropriate method to assess the physiologic impact of PE and the potential improvement in deficits following surgical correction.<sup>8,24</sup> Although some studies have showed no changes or only mild improvements in CPET results following

surgical repair,<sup>25,26</sup> most studies have shown postsurgical improvement in cardiopulmonary parameters in pediatric patients.<sup>9,10</sup>

Compared with pediatric patients, the cardiopulmonary impact of PE surgical repair in adult patients is less well studied. In our study, 68% of the 392 adult patients with preoperative evaluations had measurable cardiopulmonary deficits. In the 130 patients with post-repair CPETs, a significant improvement was seen in all cardiopulmonary parameters. To the best of our knowledge, only 2 related publications have addressed the physiologic impact of PE surgical repair in adult population.<sup>11,12</sup> An underpowered prospective study showed a non-significant trend towards improvement in VO<sub>2</sub> max in 15 patients following MIRPE.<sup>11</sup> A second



**Table 3. Changes in Percentage of Predicted Relative VO<sub>2</sub> Max According to Prespecified Subgroup Analysis**

Subgroup	Preoperative % of predicted VO <sub>2</sub> max	Postoperative % of predicted VO <sub>2</sub> max	P value (95% CI for the difference)
Sex			
Women	75.4±15.3	90.4±17.0	<0.001 (10.7–19.2)
Men	71.6±15.5	81.4±21.6	<0.001 (6.2–13.2)
Age, y			
≤32	68.5±13.7	79.3±19.8	<0.001 (6.4–15.0)
>32	77.0±16.0	89.0±20.4	<0.001 (8.5–15.6)
Inspiratory Haller index			
>3.25	72.1±15.1	83.3±20.2	<0.001 (8.3–14.2)
≤3.25	76.8±17.1	88.9±22.5	0.005 (4.0–20.3)
Basal % of predicted VO <sub>2</sub> max			
Abnormal (<80%)	64.8±9.3	77.4±17.0	<0.001 (9.2–15.8)
Normal (≥80%)	90.8±10.7	99.6±19.9	0.001 (3.8–13.8)

VO<sub>2</sub> max indicates maximum rate of oxygen consumption.

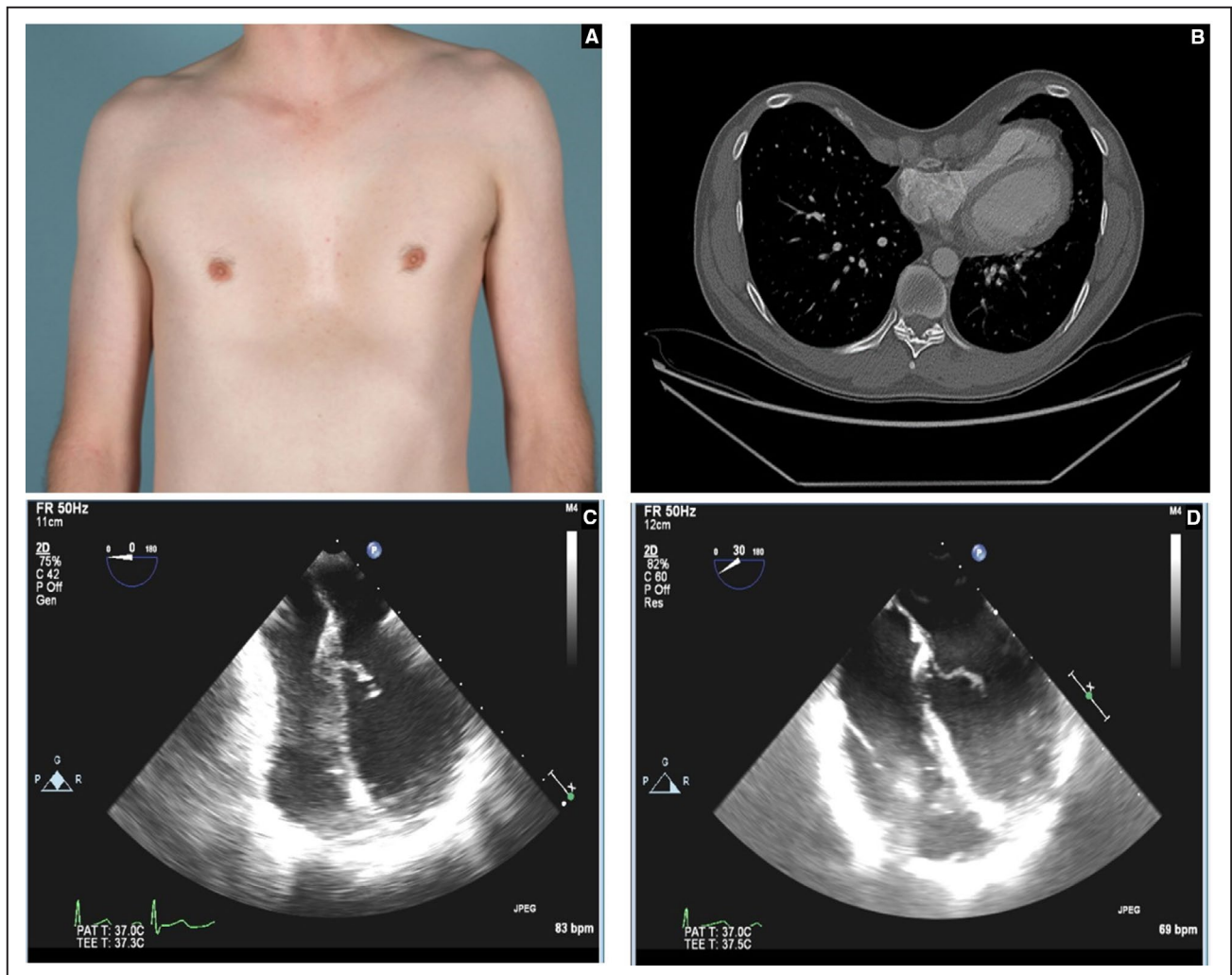
prospective study including 70 patients documented significant improvements in CPET parameters following surgical repair using an open modified Ravitch procedure.<sup>12</sup> In at least 1 study, the Nuss procedure has been associated with greater pulmonary function improvements following bar removal compared with the Ravitch procedure.<sup>27</sup> Because there is a greater loss of chest wall pliability associated with the Ravitch procedure as compared with the Nuss procedure, the Nuss procedure has been proposed as the superior method of surgical PE correction.<sup>27,28</sup> In addition, this improved chest wall pliability may contribute to the significant improvements detected by CPET despite the presence of the intrathoracic bars in our study.

Our post-repair CPETs were performed before bar removal. The presence of 2 (69%) and 3 (31%) intrathoracic bars may have significantly limited the physiological improvements detected in our patients, and further improvements may be possible with CPET evaluations performed at 6 months to 1 year after bar removal. In this investigation, the percentage of patients who reached normal VO<sub>2</sub> max values increased significantly after surgical correction (31% before surgery versus 58% after surgery,  $P<0.001$ ). Nevertheless, nearly half of patients did not reach normalization while their bars were still in place. Our study found consistent CPET improvements in both younger adults (aged ≤32 years) and older adults (aged >32 years) suggesting that PE correction may be equally beneficial to older patients. Although it is possible that some level of incomplete recovery occurs because of structural damage resulted from long periods of cardiac compression and/or displacement caused by the PE defect, the improvements seen in all age groups argued against this. Whether or not further improvements in CPET parameters may be realized at longer term evaluation following bar removal remains a subject for future investigation.

Another important finding in the subgroup analyses was the significant improvement in the percentage of predicted VO<sub>2</sub> max even in patients with apparently normal preoperative cardiopulmonary function (95% were symptomatic). Therefore, even patients with preoperative normal CPET parameters should be considered for repair if symptoms or other factors support surgery.

In a subset of patients undergoing CPET before and after surgical repair and with intraoperative TEE imaging available both at the time of MIRPE and at bar removal, there was a significant increase in TEE cardiac functional parameters at the time of bar removal. These improvements parallel the physiologic benefits assessed by CPET, further support the implications of our findings, and support the observations of previously published TEE studies in this population.<sup>13,14,22</sup>

The relationship between anatomic parameters assessed by cross-sectional imaging and cardiopulmonary impact is controversial. Some investigators found that anatomical variables, such as HI, Correction index, sternal tilt, or the site of maximum compression may predict the adverse physiologic impact of PE on cardiopulmonary function.<sup>29–32</sup> In contrast, other reports found no association between cross-sectional indices and cardiac function.<sup>13,33</sup> In our study, an association between the preoperative cross-sectional imaging anatomic parameters and the improvement in VO<sub>2</sub> max was not detected, probably as a result of the wide heterogeneity of PE malformations (including differences in the depth of the depression, location of the site of maximum depression, and severity of heart displacement)<sup>34</sup> which may contribute to the inability of standard imaging indices to consistently capture the severity of the adverse physiological impact of PE. Based on our data, we suggest that the approach to assessment of PE severity should not be based on a single diagnostic test or parameter, which clearly carries



**Figure.** Forty-two-year-old male patient with severe pectus excavatum presenting dyspnea and chest pain.

**A**, Front photo of the patient before repair. Note the sternal depression and the distorted anatomy of the chest wall. **B**, Axial chest computed tomography through the site of maximal posterior sternal displacement shows focal compression of the base of the right ventricle and the tricuspid annulus with leftward displacement of the heart (inspiratory Haller index 4.4). **C**, Intraoperative transesophageal echocardiography images show compression at the tricuspid annulus and at basal level of the right ventricle before sternal elevation. **D**, Complete release and improvement of tricuspid annulus and right ventricle diameters after Nuss repair, which correlated with an improvement in  $VO_2$  max at postoperative cardiopulmonary exercise testing (from 23.80 to 27.40 mL/kg per minute).

implications given that specific anatomical parameters, such as HI, are used as criteria for surgical intervention insurance coverage.<sup>35</sup> Indeed, our study shows that the surgical eligibility HI threshold of  $>3.25$  did not segregate patients who experienced physiologic improvement as assessed by the percentage of predicted  $VO_2$  max following surgery, from those who did not.

The strengths of this study include the use of physiologic, as opposed to anatomic, assessment of cardiopulmonary function using CPET parameters as well as a larger cohort of patients than previous published literature. Nevertheless, our conclusions may be limited by the retrospective nature of the study and the lack of formal estimation of patients' physical activity before and after surgical repair. Additionally, there was

a statistically significant increase in patients' weight and body mass index between the pre- and postsurgical assessment; to minimize the impact of this limitation we also compared the absolute  $VO_2$  max values. Furthermore, the greater patient weight in postoperative testing would theoretically limit our ability to detect physiological improvement.

Our study carries implications on the needs for future investigations. First, CPET assessment of the long-term durability of the positive physiologic impact as well as the time required to peak realization of physiologic improvement following PE repair requires study. Such a study may provide insight as to whether cardiopulmonary improvement requires additional time following bar removal for patients who failed

**Table 4. Transesophageal Echocardiography and Cardiopulmonary Exercise Testing Outcomes in the Subanalysis of 39 Patients Who Underwent Intraoperative Transesophageal Echocardiography at Primary Surgery (Before Sternal Elevation) and at Bars Removal**

Variable	Preoperative	Postoperative	P value (95% CI for the difference)
VO <sub>2</sub> max			
VO <sub>2</sub> max, mL/kg per min	26.1±6.8	29.1±8.5	<0.001 (0.9–5.0)
VO <sub>2</sub> max/predicted (%)	70.8±17.0	82.5±22.0	<0.001 (6.6–16.9)
Absolute VO <sub>2</sub> max, L/min	1.9±0.5	2.2±0.6	<0.001 (0.1–0.4)
O <sub>2</sub> pulse			
O <sub>2</sub> pulse, mL/beat	11.8±3.4	13.1±3.8	0.009 (0.3–2.3)
O <sub>2</sub> pulse/predicted, %	83.0±17.4	92.2±24.2	0.008 (2.6–15.8)
Anaerobic threshold			
VO <sub>2</sub> at anaerobic threshold, mL/kg per min	14.4±4.4	17.5±7.5	0.006 (0.9–5.3)
TEE			
RVOT VTI, cm	14.2±3.3	16.3±3.4	0.005 (0.7–3.5)
Right ventricle SV, mL	41.1±13.2	54.6±15.6	<0.001 (7.3–17.6)

RVOT indicates right ventricle outflow tract; SV, stroke volume; TEE, transesophageal echocardiography; VO<sub>2</sub> max, maximum rate of oxygen consumption; and VTI, velocity time integral.

to reach normal VO<sub>2</sub> max values at pre-bar removal CPET evaluation. An additional research focus should include identification of the combination of anatomical and functional parameters most capable of predicting the greatest improvement in cardiopulmonary function following surgical repair. Identification of such parameters would be highly useful for identifying patients in whom corrective surgery will have the most substantial impact and for calculating the risk-benefit ratios for operative repair in an aging population.<sup>3</sup>

## CONCLUSIONS

To our knowledge, this investigation is the first to demonstrate a consistent improvement in cardiopulmonary function as assessed by CPET for adult patients with

PE undergoing MIRPE. Results strongly support the existence of adverse cardiopulmonary consequences of PE as well as the benefits of surgical repair, even for patients with apparently normal baseline cardiopulmonary function and without severe anatomical defects.

There is an urgent need for a more holistic approach to PE that emphasizes physiologic disability and is not focused solely on the cosmetic consequences. Further investigations into the long-term physiological effects of PE repair as well as the predictors of improvement of adverse physiology will be important for optimizing patient selection for correction.

**Table 5. Association Between Baseline Anatomical Characteristics and Cardiopulmonary Improvement**

Variable	P for association	Odds ratio	95% CI for odds ratio
Inspiratory measurements			
Haller index	0.12	1.27	0.94–1.71
Correction index	0.12	1.03	0.99–1.06
Sternal tilt	0.57	1.01	0.97–1.05
Cardiac compression index	0.20	1.37	0.84–2.24
Expiratory measurements			
Haller index	0.56	1.06	0.88–1.27
Correction index	0.48	1.01	0.98–1.04
Sternal tilt	0.86	1.01	0.95–1.06
Cardiac compression index	0.94	1.02	0.64–1.63

## ARTICLE INFORMATION

Received September 1, 2021; accepted December 8, 2021.

### Affiliations

Department of Cardiovascular and Thoracic Surgery (D.E.J., J.M.F., M.A.P., V.S.P., P.B., A.S.A., A.G.), Department of Radiology (M.B.G.), Department of Anesthesiology and Perioperative Medicine (J.D.S.), and Department of Cardiovascular Medicine (D.S.M., C.M.W., R.A.), Mayo Clinic Arizona, Phoenix, AZ.

### Sources of Funding

None.

### Disclosures

Jaroszewski is a consultant and has IP/royalty rights under Mayo Clinic Ventures with Zimmer Biomet, Inc. The remaining authors have no disclosures to report.

### Supplemental Material

Table S1

## REFERENCES

1. Obermeyer RJ, Goretsky MJ. Chest wall deformities in pediatric surgery. *Surg Clin N Am*. 2012;92:669–684. doi:10.1016/j.suc.2012.03.001



2. Obermeyer RJ, Cohen NS, Jaroszewski DE. The physiologic impact of pectus excavatum repair. *Semin Pediatr Surg.* 2018;27:127–132. PMID: 30078483. doi: 10.1053/j.sempedsurg.2018.05.005
3. Jaroszewski DE, Ewais MM, Chao CJ, Gotway MB, Lackey JJ, Myers KM, Merritt MV, Sims SM, McMahon LE, Notrica DM. Success of minimally invasive pectus excavatum procedures (modified Nuss) in adult patients (≥30 years). *Ann Thorac Surg.* 2016;102:993–1003. doi: 10.1016/j.athoracsur.2016.03.105
4. Jaroszewski DE, Velazco CS, Pulivarthi VSKK, Arsanjani R, Obermeyer RJ. Cardiopulmonary function in thoracic wall deformities: what do we really know? *Eur J Pediatr Surg.* 2018;28:327–346. doi: 10.1055/s-0038-1668130
5. Jayaramkrishnan K, Wotton R, Bradley A, Naidu B. Does repair of pectus excavatum improve cardiopulmonary function? *Interact Cardiovasc Thorac Surg.* 2013;16:865–870. doi: 10.1093/icvts/ivt045
6. Jaroszewski D, Notrica D, McMahon L, Steidley DE, Deschamps C. Current management of pectus excavatum: a review and update of therapy and treatment recommendations. *J Am Board Fam Med.* 2010;23:230–239. doi: 10.3122/jabfm.2010.02.090234
7. Shaalan AM, Kasb I, Elwakeel EE, Elkamali YA. Outcome of surgical repair of pectus excavatum in adults. *J Cardiothorac Surg.* 2017;12:72. doi: 10.1186/s13019-017-0635-z
8. Albouaini K, Egred M, Alahmar A, Wright DJ. Cardiopulmonary exercise testing and its application. *Heart.* 2007;93:1285–1292. doi: 10.1136/hrt.2007.121558
9. Maagaard M, Tang M, Ringgaard S, Nielsen HH, Frøkiær J, Haubuf M, Pilegaard HK, Hjortdal VE. Normalized cardiopulmonary exercise function in patients with pectus excavatum three years after operation. *Ann Thorac Surg.* 2013;96:272–278. doi: 10.1016/j.athoracsur.2013.03.034
10. Kelly RE Jr, Mellins RB, Shamberger RC, Mitchell KK, Lawson ML, Oldham KT, Azizkhan RG, Hebra AV, Nuss D, Goretsky MJ, et al. Multicenter study of pectus excavatum, final report: complications, static/exercise pulmonary function, and anatomic outcomes. *J Am Coll Surg.* 2013;217:1080–1089. doi: 10.1016/j.jamcollsurg.2013.06.019
11. Nevriere R, Montaigne D, Benhamed L, Catto M, Edme JL, Matran R, Wurtz A. Cardiopulmonary response following surgical repair of pectus excavatum in adult patients. *Eur J Cardiothorac Surg.* 2011;40:e77–e82. doi: 10.1016/j.ejcts.2011.03.045
12. Udholm S, Maagaard M, Pilegaard H, Hjortdal V. Cardiac function in adults following minimally invasive repair of pectus excavatum. *Interact Cardiovasc Thorac Surg.* 2016;22:525–529. doi: 10.1093/icvts/ivw007
13. Chao CJ, Jaroszewski DE, Kumar PN, Ewais MM, Appleton CP, Mookadam F, Gotway MB, Naqvi TZ. Surgical repair of pectus excavatum relieves right heart chamber compression and improves cardiac output in adult patients—an intraoperative transesophageal echocardiographic study. *Am J Surg.* 2015;210:1118–1125. doi: 10.1016/j.amjsurg.2015.07.006
14. Chao C-J, Jaroszewski D, Gotway M, Ewais M, Wilansky S, Lester S, Unzek S, Appleton CP, Chaliki HP, Gaitan BD, et al. Effects of pectus excavatum repair on right and left ventricular strain. *Ann Thorac Surg.* 2018;105:294–301. doi: 10.1016/j.athoracsur.2017.08.017
15. Jaroszewski DE, Velazco SC. Minimally invasive pectus excavatum repair (MIRPE). *Oper Tech Thorac Cardiovasc Surg.* 2019;23:198–215.
16. Haller JA Jr, Kramer SS, Lietman SA. Use of CT scans in selection of patients for pectus excavatum surgery: a preliminary report. *J Pediatr Surg.* 1987;22:904–906. doi: 10.1016/s0022-3468(87)80585-7
17. Poston PM, Patel SS, Rajput M, Rossi NO, Ghanamah MS, Davis JE, Turek JW. The correction index: setting the standard for recommending operative repair of pectus excavatum. *Ann Thorac Surg.* 2014;97:1176–1180. doi: 10.1016/j.athoracsur.2013.12.050
18. UK Parliament: pectus deformity treatment: NHS Funding. Volume 684: debated on Tuesday 24 November 2020. Available at: <https://hansard.parliament.uk/Commons/2020-11-24/debates/EF4E64DB-378E-456D-BAF9-3B0B9C781AA8/PectusDeformityTreatmentNHSFunding>. Accessed February 23, 2021.
19. Krasopoulos G, Dusmet M, Ladas G, Goldstraw P. Nuss procedure improves the quality of life in young male adults with pectus excavatum deformity. *Eur J Cardiothorac Surg.* 2006;29:1–5. doi: 10.1016/j.ejcts.2005.09.018
20. Hokschi B, Kocher G, Vollmar P, Praz F, Schmid RA. Nuss procedure for pectus excavatum in adults: long-term results in a prospective observational study. *Eur J Cardiothorac Surg.* 2016;50:934–939. doi: 10.1093/ejcts/ezw130
21. Kragten HA, Siebenga J, Höppener PF, Verburg R, Visker N. Symptomatic pectus excavatum in seniors (SPES): a cardiovascular problem? *Neth Heart J.* 2011;19:73–78. doi: 10.1007/s12471-010-0067-z
22. Krueger T, Chassot PG, Christodoulou M, Cheng C, Ris HB, Magnusson L. Cardiac function assessed by transesophageal echocardiography during pectus excavatum repair. *Ann Thorac Surg.* 2010;89:240–243. doi: 10.1016/j.athoracsur.2009.06.126
23. Töpfer A, Polleichtner S, Zagrosek A, Prothmann M, Traber J, Schwenke C, von Knobelsdorff-Brenkenhoff F, Schaarschmidt K, Schulz-Menger J. Impact of surgical correction of pectus excavatum on cardiac function: insights on the right ventricle. A cardiovascular magnetic resonance study. *Interact Cardiovasc Thorac Surg.* 2016;22:38–46. doi: 10.1093/icvts/ivv286
24. Malek MH, Coburn JW. Strategies for cardiopulmonary exercise testing of pectus excavatum patients. *Clinics.* 2008;63:245–254. doi: 10.1590/S1807-59322008000200014
25. Castellani C, Windhaber J, Schober PH, Hoellwarth ME. Exercise performance testing in patients with pectus excavatum before and after Nuss procedure. *Pediatr Surg Int.* 2010;26:659–663. doi: 10.1007/s00383-010-2627-0
26. O’Keefe J, Byrne R, Montgomery M, Harder J, Roberts D, Sigalet DL. Longer term effects of closed repair of pectus excavatum on cardiopulmonary status. *J Pediatr Surg.* 2013;48:1049–1054. doi: 10.1016/j.jpedsurg.2013.02.024
27. Chen Z, Amos EB, Luo H, Su C, Zhong B, Zou J, Lei Y. Comparative pulmonary functional recovery after Nuss and Ravitch procedures for pectus excavatum repair: a meta-analysis. *J Cardiothorac Surg.* 2012;7:101. doi: 10.1186/1749-8090-7-101
28. Kocher GJ, Gstrein N, Jaroszewski DE, Ewais MM, Schmid RA. Nuss procedure for repair of pectus excavatum after failed Ravitch procedure in adults: indications and caveats. *J Thorac Dis.* 2016;8:1981–1985. doi: 10.21037/jtd.2016.06.60
29. Abu-Tair T, Turial S, Hess M, Wiethoff CM, Staatz G, Lollert A, Kampmann C. Impact of pectus excavatum on cardiopulmonary function. *Ann Thorac Surg.* 2018;105:455–460. doi: 10.1016/j.athoracsur.2017.09.037
30. Das BB, Recto MR, Yeh T. Improvement of cardiopulmonary function after minimally invasive surgical repair of pectus excavatum (Nuss procedure) in children. *Ann Pediatr Cardiol.* 2019;12:77–82. doi: 10.4103/apc.APC\_121\_18
31. Rodriguez-Granillo GA, Raggio IM, Deviggiano A, Bellia-Munzon G, Capunay C, Nazar M, Martinez JL, Carrascosa P, Martinez-Ferro M. Impact of pectus excavatum on cardiac morphology and function according to the site of maximum compression: effect of physical exertion and respiratory cycle. *Eur Heart J Cardiovasc Imaging.* 2020;21:77–84. doi: 10.1093/ehjci/jez061
32. Capunay C, Martinez-Ferro M, Carrascosa P, Bellia-Munzon G, Deviggiano A, Nazar M, Martinez JL, Rodriguez-Granillo GA. Sternal torsion in pectus excavatum is related to cardiac compression and chest malformation indexes. *J Pediatr Surg.* 2020;55:619–624. doi: 10.1016/j.jpedsurg.2019.05.008
33. Swanson JW, Avansino JR, Phillips GS, Yung D, Whitlock KB, Redding GJ, Sawin RS. Correlating Haller Index and cardiopulmonary disease in pectus excavatum. *Am J Surg.* 2012;203:660–664. doi: 10.1016/j.amjsurg.2011.12.013
34. Rodriguez-Granillo GA, Martínez-Ferro M, Capuñay C, Bellia-Munzón G, Deviggiano A, Raggio I, Fernandez-Rostello E, Hurtado Hoyo E, Bastarrika G, Carrascosa P. Preoperative multimodality imaging of pectus excavatum: state of the art review and call for standardization. *Eur J Radiol.* 2019;117:140–148. doi: 10.1016/j.ejrad.2019.06.014
35. Nuss D, Kelly RE Jr. Indications and technique of Nuss procedure for pectus excavatum. *Thorac Surg Clin.* 2010;20:583–597. doi: 10.1016/j.thorsurg.2010.07.002

# **SUPPLEMENTAL MATERIAL**

**Table S1. Comparison of preoperative CPET results between 130 patients with pre- and post-operative CPET and 262 with only preoperative CPET.**

<b>Variable</b>	<b>Patients with only a preoperative CPET (n=262)</b>	<b>Patients with preoperative and postoperative CPET (n=130)</b>	<b>p value (95% CI for the difference)</b>
<b><u>Demographics</u></b>			
Age (years)	30.4 ±9.7	32.4 ±10.0	0.065 (-4.0-0.1)
Height (cm)	177.9 ±8.6	179.4 ±9.6	0.105 (-3.4-0.3)
Weight (Kg)	72.3 ±30.0	72.8 ±15.4	0.836 (-6.1-4.9)
Body Mass Index (Kg/m <sup>2</sup> )	22.8 ±10.1	22.5 ±3.6	0.732 (-1.5-2.1)
<b><u>CPET results</u></b>			
Estimated METS	9.1 ±1.9	9.4 ±1.5	0.103 (-0.7-0.1)
Actual METS	7.6 ±1.8	7.4 ±1.7	0.199 (-0.1-0.6)
Work (Watts)	164.6 ±46.0	174.5 ±44.8	0.045 (0.2-19.5)
Work (Watts per Kg body weight)	2.3 ±0.6	2.4 ±0.5	0.077 (-0.2-0.0)
RER	1.2 ±0.1	1.2 ±0.1	0.079 (-0.1-0.0)
DBP at rest (mmHg)	79.6 ±10.1	82.1 ±10.7	0.033 (0.2-4.7)
DBP at peak exercise (mmHg)	83.0 ±12.0	84.4 ±11.9	0.278 (-3.9-1.1)
SBP at rest (mmHg)	119.9 ±14.2	124.9 ±14.7	0.002 (1.9-8.2)

SBP at peak exercise (mmHg)	163.2 ±25.8	164.5 ±26.2	0.629 (-6.9-4.2)
Heart rate at rest (bpm)	90.1 ±15.8	90.8 ±13.9	0.658 (-3.9-2.4)
Maximum heart rate (bpm)	161.5 ±16.8	161.6 ±15.4	0.921 (-3.6-3.3)
VE/VCO <sub>2</sub> Slope	28.1 ±4.7	27.0 ±5.2	0.059 (-0.1-2.4)
Relative VO <sub>2</sub> Max (ml/Kg/min)	26.7 ±6.3	25.9 ±6.0	0.199 (-0.4-2.2)
Relative VO <sub>2</sub> Max/Predicted (%)	73.9 ±16.0	72.8 ±15.4	0.513 (-2.2-4.4)
Absolute VO <sub>2</sub> Max (L/min)	1.9 ±0.9	1.9 ±0.6	0.570 (-0.1-0.2)
% of patients with abnormal VO <sub>2</sub> Max results	176 (67.1%)	90 (69.2%)	0.682
O <sub>2</sub> pulse (ml/beat)	11.7 ±3.4	11.7 ±3.6	0.951 (-0.7-0.8)
O <sub>2</sub> pulse/Predicted (%)	86.8 ±17.5	84.5 ±16.9	0.232 (-1.4-5.9)
VO <sub>2</sub> at Anaerobic Threshold (ml/Kg/min)	16.4 ±5.2	14.6 ±4.3	<0.001 (0.8-2.9)
VE BTPS (L/min)	67.1 ±19.9	67.5 ±18.8	0.827 (-4.6-3.6)

CPET: cardiopulmonary exercise testing. METS: metabolic equivalents. VO<sub>2</sub> Max: maximum rate of oxygen consumption. VE BTPS: ventilation at body temperature ambient pressure, saturated. RER: respiratory exchange ratio. VE/VCO<sub>2</sub> slope: slope of the relationship between ventilation and carbon dioxide output from start of exercise until the respiratory compensation point if reached. DBP: diastolic blood pressure. SBP: systolic blood pressure.