

Mechanically Induced Vasospasm and Postoperative Cerebral Infarction after Coil Embolization of Unruptured Cerebral Aneurysms in Anterior Circulation

Daiichiro ISHIGAMI,¹ Wataro TSURUTA,¹ Masahiro KATSUMATA,¹
and Hisayuki HOSOO¹

¹Department of Endovascular Neurosurgery, Toranomon Hospital, Tokyo, Japan

Abstract

We occasionally encounter situations which requires retraction of the guiding system or administration of vasodilatory agents for mechanically induced vasospasm (MVS). However, whether MVS is associated with postoperative cerebral infarction has not been reported. To explore factors associated with MVS and to verify how MVS influences procedure outcomes, we reviewed consecutive cases of unruptured aneurysms in the anterior circulation treated with coil embolization between January 2017 and February 2020. Collected data included patients' clinical characteristics, devices, vessel tortuosity, severity of MVS, diameter of the parent vessel, and procedure duration. Significant MVS was defined as a condition necessitating a pause in the procedure. We also counted postoperative diffusion-weighted imaging (DWI) hyperintense spots (DHS). Parameters associated with MVS and postoperative DHS were investigated by multivariate logistic regression. A total of 103 cases met the eligibility criteria, with significant MVS occurring in 21 cases (20.3%), and postoperative DHS (≥ 3) confirmed in 30 cases (29.1%). Significant MVS was associated only with larger caliber at the tip of the guiding system compared with the parent vessel ($p = 0.001$). Postoperative DHS was associated with significant MVS ($p = 0.002$, OR: 5.313; 95% CI: 1.851–15.254). Significant MVS is a predictor of postoperative cerebral ischemia and occurs in patients with smaller caliber of the parent vessel. In patients with high-risk features for MVS, we should avoid navigating the guiding system forcibly through the narrow parent vessel. In other words, it is crucial to place the large-caliber guiding sheath/catheter proximally and only guide distally the intermediate catheter with better trackability.

Keywords: mechanically induced vasospasm, unruptured cerebral aneurysm, neuroendovascular surgery, diffusion-weighted imaging

Introduction

Appropriate and stable positioning of the guiding system is prerequisite for neuroendovascular surgeries. This is because manipulation of microcatheters becomes much smoother with good support by a distally navigated, large-caliber guiding system. However, mechanically induced vasospasm (MVS)

often occurs when navigating the guiding system. If MVS is present, guiding catheters cannot be navigated distally enough, and delicate microcatheter manipulation becomes impossible. In fact, the procedure occasionally needs to be paused. In cases with severe MVS, intra-arterial administration of vasodilatory agents might be required. In addition, if severe MVS causes flow stagnation, thromboembolic events may subsequently occur. On the other hand, many reports have described cerebral infarction after endovascular surgeries for cerebral aneurysms.^{1–5} Those reports have described age, diabetes mellitus, use of stents,³ and duration of the procedure⁵ as risk factors for MVS. However, whether MVS is

Received July 9, 2020; Accepted September 3, 2020

Copyright© 2020 by The Japan Neurosurgical Society This work is licensed under a Creative Commons Attribution-NonCommercial-NoDerivatives International License.

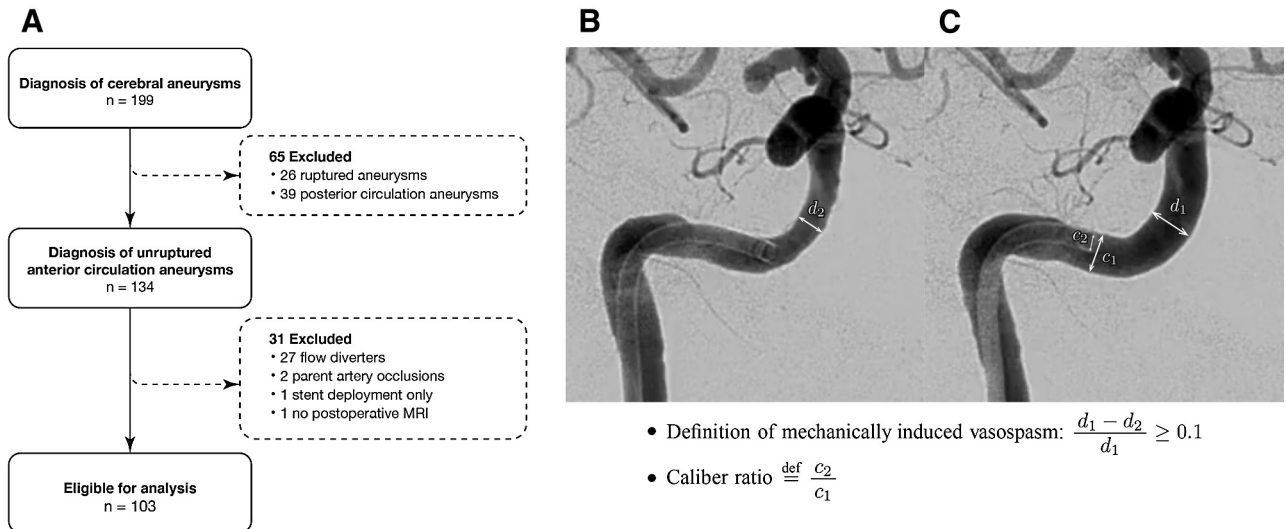


Fig. 1 The selection process for cases with cerebral aneurysm and the definition of mechanical vasospasm and a caliber ratio. (A) The selection process for cases with cerebral aneurysm. Cases were limited to unruptured aneurysms of the anterior circulation, treated by coil embolization. (B and C) The guiding system comprised a 6-Fr guiding sheath and a 6-Fr intermediate catheter. Digital subtraction angiography was obtained immediately after navigation of the intermediate catheter (B) and after completion of coil embolization (C). We defined mechanically induced vasospasm as a caliber change $\geq 10\%$ in the parent vessel. Caliber ratio was defined as illustrated above. MRI: magnetic resonance imaging.

associated with postoperative cerebral infarction has not been investigated. We stratified MVS by severity and reviewed the risk factors. In addition, we verified the association between MVS and postoperative cerebral infarction.

Materials and Methods

Patient population

We retrospectively reviewed 199 consecutive cases of cerebral aneurysm treated in our institute between January 2017 and February 2020. All study protocols were approved by the institutional review board and all patients provided informed consent for use of their anonymized clinical data. We performed postoperative magnet resonance imaging (MRI) 12–24 hours after the procedure. In all, 26 cases with ruptured aneurysms, 39 cases with unruptured aneurysms in the posterior circulation, 27 cases with aneurysm in the anterior circulation treated with flow diverters, 2 cases in the anterior circulation treated with parent artery occlusion, 1 case in the anterior circulation treated with stent deployment alone, and 1 case with no postoperative MRI were excluded. Bilateral procedures were performed in two patients, and data were collected for each procedure on each side. Finally, we analyzed 103 cases of unruptured cerebral aneurysm in the anterior circulation treated with coil embolization (Fig. 1A).

Selection of guiding system

When treating unruptured cerebral aneurysm in the anterior circulation, we prefer to use a 6-Fr guiding sheath (Fubuki 90cm ST; Asahi Intecc, Tokyo, Japan) and a 6-Fr intermediate catheter (Cerulean DD6 Plus 118cm; Medikit, Tokyo, Japan). A relatively rigid 4-Fr inner coaxial catheter had been used to navigate the intermediate catheter until May 2018, but we have been using a 4.2-Fr softer inner catheter since June 2018 (Fubuki 130cm; Asahi Intecc). If we need to guide the intermediate catheter more distally, a 5-Fr intermediate catheter (Cerulean G 127cm; Medikit) is used instead. When multiple microcatheters are unnecessary, a 6-Fr guiding catheter (Fubuki 90cm AN; Asahi Intecc) is used.

Coil embolization and perioperative management

All patients received dual antiplatelet medications (aspirin 100 mg/day and clopidogrel 75 mg/day) for at least 14 days prior to the procedure without a loading dose. When a stent-assisted technique was planned, we always checked the aspirin reaction units (ARU) and P2Y12 reaction units (PRU) (VerifyNow; Accumetrics, San Diego, CA, USA) on each patient prior to the procedure. If the test result showed PRU ≥ 230 , the patient received a 20-mg loading dose of prasugrel followed by 3.75 mg/day of prasugrel instead of clopidogrel. Following the induction of general anesthesia, systemic heparinization

was achieved with a target activated clotting time (ACT) of 200–250 s or 2–2.5 times the baseline level. Thereafter, ACT was verified every hour during the procedure, and additional heparin was administered as needed.

Miscellaneous assistive techniques (balloon-assisted technique, stent-assisted technique, and multiple-microcatheter technique) were applied. The balloon-assisted technique was usually performed with ScepterC or ScepterXC (MicroVention, Tustin, CA, USA). Four types of stents were used based on the aneurysm characteristics: a Neuroform Atlas stent (Stryker, Kalamazoo, MI, USA), an Enterprise stent (Codman, Miami, FL, USA), an LVIS Jr. stent (MicroVention), and an LVIS stent (MicroVention). After completing the procedure, each patient was transferred to the intensive care unit (ICU) without reversal of heparinization. In uneventful cases, the patient was observed for 24 hours in the ICU.

Data collection

Data in the medical records were collected for the following parameters: demographics (age and sex), body mass index (BMI), past medical history (diabetes mellitus, hypertension, or dyslipidemia), smoking history (current smoker or not, and amount of previous cigarette smoking), family history of cerebral aneurysms (including autosomal-dominant polycystic kidney disease), and location of the aneurysm. Procedural data were checked for the following parameters: procedure duration (interval from entry of the guiding catheter into the common carotid artery until pull-out), devices used in the procedure, location of the guiding catheter, caliber ratio (Figs. 1B and 1C), and vessel tortuosity. As an indicator of vessel tortuosity, we checked the number of the internal carotid artery (ICA) curves $\geq 30^\circ$ (only those involved in the tract being used for the guiding system) and whether the maximum ICA angle exceeded 70° or 90° .^{6, 7)}

Radiographic outcomes

All vasospasms in the cervical to pre-cavernous ICA were evaluated in both anteroposterior and lateral views and defined as $\geq 10\%$ stenosis of vessel diameter compared to the image after remission of vasospasm (Fig. 1B and 1C). We also defined significant MVS as a condition satisfying at least one of the following criteria: (1) contrast medium injected from the catheter showing flow stagnation, and requiring retraction of the catheter until contrast medium disappeared; (2) procedure needing to be paused due to narrowed caliber; or (3) intra-arterial administration of diluted nicardipine. To distinguish MVS from a stretched vessel with a kink caused

by the guiding system, when the blood flow stagnated, we pulled out the catheter and always confirmed the vessel morphology. A neurosurgeon (7 years of experience) and a neurologist (9 years of experience) counted diffusion-weighted imaging (DWI) hyperintense spots (DHS) independently. If a discrepancy was encountered, another neurosurgeon (13 years of experience) checked the image without any information about the patient's name, laterality, or angiographic data, and determined the number of DHS.

Statistical analysis

Descriptive statistics are reported as means with standard deviation or medians with interquartile ranges for continuous variables, or as frequency with percentage for categorical variables. Comparisons of proportions were performed with either a two-sided t-test or the Mann–Whitney U test for continuous data, and chi-square tests or Fisher's exact tests for categorical variables. Statistical significance was defined as a p value < 0.05 . Kolmogorov–Smirnov normality tests were used to determine which test to use for continuous variables, and the t-test was applied to those with values of $p \geq 0.05$. For multivariate analysis, we adopted logistic regression analyses for overall MVS, significant MVS, and postoperative DHS. Factors with the p value < 0.05 in bivariate analysis were selected as explanatory variables and analyzed by the entering method. Regarding postoperative DHS, factors that were considered significant in previous reports were also included as explanatory variables.³⁾ All statistical analyses were performed using SPSS Statistics version 26.0 software (IBM, Armonk, NY, USA).

Results

Characteristics and procedural outcomes of patients

The 103 cases had a median age of 61 years (interquartile range: 55–70 years) and 74.8% were women. Additional patient baseline characteristics are summarized in Table 1. We used the combination of a 6-Fr guiding sheath and a 6-Fr intermediate catheter in 88 cases (85.4%). MVS of any severity was identified in 59 cases (57.3%), with significant MVS in 21 cases (20.3%), and intra-arterial administration of nicardipine in six cases (5.8%). Postoperative DHS (≥ 3) was observed in 30 cases (29.1%).

Results of univariate and multivariate analyses for overall MVS

Univariate analyses showed significant differences between MVS-positive and MVS-negative groups in

Table 1 Demographics and clinical characteristics of 103 enrolled cases

Characteristics	Values
Age (years)	61 (55–70)
Female	77 (74.8%)
Body mass index (kg/m ²)	21.3 (19.5–24.6)
Current smoker	11 (10.7%)
Past smoking history (pack-years)	0 (0–11)
Hypertension	54 (52.4%)
Dyslipidemia	25 (24.3%)
Diabetes mellitus	2 (1.9%)
Family history of cerebral aneurysms	28 (27.2%)
Location of aneurysm	
ICA	
Paraclinoid	52 (50.5%)
Posterior communicating artery	20 (19.4%)
Anterior choroidal artery	3 (2.9%)
Carotid terminus	3 (2.9%)
ACA	
A1 segment	2 (1.9%)
Anterior communicating artery	10 (9.7%)
Distal ACA	8 (7.8%)
MCA	5 (4.9%)
Guiding system	
6-Fr guiding sheath and 6-Fr intermediate catheter	88 (85.4%)
6-Fr guiding sheath and 5-Fr intermediate catheter	2 (1.9%)
6-Fr guiding sheath only	10 (9.7%)
6-Fr guiding catheter only	3 (2.9%)
Use of softer coaxial catheter during navigation	50 (48.5%)
Number of pertinent carotid curves ($\geq 30^\circ$)	2 (1–2)
Maximum carotid angle $\geq 70^\circ$	56 (54.4%)
Maximum carotid angle $\geq 90^\circ$	32 (31.1%)
Guiding sheath/catheter navigated above C2 vertebral body	54 (52.4%)
Guiding sheath/catheter navigated above C1 vertebral body	11 (10.7%)
Caliber ratio	0.46 (0.42–0.54)
Overall MVS	59 (57.3%)
Significant MVS	21 (20.3%)
Intra-arterial nicardipine administration	6 (5.8%)
Balloon assist	55 (53.4%)
Stent assist	40 (38.8%)
Multiple-catheter technique	11 (9.3%)
Duration of procedure (min)	106 (78–146)
≥ 3 DWI hyperintense spots	30 (29.1%)

Data are presented as the number of patients (%) or median (interquartile range). ACA: anterior cerebral artery, DWI: diffusion-weighted imaging, ICA: internal carotid artery, MCA: middle cerebral artery, MVS: mechanically induced vasospasm.

Table 2 Univariate and multivariate analyses of factors associated with overall/significant mechanical vasospasm

	Overall MVS				Significant MVS			
	Univariate analysis		Multivariate analysis		Univariate analysis		Multivariate analysis	
	(+)MVS (n = 59)	(-)MVS (n = 44)	p value	p value	(+)Significant MVS (n = 21)	(-)Significant MVS (n = 82)	p value	p value
Age	59.9 ± 10.7	62.4 ± 13.1	0.282		57.7 ± 13.0	61.8 ± 11.4	0.163	
Female	49	28	0.025	0.011 (OR 5.39; 95% CI 1.47–19.8)	19	58	0.063	
Body mass index	21.5 ± 3.5	23.0 ± 3.3	0.014	0.305	21.3 ± 2.6	22.3 ± 3.7	0.306	
Current smoker	6	5	>0.999		0	11	0.114	
Smoking history (pack-years)	6.9 ± 12.8	8.7 ± 14.6	0.680		4.5 ± 9.3	8.4 ± 14.4	0.262	
Hypertension	27	27	0.117		7	47	0.050	
Dyslipidemia	12	13	0.281		4	21	0.531	
Diabetes mellitus	0	2	0.180		0	2	>0.999	
Family history of cerebral aneurysms	16	12	0.986		6	22	0.873	
Guiding system								
6-Fr guiding sheath and 6-Fr intermediate catheter	55	33	0.010		18	70	>0.999	
6-Fr guiding sheath and 5-Fr intermediate catheter	0	2	0.180		0	2	>0.999	
6-Fr guiding sheath only	4	6	0.166		2	7	>0.999	
6-Fr guiding catheter only	0	3	0.075		0	3	>0.999	
Use of softer coaxial catheter during navigation	25	25	0.147		10	40	0.924	
Number of pertinent carotid curves (≥30°)	1.7 ± 0.75	2.1 ± 0.95	0.029	0.687	1.5 ± 0.75	1.9 ± 0.87	0.029	0.143
Maximum carotid angle ≥70°	25	31	0.005	0.006 (OR 0.145; 95% CI 0.037–0.576)	9	47	0.235	
Maximum carotid angle ≥90°	12	20	0.006		4	28	0.182	
Guiding sheath/catheter navigated above C2 vertebral body	23	31	0.002	0.052	7	47	0.050	
Guiding sheath/catheter navigated above C1 vertebral body	2	9	0.008		0	11	0.114	
Caliber ratio	0.49 ± 0.086	0.47 ± 0.087	0.197		0.55 ± 0.086	0.46 ± 0.079	<0.001	0.001(OR 65,248.2; 95% CI 88.268–48,232,079.4)

MVS: mechanically induced vasospasm.

Table 3 Univariate and multivariate analyses of factors associated with ≥ 3 DWI hyperintense spots

	Univariate analysis			Multivariate analysis
	≥ 3 DWI hyperintense spots (n = 30)	<3 DWI hyperintense spots (n = 73)	p value	p value
Age	59.8 \pm 12.3	61.4 \pm 11.7	0.523	
Female	21	56	0.476	
Body mass index	22.2 \pm 3.3	22.1 \pm 3.6	0.586	
Current smoker	3	8	>0.999	
Past smoking history (pack-years)	8.3 \pm 11.4	7.3 \pm 14.4	0.422	
Hypertension	14	40	0.453	
Dyslipidemia	9	16	0.385	
Diabetes mellitus	0	2	>0.999	
Family history of cerebral aneurysms	8	20	0.940	
Location of aneurysm				
ICA	24	54	0.517	
Paraclinoid	13	39	0.352	
Posterior communicating artery	7	13	0.520	
Anterior choroidal artery	3	0	0.006	
Carotid terminus	1	2	>0.999	
ACA	5	15	0.651	
A1 segment	0	2	>0.999	
Anterior communicating artery	3	7	>0.999	
Distal ACA	2	6	>0.999	
MCA	1	4	>0.999	
Guiding system				
6-Fr guiding sheath and 6-Fr intermediate catheter	26	62	>0.999	
6-Fr guiding sheath and 5-Fr intermediate catheter	0	3	>0.999	
6-Fr guiding sheath only	4	6	0.442	
6-Fr guiding catheter only	0	2	0.554	
Use of softer coaxial catheter during navigation	13	37	0.498	
Number of pertinent carotid curves ($\geq 30^\circ$)	1.6 \pm 0.77	2.0 \pm 0.10	0.056	
Maximum carotid angle $\geq 70^\circ$	16	40	0.892	
Maximum carotid angle $\geq 90^\circ$	9	23	0.881	
Guiding sheath/catheter navigated above C2 vertebral body	16	38	0.906	
Guiding sheath/catheter navigated above C1 vertebral body	2	9	0.398	
Caliber ratio	0.51 \pm 0.096	0.47 \pm 0.080	0.053	
Overall MVS	20	39	0.217	
Significant MVS	12	9	0.002	0.002 (OR 5.313; 95% CI 1.851–15.254)
Intra-arterial nicardipine administration	3	3	0.354	
Balloon assist	15	40	0.658	
Stent assist	16	24	0.053	0.436
Multiple-catheter technique	5	6	0.291	
Duration of procedure (min)	132 \pm 9.0	111 \pm 5.6	0.022	0.175

ACA: anterior cerebral artery, DWI: diffusion-weighted imaging, ICA: internal carotid artery, MCA: middle cerebral artery, MVS: mechanically induced vasospasm.

terms of sex, BMI, the combination of 6-Fr guiding sheath and 6-Fr intermediate catheter, number of pertinent carotid curves ($\geq 30^\circ$), maximum carotid angle (either $\geq 70^\circ$ or $\geq 90^\circ$), and location of the guiding sheath or catheter (above either the C2 or C1 vertebral body level). Neither age nor history of hypertension showed significant differences (Table 2). Subsequent multivariate analysis showed significant difference between the two groups in terms of sex ($p = 0.011$; OR: 5.39; 95% CI: 1.47–19.8), the combination of 6-Fr guiding sheath and 6-Fr intermediate catheter ($p = 0.027$, OR: 5.248; 95% CI: 1.202–22.909), and maximum carotid angle $\geq 70^\circ$ ($p = 0.006$, OR: 0.145; 95% CI: 0.037–0.576).

Results of univariate and multivariate analyses for significant MVS

Univariate analyses showed that the number of pertinent carotid curves ($\geq 30^\circ$) and caliber ratio differed significantly between significant MVS-positive and significant MVS-negative groups (Table 2). Multivariate analysis identified caliber ratio as the only risk factor for significant MVS ($p = 0.001$, OR: 65,248.2; 95% CI: 88.268–48,232,079.4). Other factors identified as associated with MVS of any severity did not continue to show a relationship with significant MVS.

Results of univariate and multivariate analyses for postoperative DHS

Univariate analyses showed that the number of significant MVS and procedure duration differed significantly between the groups with ≥ 3 DHS and < 3 DHS (Table 3). Stent use tended to differ between groups, but not significantly. Multivariate analysis showed significant MVS as the single significant risk factor for postoperative DHS ($p = 0.002$, OR: 5.313; 95% CI: 1.851–15.254). Other factors previously reported as associated with postoperative DHS such as age, diabetes mellitus, and duration of procedure were not found to be significant in this analysis.

Illustrative case

A 79-year-old woman with left-sided internal carotid-posterior communicating aneurysm was treated with balloon-assisted coil embolization (Fig. 2A–2D). During navigation of the guiding system, the 6-Fr intermediate catheter became stuck in a prepetrous portion. Test injection of contrast medium from the catheter showed flow stagnation at the catheter tip, and we had to withdraw the intermediate catheter (Fig. 2A). We also administered diluted nicardipine intra-arterially to resolve the vasospasm. Coil embolization was completed without any intraoperative events (preoperative image, Fig. 2B;

postoperative image, Fig. 2C). Postoperative MRI performed approximately 24 h after the procedure revealed 7 DHS in the left hemisphere. Three spots are shown in Fig. 2D.

Discussion

Our results suggest that female sex, use of large-caliber intermediate catheters, and straighter ICA can be risk factors for overall MVS. When limiting the focus to significant MVS, however, caliber ratio was the only risk factor. Most importantly, significant MVS was the only risk factor for postoperative DHS.

One advantage of this research was the homogeneity of the target group. In this study, cases were limited to unruptured aneurysms of the anterior circulation treated by coil embolization. The reason for focusing on coil embolization was that a higher incidence of DWI-positive lesions tends to be seen following treatment with flow diversion compared with coiling.¹⁾ Reasons for limiting the study to aneurysms of the anterior circulation were as follows. First, regarding posterior circulation, the combination of catheters differs depending on the diameter of the target vertebral artery. Second, in the posterior circulation, diameters of the posterior communicating arteries and contralateral vertebral artery are determinants of collateral flow, which is associated with the presence of postoperative cerebral ischemia. Third, reasons for excluding ruptured aneurysms included insufficient heparinization following possible increased DHS, potential difficulty distinguishing this pathology from cerebral ischemia due to subarachnoid hemorrhage-induced vasospasm, and that postoperative MRI is not always performed within 24 h after the procedure. We adopted the same guiding system (a combination of the guiding catheter and intermediate catheter) in 85.4% of cases, which indicates that most procedures were performed under similar conditions.

We defined 3 as the cut-off number for dividing postoperative DHS into two groups, since dividing patients into two groups based on whether DWI was positive or negative might have led to discrepancies among examiners. This value is a criterion to clearly indicate the presence of an ischemic lesion. Previous studies have reported that the rate of ischemic lesions on postoperative DWI ranges from 10 to 77% following coil embolization.^{1-4, 8-10)} Nonetheless, most previous papers examined only the presence or absence of DWI hyperintensity.

According to one previous report, MVS is more likely to occur in younger patients, women, and patients without hypertension.¹¹⁾ Another previous report indicated that vasospasm during diagnostic

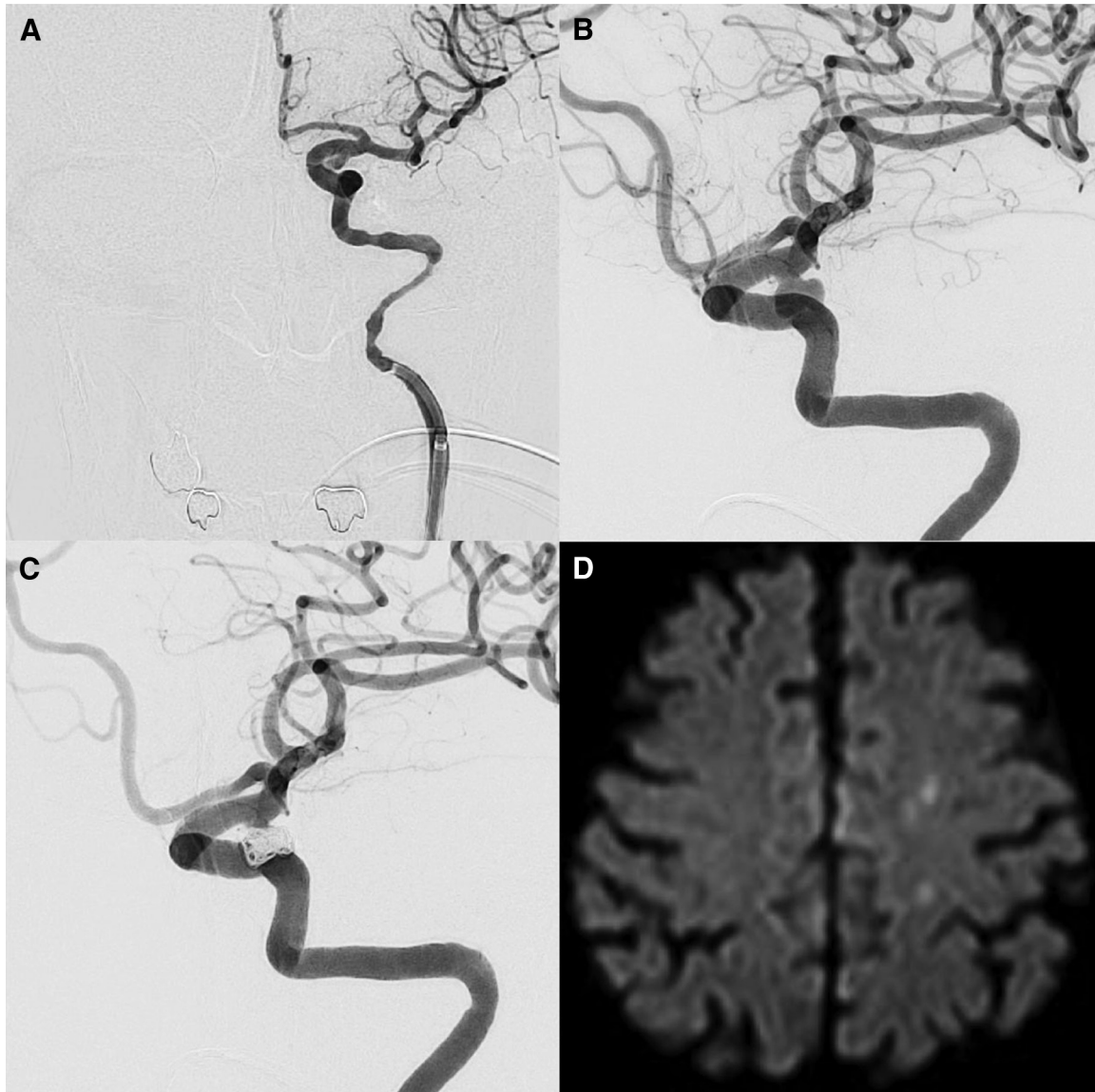


Fig. 2 A representative case of mechanical vasospasm and postoperative cerebral infarction. Representative case of a 79-year-old woman with left-sided internal carotid-posterior communicating aneurysm. Test injection of contrast medium showed flow stagnation at the catheter tip, and we had to pull the intermediate catheter down to the level shown in A. Coil embolization was completed without any intraoperative problems (B, preoperative image; C, postoperative image). Postoperative MRI showed seven DWI hyperintense spots, with three of these seven spots shown in D. DWI: diffusion-weighted imaging, MRI: magnetic resonance imaging.

catheter angiography, more carotid curves $\geq 30^\circ$, and intense anxiety were risk factors for MVS.⁷⁾ Our study revealed that female sex, use of a 6-Fr intermediate catheter, and maximum carotid angle $< 70^\circ$ were risk factors for MVS. Maximum carotid angle $< 70^\circ$, indicating milder tortuosity, was a paradoxical risk factor for MVS, considering that vasospasm has been empirically known to be more likely to occur when guiding a catheter in cases with tortuous vessels. In our treatment, however, we used a flexible intermediate catheter for passage through a tortuous vessel,

and the primary guiding catheter was often placed proximally to the prominent curve to preclude vasospasm. The present results suggest that women without tortuous vessels, that is, those who have few vascular risks, were more likely to develop MVS.

With regard only to significant MVS, the risk factor was a higher ratio of the caliber of the guiding system to that of the parent artery. If the catheter caliber increases by 10% of the diameter of the parent artery, the risk of postoperative DHS ≥ 3 is increased approximately three-fold. In addition,

significant MVS was the most significant risk factor for ≥ 3 DHS. However, we consider that insufficient cerebral perfusion during a vasospastic state of the vessel is not only the primary cause of postoperative cerebral ischemia. According to previous reports on vasospasm in other areas, distal embolism might occur due to intimal injury.¹²⁾

In our study, navigating the guiding system more distally was not identified as a risk factor for overall MVS, significant MVS, or postoperative DHS. We suggest that an intermediate catheter with better trackability would not interfere with treatment if safely guided distally. Use of stents and a longer procedure time, which have been noted as risk factors for postoperative DHS in the literature,^{3, 5)} were also not significantly associated with postoperative DHS in this study. However, univariate analysis showed significant differences in both parameters, and continued accumulation of cases may clarify the relationship between these factors and postoperative DHS.

No patients in this study developed noticeable cognitive deterioration or permanent neurological deficits. Whether clinically silent DWI hyperintensity affects the daily activity of patients remains unclear. No previous studies found any significant association between DWI hyperintensity and postoperative cognitive changes.⁸⁾ Nevertheless, the risk of thromboembolic complications is substantial if flow stagnation persists, which is likely to affect outcomes. Significant MVS thus potentially worsens the prognosis of treatment, and the selection and navigation of the devices should be performed with due care.

Limitations

First, this study was retrospective. Second, risk factors for MVS of any severity might have been overfitted in logistic regression analysis. Third, these findings may not be applicable to different guiding systems. Fourth, parameters in DWI differed between the latest and old image protocols. Fifth, we did not evaluate all the anatomical factors that can be associated with postoperative cerebral infarction, such as the branching angle of the common carotid artery from the aortic arch. In addition, we did not examine the causes of postoperative cerebral infarction individually according to the underlying conditions (hypoperfusion or embolism). Finally, three neurointerventionists verified the number of DHS, but this was not absolutely objective data.

Conclusion

Regarding significant MVS, which influences the procedure, the only risk factor appears to be a higher

caliber ratio. In addition, significant MVS is the only risk factor in postoperative DHS. Among patients with high-risk features for MVS, we should avoid navigating the guiding system forcibly into narrow segments of the parent vessel. Higher positioning of the guiding catheter itself was not identified as a risk, suggesting that guiding an intermediate catheter with better trackability safely and distally will not hinder the procedure. That is, navigating the large-caliber guiding sheath/catheter proximally and guiding only the small-caliber intermediate catheter distally appears crucial.

Conflicts of Interest Disclosure

This research did not receive any specific grant from funding agencies from the public, commercial, or not-for-profit sectors. There are no competing interests to declare.

References

- 1) Bond KM, Brinjikji W, Murad MH, Kallmes DF, Cloft HJ, Lanzino G: Diffusion-weighted imaging-detected ischemic lesions following endovascular treatment of cerebral aneurysms: a systematic review and meta-analysis. *AJNR Am J Neuroradiol* 38: 304–309, 2017
- 2) Kang DH, Kim BM, Kim DJ, et al.: MR-DWI-positive lesions and symptomatic ischemic complications after coiling of unruptured intracranial aneurysms. *Stroke* 44: 789–791, 2013
- 3) Park JC, Lee DH, Kim JK, et al.: Microembolism after endovascular coiling of unruptured cerebral aneurysms: incidence and risk factors. *J Neurosurg* 124: 777–783, 2016
- 4) Sim SY, Shin YS: Silent microembolism on diffusion-weighted MRI after coil embolization of cerebral aneurysms. *Neurointervention* 7: 77–84, 2012
- 5) Lee SH, Jang MU, Kang J, et al.: Impact of reducing the procedure time on thromboembolism after coil embolization of cerebral aneurysms. *Front Neurol* 9: 1125, 2018
- 6) Ikeda G, Tsuruta W, Nakai Y, et al.: Anatomical risk factors for ischemic lesions associated with carotid artery stenting. *Interv Neuroradiol* 20: 746–754, 2014
- 7) Ishihara H, Ishihara S, Niimi J, et al.: Risk factors and prevention of guiding catheter-induced vasospasm in neuroendovascular treatment. *Neurol Med Chir (Tokyo)* 55: 261–265, 2015
- 8) Kang DH, Hwang YH, Kim YS, Bae GY, Lee SJ: Cognitive outcome and clinically silent thromboembolic events after coiling of asymptomatic unruptured intracranial aneurysms. *Neurosurgery* 72: 638–645; discussion 645, 2013
- 9) Takigawa T, Suzuki K, Sugiura Y, et al.: Thromboembolic events associated with single balloon-, double balloon-, and stent-assisted coil embolization of asymptomatic unruptured cerebral aneurysms:

- evaluation with diffusion-weighted MR imaging. *Neuroradiology* 56: 1079–1086, 2014
- 10) Kim MS, Jo KI, Yeon JY, et al.: Association between postprocedural infarction and antiplatelet drug resistance after coiling for unruptured intracranial aneurysms. *AJNR Am J Neuroradiol* 37: 1099–1105, 2016
- 11) Kanamaru H, Satow T, Sugata S, et al.: Risk factors of mechanical vasospasm caused by guiding catheter during neuroendovascular therapy. *JNET J Neuroendovas Ther* 9: 233–237, 2015
- 12) Etsuda H, Mizuno K, Arakawa K, Satomura K, Shibuya T, Isojima K: Angioscopy in variant angina: coronary artery spasm and intimal injury. *Lancet* 342: 1322–1324, 1993

Corresponding author: Wataro Tsuruta, MD, PhD
Department of Endovascular Neurosurgery, Toranomon Hospital, 2-2-2 Toranomon, Minato-ku, Tokyo 105-8470, Japan.
e-mail: wataro@cf6.so-net.ne.jp