

Dual Pathology of Mandible

Suday G. Rajurkar, Mohan D. Deshpande, Noaman Kazi, Dhanashree Jadhav¹, Pallavi Ranadive, Snehal Ingole

Department of Oral and Maxillofacial Surgery, Nair Hospital Dental College, Mumbai, ¹Department of Dentistry, Sasoon Hospital, Pune, Maharashtra, India

Abstract

Aneurysmal Bone cyst (ABC) is a rare benign lesion of the bone which is infrequent in craniofacial region (12%). Rapid growth pattern causing bone expansion and facial asymmetry is a characteristic feature of ABC. Giant cell lesion is another distinct pathological entity. Here we present to you a rare case of dual pathology in an 11 year old female patient who presented with a large expansile lesion in the left hemimandible. All radiographic investigations were suggestive of ABC, aspiration of the lesion resulted in blood aspirate. However only after a histologic examination the dual nature of the lesion was revealed.

Keywords: Aneurysmal bone cyst, dual pathology, giant cell lesion

INTRODUCTION

Aneurysmal bone cyst (ABC) is rare benign, osteolytic^[1,2] lesion occurring more often in long bones owing to high marrow content and relatively higher venous pressure.^[3] ABC is considered to be a pseudocyst and accounts for a rare number of nonodontogenic cysts; more common in mandible than maxilla, preferentially posterior mandible, and generally seen before second decade of life.

CASE REPORT

An 11-year-old female patient reported with painless, gradually increasing but otherwise asymptomatic swelling in the left mandible for 1 year. History of trauma, family, and medical history was insignificant. Extraoral examination revealed fluctuant 5 x 5cm swelling involving (L) body and inferior border of mandible [Figure 1]. No carious teeth were seen. In view of patient's age and the absence of any dental focus, necessary consultations were done to rule out tuberculosis or any other systemic endocrinal disease. Orthopantomogram (OPG) and computed tomography (CT) scans revealed a multilocular lytic radiolucency extending from 33 to (L) retromolar region with marked thinning and discontinuity of lower border and apical root resorption of second premolar and first molar [Figures 2 and 3]. Differential diagnosis suggested was pediatric ameloblastoma/ABC. Aspiration yielded bright red blood. USG described the lesion as hypochoic having internal vascularity and calcification suggestive of neoplastic pathology.

Magnetic resonance imaging (MRI) was advised for a definitive diagnosis. However, patient reported for further treatment only after 3 months due to financial constraints. MRI was suggestive of ABC. Mandibular occlusal radiograph showed expansion of both cortices. Clinical examination carried out subsequent to the MRI, showed loss of fluctuation along the inferior border replaced by a firm, nontender expansion resistant to aspiration. Overlying skin was normal. Distinguishing characteristic about the swelling was a pronounced ballooning nature along the inferior border of mandible. Digital OPG was repeated to compare the radiographic changes with previous OPG. Second, OPG showed an aggressive picture with considerable increase in size, a characteristic honeycomb appearance and gross expansion of inferior border of mandible. Mandibular canal could not be traced. First and second molars showed aggressive external resorption extending to middle thirds of roots.

Intraoperatively, the lesion was found to be solidified and relatively hypovascular than expected [Figure 4]. Considering the large size, aggressive behavior of the lesion and CT/MRI diagnosis, namely, ABC-segmental resection with adequate safe margins and primary reconstruction with Titanium recon plate was performed. The ideal reconstruction would have been

Address for correspondence: Dr. Suday Gajananrao Rajurkar, Department of Oral and Maxillofacial Surgery, Nair Hospital Dental College, Mumbai, Maharashtra, India.
E-mail: suday.rajurkar@gmail.com

Access this article online

Quick Response Code:



Website:
www.amsjournal.com

DOI:
10.4103/ams.ams_146_16

This is an open access article distributed under the terms of the Creative Commons Attribution-NonCommercial-ShareAlike 3.0 License, which allows others to remix, tweak, and build upon the work non-commercially, as long as the author is credited and the new creations are licensed under the identical terms.

For reprints contact: reprints@medknow.com

How to cite this article: Rajurkar SG, Deshpande MD, Kazi N, Jadhav D, Ranadive P, Ingole S. Dual pathology of mandible. Ann Maxillofac Surg 2017;7:316-8.

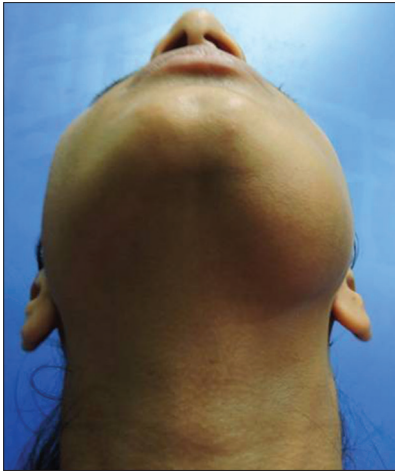

Figure 1: Facial swelling in left hemimandible

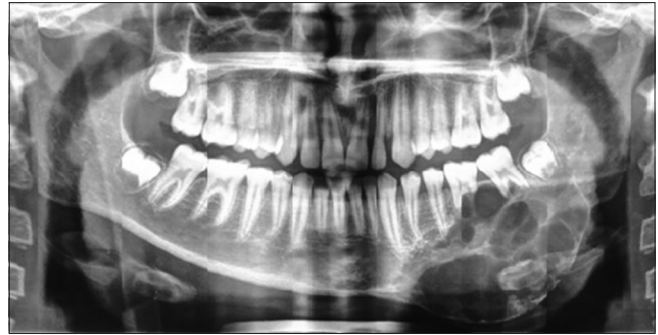

Figure 2: Orthopantomogram showing honeycomb appearance

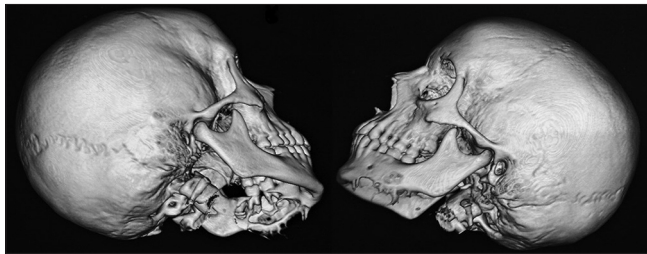

Figure 3: Three-dimensional computed tomography face showing perforation of lingual and buccal cortices

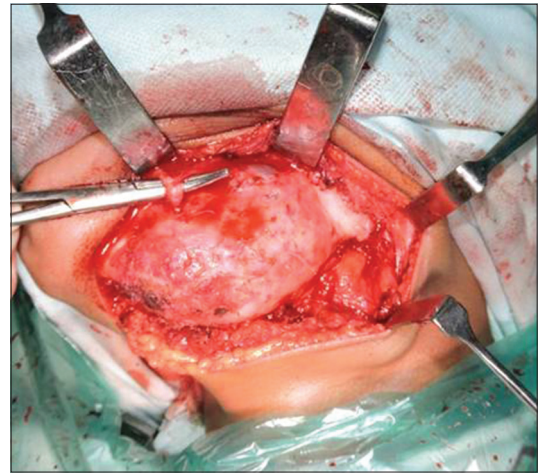


Figure 4: Intraoperative exposed tumor mass

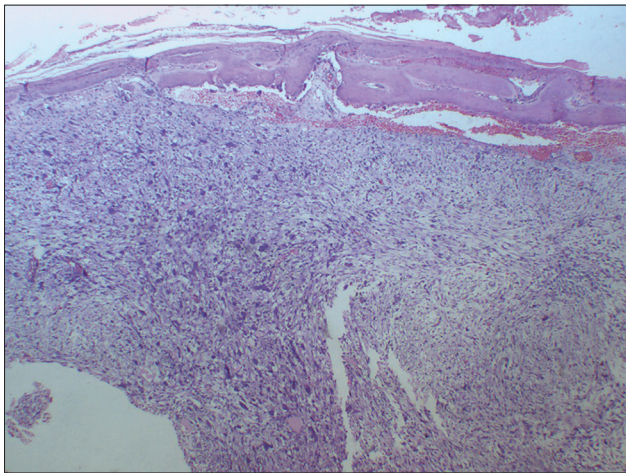


Figure 5: Histopathology image showing bone, large vascular space, cellular tumor mass consisting of multinucleated giant cells confirming giant cell lesion with Aneurysmal bone cystic changes

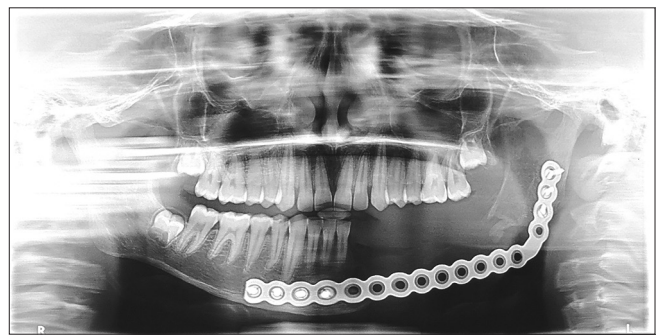


Figure 6: Postoperative orthopantomogram

using free fibula graft; however, as the patient was unwilling for a second surgical site, we had to do the reconstruction with Titanium plate [Figure 5]. Histopathologic diagnosis obtained was Giant Cell lesion with ABC changes [Figure 6].

DISCUSSION

ABC of the jaws is a lesion with controversy surrounding its etiology and pathogenesis. Some authorities recognize that

trauma plays a significant role in its development but our patient did not give any history of trauma. Hernandez *et al.* and Steiner proposed 2 types of ABC:

1. Primary-arise de novo; could be congenital or acquired
2. Secondary-occur in children and young adults and has a coexisting lesion.^[4,5]

In our case, ABC coexisted with a giant cell lesion but there was no classical “welling up” of blood phenomenon encountered at the time of surgery. Therefore, this case should be considered in dual lesion category. The concept that ABC can arise from a preexisting bone lesion has been suggested by Beiseker *et al.* and there is a good evidence to sustain it.^[6] It presented with



Figure 7: Postoperative clinical photograph

confusing clinical and radiological picture which in turn created a dilemma in our minds regarding the nature of the pathology and the choice of treatment. Sclerotherapy, embolization followed by enucleation and curettage have been reported. Motamedi and Stavropoulos^[7] have advocated conservative management such as curettage of mandibular lesions as they did not note any recurrences in the cases treated by them. However, due to high recurrence rate of 21%–50%, resection of the lesion followed by immediate reconstruction has been advocated.

In view of the patient's age, conservative management to prevent postsurgical cosmetic and functional deformity should have been the preferred choice of treatment. However, due to aggressive nature of the lesion, resection was the only choice. The multilocular appearance and vascularity of the lesion implied intraoperative blood loss which posed a potential risk to the patient. However, during surgery, the lesion presented a solid multicystic appearance with minimum vascularity, which was in contrast to the radiological picture and ultrasound. Considering the age of the patient and aggressive nature of the lesion, caution, and restraint remained the cornerstones in the choice of treatment. In hindsight, the delay which occurred

between initial investigations and the final treatment seems to have proved beneficial to the patient as the lesion was found to have solidified.

Surgery was uneventful and postsurgical recovery was satisfactory with minimal loss of facial contours [Figure 7]. Patient is now kept under observation.

Declaration of patient consent

The authors certify that they have obtained all appropriate patient consent forms. In the form the patient(s) has/have given his/her/their consent for his/her/their images and other clinical information to be reported in the journal. The patients understand that their names and initials will not be published and due efforts will be made to conceal their identity, but anonymity cannot be guaranteed.

Financial support and sponsorship

Nil.

Conflicts of interest

There are no conflicts of interest.

REFERENCES

1. Breuer C, Paul H, Zimmermann A, Braunstein S, Schaper J, Mayatepek E, *et al.* Mandibular aneurysmal bone cyst in a child misdiagnosed as acute osteomyelitis: A case report and a review of the literature. *Eur J Pediatr* 2010;169:1037-40.
2. Cottalorda J, Kohler R, Sales de Gauzy J, Chotel F, Mazda K, Lefort G, *et al.* Epidemiology of aneurysmal bone cyst in children: A multicenter study and literature review. *J Pediatr Orthop B* 2004;13:389-94.
3. Goyal A, Tyagi I, Syal R, Agrawal T, Jain M. Primary aneurysmal bone cyst of coronoid process. *BMC Ear Nose Throat Disord* 2006;6:4.
4. Dormans JP, Hanna BG, Johnston DR, Khurana JS. Surgical treatment and recurrence rate of aneurysmal bone cysts in children. *Clin Orthop Relat Res* 2004;421:205-11.
5. Martinez V, Sissons HA. Aneurysmal bone cyst. A review of 123 cases including primary lesions and those secondary to other bone pathology. *Cancer* 1988;61:2291-304.
6. Biesecker JL, Marcove RC, Huvos AG, Miké V. Aneurysmal bone cysts. A clinicopathologic study of 66 cases. *CANCER* 1970;26:615-25.
7. Motamedi MH, Stavropoulos MF. Large radiolucent lesion of the mandibular condyle. *J Oral Maxillofac Surg* 1997;55:1300-4.