

Received: 2011.01.10
Accepted: 2011.03.16
Published: 2011.09.01

Eph-A2 and Eph-A4 expression in human benign and malignant thyroid lesions: An immunohistochemical study

Authors' Contribution:

- A** Study Design
- B** Data Collection
- C** Statistical Analysis
- D** Data Interpretation
- E** Manuscript Preparation
- F** Literature Search
- G** Funds Collection

Nikolaos P. Karidis^{1BEG}, Constantinos Giaginis^{1ACDE}, Gerasimos Tsourouflis^{1BG}, Paraskevi Alexandrou^{2B}, Ioanna Delladetsima^{2B}, Stamatios Theocharis^{1ADEG}

¹ Department of Forensic Medicine and Toxicology, Medical School, University of Athens, Athens, Greece

² 1st Department of Pathology, Medical School, University of Athens, Athens, Greece

Source of support: Departmental sources

Summary

Background:

Ephrin receptors (Ephs) are frequently overexpressed in a wide variety of human malignant tumors, being associated with tumor growth, invasion, metastasis and angiogenesis. The aim of the present study was to evaluate the clinical significance of Eph-A2 and Eph-A4 expression in human benign and malignant thyroid lesions.

Material/Methods:

Eph-A2 and Eph-A4 protein expression was assessed immunohistochemically on paraffin-embedded thyroid tissues from 131 patients with benign and malignant lesions.

Results:

Eph-A2 was significantly overexpressed in malignant compared to benign thyroid lesions ($p < 0.001$). Papillary carcinoma cases presented significantly increased Eph-A2 expression compared to those with hyperplasia nodules ($p < 0.001$). Eph-A4 expression was not differentiated between cases with malignant or benign thyroid lesions. Papillary carcinoma cases presented significantly increased Eph-A4 expression compared to those with hyperplasia nodules ($p = 0.006$). In the subgroup of malignant thyroid lesions, Eph-A2 and Eph-A4 expression was not associated with TNM stage, capsular, lymphatic or vascular invasion.

Conclusions:

The present data suggest that Eph-A2, but not Eph-A4, overexpression may be associated with the malignant transformation of thyroid neoplasia. Further studies conducted on cohorts including a higher proportion of patients with advanced nodal and metastatic disease are recommended to draw definite conclusions on the clinical significance of Eph proteins in thyroid neoplasia.

Key words:

Ephrin receptors • Eph-A2 • Eph-A4 • thyroid malignancy • clinicopathological parameters • immunohistochemistry

Full-text PDF:

<http://www.medscimonit.com/fulltxt.php?ICID=881929>

Word count:

3298

Tables:

4

Figures:

2

References:

54

Author's address:

Stamatios E. Theocharis, Pathologist, Assistant Professor of Forensic Medicine and Toxicology, University of Athens, Medical School, 75, Mikras Asias street, Goudi, Athens, GR11527, Greece, e-mail: theocharis@ath.forthnet.gr

BACKGROUND

Ephrin receptors (Eph) are the largest family of tyrosine kinase receptors (RTKs), divided into 2 distinct classes (A and B) based on sequence homology of their extracellular domain, which largely determines their ephrin ligands [1]. In general, A-class ephrins (ephrin A1-A6) bind to the A-class Eph receptors (Eph-A1-A10) and B-class ephrins (ephrin B1-B3) bind to B-class receptors (EphB1-B6), although cross-reactions have also been described [2,3]. Interaction between ephrin receptors and their ligands (ephrins) occurs at sites of cell-to-cell contact, since both molecules are membrane-bound, or between plasma membrane clusters (microdomains) that transform into clearly defined signaling centers upon Eph/ephrin complex formation [4]. The cellular response to Eph stimulation by ligands includes a wide range of biological effects exerted through several signaling pathways in a bi-directional mode. This is considered a unique property of Eph/ephrin interaction and consists of forward and reverse signaling components [5]. Eph/ephrin signaling has mainly been implicated in angiogenesis [6,7], cell shape formation, adhesion and motility [8,9] in normal developmental and in pathological processes. Ubiquitous expression of Eph and ephrins in the vast majority of normal human tissues has suggested a crucial role in the maintenance of organized and differentiated cellular function in adults, although specific expression patterns by organ have also been described [10]. More recently, tumorigenesis has been related to transcriptional alterations of Eph genes through somatic mutations and epigenetic silencing, especially in more advanced stages of tumor progression [11,12], suggesting a potential role for Ephs in tumor cell migration and metastasis.

Recent studies have been focused mainly on Eph-A2 expression and the role of Eph-A2/ephrin-A1 interaction in several human malignancies, indicating a crucial role in tumor development and progression. Eph-A2 was found to be widely expressed in highly proliferating human tissues and overexpressed in several types of malignancy, such as melanoma, prostate, breast, ovarian, esophageal, liver, lung and gastrointestinal cancer [10,13–18]. According to a theoretical, but realistic, model proposed by Wykosky and Debinski, non-phosphorylated Eph-A2 may stimulate oncogenic signaling pathways, leading to increased cell migration and invasion due to Eph-A2 gene overexpression or lack of ephrinA1-induced down-regulation [18]. The expression levels of Eph receptor in pathological processes seem to correlate positively with the degree of malignant transformation, whereas this has not been well documented for the ephrin ligands [11]. The predictive value of Eph-A2 expression pattern for tumor grade, stage, recurrence and/or survival has also been investigated in ovarian, gastric, lung and prostate cancers, suggesting a substantial correlation between Eph-A2 overexpression and poor clinical prognosis in most cases [17,19–22]. The diversity of Eph-mediated functions in virtually every stage of tumorigenesis from development to metastasis and interference in cell-to-cell interactions and the tumor microenvironment have made this receptor family an attractive target for novel drug design in cancer therapeutics.

Thyroid cancer is generally considered a curable malignancy in its early stages, although management of suspect thyroid lesions has continuously evolved during the last decades

and is updated on a regular basis, indicating the presence of diagnostic pitfalls and limitations of the current patient workup. Several markers have been investigated in an effort to increase the diagnostic accuracy of fine-needle aspiration biopsy in the preoperative setting [23–25]. At the same time, novel prognostic indices are being evaluated for their role in the optimal postoperative management of thyroid cancer [26–29]. Unlike the other above-mentioned solid organ tumors, the expression of Ephs in human benign and malignant thyroid lesions has not yet been evaluated. In light of the above considerations, the present study aimed to examine the immunohistochemical expression of Eph-A2 and -A4 in 131 patients with benign and malignant thyroid lesions and to assess their diagnostic utility. We also aimed to evaluate the association of Eph-A2 and Eph-A4 expression with important clinicopathological characteristics for the management of patients with malignant thyroid tumors, such as TNM stage, and capsular, lymphatic and vascular invasion.

MATERIAL AND METHODS

Clinical material

We used 131 formalin-fixed, paraffin-embedded thyroid specimens from an equal number of patients who had undergone surgery for benign or malignant thyroid disease. None of the patients had received anti-cancer treatment preoperatively. The WHO histological classification of thyroid tumors was used, according to which 59 malignant (47 papillary, 5 follicular, 5 medullary and 2 anaplastic thyroid carcinomas) and 72 benign (61 hyperplastic nodules and 11 Hashimoto thyroiditis) thyroid cases were observed. Among papillary thyroid carcinoma cases, 43 were classified as classical subtype with papillary architecture and 5 as follicular variant. All follicular carcinomas were classified as minimally invasive. Thyroid malignancies were grouped according to the latest TNM classification (American Joint Committee on Cancer – AJCC Cancer Staging Manual, seventh edition) [30] as: stage I, 40 cases (67.8%); stage II, 8 cases (13.6%); stage III, 8 cases (13.6%); and stage IV, 3 cases (5%). A female predominance was also noted in our study population, which reached 5:1 in the subset of malignant thyroid tumors. The median size of malignant thyroid tumors was 8 mm (range 0.9–80 mm). The characteristics of the study population are summarized in Table 1.

Immunohistochemistry

Eph-A2 and Eph-A4 immunostaining was performed on formalin-fixed, paraffin-embedded thyroid tissue sections using rabbit polyclonal anti-Eph-A2 (S-20) and anti-Eph-A4 (H-77) primary IgG antibodies (Santa Cruz Biochemicals, Santa Cruz, CA, USA). Briefly, 4 µm-thick tissue sections were dewaxed in xylene and were brought to water through graded alcohols. Antigen retrieval (citrate buffer at pH 6.1 and microwave heating) was performed according to the manufacturer's instructions. To remove the endogenous peroxidase activity, sections were treated with freshly prepared 0.3% hydrogen peroxide in methanol in the dark for 30 minutes (min) at room temperature. Non-specific antibody binding was then blocked using Sniper (Sniper, Biocare Medical, Walnut, Creek, CA, USA), a specific blocking reagent for mouse and rabbit primary antibodies, for 5 min.



Table 1. Study population characteristics.

	Benign	Malignant
N (total)=131	72 (55)	59 (45)
Male	18 (25)	10 (16.9)
Female	54 (75)	49 (83.1)
Age (yrs)	47.6±12.1	49.7±12.9
Histopathology	Hyperplastic nodule 61 (46.6)	Papillary 47 (35.9)
	Hashimoto's thyroiditis 11 (8.4)	Follicular 5 (3.8)
		Medullary 5 (3.8)
		Anaplastic 2 (1.5)
Tumor size (T)	N/A ^a	
T1		40 (67.8) ^b
T2		13 (22) ^b
T3		3 (5.1) ^b
T4		3 (5.1) ^b
Lymph node metastases (N)	N/A	
N0		51 (86.4) ^b
N1		8 (14.6) ^b
Distant metastases (M)	N/A	
M0		59 (100) ^b

	Benign	Malignant
TNM staging	N/A	
Stage I		40 (67.8) ^b
Stage II		8 (13.6) ^b
Stage III		8 (13.6) ^b
Stage IV		3 (5) ^b
Capsular invasion	N/A	
No		38 (79.2) ^c
Yes		10 (20.8) ^c
Lymphatic invasion	N/A	
No		40 (83.3) ^c
Yes		8 (16.7) ^c
Vessel invasion	N/A	
No		44 (91.7) ^c
Yes		4 (8.3) ^c
Ki-67 protein statement		
< Mean value	24 (33.3)	10 (17)
≥ Mean value	48 (66.7)	49 (83)

^a N/A: not applicable, ^b Percentages in parentheses correspond to the number of malignant thyroid cases, ^c Data were available for 48 malignant thyroid cases.

The sections were then incubated for 1 hour at room temperature, with the primary antibodies diluted 1:100 in phosphate-buffered saline (PBS). After washing 3 times with PBS, sections were incubated at room temperature with biotinylated linking reagent (Biocare Medical) for 10 min, followed by incubation with peroxidase-conjugated streptavidin label (Biocare Medical) for 10 min. The resultant immune peroxidase activity was developed in 0.5% 3,3'-diaminobenzidine hydrochloride (DAB; Sigma, St. Louis, MO, USA) in PBS containing 0.03% hydrogen peroxide for 3 min. Sections were counterstained with Harris' hematoxylin and mounted in Entellan (Merck, Darmstadt, Germany). Appropriate negative controls were performed by omitting the primary antibody and/or substituting it with an irrelevant anti-serum. As a positive control, pancreatic cancer tissue sections with known increased Eph-A2 and Eph-A4 immunoreactivity were used [31]. Follicular cells' proliferative capacity was assessed immunohistochemically, using a mouse *anti*-human Ki-67 antigen; IgG_{1k} antibody (clone MIB-1, Dakopatts, Glostrup, Denmark) as previously described [32,33].

Evaluation of immunohistochemistry

Specimens were considered positive for Eph-A2, Eph-A4 and Ki-67 when more than 5% of the follicular cells were stained.

The percentage of positively stained follicular cells was obtained by counting at least 1000 cells in each case by 2 independent observers (S.T. and P.A.) blinded to the clinical data, with complete observer agreement. Both membranous and cytoplasmic staining was taken into consideration in determining Eph-A2 and Eph-A4 immunoreactivity. Ki-67 immunoreactivity was classified into 2 categories (below and over mean value) according to the percentage of positively stained follicular cells exceeding the mean percentage value, as previously reported [32,33].

As there are no clinically relevant cut-off values available for Eph-A2 and Eph-A4 expression levels in thyroid lesions, a quantitative scoring system was applied based on previously published reports for other immunohistochemical markers on thyroid tissue lesions [34–37]. The immunoreactivity of follicular cells for Eph-A2 and Eph-A4 was scored according to the percentage of positively stained cells as follows: 0 = 0–4% of follicular cells positive (considered as negative staining), 1 = 5–30% of follicular cells positive, 2 = 31–60% of follicular cells positive, 3 = 61–100% of follicular cells positive, and their intensity scored as 0 = negative staining, 1 = weak staining, 2 = intermediate staining, and 3 = intense staining. Immunoreactivity was also classified, using the term total immunohistochemical (IHC) score,

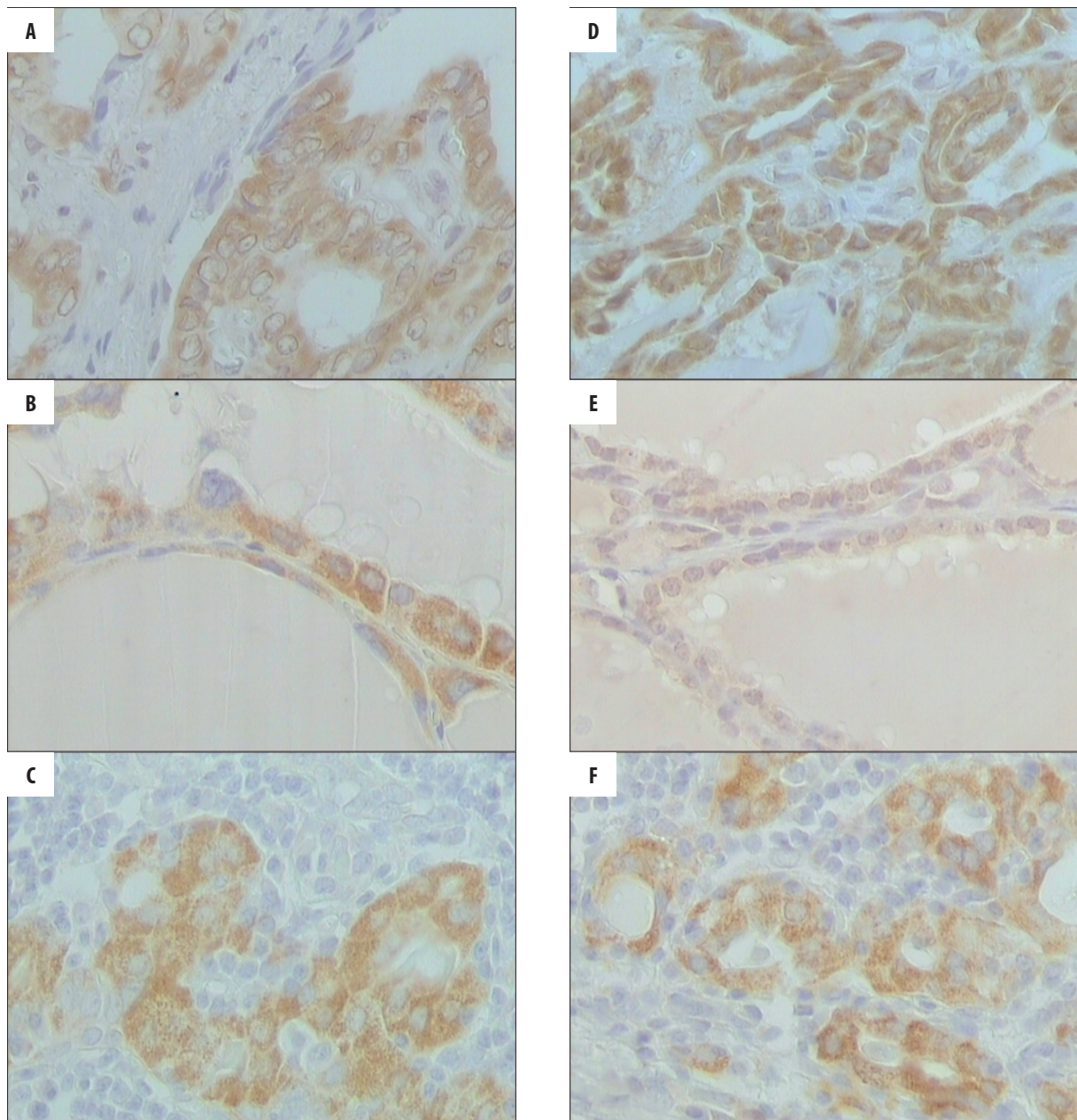


Figure 1. Representative immunostainings for Eph-A2 (A, B and C) and Eph-A4 (D, E and F) in cases with papillary carcinoma, hyperplastic nodules and Hashimoto thyroiditis (original magnification $\times 400$).

as “negative or weak” for a total score 0–2, “moderate” for a total score 3–4, and “strong” for a total score 5–7. In this way we ensured that each group had a sufficient and more homogeneous number of cases in order to be comparable with the other groups [37].

Statistical analysis

The differences in Eph-A2 and Eph-A4 expression between the histopathological types of thyroid lesions, as well as the association with the clinicopathological parameters in the subgroup of malignant cases, were investigated. Possible associations were analyzed with the Pearson’s chi-square test and linear correlations were investigated using Spearman’s rho coefficient and Cramer’s V test for categorical data. A

Kruskal-Wallis analysis was made for ordinal variables, followed by a Mann-Whitney U test for significant associations only. The α level of statistical significance was determined at 5% (2-tailed $p < 0.05$). SPSS Statistics software v.17.0 (SPSS Inc., Chicago, IL, USA) was used for statistical analysis.

RESULTS

Eph-A2 positivity (IHC score > 0) was noted in 75 out of 131 (57.3%) thyroid tissue specimens. Positive staining was observed in 74.6% (44/59) of malignant thyroid tumors, 39.3% (24/61) of hyperplastic nodules and 63.6% (7/11) of Hashimoto thyroiditis cases. In Figure 1, representative Eph-A2 immunostaining for papillary carcinoma, hyperplastic nodules and Hashimoto thyroiditis cases are depicted

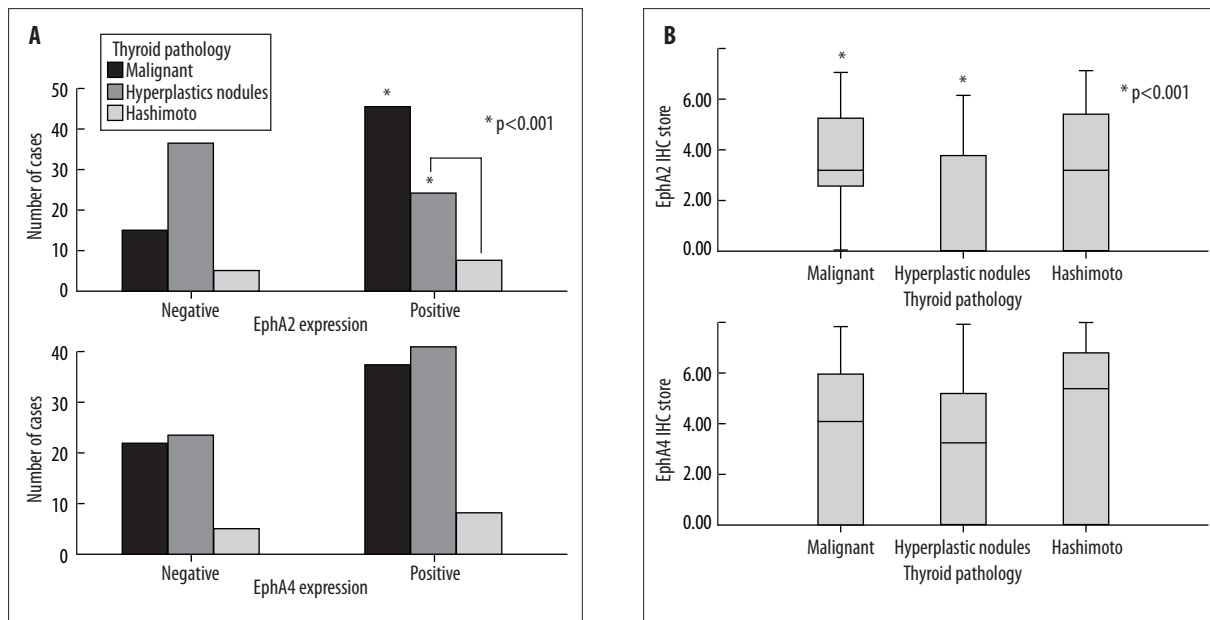


Figure 2. Eph-A2 and Eph-A4 expression pattern in malignant and benign thyroid lesions (A and C). Box-whisker plot of Eph-A2 and Eph-A4 immunoreactivity score by type of thyroid pathology (B and D).

Table 2. Eph-A2 expression in malignant and benign thyroid lesions.

Thyroid lesions	N	Eph-A2 expression			IHC score ^a (mean±SD)	p-value
		Negative/Weak	Moderate	Strong		
Malignant						0.001 ^b
Papillary carcinoma	47	12 (25.6)	17 (36.2)	18 (38.3)	3.38±2.12	
Follicular carcinoma	5	1 (20)	3 (60)	1 (20)	2.80±1.79	
Medullary carcinoma	5	2 (40)	2 (40)	1 (20)	2.20±2.17	
Anaplastic carcinoma	2	0 (0)	2(100)	0 (0)	4.0±0.0	
Benign						
Hyperplastic nodules	61	37 (60.7)	18 (29.5)	6 (9.8)	1.61±2.01	<0.001 ^c
Hashimoto's thyroiditis	11	4 (36.4)	4 (36.4)	3 (27.3)	2.91±2.66	0.457 ^d

Numbers in parentheses represent percentages.

^a Immunohistochemical score. ^b Cramer's V chi-square; statistical significance between malignant and benign lesions. ^c Mann-Whitney test; statistical significance between papillary carcinoma and hyperplastic nodules. ^d Mann-Whitney test; no statistical significance between malignant lesions and hashimoto's thyroiditis.

(Figure 1A–C, respectively). Cases with malignant thyroid lesions showed significantly increased incidence of Eph-A2 positivity compared to those with benign thyroid lesions (Cramer's V=0.343, p<0.001). Eph-A2 positivity was definitely distinctive between cases with papillary carcinoma and hyperplastic nodules (z=-3.877, p<0.001, Figure 2A). No significant differences between malignant and Hashimoto thyroiditis or benign hyperplasia and Hashimoto thyroiditis cases were noted (p=0.457 and p=0.137, respectively). Significant intergroup differences were also not observed for all possible comparisons of malignant histopathological types (data not shown). Eph-A2 positively stained cases of thyroid lesions, either malignant or benign, exhibited overall higher proliferative capacity, as shown by Ki-67

immunoreactivity (p=0.04), although no statistically significant difference was observed in favor of malignant lesions (data not shown). The mean total score of Eph-A2 positive malignant cases was significantly higher than that of benign cases (Cramer's V=0.361, p=0.001). Significantly higher IHC score for malignant compared to hyperplastic thyroid lesions was also noted (z=-3.899, p<0.001, Figure 2B). Papillary carcinomas showed significantly higher Eph-A2 expression than hyperplastic thyroid nodules (z=-4.270, p<0.001), whereas this was not found for other types of malignant thyroid lesions (i.e., follicular, medullary or anaplastic cancer). The mean total IHC score of malignant tumors was 3.25±2.06, with 40.7% of them exhibiting moderate (total score 3 or 4) and 33.9% strong (total score 5-7) Eph-A2

Table 3. Eph-A4 expression in malignant and benign thyroid lesions.

Thyroid lesions	N	Eph-A4 expression			IHC score ^a (mean±SD)	p-value
		Negative/Weak	Moderate	Strong		
Malignant						0.546^b
Papillary carcinoma	47	14 (29.8)	8 (17)	25 (53.2)	3.77±2.73	
Follicular carcinoma	5	3 (60)	1 (20)	1 (20)	2.00±2.83	
Medullary carcinoma	5	4 (80)	0 (0)	1 (20)	1.40±3.13	
Anaplastic carcinoma	2	1 (50)	0 (0)	1 (50)	3.50±4.95	
Benign						0.006^c
Hyperplastic nodules	61	22 (36.1)	21 (34.5)	18 (29.5)	2.84±2.33	
Hashimoto's thyroiditis	11	4 (36.4)	1 (9.1)	6 (54.6)	3.64±3.11	

Numbers in parentheses represent percentages.

^a Immunohistochemical score. ^b Pearson's R chi-square; no statistical significance between malignant and benign lesions. ^c Mann-Whitney test; statistical significance between papillary carcinoma and hyperplastic nodules.

expression. On the other hand, the mean total score of benign thyroid lesions was 1.8 ± 2.2 , with a significantly lower proportion of strong Eph-A2 expression (12.5%, $p<0.05$, Table 2). Eph-A2 expression was not differentiated between conventional type cases and follicular variant cases of papillary carcinoma (data not shown).

Eph-A4 positivity (IHC score >0) was noted in 83 (63.4%) of 131 thyroid tissue specimens. Positive staining was observed in 62.7% (37/59) of malignant lesions, 63.9% (39/61) of hyperplastic nodules and 63.6% (7/11) of Hashimoto thyroiditis cases. In Figure 1, representative Eph-A4 immunostaining for papillary carcinoma, hyperplastic nodules and Hashimoto thyroiditis cases are depicted (Figures 1D, E and F, respectively). No significant differences were noted between cases with malignant and benign thyroid lesions in respect to Eph-A4 positivity (Figure 2C). The mean total IHC score of Eph-A4-positive malignant cases was 3.47 ± 2.87 , with a remarkable proportion of 47.5% showing strong Eph-A4 expression (total score 5-7). Benign thyroid lesions yielded a mean IHC score of 2.96 ± 2.46 , with strong Eph-A4 expression in 33.3% of cases; however, significant differences were not observed (Figure 2D). Non-parametric comparison of the mean ranks by histopathological type of thyroid cancer revealed significantly higher IHC score for cases with papillary carcinoma compared to those with hyperplastic nodules ($z=-2.724$, $p=0.006$), although this effect was not detected for other histopathological types of malignant lesions. In Table 3, Eph-A4 expression by type of thyroid lesion is depicted. The proliferative capacity of all positively stained thyroid lesions for Eph-A4 was similar to Eph-A2-positive samples (ie, increased Ki-67 immunoreactivity) ($p=0.01$) without significant difference between malignant and benign lesions (data not shown). Eph-A4 expression was not differentiated between conventional subtype cases and follicular variant cases of papillary carcinoma (data not shown).

We also assessed whether Eph-A2 and Eph-A4 expression exerts a diagnostic effect in the subgroup of patients with malignant thyroid lesions. For both Ephs, positive staining and IHC score were not correlated with capsular, lymphatic

and vascular invasion. The associations of the clinicopathological characteristics of malignant thyroid lesions (ie, tumor size [T] and nodal status [N]) with Eph-A2 and Eph-A4 expression were also investigated. Overall, 40 T1 (67.8%), 13 T2 (22%), 3 T3 (5.1%) and 3 T4 (5.1%) malignant thyroid cases were analyzed. Nodal involvement was observed in 8 cases (14.6%). T1 cases expressed Eph-A2 in 72.5% (29/40), with a mean total IHC score of 3.22 ± 2.08 , T2 cases in 69.2% (9/13) with a mean total IHC score 2.92 ± 2.43 , T3 and T4 cases in 100% (3/3 in both groups) with a mean total IHC score 4.33 ± 1.15 and 4.0, respectively. Eph-A4 expression was detected in 65% (26/40) of T1 cases with a mean total score 3.56 ± 2.82 , 46.2% (6/13) of T2 tumors with a mean total score 2.46 ± 2.96 , 66.7% (2/3) of T3 tumors with a mean total score 4.33 ± 3.79 and 100.0% (3/3) of T4 tumors with a mean total score 5.66 ± 1.53 . Although T3 and T4 malignant cases showed increased total score for both Eph-A2 and Eph-A4, significant correlations could not be extracted. Similarly, nodal status and the TNM stage were not significantly correlated to Eph-A2 or Eph-A4 expression. Moderate to strong Eph-A2 and Eph-A4 expression was associated with high Ki-67 protein statement, but this association was not statistically significant. The associations between Eph-A2 and Eph-A4 immunoreactivity and the clinicopathological characteristics of the thyroid samples of our study are presented in Table 4.

DISCUSSION

Ephrin receptors and the bidirectional signaling to their ephrin ligands have been shown to actively participate in solid tumor development and/or progression. Substantial evidence has documented the presence of Eph/ephrin complex formation and/or overexpression in response to oncogenic mutations [38] that directly affect tumor immunology, cell motility and adhesion, vessel invasion and metastatic potential [39]. Notably, A-class Eph receptors (EphA) have been involved in tumor angiogenesis and vascularization, mainly through positive and negative stimulation [40-42]. In this aspect, several studies have suggested that Eph-A2 was overexpressed in a variety of malignant tumors, being

Table 4. Associations of Eph-A2 and Eph-A4 expression with clinicopathological characteristics in patients with malignant thyroid lesions

Clinicopathological Characteristics	Eph-A2 expression			p-value ^a	Eph-A4 expression			p-value ^a
	Negative/weak	Moderate	Strong		Negative/weak	Moderate	Strong	
N=59	15 (25.4)	24 (40.7)	20 (33.9)		22 (37.3)	9 (15.2)	28 (47.5)	
Tumor size (T)				0.481				0.510
T1	11 (27.5)	14 (35)	15 (37.5)		14 (35)	6 (15)	20 (50)	
T2	4 (30.8)	6 (46.2)	3 (23)		7 (53.8)	2 (15.4)	4 (30.8)	
T3	0 (0)	1 (33.3)	2 (66.7)		1 (33.3)	0 (0)	2 (66.6)	
T4	0 (0)	3(100)	0 (0)		0 (0)	1 (33.3)	2 (66.6)	
TNM staging				0.953				0.898
I	10 (25)	15 (37.5)	15 (37.5)		13 (32.5)	7 (17.5)	20 (50)	
II	3 (37.5)	4 (50)	1 (12.5)		5 (62.5)	0 (0)	3 (37.5)	
III	2 (25)	2 (25)	4 (50)		4 (50)	1 (12.5)	3 (37.5)	
IV	0 (0)	3(100)	0 (0)		0 (0)	1 (33.3)	2 (66.6)	
Capsular invasion				0.287				0.232
Negative	9 (22.5)	14 (36.8)	15 (37.5)		11 (28.9)	7 (18.4)	20 (52.6)	
Positive	2 (20)	4 (40)	4 (40)		2 (20)	1 (10)	7 (70)	
Lymphatic invasion				0.313				0.964
Negative	9 (23.1)	16 (40)	15 (38.5)		11 (27.5)	6 (15.0)	23 (57.5)	
Positive	2 (25)	2 (25)	4 (50)		2 (25)	2 (25)	4 (50)	
Vessel invasion				0.659				0.799
Negative	10 (25)	15 (37.5)	19 (47.5)		12 (27.3)	7 (15.9)	25 (56.8)	
Positive	1 (25)	2 (50)	1 (25)		0 (0)	1 (20)	3 (60)	
Ki67 protein statement				0.433				0.091
< Mean value	3 (30)	4 (40)	3 (30)		3 (30)	3 (30)	4 (40)	
≥ Mean value	12 (24.5)	20 (40.8)	17 (34.7)		19 (38.8)	6 (12.2)	24 (49)	

^a Pearson's chi-square test.

associated with clinicopathological parameters crucial for patients' management and prognosis, whereas there is no comprehensive research on Eph-A4 member [17,19–22,31]. In this regard, the present study aimed to evaluate the clinical significance of Eph-A2 and Eph-A4 expression in human benign and malignant thyroid lesions.

The present study shows that Eph-A2 but not Eph-A4 expression was enhanced in cases with malignant compared to those with benign thyroid lesions, and especially in papillary carcinomas compared to hyperplastic nodules. Expression of mutant inactive Eph-A2 variants resulted in tumor mass reduction, whereas Eph-A2 upregulation was correlated with tumor stage and progression in several cancers [22,41,43]. Modification of cytoskeletal architecture and loss of expression of adhesion molecules such as E-cadherin have been considered as possible effects of Eph-A2 overexpression, which may in turn lead to cancer cell migration and metastasis. More specifically, the ratio of Eph receptor to ligand density

seems to play a major role *in vivo* by modulating integrin function and increasing tissue invasiveness [44]. However, the role of this potent bidirectional receptor in tumorigenesis and cell migration has been considered far more complex due to ligand-dependency [18]. A dynamic temporal interaction between Eph-A2, its ligands (mainly ephrin A1), and tumor microenvironment might reasonably account for the crucial role of Eph-A2 in several types of cancers. In line with overexpression patterns observed in other solid organ malignancies [16,21,45,46], Eph-A2 receptor seems to play a role in thyroid tumorigenesis, probably associated with the increased proliferative activity of malignant thyroid lesions. Expression of eph-A2 gene, located on chromosome 1p36, was limited to normal tissues with high proliferation rates [10] (e.g., skin and small intestine), although a systematic analysis of Eph-A2 expression in normal tissues has not been done to date. Moreover, we found enhanced proliferative capacity of follicular cells (reflected by Ki-67 protein statement) expressing Eph-A2 or Eph-A4. Although no

distinction could be made between malignant and benign thyroid lesions on the basis of this finding, significant correlations between increased Eph receptor expression and upregulated proliferative status of thyroid cells might underlie the presence of a common pathogenetic deviation from normal development in all types of thyroid pathology.

Substantial studies have documented an oncogenic effect of Eph-A2 even in the absence of related ligands, which may elicit malignant transformation and metastatic potential in normal cells [12,47]. According to Ruoslahti et al, Eph-A2 overexpression appears to alter extracellular matrix adhesions rather than affecting cell proliferation, due to mislocalization and inability of the receptors to bind to their ligands [48]. Moreover, excessive Eph-A2 production was shown to reduce focal-adhesion kinase (FAK) phosphorylation, thus inhibiting integrin-mediated cell adhesion and enhancing cell motility and invasion [9]. However, possible clinical implications of Eph-A2 expression on local progression of malignant thyroid lesions were not generated in the present work. Thyroid capsule disruption, a significant pathological determinant influencing the choice of postoperative treatment of malignant tumors, as well as lymphatic or blood vessel invasion, which negatively influence prognosis, were not significantly correlated to Eph-A2 and Eph-A4 expression. T3 and T4 malignant lesions showed a higher IHC score – moderate to high – for Eph-A2 and Eph-A4, compared to T1 and T2 tumors; however, significant correlations could not be made, possibly due to the small number of locally advanced thyroid cancers. Similarly, the 8 cases with nodal involvement could not be reliably related to Eph-A2 and Eph-A4 expression. With regard to the TNM stage of thyroid cancers of our study, a high proportion of early-stage tumors (i.e., T1 and T2) positively expressed Eph-A2 (72.5% and 69.2%, respectively) with a moderate IHC score. This finding is consistent with available data for Eph-A2 expression in colorectal cancer and has been attributed to high microvessel density in Eph-A2-positive tumor areas [49], thus emphasizing the role of Eph receptors through angiogenesis in earlier stages of tumorigenesis.

Thyroid cancer is 3 times more prevalent in women than in men; however, the role of sex hormones in its pathogenesis has not yet been elucidated. In this context, several studies have documented a possible implication of estrogen receptor (ER)- α and/or - β in thyroid carcinoma growth and progression [50,51]. Notably, dual targeting of Eph-A2 and estrogen receptor (ER) was shown to restore tamoxifen sensitivity in ER/EphA2-positive breast cancer [52]. Eph-A2 overexpression was also associated with aggressive phenotypic features and inversely with ER and progesterone receptor (PR) expression in endometrioid endometrial carcinoma patients, making Eph-A2 a potential therapeutic target, especially in hormone receptor-negative endometrial carcinoma [53]. Further studies could be conducted to evaluate the expression profile of both Eph-A2 and ER in thyroid carcinoma patients and especially in cases where a strong association between ER and thyroid neoplastic transformation has been documented, such as in the case of papillary carcinoma arising in premenopausal women [54].

CONCLUSIONS

Our results suggest that upregulation of Eph-A2 but not Eph-A4 expression may be associated with the malignant

transformation of thyroid neoplasia. On the other hand, correlations of Eph-A2 and Eph-A4 with clinicopathological parameters, which may reinforce their role in tumor invasion and metastasis through modification of adhesive properties of malignant cells, were not found. However, these findings are provisional and need to be further confirmed in cohort studies including a higher proportion of patients with advanced nodal and metastatic disease. Subset analysis of histological subtypes of papillary and follicular carcinoma, with the latter the most difficult for pathologists to diagnose, is also recommended.

REFERENCES:

- Gale NW, Yancopoulos GD: Ephrins and their receptors: a repulsive topic? *Cell Tissue Res*, 1997; 290(2): 227–41
- Pasquale EB: Eph receptor signalling casts a wide net on cell behaviour. *Nat Rev Mol Cell Biol*, 2005; 6(6): 462–75
- Kullander K, Klein R: Mechanisms and functions of Eph and ephrin signalling. *Nat Rev Mol Cell Biol*, 2002; 3(7): 475–86
- Vearing CJ, Lackmann M: Eph receptor signalling: dimerisation just isn't enough. *Growth Factors*, 2005; 23(1): 67–76
- Himanen JP, Saha N, Nikolov DB: Cell-cell signaling via Eph receptors and ephrins. *Curr Opin Cell Biol*, 2007; 19(5): 534–42
- Wang HU, Chen ZF, Anderson DJ: Molecular distinction and angiogenic interaction between embryonic arteries and veins revealed by ephrin-B2 and its receptor Eph-B4. *Cell*, 1998; 93(5): 741–53
- Palmer A, Zimmer M, Erdmann KS et al: EphrinB phosphorylation and reverse signaling: regulation by Src kinases and PTP-BL phosphatase. *Mol Cell*, 2002; 9(4): 725–37
- Carles-Kinch K, Kilpatrick KE, Stewart JC et al: Antibody targeting of the EphA2 tyrosine kinase inhibits malignant cell behavior. *Cancer Res*, 2002; 62(10): 2840–47
- Miao H, Burnett E, Kinch M et al: Activation of EphA2 kinase suppresses integrin function and causes focal-adhesion-kinase dephosphorylation. *Nat Cell Biol*, 2002; 2(2): 62–69
- Hafner C, Schmitz G, Meyer S et al: Differential gene expression of Eph receptors and ephrins in benign human tissues and cancers. *Clin Chem*, 2004; 50(3): 490–99
- Dodelet VC, Pasquale EB: Eph receptors and ephrin ligands: embryogenesis to tumorigenesis. *Oncogene*, 2000; 19(49): 5614–19
- Zelinski DP, Zantek ND, Stewart JC et al: EphA2 overexpression causes tumorigenesis of mammary epithelial cells. *Cancer Res*, 2001; 61(5): 2301–6
- Brannan JM, Sen B, Saigal B et al: EphA2 in the early pathogenesis and progression of non-small cell lung cancer. *Cancer Prev Res (Phila Pa)*, 2009; 2(12): 1039–49
- Feng YX, Zhao JS, Li JJ et al: Liver cancer: EphrinA2 promotes tumorigenicity through Rac1/Akt/NF-kappaB signaling pathway 120. *Hepatology*, 2010; 51(2): 535–44
- Lu C, Shahzad MM, Wang H et al: EphA2 overexpression promotes ovarian cancer growth. *Cancer Biol Ther*, 2008; 7(7): 1098–103
- Nakamura R, Kataoka H, Sato N et al: EPHA2/EFNA1 expression in human gastric cancer. *Cancer Sci*, 2005; 96(1): 42–47
- Walker-Daniels J, Coffman K, Azimi M et al: Overexpression of the EphA2 tyrosine kinase in prostate cancer. *Prostate*, 1999; 41(4): 275–80
- Wykosky J, Debinski W: The EphA2 receptor and ephrinA1 ligand in solid tumors: function and therapeutic targeting. *Mol Cancer Res*, 2008; 6(12): 1795–806
- Kinch MS, Moore MB, Harpole DH Jr: Predictive value of the EphA2 receptor tyrosine kinase in lung cancer recurrence and survival. *Clin Cancer Res*, 2003; 9(2): 613–18
- Meade-Tollin L, Martinez JD: Loss of p53 and overexpression of EphA2 predict poor prognosis for ovarian cancer patients. *Cancer Biol Ther*, 2007; 6(2): 288–89
- Thaker PH, Deavers M, Celestino J et al: EphA2 expression is associated with aggressive features in ovarian carcinoma. *Clin Cancer Res*, 2004; 10(15): 5145–50
- Yuan W, Chen Z, Wu S et al: Expression of EphA2 and E-cadherin in gastric cancer: correlated with tumor progression and lymphogenous metastasis. *Pathol Oncol Res*, 2009; 15(3): 473–78

23. Garg M, Kanojia D, Suri S et al: Sperm-associated antigen 9: a novel diagnostic marker for thyroid cancer. *J Clin Endocrinol Metab*, 2009; 94(11): 4613-18
24. Solini A, Cuccato S, Ferrari D et al: Increased P2X7 receptor expression and function in thyroid papillary cancer: a new potential marker of the disease? *Endocrinology*, 2008; 149(1): 389-96
25. Wiseman SM, Melck A, Masoudi H et al: Molecular phenotyping of thyroid tumors identifies a marker panel for differentiated thyroid cancer diagnosis. *Ann Surg Oncol*, 2008; 15(10): 2811-26
26. Kebebew E, Weng J, Bauer J et al: The prevalence and prognostic value of BRAF mutation in thyroid cancer. *Ann Surg*, 2007; 246(3): 466-70; discussion 470-71
27. Siironen P, Louhimo J, Nordling S et al: Prognostic factors in papillary thyroid cancer: an evaluation of 601 consecutive patients. *Tumour Biol*, 2005; 26(2): 57-64
28. Wreesmann VB, Siczka EM, Socci ND et al: Genome-wide profiling of papillary thyroid cancer identifies MUC1 as an independent prognostic marker. *Cancer Res*, 2004; 64(11): 3780-89
29. Krawczyk-Rusiecka K, Lewinski A: Cyclooxygenase-2 expression and its association with thyroid lesions. *Arch Med Sci*, 2010; 6(5): 653-57
30. Edge SB, Byrd DR, Compton CC et al. (eds.): *AJCC cancer staging manual* (7th ed). New York, NY, Springer, 2010
31. Giaginis C, Tsourouflis G, Zizi-Serbetzoglou A et al: Clinical Significance of Ephrin (Eph)-A1, -A2, -A4, -A5 and -A7 Receptors in Pancreatic Ductal Adenocarcinoma. *Pathol Oncol Res*, 2010; 16(2): 267-76
32. Giaginis C, Davides D, Zarros A et al: Clinical significance of tumor-associated antigen RCAS1 expression in human pancreatic ductal adenocarcinoma. *Dig Dis Sci*, 2008; 53(6): 1728-34
33. Giaginis CT, Vgenopoulou S, Tsourouflis GS et al: Expression and clinical significance of focal adhesion kinase in the two distinct histological types, intestinal and diffuse, of human gastric adenocarcinoma. *Pathol Oncol Res*, 2009; 15(2): 173-81
34. Cho Mar K, Eimoto T, Tateyama H et al: Expression of matrix metalloproteinases in benign and malignant follicular thyroid lesions. *Histopathology*, 2006; 48(3): 286-94
35. Melck A, Masoudi H, Griffith OL et al: Cell cycle regulators show diagnostic and prognostic utility for differentiated thyroid cancer. *Ann Surg Oncol*, 2007; 14(12): 3403-11
36. Wiseman SM, Griffith OL, Melck A et al: Evaluation of type 1 growth factor receptor family expression in benign and malignant thyroid lesions. *Am J Surg*, 195(5): 667-73; discussion 673
37. Giaginis C, Zarros A, Alexandrou P et al: Evaluation of coxsackievirus and adenovirus receptor expression in human benign and malignant thyroid lesions. *APMIS*, 2010; 118(3): 210-21
38. Surawska H, Ma PC, Salgia R: The role of ephrins and Eph receptors in cancer. *Cytokine Growth Factor Rev*, 2004; 15(6): 419-33
39. Nakamoto M, Bergemann AD: Diverse roles for the Eph family of receptor tyrosine kinases in carcinogenesis. *Microsc Res Tech*, 2002; 59(1): 58-67
40. Ogawa K, Pasqualini R, Lindberg RA et al: The ephrin-A1 ligand and its receptor, EphA2, are expressed during tumor neovascularization. *Oncogene*, 2000; 19(52): 6043-52
41. Walker-Daniels J, Hess AR, Hendrix MJ et al: Differential regulation of EphA2 in normal and malignant cells. *Am J Pathol*, 2003; 162(4): 1037-42
42. Brantley-Sieders DM, Caughron J, Hicks D et al: EphA2 receptor tyrosine kinase regulates endothelial cell migration and vascular assembly through phosphoinositide 3-kinase-mediated Rac1 GTPase activation. *J Cell Sci*, 2004; 117(Pt 10): 2037-49
43. Fang WB, Brantley-Sieders DM, Parker MA et al: A kinase-dependent role for EphA2 receptor in promoting tumor growth and metastasis. *Oncogene*, 2005; 24(53): 7859-68
44. Huynh-Do U, Stein E, Lane AA et al: Surface densities of ephrin-B1 determine EphB1-coupled activation of cell attachment through alpha5beta3 and alpha5beta1 integrins. *EMBO J*, 1999; 18(8): 2165-73
45. Mudali SV, Fu B, Lakkur SS et al: Patterns of EphA2 protein expression in primary and metastatic pancreatic carcinoma and correlation with genetic status. *Clin Exp Metastasis*, 2006; 23(7-8): 357-65
46. Hess AR, Sefror EA, Gardner LM et al: Molecular regulation of tumor cell vasculogenic mimicry by tyrosine phosphorylation: role of epithelial cell kinase (Eck/EphA2). *Cancer Res*, 2001; 61(8): 3250-55
47. Duxbury MS, Ito H, Zinner MJ et al: Ligation of EphA2 by Ephrin A1-Fc inhibits pancreatic adenocarcinoma cellular invasiveness. *Biochem Biophys Res Commun*, 320(4): 1096-102
48. Ruoslahti E: Fibronectin and its integrin receptors in cancer. *Adv Cancer Res*, 1999; 76: 1-20
49. Kataoka H, Igarashi H, Kanamori M et al: Correlation of EPHA2 overexpression with high microvessel count in human primary colorectal cancer. *Cancer Sci*, 2004; 95(2): 136-41
50. Vaiman M, Olevson Y, Habler L et al: Diagnostic value of estrogen receptors in thyroid lesions. *Med Sci Monit*, 2010; 16(7): BR203-7
51. Cho MA, Lee MK, Nam KH et al: Expression and role of estrogen receptor alpha and beta in medullary thyroid carcinoma: different roles in cancer growth and apoptosis. *J Endocrinol*, 2007; 195(2): 255-63
52. Gökmen-Polar Y, Toroni RA, Hocevar BA et al: Dual targeting of EphA2 and ER restores tamoxifen sensitivity in ER/EphA2-positive breast cancer. *Breast Cancer Res Treat* DOI: 10.1007/s10549-010-1004-y
53. Kamat AA, Coffey D, Merritt WM et al: EphA2 overexpression is associated with lack of hormone receptor expression and poor outcome in endometrial cancer. *Cancer*, 2009; 115(12): 2684-92
54. Kawabata W, Suzuki T, Moriya T et al: Estrogen receptors (alpha and beta) and 17beta-hydroxysteroid dehydrogenase type 1 and 2 in thyroid disorders: possible *in situ* estrogen synthesis and actions. *Mod Pathol*, 2003; 16(5): 437-44