



ELSEVIER

Available online at [www.sciencedirect.com](http://www.sciencedirect.com)

ScienceDirect

journal homepage: <http://Elsevier.com/locate/radcr>

## Case Report

# Radiologic presentation of a myofibroblastoma of the adult male breast

Evan Rochlis MD<sup>a,\*</sup>, Pauline Germaine DO<sup>b</sup>

<sup>a</sup> Cooper University Hospital, 1 Cooper Plaza, Camden, NJ 08103, USA

<sup>b</sup> Cooper University Hospital, Camden, NJ, USA

## ARTICLE INFO

## Article history:

Received 13 March 2017

Received in revised form

25 April 2017

Accepted 29 April 2017

Available online 8 June 2017

## Keywords:

Myofibroblastoma

Mammography

Male breast mass

Benign breast lesion

Breast radiology

Mesenchymal tumor

## ABSTRACT

We present the case of a 50-year-old male with bilateral gynecomastia who was incidentally found to have 0.8-cm subareolar mass on computed tomography. Mammographic and sonographic characteristics of the lesion are described as well as a brief historical review of myofibroblastoma, a rare mesenchymal tumor.

© 2017 the Authors. Published by Elsevier Inc. under copyright license from the University of Washington. This is an open access article under the CC BY-NC-ND license (<http://creativecommons.org/licenses/by-nc-nd/4.0/>).

## Introduction

Myofibroblastomas are rare benign mesenchymal neoplasms composed of stromal fibroblast cells within whorls of collagen. Myofibroblastomas were first described in 1987 as benign breast tumors contained in a pseudocapsule with spindle cells and abundant collagen [1]. These cells show smooth muscle differentiation and stain positive for muscle-specific actin, alpha-smooth muscle actin, and desmin. These tumors are entirely benign and will grow slowly over time if not excised [2]. Myofibroblastomas are most commonly

described in the middle-aged male breast, with multiple cases reported in postmenopausal women. There is 1 case report of a breast myofibroblastoma in a 10-month-old male [3]. Though myofibroblastomas are most commonly found in the breast, tumors have been reported in many locations including the liver [4], inguinal canal, posterior vaginal wall, buttock, anterior abdominal wall, mid back [5], and in the scrotum [6,7]. Some have theorized that these tumors arise from ectopic breast tissue along the embryonic milk lines; however, tumors occurring in regions outside the milk line such as buttock or liver contradict this theory [5].

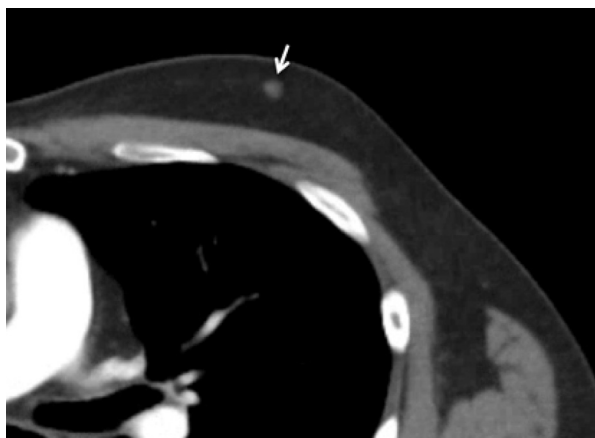
Competing Interests: The authors have declared that no competing interests exist.

\* Corresponding author.

E-mail address: [rochlise0@rowan.edu](mailto:rochlise0@rowan.edu) (E. Rochlis).

<http://dx.doi.org/10.1016/j.radcr.2017.04.025>

1930-0433/© 2017 the Authors. Published by Elsevier Inc. under copyright license from the University of Washington. This is an open access article under the CC BY-NC-ND license (<http://creativecommons.org/licenses/by-nc-nd/4.0/>).



**Fig. 1 – Contrast-enhanced CT scan of the chest shows a small, circumscribed, soft-tissue density mass in the left breast. CT, computed tomography.**

## Case

A 50-year-old male with a past history of bilateral gynecomastia and sarcoidosis maintained on low-dose corticosteroids for 2 decades presented to the Emergency Department with a chief complaint of hemoptysis. The hemoptysis resolved spontaneously without an identifiable cause. Computed tomography (CT) chest with intravenous contrast was performed to evaluate patient symptoms and revealed an incidental 0.6-cm soft-tissue density mass in the left breast (Fig. 1). Upon further questioning, the patient reported a year

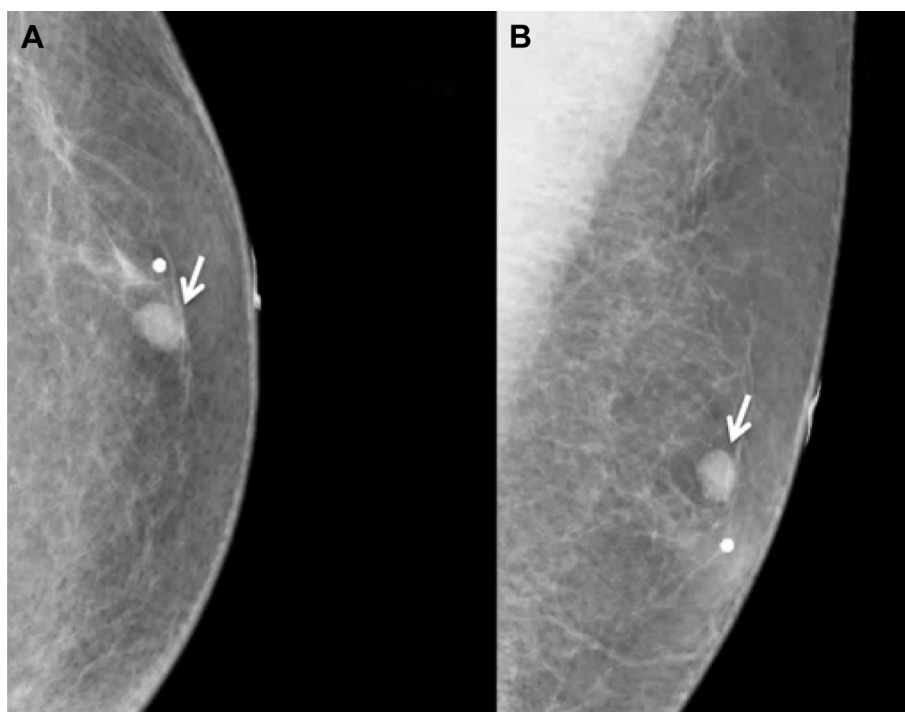
long history of a palpable tender mass in the left breast. The patient was referred to breast clinic for further evaluation of this finding.

## Imaging and diagnosis

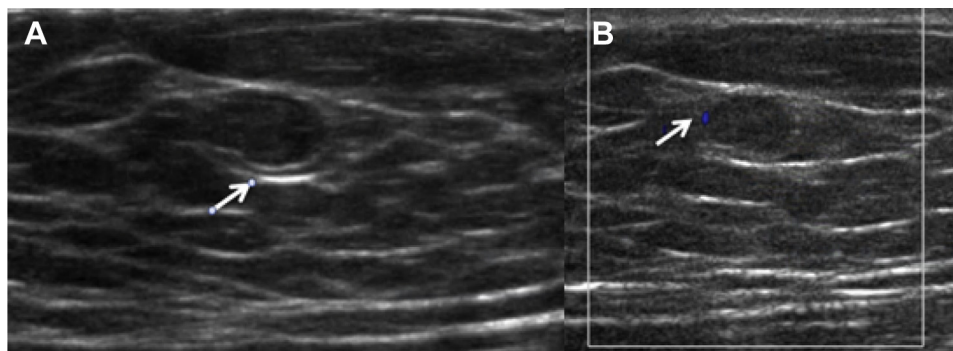
Mammogram confirmed the presence of a circumscribed subareolar mass corresponding to a palpable mass and CT finding (Figs 2A and B). No associated calcifications or architectural distortion were seen. Ultrasound confirmed the presence of circumscribed, nearly isoechoic 0.8-cm mass with minimal internal vascularity on color Doppler assessment without posterior shadowing (Figs 3A and B). There was no axillary lymphadenopathy. An ultrasound-guided core-needle biopsy of the mass was performed, showing immunohistochemical stains positive for vimentin, CD34, CD99, bcl-2, and desmin and negative for AE1/3 consistent with a myofibroblastoma. Surgical resection followed with final pathology confirming a mammary myofibroblastoma composed of bland-appearing, plump spindle cells in vague fascicular groups with interspersed hyalinized collagen bundles.

## Discussion

Myofibroblastomas have been characterized in multiple case reports with a variety of radiographic findings. Typical masses measure 1-4 cm [1,8], with rare cases demonstrating much larger lesions up to 16 cm [9,10]. This case demonstrates a small myofibroblastoma, possibly due to the



**Fig. 2 – Craniocaudal (A) and mediolateral oblique (B) views of the left breast confirmed a round, circumscribed hyperdense mass in the subareolar left breast. The arrows denotes the location of the mass.**



**Fig. 3 – Ultrasound images show a round, circumscribed nearly isoechoic nodule, corresponding to the mammography and CT findings (A). The Doppler image (B) shows a focus of vascular flow (arrow) within the nodule. CT, computed tomography.**

workup being triggered by incidental discovery on CT rather than the patient presenting with a larger mass. Mammography characterizes masses as round to oval shaped. They may demonstrate microlobulated margins and are without calcifications or other suspicious features [11–14], similar to the findings in the presented case. Sonographic findings vary from homogeneously hypoechoic to heterogeneous mass with or without posterior shadowing [8,12,14–16]. Doppler may demonstrate variable internal vascularity [9,13]. Sonography in this case demonstrated a homogeneous nearly isoechoic mass with minimal vascularity on Doppler. CT is less often performed but typically shows a circumscribed mass, with 1 case report showing low-density attenuation due to the presence of fat [4]. MRI findings show T1 hypointensity to isointensity with positive early enhancement and nonenhancing septations. The masses are typically T2 hyperintense [4,9,11,13]. Myofibroblastoma is benign with no known cases of lymph node or distant metastasis. The differential diagnosis for a breast mass in a male includes breast cancer, gynecomastia, subareolar abscess, fat necrosis, epidermoid cyst, lipoma, and malignant melanoma [17].

The benign appearance of male myofibroblastoma must be contrasted to the appearance of breast cancer in men, the most severe diagnosis on the differential list for a male breast mass. Mammographic appearance of male breast cancer typically parallels that of a female breast cancer showing an irregular mass with spiculated margins with or without microcalcifications or rarely microcalcifications alone. The lesion size can vary, with a mean size of 2.2 cm ranging as high as 19 cm, with increasing size indicating more advanced disease. Sonographic appearance of male breast carcinoma is most frequently a solid mass with irregular margins and variable vascularity on color Doppler evaluation. Axillary lymphadenopathy occurs in a minority of patients [18]. Although mammographic and sonographic features of myofibroblastoma are not pathognomonic, they are significantly different from the typical appearance of breast cancer and should be considered in the differential list of benign though uncommon masses in the male breast.

## Conclusion

The case of a 50-year-old male with a small myofibroblastoma is presented, with imaging findings demonstrating typical appearance on CT, mammography, and ultrasound. Myofibroblastomas represent a rare benign mesenchymal neoplasm that may be encountered in male patients presenting for evaluation of palpable abnormalities in the breast.

## REFERENCES

- [1] Weiss S, Norris H, Wargotz E. Myofibroblastoma of the breast: sixteen cases of a benign mesenchymal tumor. *Am J Surg Pathol* 1987;11(7):493–502.
- [2] Schickman R, Leibman AJ, Handa P, Kornmehl A, Abadi M. Mesenchymal breast lesions. *Clin Radiol* 2015;70:565–75.
- [3] Soyer T, Ayva S, Senyuçel MF, Senyuçel C, Aslan MK, Cakmak M. Myofibroblastoma of breast in a male infant. *Fetal Pediatr Pathol* 2012;31:164–8.
- [4] Yee EU, Morteale KJ, Millo N. Mammary-type myofibroblastoma of the liver: multi-modality imaging features with histopathologic correlation. *Abdom Imaging* 2014;39:482–7.
- [5] Magro G. Mammary myofibroblastoma a tumor with a wide morphologic spectrum. *Arch Pathol Lab Med* 2008;132:1813–20.
- [6] An S, Song JS, Park S, Lee JW, Cho KJ. Mammary-Type myofibroblastoma: a report of two cases. *J Pathol Transl Med* 2016;50:385–9.
- [7] Mukonoweshuro P, McCormick F, Rachapalli V, Natale S, Smith ME. Paratesticular mammary-type myofibroblastoma. *Histopathology* 2007;50:396–7.
- [8] Bisceglia M, Michal M, Magro VEG. Spindle cell lipoma-like tumor, solitary fibrous tumor and myofibroblastoma of the breast: a clinico-pathological analysis of 13 cases in favor of a unifying histogenetic concept. *Virchows Arch* 2002;440:249–60.
- [9] Omar LA, Rojanapremsuk T, Saluja K, Merchant KA, Sharma PB. Radiologic and histologic presentation of male mammary myofibroblastoma. *Proc (Bayl Univ Med Cent)* 2016;29(3):321–2.

- 
- [10] Kataria K, Srivastava A, Singh L, Suri V, Yadav R. Giant myofibroblastoma of the male breast: a case report and literature review. *Malays J Med Sci* 2012;19(3):74–6.
- [11] Vourtsi A, Kehagias D, Antoniou A, Mouloupoulos LA, Deligeorgi-Politi H, Vlahos L. Male breast myofibroblastoma and MR findings. *J Comput Assist Tomogr* 1999;23(3):414–6.
- [12] Kaplan SS, Grady C, Greenberg JS. Myofibroblastoma of the breast in women: imaging appearances. *Am J Roentgenol* 1998;171:71–2.
- [13] Yoo EY, Shin JH, Ko EY, Han BK, Oh YL. Myofibroblastoma of the female breast. *J Ultrasound Med* 2010;29:1833–6.
- [14] Singh HR, Wilentz RE, Dockery WD. Myofibroblastoma of the male breast: imaging appearance and ultrasound-guided core biopsy diagnosis. *Breast J* 2001;7(3):192–4.
- [15] Pina L, Apesteguía L, Cojo R, Cojo F, Arias-Camisón I, Rezola R, et al. Myofibroblastoma of male breast: report of three cases and review of the literature. *Eur Radiol* 1997;7:931–4.
- [16] Porter GJ, Evans AJ, Lee AH, Hamilton LJ, James JJ, et al. Unusual benign breast lesions. *Clin Radiol* 2006;61:562–9.
- [17] Ng AML, Dissanayake D, Metcalf C, Wylie E. Clinical and imaging features of male breast disease, with pathological correlation: a pictorial essay. *J Med Imaging Radiat Oncol* 2014;58:189–98.
- [18] Mathew J, Perkins GH, Stephens T, Middleton LP, Yang WT. Primary breast cancer in men: clinical, imaging, and pathologic findings in 57 patients. *AJR Am J Roentgenol* 2008;191(6):1631–9.