



OPEN ACCESS

# Effective treatment of hypertrophic cardiomyopathy with left ventricular outflow tract obstruction using a covered stent

Devon Pekas,<sup>1</sup> Adya Chawda,<sup>2</sup> Nayan Desai<sup>2</sup>

<sup>1</sup>School of Medicine and Health Sciences, University of North Dakota, Grand Forks, North Dakota, USA

<sup>2</sup>Interventional Cardiology, Sanford Health Bismarck, Bismarck, North Dakota, USA

## Correspondence to

Devon Pekas;  
devon.pekas@und.edu

Accepted 25 November 2022

## SUMMARY

A woman in her 60s presented with progressive exertional dyspnoea, exertional chest pressure and exertional dizziness. Echocardiogram identified a 156 mm Hg left ventricular outflow tract gradient with provocation, indicating hypertrophic cardiomyopathy with left ventricular outflow obstruction—confirmed with MRI and angiogram. An alcohol septal ablation was planned but due to communication of the second septal perforator with the right ventricle and a wire-induced mid-left anterior descending artery dissection, alcohol septal ablation was not performed. Instead, a covered stent was placed in the mid-left anterior descending artery covering the origins of the third and fourth septal perforators. The left ventricular outflow tract gradient decreased from 90 to 30 mm Hg with provocation and her symptoms improved. Follow-up showed a left ventricular outflow tract gradient of 35 mm Hg with provocation and decreased symptoms.

## BACKGROUND

Hypertrophic cardiomyopathy is a common cardiovascular disorder which is found globally and can affect either sex, various races/ethnicities and all ages.<sup>1</sup> Hypertrophic cardiomyopathy commonly results in atrial fibrillation, arrhythmic sudden death and heart failure.<sup>1</sup> It is mainly characterised by asymmetric left ventricular hypertrophy with subaortic obstruction due to mitral valve systolic anterior motion with septal contact which leads to the disruption of laminar flow through the left ventricular outflow tract.<sup>2</sup> This obstruction leads to left ventricle systolic pressure overload with secondary mitral regurgitation and preserved/increased left ventricle function.

The diagnosis is made clinically with echocardiographic or MRI displaying a hypertrophied, non-dilated left ventricle in the absence of secondary causes.<sup>3</sup> Mild-to-severe functional impairment seen in many hypertrophic cardiomyopathy patients manifests with exertional dyspnoea and fatigue.<sup>2</sup> There are medical, surgical (myectomy, cardioverter-defibrillators and transplantation) and percutaneous (alcohol septal ablation) interventions available. Pharmacological therapy (beta blockers and calcium channel blockers) is first line as they improve obstructive symptoms by decreasing the heart rate and prolonging diastolic fill time, elevating their quality of life.<sup>4</sup> Septal myectomy and alcohol septal ablation are available for severe cases with the goal of decreasing the left ventricular

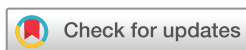outflow tract obstruction gradient and restoring proper flow.<sup>4–6</sup> There have also been a small number of cases using covered stents to occlude septal perforators—due to collateralisation, there has been mixed long-term results.<sup>7–10</sup>

## CASE PRESENTATION

A woman in her 60s was evaluated following an abnormal echocardiogram, indicating hypertrophic cardiomyopathy with left ventricular outflow tract obstruction. Symptoms were progressively worsening for 6–18 months and included severe exertional dyspnoea, exertional chest pressure, exertional dizziness and resting dizziness, which worsened while dehydrated. History of cerebrovascular accident, hypertension and hyperlipidaemia. No family cardiac history including no sudden death. Brief smoking history 35 years ago. Medication included 100 mg/day metoprolol. Physical examination showed a body mass index (BMI) of 34.39 kg/m<sup>2</sup> BMI and a 2/6 aortic area systolic murmur, which increased to 3/6 with Valsalva and standing.

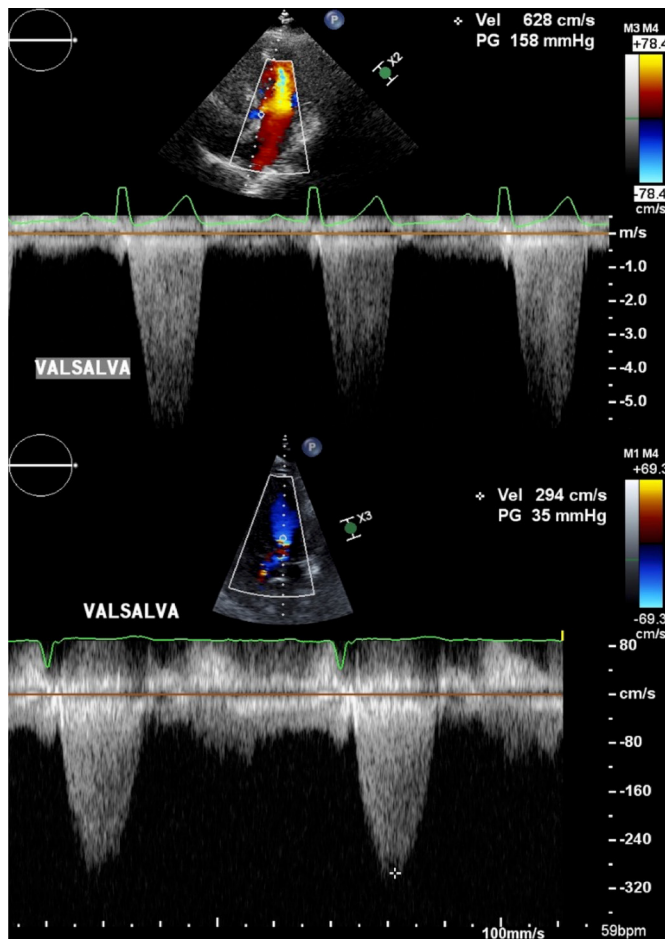
The original echocardiogram (figure 1) showed ejection fraction of 70%–75%, hypertrophic cardiomyopathy with dynamic subaortic stenosis and left ventricular outflow tract obstruction (156 mm Hg gradient with provocation) and moderate-to-severe mitral regurgitation. Cardiac MRI (figure 2) displayed a severe ostial tract obstruction (130 mm Hg gradient with provocation) and moderate-to-severe mitral regurgitation with systolic anterior motion. Myectomy or alcohol septal ablation were offered. Investigatory coronary angiogram found mild-to-moderate non-obstructive coronary artery disease involving the right coronary artery and a significant subaortic outflow tract gradient of >100 mm Hg with spike and dome pattern—alcohol septal ablation was planned.

Right ulnar access was obtained for pigtail catheter to measure left ventricle pressure and right femoral access was obtained for intervention. A 0.14 coronary wire was placed into the second septal perforator. A 2.0 balloon occluded the second septal perforator's origin and dye was injected distally. There was no extravasation or backflow in the left anterior descending; however, dye was seen within the right ventricle—confirmed echocardiographically with the presence of Definity contrast agent in the right ventricle (figure 3). Wiring of the third and fourth septal perforators was then attempted. During which, a flow-limiting dissection



© BMJ Publishing Group Limited 2022. Re-use permitted under CC BY-NC. No commercial re-use. See rights and permissions. Published by BMJ.

**To cite:** Pekas D, Chawda A, Desai N. *BMJ Case Rep* 2022;**15**:e250929. doi:10.1136/bcr-2022-250929



**Figure 1** Echocardiograms pre-stent placement (top) and post-stent placement (bottom). Take note of the y-axis unit change.

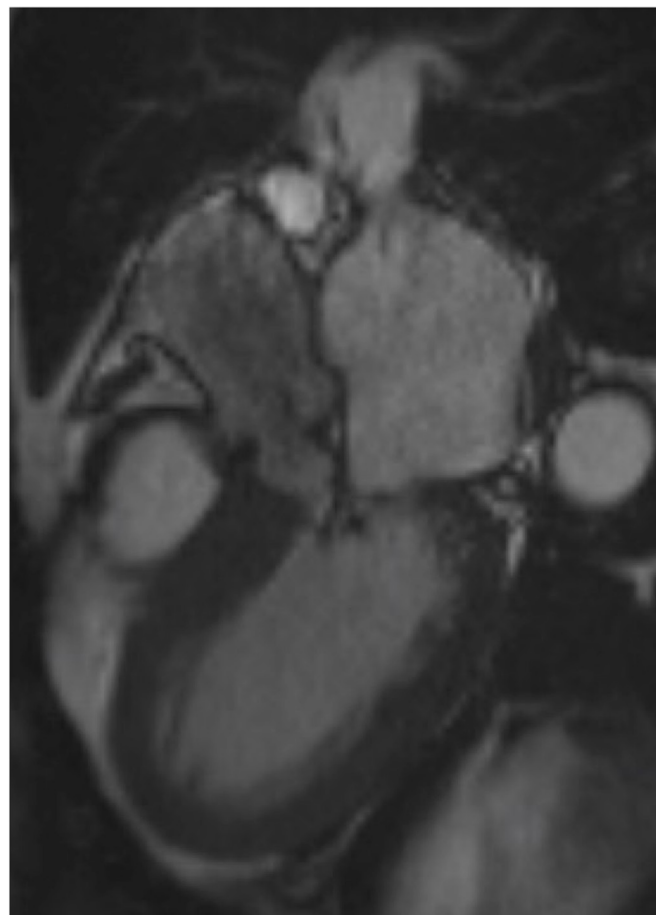
of the mid-left anterior descending was identified. Due to these procedural findings, the alcohol septal ablation was not performed. Instead, a Papyrus  $3.5 \times 20$  mm covered stent was placed at the origins of the third and fourth septal perforators overlapping distally with a Xience  $2.75 \times 12$  mm drug-eluted stent (figure 4). This resulted in thrombolysis in myocardial Infarction (TIMI) 3 flow and improvement of the left ventricular outflow tract gradient from 90 to 30 mmHg with provocation, measured intraoperatively. On follow-up evaluation, her symptoms had drastically decreased and an echocardiogram showed a significantly improved left ventricular outflow tract gradient of 35–49 mmHg with provocation (original echocardiogram showed 156–158 mmHg; figure 1). Her decreased symptoms are stable 2 months postprocedure.

#### FOLLOW-UP

One day postoperation, the left ventricular outflow tract gradient was 35 mmHg and their symptoms were significantly decreased. Two months postoperation, their symptoms remained decreased.

#### DISCUSSION

The present case used a covered stent since the original plan of alcohol septal ablation was abandoned due to mid-left anterior descending dissection and communication of the second septal perforator with the right ventricle. Stent placement over the origins of the third and fourth septal perforators resulted in a significantly decreased left ventricular outflow tract obstruction

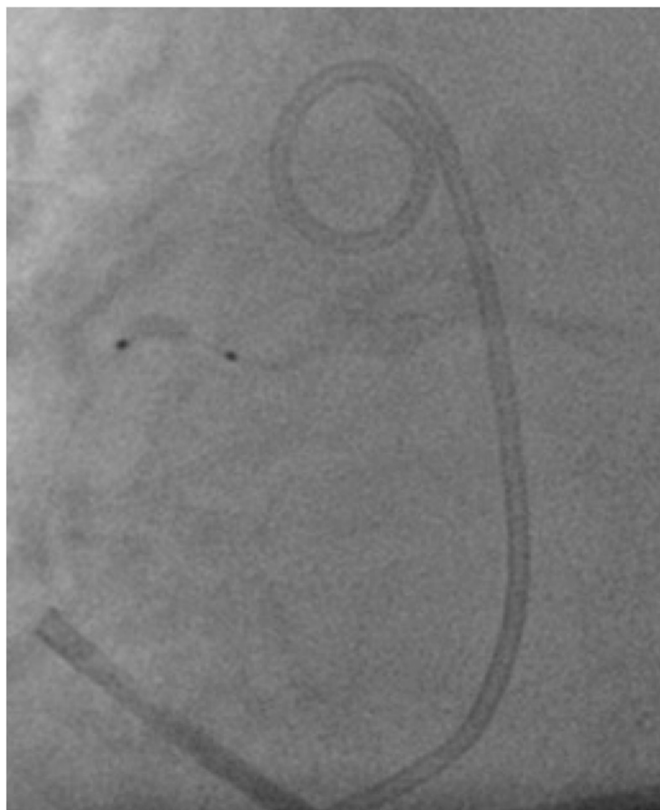

**Figure 2** Cardiac MRI showing a hypertrophic basal interventricular septum and systolic anterior motion of the mitral valve.

gradient as well as improved symptoms. While this is an atypical approach, it has been used previously.<sup>7–10</sup>

The first successful case of treating hypertrophic cardiomyopathy with a covered stent was published in 1999. A covered stent was used to cover the origins of three septal perforators since balloon occlusion of each perforator individually only led to a partial gradient decrease. The intervention led to a ‘complete reduction’ in the gradient and after 4 months, the patient remained asymptomatic.<sup>10</sup> In 2003, an alcohol septal ablation was unable to be performed due to the branch angle of the first septal perforator so a stent was placed occluding the origin. This resulted in 6 asymptomatic months with a decreased gradient (21 mmHg) before collateralisation from the right coronary artery resulted in recurrence of symptoms and gradient (97 mmHg); myectomy was then performed.<sup>7</sup> In 2004, a covered stent was used due to the inability to cannulate the first septal artery; collateralisation from the right coronary artery led to symptom recurrence after an undisclosed period of time.<sup>8</sup> Finally, in 2006, a woman with coronary artery disease and an alcohol septal ablation 6 months prior had a covered stent placed after symptom recurrence due to 70% stenosis of the left anterior descending and D1. Twelve months after placement, her gradient remained low and she was asymptomatic.<sup>9</sup> These cases display the varying reasons for covered stent placement to treat hypertrophic cardiomyopathy along with their results over a relatively short follow-up period.

Our patient remains improved 2 months postprocedure, which is consistent with previous cases. However, two of the four previous cases ultimately resulted in symptom recurrence

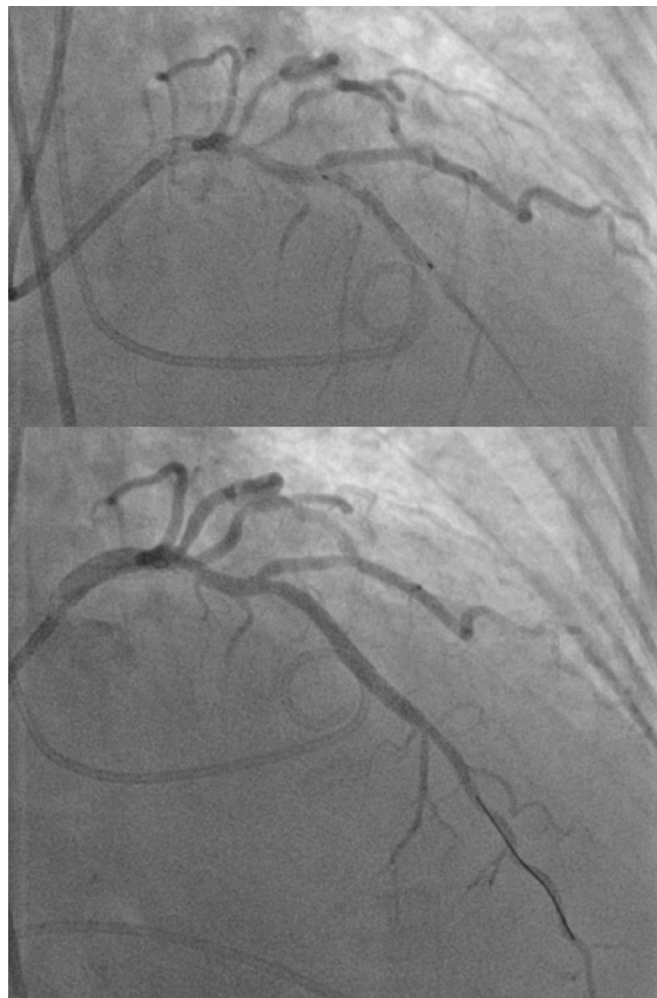


**Figure 3** Cardiac Catheterization image and simultaneous echocardiogram showing Definity contrast agent in the right ventricle when injected into the second septal perforator. Pig tail in left ventricle. A 2.25 × 12 balloon occluding the second septal perforator.

due to collateralisation and the two that did not either had a previous alcohol septal ablation performed or was only 4 months postprocedure. With that said, since alcohol septal ablation was contraindicated due to the risk of leaking through the dissection or ablating a portion of the right ventricle through the communication, the covered stent was a satisfactory backup for this unique patient. Additionally, with the limited data available, it seems that treating hypertrophic cardiomyopathy by occluding the origins of septal perforators with a covered stent provides short-term symptom relief and a reduced gradient. Nevertheless, long-term results are uncertain at this point and more data is needed to draw further conclusions.

### Learning points

- ▶ To understand how using a covered stent to treat hypertrophic cardiomyopathy with left ventricular outflow tract obstruction can be considered in cases where alcohol septal ablation is either difficult or contraindicated.
- ▶ To recognise that while this case shows short-term efficacy, long-term conclusions should not be drawn due to varying results with previous case reports and no long-term follow-up.
- ▶ To acknowledge that more scientific data must validate this approach before it is routinely considered concomitantly with alcohol septal ablation or myectomy.



**Figure 4** Cardiac catheterization. (Top) Left anterior descending artery with septal perforators present placement. (Bottom) Left anterior descending artery with septal perforators poststent placement—no flow in third or fourth septal perforators.

**Contributors** DP wrote the manuscript, participated in the editing and proofreading of the manuscript and participated in the collection of data. AC participated in the writing, editing and proofreading of the manuscript. ND performed the procedure, participated in the collection/interpretation of data and participated in manuscript editing and proofreading.

**Funding** The authors have not declared a specific grant for this research from any funding agency in the public, commercial or not-for-profit sectors.

**Competing interests** None declared.

**Patient consent for publication** Consent obtained directly from patient(s).

**Provenance and peer review** Not commissioned; externally peer reviewed.

**Open access** This is an open access article distributed in accordance with the Creative Commons Attribution Non Commercial (CC BY-NC 4.0) license, which permits others to distribute, remix, adapt, build upon this work non-commercially, and license their derivative works on different terms, provided the original work is properly cited and the use is non-commercial. See: <http://creativecommons.org/licenses/by-nc/4.0/>.

Case reports provide a valuable learning resource for the scientific community and can indicate areas of interest for future research. They should not be used in isolation to guide treatment choices or public health policy.

### REFERENCES

- 1 Maron BJ. Hypertrophic cardiomyopathy: a systematic review. *JAMA* 2002;287:1308–20.

- 2 Maron BJ, Rowin EJ, Udelson JE, *et al.* Clinical Spectrum and Management of Heart Failure in Hypertrophic Cardiomyopathy. *JACC Heart Fail* 2018;6:353–63.
- 3 Maron BJ, Maron MS. The Remarkable 50 Years of Imaging in HCM and How it Has Changed Diagnosis and Management: From M-Mode Echocardiography to CMR. *JACC Cardiovasc Imaging* 2016;9:858–72.
- 4 Maron BJ. Clinical course and management of hypertrophic cardiomyopathy. *N Engl J Med Overseas Ed* 2018;379:655–68.
- 5 Bytçı I, Nistri S, Mörrer S, *et al.* Alcohol septal ablation versus septal myectomy treatment of obstructive hypertrophic cardiomyopathy: a systematic review and meta-analysis. *J Clin Med* 2020;9. doi:10.3390/jcm9103062. [Epub ahead of print: 23 09 2020].
- 6 Osman M, Kheiri B, Osman K, *et al.* Alcohol septal ablation vs myectomy for symptomatic hypertrophic obstructive cardiomyopathy: systematic review and meta-analysis. *Clin Cardiol* 2019;42:190–7.
- 7 Fifer MA, Yoerger DM, Picard MH, *et al.* Images in cardiovascular medicine. covered stent septal ablation for hypertrophic obstructive cardiomyopathy: initial success but ultimate failure resulting from collateral formation. *Circulation* 2003;107:3248–9.
- 8 Anzuini A, Uretsky BF. Covered stent septal ablation for hypertrophic obstruction cardiomyopathy. *Circulation* 2004;109:e6.
- 9 Sianos G, Papafaklis MI, Vourvouri EC, *et al.* Images in cardiovascular medicine. hypertrophic obstructive cardiomyopathy: septal ablation with overlapping sirolimus-eluting and covered stents after failed alcoholization and concomitant coronary artery disease. *Circulation* 2006;114:e553–5.
- 10 Gaspar J, Martínez-Ríos MA, Vonderwalde C, *et al.* Pericardium-covered stent for septal myocardial ablation in hypertrophic obstructive cardiomyopathy. *Catheter Cardiovasc Interv* 1999;47:73–9.

Copyright 2022 BMJ Publishing Group. All rights reserved. For permission to reuse any of this content visit <https://www.bmj.com/company/products-services/rights-and-licensing/permissions/>  
BMJ Case Report Fellows may re-use this article for personal use and teaching without any further permission.

Become a Fellow of BMJ Case Reports today and you can:

- ▶ Submit as many cases as you like
- ▶ Enjoy fast sympathetic peer review and rapid publication of accepted articles
- ▶ Access all the published articles
- ▶ Re-use any of the published material for personal use and teaching without further permission

### Customer Service

If you have any further queries about your subscription, please contact our customer services team on +44 (0) 207111 1105 or via email at [support@bmj.com](mailto:support@bmj.com).

Visit [casereports.bmj.com](http://casereports.bmj.com) for more articles like this and to become a Fellow