



Case report

Liner dissociation leading to catastrophic failure of an Oxinium femoral head

Anthony H. Zou, BA^a, David Novikov, BS^a, James E. Feng, MD^a,
Afshin A. Anoushiravani, MD^{a, b}, Ran Schwarzkopf, MD, MSc^a,
Jonathan M. Vigdorichik, MD^{a, *}

^a Division of Adult Reconstructive Surgery, NYU Langone Orthopedics, NYU Langone Health, New York, NY, USA

^b Department of Orthopaedics, Albany Medical Center, Albany, NY, USA

ARTICLE INFO

Article history:

Received 1 May 2018

Received in revised form

10 September 2018

Accepted 25 September 2018

Available online 28 November 2018

Keywords:

Liner dissociation

Dual-mobility system

Oxinium

Oxidized zirconium

Total hip arthroplasty

Total hip replacement

ABSTRACT

Oxinium is an alternative bearing surface designed to emulate the superior wear and scratch properties of ceramic femoral heads in total hip arthroplasty while minimizing the risk for brittle fracturing. However, recent studies have indicated that hip dislocation following total hip arthroplasty may be a risk factor for catastrophic failure of the femoral head. Here, we report on a novel case of a catastrophic Oxinium head and polyethylene liner failure in the absence of previous hip dislocation or trauma and review the probable failure mechanism. This report underscores the need to be vigilant about proper acetabular cup and liner seating, particularly in the setting of Oxinium femoral head use. In the event of Oxinium head failure, metallosis may compromise stabilizing soft tissues including the abductors. Dual-mobility articulation, which was successful in this case, is one option to consider when the risk for chronic redislocation is elevated.

© 2018 Published by Elsevier Inc. on behalf of The American Association of Hip and Knee Surgeons. This is an open access article under the CC BY-NC-ND license (<http://creativecommons.org/licenses/by-nc-nd/4.0/>).

Introduction

Total hip arthroplasty (THA) has been identified as one of the most impactful surgeries of this century [1]. Health-care economists have reported that the incremental cost-effectiveness ratio is well below the cost-efficiency threshold outlined by the World Health Organization, underscoring the value of THA [2–4]. With an increasingly active population in the United States, THAs among 45- to 54-year-olds have doubled, with the proportion of patients younger than 65 years projected to increase to 50% of all THAs by 2030 [5,6]. This demographic trend has diverted attention towards the development of longer lasting implant materials.

With a higher demand, younger, and more active patient population, various innovations have been developed to reduce the rate

of revision THA. In the 1970s, monolithic ceramic heads were introduced as a superior femoral head bearing surface. They offered exceptional lubrication surface hardness, and abrasive wear resistance properties when compared against their stainless steel counterparts, but were prone to brittle fracturing, resulting in more challenging revision THAs as a result of ceramic debris contamination [7–9].

The increasing prevalence of modular over monobloc designs have allowed for finer correction of leg-length discrepancy and control of hip offset, but at the expense of higher rates of trunnionosis [10,11]. This has led to the dramatic rise in the popularity of galvanic corrosion-resistant head and stem materials, namely ceramic and oxidized zirconium (Oxinium; Smith and Nephew Corporation, Memphis, TN) [12]. Cross-linked high-molecular weight polyethylene has also proven to prolong implant longevity [13]. Coupled with the advent of alumina matrix composite [14,15] (BIOLOX Delta; Ceramtec AG, Plochingen, Germany) in 2000 and Oxinium technology in 2009, a new era of THA technology appeared promising.

Oxinium femoral heads are created by heating zirconium alloy (Zr-2.5% Nb) to 500°C, oxidizing the first 5 μm of the surface from zirconium to zirconium oxide [16]. The combination of a fatigue-resistant substrate underneath an oxidized, ceramicized surface

One or more of the authors of this paper have disclosed potential or pertinent conflicts of interest, which may include receipt of payment, either direct or indirect, institutional support, or association with an entity in the biomedical field which may be perceived to have potential conflict of interest with this work. For full disclosure statements refer to <https://doi.org/10.1016/j.artd.2018.09.009>.

* Corresponding author. Division of Adult Reconstructive Surgery, NYU Langone Orthopedics, NYU Langone Health, 301 E 17th Street, New York, NY 10003, USA. Tel.: +1 212 598 6000.

E-mail address: Jonathan.Vigdorichik@nyumc.org

<https://doi.org/10.1016/j.artd.2018.09.009>

2352-3441/© 2018 Published by Elsevier Inc. on behalf of The American Association of Hip and Knee Surgeons. This is an open access article under the CC BY-NC-ND license (<http://creativecommons.org/licenses/by-nc-nd/4.0/>).

was designed to emulate superior wear and scratch properties of ceramics while minimizing the risk for brittle fracturing [16,17]. This novel design has translated clinically to midterm in vivo studies demonstrating reduced linear and volumetric wear of polyethylene (PE) liners when compared with cobalt-chromium (CoCr), ceramic, and steel femoral heads [18–20].

Although alternative bearings were developed to improve the wear properties of CoCr femoral heads, there have been multiple reports of catastrophic implant failure after dislocation [21–23]. Here, we report on a case of a failed Oxinium head and PE liner in a patient with no known history of hip dislocation or trauma and discuss the probable failure mechanism.

The patient was informed that data and images concerning the case would be submitted for publication, and she provided consent.

Case history

Presentation

A 54-year-old woman underwent a staged bilateral THA at an outside institution in 2009. Although her right hip recovered uneventfully, she continued to experience groin pain and limited range of motion in her left hip. Since 2012, she has had progressively worsening pain and declining functional status, ultimately requiring a walker. Plain anteroposterior pelvic radiographs in 2012 demonstrated diffuse hyperdense findings, osteolysis with femoral head flattening and evident superior migration of the femoral component on radiographic imaging, indicative of a dissociated acetabular liner. Surgical intervention was recommended and risks of postponement were explained. However, as the pain was self-limited, the patient declined surgery.

Over the next 5-years, the patient's pain and condition continued to deteriorate, causing her to present to our clinic in June 2017. At this time, she reported left groin pain radiating down to her leg, which prohibited her from ambulating without a walker and attending activities of daily life such as putting on socks and reciprocating stairs. Plain anteroposterior radiographs were similar to images in 2012, demonstrating diffuse interosseous hyperdensities extending into the soft tissue along the proximal aspect of the thigh, an aspherical femoral head with superior erosion, a dissociated acetabular liner, a loose acetabular cup and a loose femoral component that collapsed into varus (Fig. 1). The patient's infectious and metal ion workups were negative (erythrocyte sedimentation rate: 23 mm/h, C-reactive protein < 5 mg/L, white blood cell count: $3.7 \times 10^3/\mu\text{L}$, plasma Co < 1 ppb, serum Cr < 1 ppb) and fluoroscopic-guided joint aspiration were unremarkable (negative gram stain and no growth in cultures).

Further evaluation with 3D computed tomography was performed to evaluate bone stock and metal ion soft tissue reaction (Fig. 2). Three-dimensional computed tomography showed lateral loss of the normal spherical contour of the femoral head with eccentric positioning within the acetabular cup suggesting a dissociated acetabular liner, varus positioning of the femoral stem, global lucency at the femoral prosthetic/bony interface, and extensive metallosis extending both superiorly and inferiorly from the greater trochanter along the lateral soft tissues of the thigh.

Surgical intervention

The patient underwent revision THA of the left hip using a posterolateral approach in September 2017. After dislocation of the femoral head, the femoral stem was found to be loose and easily removed. Intraoperative findings demonstrated flattening of the femoral head caused by probable dissociation of the liner and erosion of the femoral head on the metallic rim of the acetabular

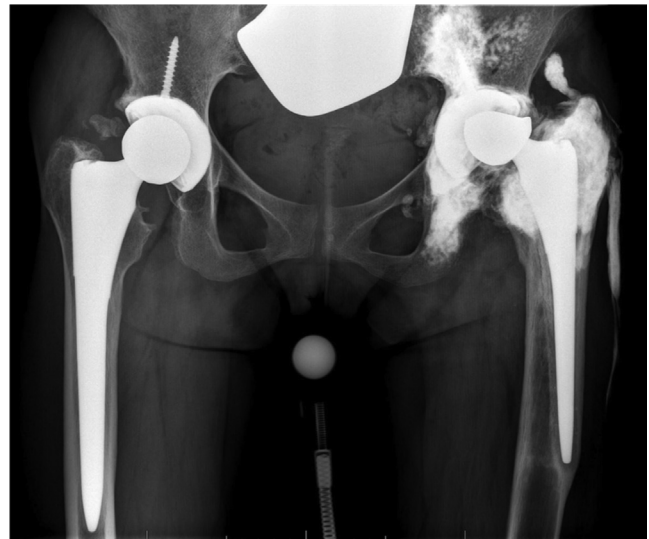

Figure 1. Preoperative anteroposterior radiograph of the hips from June 2017 demonstrating a diffuse sclerotic reaction extending into the soft tissue along the proximal aspect of the thigh, an aspherical femoral head likely due to chronic superior erosion, a loose femoral component in valgus, and a loose acetabular cup.

component (Fig. 3). Joint fluid cultured and synovium was sent for pathologic evaluation which later Demonstrated necrosis and metallosis with no evidence of infection. The acetabular cup was retroverted, loose and effortlessly removed. The abductors were found to be completely avulsed, and there was abundant metallosis requiring meticulous debridement (Fig. 4). A 66-mm fully porous Redapt cup (Smith and Nephew Corporation) was impacted, and 6 acetabular screws were placed. A POLARCUP Dual-Mobility System (Smith and Nephew Corporation, Memphis, TN) 53 mm outer shell was subsequently cemented into the larger 66 mm porous metal REDAPT cup.

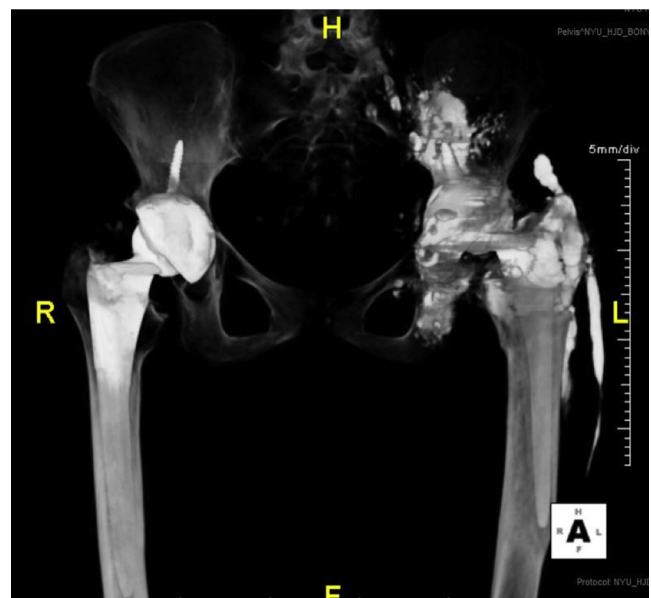


Figure 2. Three-dimensional computed tomography showing lateral loss of the normal spherical contour of the femoral head with eccentric positioning within the acetabular cup, varus positioning of the femoral stem with global lucency at the femoral prosthetic/bony interface, and extensive metallosis extending both superiorly and inferiorly from the greater trochanter along the lateral soft tissues of the thigh.

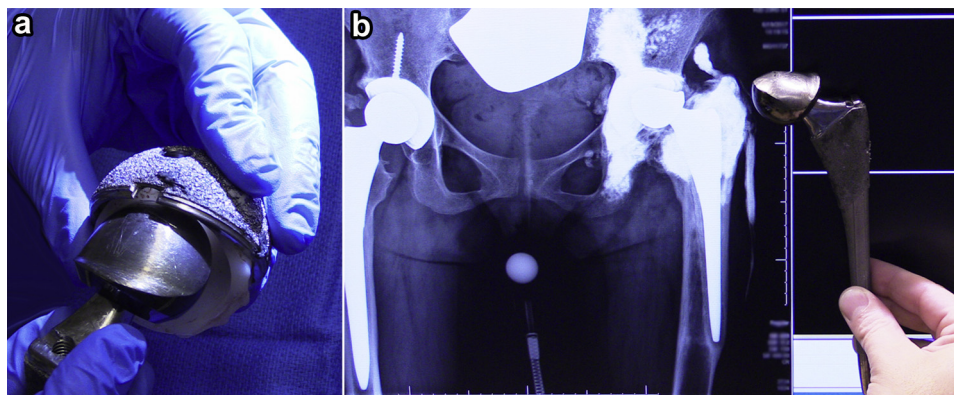


Figure 3. (a) Intraoperative gross image demonstrating flattening of the femoral head caused by probable dissociation of the liner and erosion of the femoral head on the metallic rim of the acetabular component. (b) Intraoperative comparison of retrieved implant alongside the preoperative anteroposterior pelvis radiograph.

Attention was then diverted to the femur where a false cortex was circumnavigated using a Midas Rex MR7 high-speed pneumatic surgical drill (Medtronic, Minneapolis, MN), and the femoral canal was reamed over a guidewire under fluoroscopic guidance. After further irrigation, a size 22 standard offset Redapt stem was impacted. A 28 mm -3 mm offset CoCr head was pressfit into the dual-articulating polyethylene liner of the POLARCUP Dual Mobility system. This construct was assembled onto the femoral stem, and the hip was subsequently reduced. The wound and soft tissues were again copiously irrigated. The posterior soft tissue flap was repaired to the greater trochanter through drill holes. The fascia was closed, and the skin was reapproximated with skin staples.

Postoperative course

The patient's postoperative course was complicated by a fever to 101.5°F on postoperative day 3. After further workup, no infectious source was identified. The patient defervesced 6 hours later with no acute intervention, and the patient was eventually discharged on postoperative day 7 after achieving physical therapy and occupational therapy goals as well as adequate pain management.

At the patient's latest follow-up, her groin pain had resolved, leg-length discrepancy corrected, range of motion improved, and she was transitioned from a rolling-walker to a single-point cane. Radiographic imaging demonstrated no evidence of hardware complications; however, there was persistent metallosis involving the surrounding soft tissue consistent with prior radiographs (Fig. 5).

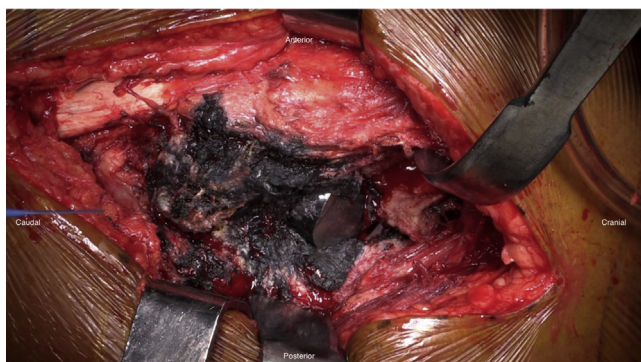

Figure 4. Intraoperative image showing abundant metallosis and a flattened femoral head.

Discussion

Several investigators have reported that dislocated Oxinium femoral heads may undergo rapid accelerated wear resulting in catastrophic implant failure [22–24]. Although the Oxinium femoral head surface is twice as hard as CoCr femoral heads [25], Kop *et al.* [22] found that the substrate is softer, lending itself to plastic deformity when left exposed and in contact with acetabular shell materials that are twice as hard [26–29]. However, in our patient, there was no known history of dislocation. We hypothesize that the acetabular liner dissociated due to incomplete seating during the index procedure.

Acetabular liner dissociation is a rare complication of THA, with the current Pinnacle (DePuy, Warsaw, IN) [26–29] and historic Galante-Harris (Zimmer, Warsaw, IN) [30–32] designs showing greater risk. Yun *et al.* [33] described 23 Pinnacle acetabular liner dissociations among 8 surgeons at 4 hospitals. There was no history of trauma in any of the patients, and clinically, they experienced a characteristic sudden-onset discomfort. Radiographs demonstrated superior subluxation of the femoral component similar to our patient. In addition, Yun and colleagues found fractures of the 3 antirotation tabs at the PE rim, allowing for rotational liner displacement and subsequent direct articulation of the femoral head with the acetabular shell. Notably, one hip showed extensive metallosis requiring revision THA 3 months after the index procedure. Liner dissociation is the likely etiology of our patient's implant failure given our patient's continued pain after her index procedure, radiographic evidence of a superiorly displaced and aspherical femoral head with extensive metallosis at her 3-year follow-up, and the intraoperative findings of liner dissociation and aspherical femoral head wear.

Despite the overt metallosis present at the time of revision THA, the patient had low levels of plasma Co and serum Cr as the Oxinium femoral head is made from zirconium. Even when CoCr alloy components fail, studies have shown that metal ion levels are unreliable predictors of metallosis and should not be used as primary indicator for revision THA [34–36]. Griffin *et al.* [34] reported a sensitivity and specificity of 61% and 58% for Co and 31% and 76% for Cr, respectively. Our findings confirm that metal ion levels alone should not be used as a screening test for metallosis and should only be used to supplement clinical and radiological findings. Considering our patient had residual metallosis postoperatively, surveillance should include annual clinical examinations with a focus on cardiac, neurologic, and dermatologic physical examinations. In addition, measurements of blood metal ion levels and radiologic evaluations should be performed at subsequent follow-up visits.

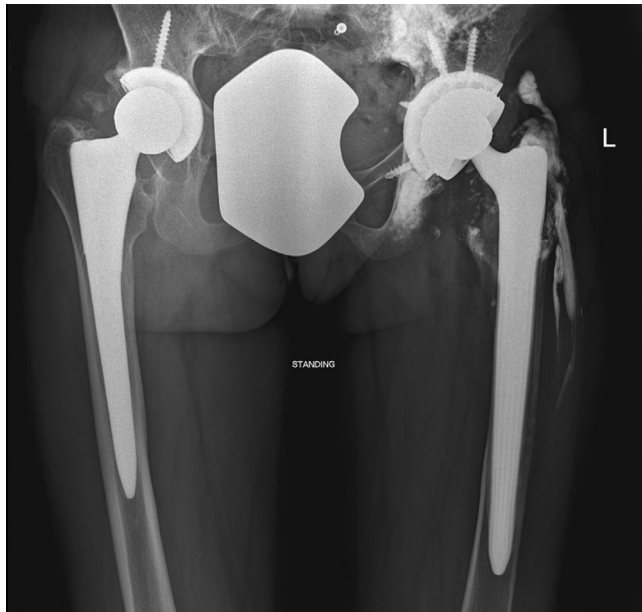

Figure 5. Anteroposterior radiograph of the pelvis at latest follow-up demonstrating no evidence of hardware complication and diffuse metallosis involving the surrounding soft tissue and bone.

Other described etiologies of Oxinium femoral head failure include third-body wear, ceramic liner pairing, and PE liner compromise [37,38]. Tribe *et al.* [39] described a case of a cracked PE liner, allowing direct articulation of an Oxinium head with the acetabular cup, leading to accelerated femoral head wear.

Regarding management, we chose to revise the hip with a dual-mobility cup to reduce the risk of future dislocation given extensive soft tissue disruption in part due to metallosis [40]. We recommend that surgeons take particular care to ensure that the liner is properly seated and engaged at the time of implantation, especially when using Oxinium femoral heads.

Summary

This report presents a unique case highlighting failure of the Oxinium femoral head in a patient with no known history of hip dislocation or trauma. Improper seating of the liner leading to liner dissociation was the most likely etiology leading to catastrophic failure. Our findings stress the importance of ensuring proper liner engagement when using Oxinium femoral heads, as failure to do so may lead to catastrophic implant failure. In such cases, dual-mobility or constrained liners should be highly considered to reduce the risk of dislocation given the resultant extensive metallosis.

References

- [1] Learmonth ID, Young C, Rorabeck C. The operation of the century: total hip replacement. *Lancet* 2007;370(9597):1508.
- [2] Neumann PJ, Cohen JT, Weinstein MC. Updating Cost-Effectiveness — the Curious Resilience of the \$50,000-per-QALY Threshold. *N Engl J Med* 2014;371(9):796.
- [3] Daigle ME, Weinstein AM, Katz JN, Losina E. The cost-effectiveness of total joint arthroplasty: a systematic review of published literature. *Best Pract Res Clin Rheumatol* 2012;26(5):649.
- [4] Elmallah RK, Chughtai M, Khlopas A, et al. Determining cost-effectiveness of total hip and knee arthroplasty using the short form-6D utility measure. *J Arthroplasty* 2017;32(2):351.
- [5] Kurtz SM, Lau E, Ong K, Zhao K, Kelly M, Bozic KJ. Future young patient demand for primary and revision joint replacement: national projections from 2010 to 2030. *Clin Orthop Relat Res* 2009;467(10):2606.

- [6] Wolford ML, Palso K, Bercovitz A. Hospitalization for total hip replacement among inpatients aged 45 and over: United States, 2000–2010 key findings. *NCHS Data Brief* 2015;186:1.
- [7] Semlitsch M, Lehmann M, Weber H, Doerre E, Willert HG. New prospects for a prolonged functional life-span of artificial hip joints by using the material combination polyethylene/aluminium oxide ceramic/metal. *J Biomed Mater Res* 1977 Jul;11(4):537.
- [8] Allain J, Roudot-Thoraval F, Delecrin J, Anract P, Migaud H, Goutallier D. Revision total hip arthroplasty performed after fracture of a ceramic femoral head. A multicenter survivorship study. *J Bone Joint Surg Am* 2003;85A(5):825.
- [9] Fritsch EW, Gleitz M. Ceramic femoral head fractures in total hip arthroplasty. *Clin Orthop Relat Res* 1996;328:129.
- [10] Archibeck MJ, Cummins TR, Carothers J, Junick DW, White Jr RE. A Comparison of Two Implant Systems in Restoration of Hip Geometry in Arthroplasty. *Clin Orthop Relat Res* 2011;469(2):443.
- [11] Beaulé PE, Kim PR, Hamdi A, Fazekas A. A prospective metal ion study of large-head metal-on-metal bearing: a matched-pair analysis of hip resurfacing versus total hip replacement. *Orthop Clin North Am* 2011;42(2):251.
- [12] Tan SC, Lau ACK, Del Balso C, Howard JL, Lanting BA, Teeter MG. Tribocorrosion: ceramic and oxidized zirconium vs cobalt-chromium heads in total hip arthroplasty. *J Arthroplasty* 2016;31(9):2064.
- [13] McCalden RW, MacDonald SJ, Rorabeck CH, Bourne RB, Chess DG, Charron KD. Wear rate of highly cross-linked polyethylene in total hip arthroplasty. *J Bone Joint Surg Am* 2009;91(4):773.
- [14] Baek S-H, Kim WK, Young J, et al. Do alumina matrix composite bearings decrease hip noises and bearing fractures at a minimum of 5 years after THA? *Clin Orthop Relat Res* 1999;473:3796.
- [15] Hamilton WG, Mcauley JP, Dennis DA, et al. THA with delta ceramic on ceramic results of a multicenter investigational device exemption trial level of evidence: level I, therapeutic study. See guidelines for Authors for a complete description of levels of evidence. *Clin Orthop Relat Res* 2010;468:358.
- [16] Good V, Ries M, Barrack RL, Widding K, Hunter G, Heuer D. Reduced wear with oxidized zirconium femoral heads. *J Bone Joint Surg Am* 2003;85-A(Suppl 4):105.
- [17] Patel AM, Spector M. Tribological evaluation of oxidized zirconium using an articular cartilage counterface: a novel material for potential use in hemiarthroplasty. *Biomaterials* 1997;18(5):441.
- [18] Karidakis GK, Karachalios T. Oxidized zirconium head on crosslinked polyethylene liner in total hip arthroplasty: a 7- to 12-year in vivo comparative wear study. *Clin Orthop Relat Res* 2015;473(12):3836.
- [19] Zaoui A, Hage S El, Langlois J, Scemama C, Coupied JP, Hamadouche M. Do oxidized zirconium femoral heads reduce polyethylene wear in cemented THAs? A blinded randomized clinical trial. *Clin Orthop Relat Res* 2015;473(12):3822.
- [20] Petis SM, Vasarhelyi EM, Lanting BA, et al. Mid-term survivorship and clinical outcomes of cobalt-chrome and oxidized zirconium on highly crosslinked polyethylene. *Can J Surg* 2016;59(1):48.
- [21] Evangelista GT, Fulkerson E, Kummer F, Di Cesare PE. Surface damage to an Oxinium femoral head prosthesis after dislocation. *J Bone Joint Surg Br* 2007;89-B(4):535.
- [22] Kop AM, Whitewood C, Johnston DJL. Damage of oxinium femoral heads subsequent to hip arthroplasty dislocation. *J Arthroplasty* 2007;22(5):775.
- [23] Jaffe WL, Strauss EJ, Cardinale M, Herrera L, Kummer FJ. Surface oxidized zirconium total hip arthroplasty head damage due to closed reduction: effects on polyethylene wear. *J Arthroplasty* 2009;24(6):898.
- [24] Moussa ME, Esposito CI, Elpers ME, Wright TM, Padgett DE. Hip dislocation increases roughness of oxidized zirconium femoral heads in total hip arthroplasty: an analysis of 59 retrievals. *J Arthroplasty* 2015;30(4):713.
- [25] Hunter G, Dickinson J, Herb B, Graham R. Creation of oxidized zirconium orthopaedic implants. *J ASTM Int* 2005;2(7):12775.
- [26] Mesko JW. Acute liner dissociation of a pinnacle acetabular component. *J Arthroplasty* 2009;24(5):815.
- [27] Gray CF, Moore RE, Lee G-C. Spontaneous dissociation of offset, face-changing polyethylene liners from the acetabular shell. *J Bone Joint Surg Am* 2012;94(9):841.
- [28] Mayer SW, Wellman SS, Bolognesi MP, Attarian DE. Late liner dissociation of a pinnacle system acetabular component. *Orthopedics* 2012;35(4):e561.
- [29] Jameson SS, Baker PN, Mason J, et al. Independent predictors of failure up to 7.5 years after 35 386 single-brand cementless total hip replacements. *Bone Joint J* 2013;95-B(6):747.
- [30] González della Valle A, Ruzo PS, Li S, Pellicci P, Sculco TP, Salvati EA. Dislodgment of polyethylene liners in first and second-generation Harris-Galante acetabular components. A report of eighteen cases. *J Bone Joint Surg Am* 2001;83-A(4):553.
- [31] Werle J, Goodman S, Schurman D, Lannin J. Polyethylene liner dissociation in Harris-Galante acetabular components: a report of 7 cases. *J Arthroplasty* 2002;17(1):78.
- [32] Saito S, Ryu J, Seki M, Ishii T, Saigo K, Mori S. Analysis and results of dissociation of the polyethylene liner in the Harris-Galante I acetabular component. *J Arthroplasty* 2008;23(4):522.

- [33] Yun A, Koli EN, Moreland J, et al. Polyethylene liner dissociation is a complication of the depuy pinnacle cup: a report of 23 cases. *Clin Orthop Relat Res* 2016;474(2):441.
- [34] Griffin WL, Fehring TK, Kudrna JC, et al. Are metal ion levels a useful trigger for surgical intervention? *J Arthroplasty* 2012;27(8 SUPPL):32.
- [35] Malek IA, King A, Sharma H, et al. The sensitivity, specificity and predictive values of raised plasma metal ion levels in the diagnosis of adverse reaction to metal debris in symptomatic patients with a metal-on-metal arthroplasty of the hip. *Bone Joint J* 2012;94–B(8):1045.
- [36] Macnair RD, Wynn-Jones H, Wimhurst JA, Toms A, Cahir J. Metal ion levels not sufficient as a screening measure for adverse reactions in metal-on-metal hip arthroplasties. *J Arthroplasty* 2013;28(1):78.
- [37] Gibon E, Scemama C, David B, Hamadouche M. Oxinium femoral head damage generated by a metallic foreign body within the polyethylene cup following recurrent dislocation episodes. *Orthop Traumatol Surg Res* 2013;99(7):865.
- [38] Ozden VE, Saglam N, Dikmen G, Tozun IR. Oxidized zirconium on ceramic; Catastrophic coupling. *Orthop Traumatol Surg Res* 2017;103(1):137.
- [39] Tribe H, Malek S, Stammers J, Ranawat V, Skinner JA. Advanced wear of an Oxinium™ femoral head implant following polyethylene liner dislocation. *Ann R Coll Surg Engl* 2013;95(8):e133.
- [40] Vigdorchik JM, D'Apuzzo MR, Markel DC, et al. Lack of early dislocation following total hip arthroplasty with a new dual mobility acetabular design. *Hip Int* 2015;25(1):34.