



Acute increase in a thyroid cyst during cesarean section under general anesthesia in a full-term parturient: a case report

Ju Eun Kwak[^], Kwon Hui Seo[^], Jiheon Kim[^], Yuseung Oh[^]

Department of Anesthesiology and Pain Medicine, Yeouido St. Mary's Hospital, College of Medicine, The Catholic University of Korea, Seoul, Republic of Korea

Contributions: (I) Conception and design: KH Seo; (II) Administrative support: KH Seo; (III) Provision of study materials or patients: JE Kwak; (IV) Collection and assembly of data: All authors; (V) Data analysis and interpretation: J Kim; (VI) Manuscript writing: All authors; (VII) Final approval of manuscript: All authors.

Correspondence to: Kwon Hui Seo, MD, PhD. Department of Anesthesiology and Pain Medicine, Yeouido St. Mary's Hospital, College of Medicine, The Catholic University of Korea, 10 63-ro, Yeongdeungpo-gu, Seoul 07345, Republic of Korea. Email: julianakh@hanmail.net.

Background: Pregnancy is associated with thyroid nodule formation and increased size. However, an acute increase in thyroid cysts during cesarean section is unusual.

Case Description: We describe the case of a 23-year-old primiparous woman at 37 weeks of gestation, without a history of thyroid disease, who underwent a cesarean section under general anesthesia. When the baby was delivered after induction of general anesthesia, the patient's airway pressure increased by approximately 5–7 mmHg, and her blood pressure increased to 170/78 mmHg. After delivery of the baby, the mother's anterior region of the neck began to swell, and ultrasonography revealed a large cystic mass. Even after aspiration of approximately 120 mL of dark brown intra-cystic fluid, the neck swelled again. Airway and blood pressure decreased after delivery and remained within the normal range until the end of surgery. Computed tomography performed after recovery from anesthesia revealed an approximately 320 mL-sized hemorrhagic cyst in the left thyroid gland with right tracheal deviation. Despite repeated aspirations and two alcohol ablations, the cyst's size increased rapidly, and the patient underwent radiofrequency ablation.

Conclusions: This case indicates that rapid increases in intrathoracic and blood pressure could precipitate a rapid increase in pre-existing thyroid cysts in a parturient during delivery.

Keywords: Caesarean section; thyroid nodule; pregnancy; intrathyroidal hemorrhage; case report

Submitted Jun 09, 2023. Accepted for publication Oct 12, 2023. Published online Nov 14, 2023.

doi: 10.21037/gs-23-245

View this article at: <https://dx.doi.org/10.21037/gs-23-245>

Introduction

During pregnancy, the thyroid gland can increase by 10–40%, depending on iodine intake and race, and the prevalence of thyroid nodules is approximately 20–30% (1,2). Pregnancy is also associated with an increase in the size of pre-existing thyroid nodules (3), which can sometimes cause severe complications in a parturient who has never been diagnosed with nodules before pregnancy

(4,5). Thyroid nodules are often discovered when the thyroid gland or nodule size is noticeably enlarged or when symptoms appear during the peripartum period (4,6). An increase in the size of cysts due to intrathyroidal hemorrhage and airway obstruction due to multiple nodules during pregnancy have also been reported; however, in most cases, the observed increase is gradual (4,7). We report an unusual case of acute neck swelling due to a huge thyroid

[^] ORCID: Ju Eun Kwak, 0000-0001-9034-3645; Kwon Hui Seo, 0000-0003-4397-9207; Jiheon Kim, 0000-0001-7308-1292; Yuseung Oh, 0009-0004-7421-528X.

cyst increase after delivery through a cesarean section under general anesthesia. We present this case in accordance with the CARE reporting checklist (available at <https://gs.amegroups.com/article/view/10.21037/gS-23-245/rc>).

Case presentation

A 23-year-old primiparous woman (height, 161 cm; weight, 63.6 kg) at 37 weeks of gestation underwent a cesarean section due to fetal growth restriction. The fetal weight estimated by prenatal ultrasonography (US) was 2.55 percentile of the gestational age, and the maternal blood pressure measured in the ward was 150/99 mmHg, suggesting preeclampsia. She wanted general anesthesia, so anesthesia was induced with 1% propofol and rocuronium bromide and maintained with 5–7 vol% desflurane. Approximately 11 min after tracheal intubation, a uterine incision was made, and the fetus was delivered approximately 2 min later. The baby was a boy weighing 2.48 kg, and the 1- and 5-min Apgar scores were 9 and 10, respectively. Immediately after delivery, the anterior region of the mother's neck was swollen (*Figure 1A*), and an emergency consultation with an otolaryngologist was requested. After US was performed in the operating room, a cystic mass was confirmed. Approximately 120 mL of dark brown intra-cystic fluid (*Figure 1B*) was aspirated using an 18-gauge angio-needle under ultrasound guidance.

However, the swelling returned and persisted until the surgery was complete. The airway pressure did not increase significantly despite neck swelling due to increased cyst size. The peak inspiratory pressure (PIP) before delivery was 17–18 mmHg, which increased to approximately 23–25 mmHg during delivery due to abdominal compression by the surgeon but decreased to 18 mmHg and was maintained after delivery. The patient's blood pressure increased to 170/78 mmHg at delivery; however, it decreased to 141/75 mmHg when measured again. Subsequently, systolic blood pressure was maintained at 110–120 mmHg until the end of the operation. The neck mass was soft, and there was no evidence of airway compression. After confirming that spontaneous breathing had returned after administration of a neuromuscular reversal agent and recovery of consciousness, the trachea was extubated. The patient was observed in a sitting position in the intensive care unit (ICU) for 1 day.

As shown in *Figure 1C*, the patient's neck was still swollen after admission to the ICU. After the patient was stabilized in the ICU, computed tomography (CT) of the neck was performed (*Figure 2A,2B*). On CT, a 67 mm × 81 mm × 113 mm sized (estimated volume, 320.9 mL) cystic mass, probably a hemorrhagic cyst, was found in the left thyroid gland with right-sided tracheal deviation; however, there was no active bleeding. The cysts descended below the sternal notch and above the bronchial bifurcation. The narrowest tracheal diameter in the transverse section was 10.02 mm. Cytological examination of the aspirated fluid confirmed the presence of cystic fluid containing hemosiderin-laden macrophages. A thyroid function test was performed immediately after surgery, which revealed that free thyroxine (free T4, 2.27 ng/L) and triiodothyronine (T3, 2.22 ng/mL) were high, and thyroid stimulating hormone (TSH) was low at 0.01 mIU/mL. The systolic blood pressure remained high at 150–160 mmHg until postoperative day (POD) 1 but decreased to approximately 120 mmHg from POD 2 to discharge. On POD 1, she was transferred to the general ward for US. US revealed an echogenic mass, presumed to be a blood clot, on the posterior wall of the cyst (*Figure 2C*). Approximately 150 mL of dark brown thin fluid was aspirated, and 20 mL of ethanol was injected without complications. In the thyroid function test performed on POD 2, TSH was still low (0.01 mIU/mL), but T3 (1.18 ng/mL) and free T4 (1.52 ng/L) returned to the normal range. Under the outpatient clinic follow-up plan 1 week later, the patient was discharged with the baby on POD 4.

Highlight box

Key findings

- Increases in the mother's blood pressure and airway pressure during delivery can dramatically increase the size of a pre-existing thyroid cyst.

What is known and what is new?

- Increases in the size of thyroid cysts can occur during peripartum periods, but most have been reported to be gradual.
- Rapid production of cystic fluid and hemorrhage due to the increased vascularity during pregnancy can cause a rapid increase in the size of the thyroid cyst.

What is the implication, and what should change now?

- Abrupt increase in the size of preexisting thyroid nodules can sometimes cause severe complications in a parturient who has never been diagnosed with thyroid nodules.
- Mothers with a suspected thyroid mass or a family history of thyroid disease, radiologic exams of the thyroid or thyroid function tests will help prevent the rapid growth of the thyroid mass and emergencies.

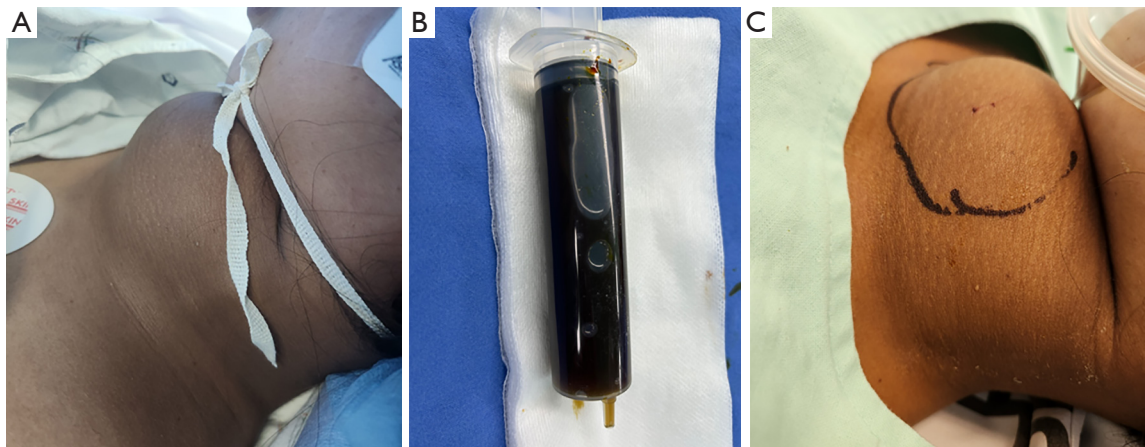


Figure 1 Photographs. (A) Photograph of the patient shortly after the onset of neck swelling; (B) fluid aspirated from the cystic mass; (C) photograph of the patient approximately 30 minutes after admission to the intensive care unit.

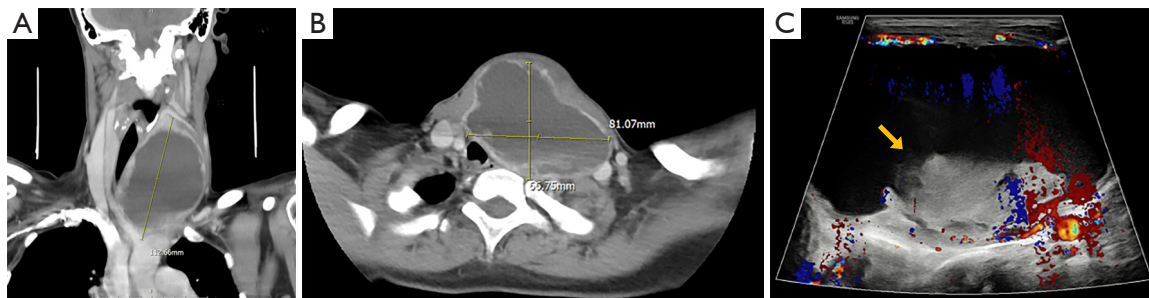


Figure 2 Radiologic findings after the operation. (A) Coronal CT scan of the neck; (B) axial CT scan of the neck; (C) thyroid ultrasonography. A re-enlarged cyst was revealed by the CT scan of the neck after the operation (A), which was probably hemorrhagic. The neck CT scan revealed that the trachea was deviated to the right by the thyroid cyst (B). In thyroid ultrasonography on postoperative day 1, an echogenic mass (yellow arrow) presumed to be a blood clot was in the lower wall of the cyst (C). CT, computed tomography.

Ten days after discharge (POD 14), the patient visited the outpatient clinic. On follow-up neck CT, a hemorrhagic cyst was still observed; however, its size was markedly reduced to 51 mm × 74 mm × 94 mm (estimated volume 185.7 mL, *Figure 3A*). The patient underwent US-guided aspiration of 96 mL of dark brown intra-cystic fluid and ethanol ablation. Five days after the first visit, she visited the outpatient clinic again, complaining of neck swelling. On US, the cyst size increased to 62 mm × 91 mm × 89 mm (262.5 mL), and tissue biopsy was performed using an 18-gauge gun biopsy needle. The cystic fluid was nearly completely aspirated, and 15 mL of ethanol was injected. Benign follicular nodules were confirmed by pathological examination. Two days after the second visit, the patient visited the outpatient clinic again with neck swelling, and 150 mL of cystic fluid was aspirated. Radiofrequency ablation

was performed with 40 watts of energy level for 24 minutes 2 days after the third visit (POD 28). A highly vascular thick cystic wall was observed before and after ablation and subtotal aspiration (*Figure 3B,3C*). The patient was discharged without complications under a follow-up plan after 2 months.

All procedures performed in this study were in accordance with the ethical standards of the institutional and/or national research committee(s) and with the Helsinki Declaration (as revised in 2013). Written informed consent was obtained from the patient for publication of this case report and accompanying images. A copy of the written consent is available for review by the editorial office of this journal.

Discussion

It is unclear why thyroid nodules increase in size, number,

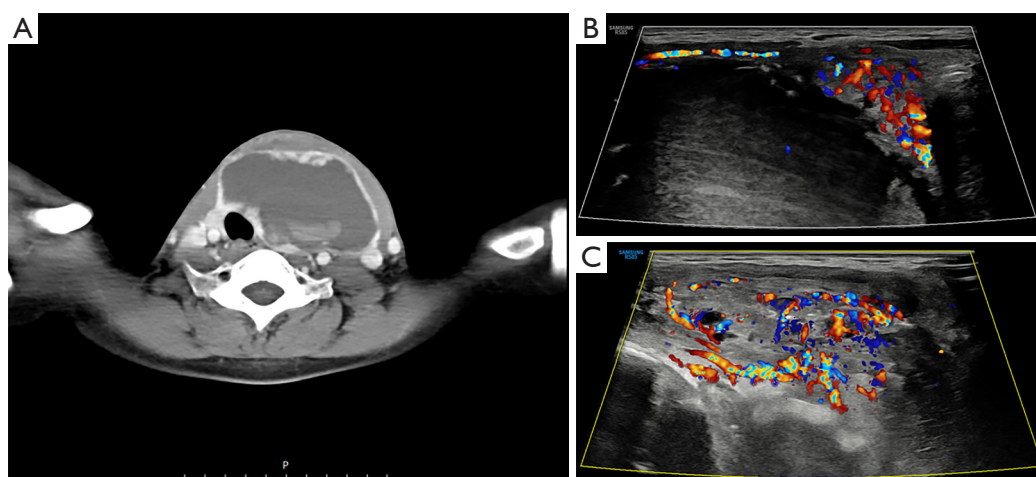


Figure 3 Radiologic findings on POD 14 and 28. (A) Axial CT scan of the neck (POD 14); (B) thyroid ultrasonography before radiofrequency ablation (POD 28); (C) thyroid ultrasonography after radiofrequency ablation and aspiration (POD 28). A hemorrhagic cyst was still observed in the CT scan on postoperative day 14 (A). Before (B) and after (C) radiofrequency ablation and aspiration, a highly vascular thick cystic wall was observed on ultrasonography. POD, postoperative day; CT, computed tomography.

and vascularity during pregnancy. Human chorionic gonadotropin (hCG) is a heterodimeric glycoprotein with the same alpha subunit as TSH (8). These structural similarities lead to cross-stimulation of TSH receptors by hCG, primarily during the first trimester of pregnancy, when hCG levels are highest (1,8). TSH receptor stimulation by high concentrations of hCG can cause thyroid nodules or glandular hyperplasia with increased thyroid hormone production (1). Relative negative iodine balance due to the physiological stress of pregnancy or insufficient iodine intake can also stimulate TSH secretion during pregnancy (9). In this patient, TSH level was lower than reference range of 0.1–4.0 mIU/L in early gestation, and T3 and T4 level was high even at full term. Other risk factors that may increase the risk of thyroid nodules during pregnancy include older age and a number of previous pregnancies (1). However, this patient was relatively young, had only one missed abortion, and did not live in an iodine deficient area.

In our case, the patient experienced diffuse neck swelling from mid-pregnancy but had never been previously diagnosed with thyroid disease. We did not notice swelling of the neck before delivery. The patient showed a contour of suspicious thyroid goiter and tracheal deviation on the preoperative chest radiograph; however, all faculty members overlooked it because only the lung lesions were checked and the patient's neck was not swollen externally. Since postoperative CT and US showed vascularity-rich

cystic walls and blood clots in the cyst, acute hemorrhage may cause rapid enlargement of the preexisting cyst and neck swelling. This may have been due to increased blood pressure for approximately 2–3 min during delivery. Also, the lower part of the cyst was partially located in the thoracic cavity on CT. It is also possible that part of the cyst in the thoracic cavity protruded into the cervical region due to increased intrathoracic pressure by positive pressure ventilation applied during general anesthesia and abdominal compression during delivery. The highest PIP was 25 mmHg, which was not very high that no intervention was required; however, the pressure might have been high enough to raise the intrathoracic portion of the cyst compared with self-respiration (negative pressure ventilation).

This case is unusual because of the repeated rapid increase in the size of the cyst. Pregnancy can increase the vascularity of thyroid nodules (9). Elevated intravascular pressure, such as in the Valsalva maneuver, asphyxia, and constipation, has been thought to be a possible cause of spontaneous intrathyroidal hemorrhage (10). Even in non-pregnant patients, it has been reported that intrathyroidal hemorrhage and infection caused a sudden increase in the size of pre-existing cysts and respiratory symptoms (10,11). Szeto *et al.* reported that intrathyroidal hemorrhage and cyst enlargement were occurred after increased blood pressure and mild cough due to endotracheal intubation in a healthy young man undergoing general anesthesia (12).

In this case, preeclampsia was suspected before surgery, and her blood pressure remained relatively high until POD 1. Since a dark brown thin fluid and not fresh blood was mainly aspirated, it was assumed that not only bleeding but also the rapid production of cystic fluid contributed to the repetitive increase in cyst size in this case. However, limited data have been published on pregnancy-induced rapid production of cystic fluids and nodular vascularity in the thyroid. One similar case was reported that the sizes of the thyroid nodules increased in a few hours due to an extraneous cause (presumed to be external compression of the neck), causing slight breathing difficulties in a woman at 20 weeks of pregnancy (5). In their case, they also reported that the goiter reformed after cyst aspiration and continued to the pre-aspiration size until the end of pregnancy.

There were no tracheal obstructions or any respiratory symptoms in the present case. However, rapid increases in solid thyroid nodules can cause severe respiratory symptoms such as dyspnea, stridor, and upper airway obstruction, requiring emergency endotracheal intubation during pregnancy and postpartum (2,6,13). Tracheal obstructions sometimes require pre-delivery thyroidectomy or emergency cesarean section and thyroidectomy before full-term (4,13). Awake intubations may be required for patients for whom airway maintenance is not guaranteed and difficult intubation is expected.

Thyroid function tests and radiologic examinations during pregnancy are not necessarily recommended unless a mother has a history of thyroid disease (2). However, in mothers with a suspected thyroid mass or a family history of benign or malignant thyroid disease, consistent follow-ups will help prevent the rapid growth of the thyroid mass and emergencies (2). In at-risk patients, the depth of anesthesia, airway pressure, and blood pressure changes should be carefully controlled to avoid sudden changes during the perioperative period.

Conclusions

In conclusion, we report an acute increase in thyroid cysts during cesarean section, likely due to increased intrathoracic and blood pressure during delivery. We suggest that preoperative assessment of thyroid nodules and preparation for airway management be done in high-risk parturients.

Acknowledgments

Funding: None.

Footnote

Reporting Checklist: The authors have completed the CARE reporting checklist. Available at <https://gs.amegroups.com/article/view/10.21037/gS-23-245/rc>

Peer Review File: Available at <https://gs.amegroups.com/article/view/10.21037/gS-23-245/prf>

Conflicts of Interest: All authors have completed the ICMJE uniform disclosure form (available at <https://gs.amegroups.com/article/view/10.21037/gS-23-245/coif>). The authors have no conflicts of interest to declare.

Ethical Statement: The authors are accountable for all aspects of the work in ensuring that questions related to the accuracy or integrity of any part of the work are appropriately investigated and resolved. All procedures performed in this study were in accordance with the ethical standards of the institutional and/or national research committee(s) and with the Helsinki Declaration (as revised in 2013). Written informed consent was obtained from the patient for publication of this case report and accompanying images. A copy of the written consent is available for review by the editorial office of this journal.

Open Access Statement: This is an Open Access article distributed in accordance with the Creative Commons Attribution-NonCommercial-NoDerivs 4.0 International License (CC BY-NC-ND 4.0), which permits the non-commercial replication and distribution of the article with the strict proviso that no changes or edits are made and the original work is properly cited (including links to both the formal publication through the relevant DOI and the license). See: <https://creativecommons.org/licenses/by-nc-nd/4.0/>.

References

1. Lee SY, Pearce EN. Assessment and treatment of thyroid disorders in pregnancy and the postpartum period. *Nat Rev Endocrinol* 2022;18:158-71.
2. Alexander EK, Pearce EN, Brent GA, et al. 2017 Guidelines of the American Thyroid Association for the Diagnosis and Management of Thyroid Disease During Pregnancy and the Postpartum. *Thyroid* 2017;27:315-89.
3. Papaleontiou M, Haymart MR. Thyroid nodules and cancer during pregnancy, post-partum and preconception planning: Addressing the uncertainties and challenges.

- Best Pract Res Clin Endocrinol Metab 2020;34:101363.
4. Aloumanis K, Mavroudis K, Vassiliou I, et al. Urgent thyroidectomy for acute airway obstruction caused by a goiter in a euthyroid pregnant woman. *Thyroid* 2006;16:85-8.
 5. Glinoeer D, Demeester R, Lemone M, et al. Acute increase in goiter size during a normal pregnancy: an exceptional case report. *Thyroid* 2003;13:881-4.
 6. Okeke CI, Merah NA, Atoyebi OA, et al. Acute airway obstruction in the puerperium secondary to massive thyroid enlargement. *Int J Obstet Anesth* 2006;15:79-84.
 7. El Jaouhari SD, Doghmi N, Najout H, et al. Acute respiratory failure secondary to a cervical goitre in a pregnant woman: a case report. *BMC Emerg Med* 2019;19:18.
 8. Rowe CW, Boelaert K. Thyroid Nodules and Thyroid Cancer Prior To, During, and Following Pregnancy. In: Feingold KR, Anawalt B, Blackman MR, et al. editors. *Endotext*. South Dartmouth (MA): MDText.com, Inc. Last updated on April 26, 2022.
 9. Kia Q, Rathakrishnan R, Hong C, et al. Pregnancy-Induced Accelerated Growth and Vascularity in a Thyroid Nodule. *J Diagn Med Sonogr* 2008;24:179-82.
 10. Başak H, Yücel L, Hasanova A, et al. Management of a Spontaneous Thyroid Nodule Hemorrhage Causing Acute Airway Obstruction. *Turk Arch Otorhinolaryngol* 2021;59:289-91.
 11. Nebiker CA, Delko T, Zulewski H, et al. Acute thyroid swelling and elevated C reactive protein. *BMJ Case Rep* 2013;2013:bcr2013200427.
 12. Szeto LD, Hung CT. Haemorrhage of a thyroid cyst as an unusual complication of intubation. *Anaesth Intensive Care* 2002;30:230-3.
 13. Hendrie MA, Kumar MM. Airway obstruction, caesarean section and thyroidectomy. *Int J Obstet Anesth* 2013;22:340-3.

Cite this article as: Kwak JE, Seo KH, Kim J, Oh Y. Acute increase in a thyroid cyst during cesarean section under general anesthesia in a full-term parturient: a case report. *Gland Surg* 2023;12(11):1636-1641. doi: 10.21037/gs-23-245