

# Supine percutaneous nephrolithotomy in horseshoe kidney

Silvia Proietti, Salvatore Di Pietro, Mon Mon Oo, Stefano Gisone, Riccardo Scalia, Franco Gaboardi, Guido Giusti

Department of Urology, European Training Centre of Endourology (ETCE), IRCCS San Raffaele Hospital, Milan, Italy

**Citation:** Proietti S, Di Pietro S, Oo MM, et al. Supine percutaneous nephrolithotomy in horseshoe kidney. Cent European J Urol. 2024; 77: 291-297.

## Article history

Submitted: Jan. 7, 2024

Accepted: Jan. 7, 2024

Published online: Feb. 25, 2024

## Corresponding author

Silvia Proietti  
IRCCS San Raffaele Hospital  
Department of Urology  
Via Olgettina 60  
20132 Milan, Italy  
proiettisil@gmail.com

**Introduction** Historically, percutaneous nephrolithotomy (PCNL) in horseshoe kidney (HSK) patients has been performed in the prone position. Nevertheless, thanks to the spread of the supine PCNL technique for patients with urinary stones and normal renal anatomy, some retrospective studies have already reported on supine PCNL and HSK, showing the effectiveness and safety of the procedure. Herein we report our experience with supine PCNL in a subset of patients with urolithiasis.

**Material and methods** Prospective data were collected for all HSK patients who underwent supine PCNL at our institution from June 2016 to June 2023. Stone volume was reported as the volume of a single stone or the sum of the volumes of multiple stones on computed tomography (CT) images. Patients were reported to be stone-free if there were no stones on postoperative non-contrast CT (NCCT) exam. Peri-/postoperative complications were reported according to the Clavien-Dindo classification system. The primary endpoint of the study was stone-free rate (SFR) and the secondary endpoints were Clavien-Dindo complications Grade I or higher.

**Results** A total of 35 patients met the inclusion criteria and were enrolled in the study. Forty-eight procedures were analyzed. SFR was 72.9% at 1-month follow-up. In 11 out of 48 procedures (22.9%) Clavien-Dindo Grade I-II complications were recorded. In one case Clavien-Dindo Grade IIIa complication was observed.

**Conclusions** In this prospective study of 35 HSK patients who underwent 48 procedures, supine PCNL was safe and effective, with minimal morbidity.

**Key Words:** percutaneous nephrolithotomy <> PCNL <> supine <> horseshoe kidney <> endourology <> urolithiasis <> renal stone

## INTRODUCTION

Horseshoe kidney (HSK) is the most common congenital renal abnormality with an incidence of 1:400, with a male-to-female ratio of 2:1 [1].

HSK is a fused anomaly with kidneys malrotated and located lower and more medial in the abdomen to their normal position; calyces are usually placed in the upper two-thirds of each kidney. The most common finding in HSK is ureteropelvic junction (UPJ) obstruction, which occurs in approximately 35% of HSK patients (high and anterior insertion of ureters into the kidney pelvis/ vessel crossing of the ureter over the HSK isthmus) [2].

The abovementioned reasons impair urinary drainage which results in increased incidence of infection and urolithiasis. Indeed, nephrolithiasis is the most common complication in HSK, occurring in 16% to 60% of cases [2].

Due to its frequency and special anatomy, stone treatment in HSK may represent a challenging situation for urologists.

The guidelines of the European and American Urological Associations suggest to treat stones larger than 2 cm with percutaneous nephrolithotomy (PCNL), even in HSK [3].

Historically, PCNL in HSK patients has been performed in prone position due to the easy access

to upper pole and consequently to the entire collecting system [4]. Nevertheless, thanks to the spread of the supine PCNL technique for patients with urinary stones and normal renal anatomy, some studies have already reported on supine PCNL and HSK, showing the effectiveness and safety of the procedure [5–7].

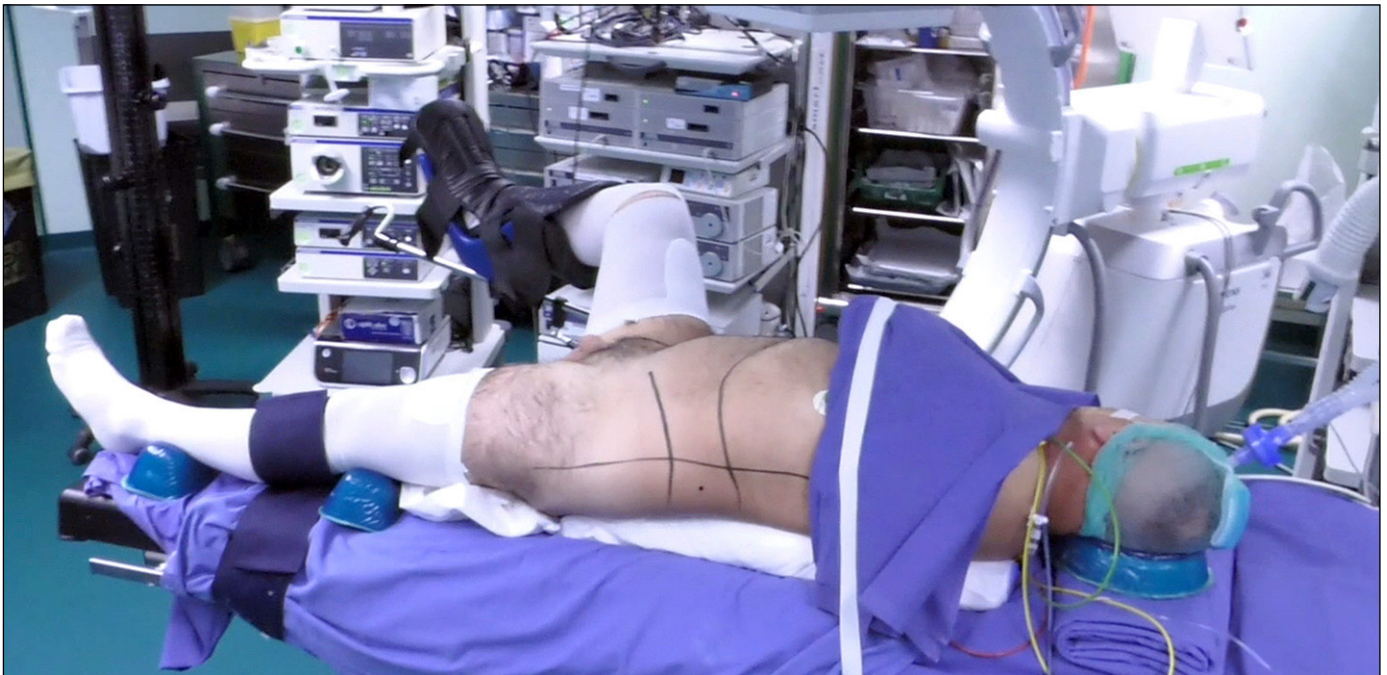That being said, regardless of the fact that the general understanding of the urological community is accepting ever more widely of the concept of supine PCNL, percutaneous treatment in HSK is still considered very demanding and consequently reserved only to prone position given that there are

only few published studies on the safety and efficacy of supine PCNL in HSK. Herein we report our experience on supine PCNL in a subset of patients with urolithiasis.

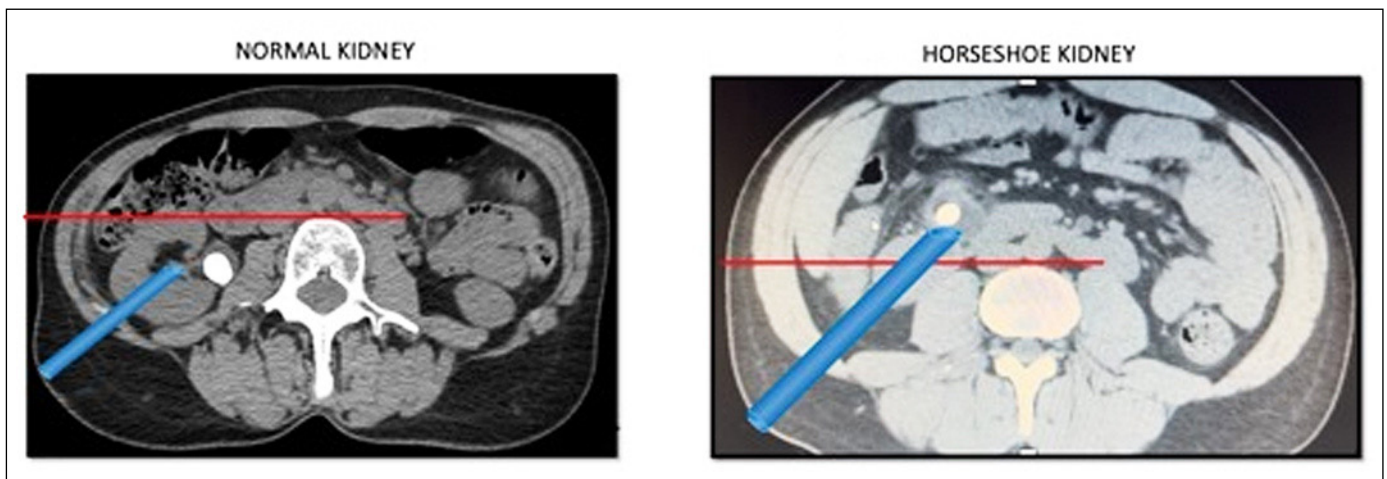
## MATERIALS AND METHODS

### Study population and endpoints

Prospective data were collected for all HSK patients who underwent supine PCNL at our institution from June 2016 to June 2023. The study was approved by the local ethics committee and patients provided



**Figure 1.** Giusti modification of Valdivia-Galdakao position.



**Figure 2.** Longer percutaneous tract in HSK patients compared to patients with normal anatomy.

informed consent. Inclusion criteria were as follows: either sex, age 18–80 years, patients with renal stone suitable for PCNL treatment (large stone burden, complex multiple stones, staghorn stones, failed other procedures) and HSK. Exclusion criteria were as follows: pregnancy, other associated anatomic abnormalities of the upper urinary tract, chronic kidney disease, untreated positive preoperative urine culture.

Routine preoperative and 1-month postoperative work-up included history, physical examination, urinalysis, urine culture and blood test. Abdominal contrast enhanced computed tomography (CT) scan was performed in all first cases preoperatively and without contrast (NCCT) at 1-month postoperatively or in case of recurrence for planning another treatment. Stone volume was reported as the volume of a single stone or the sum of the volumes of multiple stones on CT images. Patients were reported to be stone-free if there were no stones on post-operative NCCT. Operative time was calculated as the time of the first endoscope insertion to the completion of final stent placement. Peri-/postoperative complications were reported according to the Clavien-Dindo classification system [8]. The primary endpoint of the study was stone-free rate (SFR) and the secondary endpoints were Clavien-Dindo complications Grade 1 or higher.

Data are expressed as mean  $\pm$  standard deviation or as median (min-max).

## Technique

According to European Association of Urology (EAU) guidelines, preoperatively an intravenous injection of a second-generation cephalosporin was administered. After induction of general anesthesia, the patient was positioned for supine PCNL in our modified-Valdivia position as previously described [9] (Fig 1).

The procedure was then started: through a flexible cystoscope, a guidewire was placed into the kidney and coaxially a ureteral occlusion balloon was placed and positioned after retrograde pyelography.

PCNL was performed using either a 24 Fr or 17.5 Fr percutaneous tract, a rigid nephroscope and either ultrasonic/pneumatic lithotripsy or holmium laser lithotripsy, and basket extraction. At the end of every PCNL procedure, flexible nephroscopy was performed in addition to fluoroscopic evaluation to ensure all stones were removed. Flexible ureteroscopy (fURS) was combined when flexible nephroscope was not sufficient to improve the SFR.

A double-J stent was left for drainage at the end of each PCNL. A nephrostomy tube was placed

at the end of the procedure only in selected cases (i.e. multitract tract or infected stones) according to the surgeon's preference. A Foley catheter was placed in all patients at the end of the procedure.

## RESULTS

A total of 35 patients met the inclusion criteria and were enrolled in the study. Forty-eight procedures were analyzed. Demographic and stone characteristics are reported in Table 1. Intraoperative and postoperative data are shown in Table 2. SFR was 72.9% at 1-month follow-up. In 6 and 4 cases, an additional fURS and PCNL for residual fragments were performed respectively, two cases with a 4 mm residual fragment were observed and one patient refused any ancillary procedures. The transfusion rate was 2.1%. In 11 out of 48 procedures (22.9%) Clavien-Dindo Grade I-II complications were recorded (uncomplicated urinary tract infection requiring antibiotics in 2 cases; urinary retention requiring Foley catheterization in 1 case; in 7 cases fever and in 1 case anemia requiring transfusion). In one case Clavien-Dindo Grade IIIa complication was observed (renal arteriovenous fistula embolization under local anesthesia). No other intraoperative or postoperative complications were observed.

## DISCUSSION

PCNL in HSK may represent a challenge for urologists due to multiple aspects such as renal ectopia and malrotation, great variation in the number and

**Table 1.** Demographic and stone characteristics of patients (n = 35)

Gender, n (%)	
Male	27/35 (77)
Female	8/35 (23)
Age (y), mean $\pm$ SD	49.4 $\pm$ 12.1
BMI (kg/m <sup>2</sup> ), mean $\pm$ SD	26.3 $\pm$ 4.8
Stone size (cm <sup>3</sup> ), mean $\pm$ SD	3.83 $\pm$ 4.24
Guy's stone score, median (min–max)	3 (2–4)
Stone composition	
Infected stone (Carbapatite/Struvite)	18/48 (37.5)
Calcium Oxalate Monohydrate stone	7/48 (14.5)
Uric acid stone	4/48 (8.4)
Mixed stone	19/48 (39.6)
Previous stone surgery, n (%)	25/35 (71.4)
PCNL	5/35 (14.3)
FURS	9/35 (25.7)
SWL	9/35 (25.7)
Pyelolithotomy	2/35 (5.7)

n – number; SD – standard deviation; PCNL – percutaneous nephrolithotomy; FURS – flexible ureteroscopy; SWL – shock wave lithotripsy

origin of calyces with abnormal orientation, anomalous insertion of the ureter, unusual renal relationship with other abdominal organs and lastly, aberrant vascular pattern [2].

Historically, PCNL in HSK patients has been performed in prone position but thanks to the worldwide dissemination of the supine technique, recently a few retrospective series of supine PCNL for stones treatment in this subset of patients have been published showing its feasibility, effectiveness and safety [5–7]. In this report, we describe our experience with a prospective study of supine PCNL in HSK patients with kidney stones.

The largest study available in the literature is a multicentric retrospective study including 106 HSK cases treated with PCNL in both positions [5]. The Authors evaluated the impact of patient position on outcomes, showing similar SFR in both techniques, while shorter operative time ( $p = 0.04$ ) and lower Clavien II complication rate ( $p = 0.013$ ) were demonstrated in the supine group compared to the prone group. No other statistical differences were recorded between the two groups.

Therefore, they concluded that supine PCNL can be a valuable option for treating kidney stones in patients with HSK.

The above results parallel what has already been extensively shown in patients with normal anatomy treated with supine PCNL.

As a matter of fact, in a recent meta-analysis of 15 randomized controlled trials, Li et al. demonstrated that the supine PCNL group had a significantly shorter operative time and a lower rate of fever [10].

Our rate of fever of 14.5% is in line with the one reported in literature; Vicentini et al. reported a 14.3% in the supine group compared to 75% of cases in the prone group [5]. The same author, in another study on PCNL in complex cases (Guy's score 3 or greater), demonstrated similar outcomes regarding fewer infectious complications in supine PCNL cases than in those treated with prone PCNL ( $p = 0.042$ ) [11].

The abovementioned results in favor of supine position are probably due to the orientation of the percutaneous sheath, that, in this position, is parallel to the floor or angled downward with a continuing evacuation of fluid from the renal pelvis facilitated by gravity that could potentially lead to decreased intrarenal pressures and, theoretically, lower infectious risk after PCNL. However, to our best knowledge, albeit reasonable, this concept has not been scientifically demonstrated yet.

Conversely, one disadvantage of the supine position is the longer tract compared to the prone posi-

**Table 2.** Intraoperative and postoperative outcomes

Procedures, n	48
Total OR time (min), mean $\pm$ SD	55.6 $\pm$ 18.5
N° PCNL accesses, median (min-max)	1 (1–3)
1 (n, %)	38/48 (79.1)
2	8/48 (16.7)
3	2/48 (4.2)
Calyx of puncture	
Upper calyx	31/48 (64.6)
Middle calyx	6/48 (12.5)
Lower calyx	1/48 (2)
Upper + middle	10/48 (20.8)
ECIRS, n (%)	11/48 (22.9)
Nephrostomy tube, n (%)	8/48 (16.7)
Length of hospital stay (days), mean $\pm$ SD	2.6 $\pm$ 2.1
Primary SFR, n (%)	35/48 (72.9)
Transfusion rate	1/48 (2.1)
Complications by Clavien-Dindo Grade	
Grade I	12/48 (25)
Grade II	3/48 (6.2)
Grade III	8/48 (16.7)
Grade IV/V	1/48 (2.1)
	0/48(0)

n – number; SD – standard deviation; OR – operating room; SFR – stone-free rate; PCNL – percutaneous nephrolithotomy; ECIRS – endoscopic combined intrarenal surgery

tion, especially in HSK patients where the calyces and the renal pelvis are located more ventrally in the abdomen. These limitations may be overcome by routine use of a flexible nephroscope during supine PCNL, that becomes routinary in HSK patients due to the huge anatomical variation of calyces in terms of number and origin and very dependent lower pole. From a practical standpoint, when planning to perform supine PCNL in HSK patients, it is strongly suggested to have longer length rigid nephroscopes and Amplatz sheaths always available in the operating room (OR) (Fig 2).

In addition, supine position facilitates the execution of endoscopic combined intrarenal surgery (ECIRS) which can be considered the quintessence of this position [12]. In this study, ECIRS was performed in 11 out of 48 procedures (22.9%) whereas stones located in some calyces were not reachable by antegrade flexible nephroscopy. As a matter of fact, conversely to other centers where ECIRS is systematic in all cases, we resort to ECIRS only when really clinically needed i.e. when both rigid and/or flexible nephroscopy do not offer the best outcome. This practice, while offering similar SFR and limits multitract accesses, also limits procedural costs related to the execution of an additional costly fURS.

Regarding the shorter operative time in supine HSK group reported by Vicentini et al. [5], this concept follows the outcomes already widely shown by sev-

eral studies on supine PCNL in patients with normal anatomy [13, 14].

As matter of fact, the surgical position and patient draping is the same throughout the entire procedure, with unquestionably less effort for the OR personnel. All these small details of supine position combine to significantly shorten operative time.

Our operative time of  $55.6 \pm 18.5$  min was slightly shorter than those reported in literature in HSK patients. This finding may be due to the retrospective and multicentric nature of these studies where OR facilities may vary, dedicated OR personnel may be not available as it is at our stone center and different experience among surgeons may play a role in determining these diverse outcomes.

When analyzing the puncture, in our study the preferred calyx was the upper calyx in 64.6% of procedures when considering one single PCNL tract but this reaches 85.4% of cases when taking into consideration also the multitract accesses.

In contrast to the study of Vicentini et al., where the puncture of upper and middle calyx was performed similarly in 43.6% and 46.2% of supine cases respectively [5], in our study the most common access was through the upper pole, paralleling the outcomes reported by Kargi et al. where the upper pole puncture was performed in 82.1% of cases [6].

Whenever feasible, we preferred the upper pole puncture in HSK patients because of the anomalous anatomy. Indeed, it provides an optimal exposure to the upper and lower dependant and distant calyces, and the renal pelvis. As such, our suggestion generated by our two decades of experience is to consider the upper pole as the first choice for accessing the collecting system of a HSK. Notably, due to the peculiarity of this anatomical anomaly, the kidney is located more inferiorly when compared to a normal kidney, so that upper pole puncture is mostly performed below the 12<sup>th</sup> rib [15].

A demonstration of this is the fact that we have a 0% rate of pleural injury regardless of a rate of upper pole access as high as 85.4%.

In our study, the lower calyx was approached in only one case in a single access. This low rate of lower pole access was shown also by the other authors. The anatomical reason of that is that the lower calyx is displaced more anteromedially, often associated with a very long infundibulum [2]. Moreover, it is of utmost importance also not to underestimate the close relationship of the lower pole anatomy of HSK with major retroperitoneal vessels. As a consequence, this makes the percutaneous access difficult and risky as the trans-parenchymal tract is quite longer and not really versatile with an almost impossible manipulation of the remaining

part of the collecting system (middle and upper calyx). In other words, this clinical scenario is opposite to the one of normal anatomy in which supine position compared to prone guarantees a significantly better accessibility of the entire collecting system through a lower pole access [16].

As such, in our opinion this access should be reserved only in case of a bulky stone into the lower pole calyx not reachable with all other options such as flexible nephroscopy and/or retrograde ureteroscopy).

Our primary SFR was 72.9% that parallels the primary SFR reported by Vicentini et al [5].

Our outcomes are slightly lower compared to those reported by Kargi et al. where the SFR reported was 88.2% at 3-month follow-up [6]. It is noteworthy that, in the aforementioned study, cases were not classified according to the Guy's stone score in order to grade the complexity of PCNL procedure. Our median Guy's stone score was 3, comparable with that of Vicentini group whose SFR was 59%, as a consequence, quite similar to ours.

Notably, in our study, 15 cases were classified as Guy's stone score 4, being patients affected by complete staghorn stones. As a matter of fact, nephrolithiasis in HSK patients is often multiplied by the risk of large staghorn stones. The prevalence of stone disease in HSK is in the range of 16–60% [2]. Based on the meta-analysis by Pawar et al., the estimated pooled incidence of kidney stones is 36% [17]. The etiology of kidney stones in HSK patients is multifactorial: abnormal orientation of the calyces, high insertion of the ureter with common ureteropelvic obstruction can contribute to urinary stasis, urinary infection and urine crystal aggregation.

These anatomic changes, frequently associated with concomitant metabolic abnormalities, increase the risk of kidney stone formation in these patients. Pawar et al. reported that about 89.2% of kidney stones were calcium based stones (64.2% calcium oxalate, 18.8% calcium phosphate, 6.2% mixed CaOx/CaPO), followed by struvite stones (4.2%), uric acid stones (3.8%), and others (2.8%) [17].

Interestingly, in our study the stone composition was mainly carbapatite/struvite (37.5%) due to an infectious component or mixed (39.5%); similar findings were described by Garcia Rojo et al. who reported carbapatite/struvite as the main stone composition in their HSK patient series [18].

Regarding the transfusion rate, in our report it was 2.1%, perfectly in line with the previous studies published on this topic, without any increase in bleeding risk compared to supine PCNL cases with normal renal anatomy [13].

In fact, as demonstrated by Janetschek & Kunzel, the percutaneous tract in HSK patients does not induce

a higher risk of bleeding because the blood supply originates directly from the ventral-medial part, whereas the isthmus receives its supply directly from the aorta or the iliac vessels [19]; thus, the percutaneous tract is usually established onto the opposite side where the HSK vessels enter the kidney [20].

In addition, focusing on overall complication rate, in the present study, only one patient experienced a major complication such as Grade IIIA (2.1%); this patient required early embolization for renal arteriovenous fistula that was successful in stopping the bleeding without the need for blood transfusion. The overall complication rate was 25% (22.9% minor complications), enhancing the safety profile of this procedure in this position, even when dealing with such complicated cases.

To summarize our results, SFR were consistent with previously published reports in the literature and major complications were not experienced.

With that said, PCNL in HSK patients remains a demanding operation and consequently it should be performed by experienced surgeons in tertiary referral centers supplied with complete equipment and dedicated personnel.

There are several limitations to our study. First is sample size – this was a study of only 35 patients with 48 procedures and it was not randomized. This can be partially justified by the rarity of this clinical scenario. Moreover, larger prospective studies in the future are necessary to confirm the safety and efficacy of supine PCNL in HSK patients. However, our data were collected prospectively which does strengthen our findings.

Nonetheless, we feel that our results are encouraging and contribute to reinforce the results already available in the literature providing a stronger evidence based demonstration that supine PCNL is an effective procedure with low complication rate also in HSK patients with renal stones.

## CONCLUSION

In this prospective study of 35 HSK patients who underwent 48 procedures, supine PCNL was safe and effective, with minimal morbidity.

## CONFLICTS OF INTEREST

The authors declare no conflicts of interest.

## References

- Glenn JF. Analysis of 51 patients with horseshoe kidney. *N Engl J Med* 1959; 261: 684-87
- Balawender K, Cisek A; Cisek E, Orkisz S. Anatomical and Clinical Aspects of Horseshoe Kidney: A Review of the Current Literature. *Int. J. Morphol.*, 2019; 37:12-16
- EAU guidelines on Urolithiasis 2023. <http://uroweb.org/guideline/urolithiasis/>.
- Shokeir AA, El-Nahas AR, AM et al. Percutaneous nephrolithotomy in treatment of large stones within horseshoe kidneys. *Urology* 2004; 64: 426-9
- Vicentini FC, Mazzucchi E, Gokce MI et al. Percutaneous nephrolithotomy in horseshoe kidneys: results of a multicentric study. *J Endourol* 2021; 35: 979-84
- Kargi T, Eksi M, Karadag S et al. Optimal patients position for percutaneous nephrolithotomy in horseshoe kidneys: traditional prone or supine? *Actas Urologicas Espanolas* 2022; 46: 565-71
- Gupta S, Kasim A, Pal DK. Supine tubeless PCNL in horseshoe kidney (a series of cases). *Urologia Journal* 2022; 89: 559-63
- Dindo D, Demartines N, Clavien PA. Classification of surgical complications: a new proposal with evaluation in a cohort of 6336 patients and results of a survey. *Ann Surg.* 2004; 240:205
- Proietti S, Rodríguez-Socarrás ME, Eisner B et al. Supine percutaneous nephrolithotomy: tips and tricks. *Transl Androl Urol* 2019; 8 (Suppl 4): S381-388
- Li J, Gao L, Li Q, Zhang Y, Jiang Q. Supine versus prone for percutaneous nephrolithotripsy: a meta-analysis of randomized controlled trials. *Int J Surg* 2019; 66: 62-71
- Vicentini FC, Perrella R, Souza VMG, Hisano M, Murta CB, Claro JFA. Impact of patient position on the outcomes of percutaneous nephrolithotomy for complex kidney stones. *Int Braz J Urol* 2018; 44: 965-71
- Scoffone CM, Cracco CM, Cossu M, Grande S, Poggio M, Scarpa RM. Endoscopic combined intrarenal surgery in Galdakao-modified supine Valdivia position: a new standard for percutaneous nephrolithotomy? *Eur Urol.* 2008;54:1393-403.
- Perrella R, Vicentini, Eliane D. Paro et al. Supine versus Prone Percutaneous Nephrolithotomy for Complex Stones: A Multicenter Randomized Controlled Trial. *J Urol* 2022; 207: 647-56
- De Sio M, Autorino R, Quarto G, Calabrò F, Damiano R, Giugliano F, et al. Modified supine versus prone position in percutaneous nephrolithotomy for renal stones treatable with a single percutaneous access: a prospective randomized trial. *Eur Urol.* 2008;54:196-202.
- Natsis K, Piagkou M, Skotsimara A, Protogerou V, Tsitouridis I, Skandalakis P. Horseshoe kidney: a review of anatomy and pathology. *Surg. Radiol. Anat.* 2014, 36:517-26
- Sofer M, Giusti G, Proietti S, Mintz I, Kabha M, Matzkin H, et al. Upper Calyx Approachability through a Lower Calyx Access for Prone Versus Supine Percutaneous Nephrolithotomy. *J Urol.* 2016;195:377-82.
- Pawar AS, Thongprayoon C, Cheungpasitporn W, Sakhuja A, Mao MA, Erickson SB. Incidence and characteristics of kidney

- stones in patients with horseshoe kidney: A systematic review and meta-analysis. *Urol. Ann* 2018; 10:87-93
18. Garcia Rojo E, Teoh JYC, Castellani D et al. Real-world global outcomes of retrograde intrarenal surgery in anomalous kidneys: a high volume international multicenter study. *Urology* 2022; 159: 41-47
19. Janetschek G, Kunzel KH. Percutaneous nephrolithotomy in horseshoe kidneys: applied anatomy and clinical experience. *Br J Urol* 1988; 62: 117-22
20. Tepeler A, Sehgal PD, Akman T et al. Factors affecting outcomes of percutaneous nephrolithotomy in horseshoe kidneys. *Urology* 2014, 84: 1290-94. ■