

## CASE REPORT

# Thymic carcinoma with metastasis in a 29-year-old male causing radiculopathy

Kirill Alekseyev\*, Armando Iannicello, Giuseppe Amore, Travis Rosenkranz, and Marc K. Ross

Department of Medicine and Rehabilitation, Kingsbrook Jewish Medical Center, Brooklyn, NY, USA

\*Correspondence address. Department of Medicine and Rehabilitation, Kingsbrook Jewish Medical Center, 585 Schenectady Avenue, Suite 224, Brooklyn, NY 11203, USA. Tel: +(917)-379-8964; E-mail: kirill.alekseyev@gmail.com

## Abstract

Thymic carcinoma is a rare, aggressive neoplasm with low 5-year survival rates ranging from 28 to 67%. Initial presentation with spinal or bone metastasis in primary thymic carcinoma is extremely rare. Thymic carcinoma, compared with thymoma, has higher recurrence rates and worse survival. We report one patient, a 29-year-old African-American male, with thymic carcinoma with metastasis to the epidural space (with cord compression), multiple bony structures (T10–L1) and left supraclavicular lymph node. Immunohistochemical staining was CD5 and c-Kit positive, consistent with thymic carcinoma. Patient underwent T12–L1 laminectomy with tumor resection to relieve cord compression and leg numbness/weakness. Patient was deemed a good candidate for rehabilitation. Soon after starting a rehabilitation program, he quickly demonstrated gains in gait distance with little to no assistance. Follow-up appointments with oncology were scheduled, and further planning of radiation and chemotherapy treatments were discussed.

## INTRODUCTION

The purpose of this article is to present a case that highlights a rare occurrence of thymic carcinoma in a 29-year-old African-American male and help shed light on the debilitating effects caused by cancer metastasis.

The thymus, located in the anterior superior mediastinum, plays a central role in T-cell maturation and adaptive immunity. The organ decreases in size and function with age. Cancer of the thymus is rare with thymomas comprising only 0.13 per 100 000 patient-years and thymic carcinoma only 0.06% of all thymic neoplasms [1]. While thymomas typically run an indolent course, thymic carcinoma is a rare, aggressive neoplasm with low 5-year survival rates ranging from 28 to 67% [2]. Additionally, thymomas have a variable presentation, manifesting concomitantly with myasthenia gravis (one third of cases), local symptoms (chest pain, shortness of breath, neck mass, SVC syndrome; one third)

or asymptotically as mediastinal mass on imaging studies [3]. In contrast, thymic carcinoma frequently spreads to the pleural space, regional lymph nodes, liver and lungs [4]. Thymic carcinoma, compared with thymoma, has higher recurrence rates and worse survival [5, 6]. Prognostic factors of thymic carcinoma include histology, resectability, stage and tumor size [2]. The current stage classification is four-tiered and named the Masaoka-Koga staging system. Early staging is vital for treatment and prognostic purposes. Advanced Masaoka-Koga stage correlates with shorter survival even in those patients that undergo complete excision [7].

Due to the rarity of thymic carcinoma, analysis of treatment outcomes is problematic. The gold standard for resectable thymic carcinoma is surgery with chemotherapy and radiation used as adjuncts [2]. While complete resection remains the standard of therapy for thymoma and thymic carcinoma, the dismal prognosis has led to experimentation with new chemotherapeutic

Received: April 6, 2016. Revised: May 3, 2016. Accepted: May 10, 2016

© The Author 2016. Published by Oxford University Press.

This is an Open Access article distributed under the terms of the Creative Commons Attribution Non-Commercial License (<http://creativecommons.org/licenses/by-nc/4.0/>), which permits non-commercial re-use, distribution, and reproduction in any medium, provided the original work is properly cited. For commercial re-use, please contact [journals.permissions@oup.com](mailto:journals.permissions@oup.com)

treatment modalities [5]. Although chemotherapy could play an important role in treating thymic carcinoma, the best regimen has yet to be determined owing to the rarity of this malignancy. In small retrospective studies, the combination of cisplatin, doxorubicin, vincristine and cyclophosphamide (ADOC) showed a higher response and remission rate when compared with carboplatin and paclitaxel [8].

## CASE REPORT

Here, we describe an extremely rare case of thymic carcinoma in a young patient that initially presented with back pain and lower extremity weakness following an accidental fall. Hip and lower extremity flexion and extension motor strength was rated 1/5 on left and 2/5 on right. The patient did not exhibit signs and symptoms of myasthenia gravis (ptosis, double vision or weakness worse with activity) or local manifestations of a thymoma

(neck mass, shortness of breath or chest pain). Subsequent computed tomography (CT) and magnetic resonance imaging (MRI) studies on admission revealed a large anterior mediastinal mass, pathological fractures involving T10–L1, epidural tumor extension with cord compression at T11–T12 and multiple sites of bony metastasis. Biopsy and immunohistochemical staining of the enlarged left supraclavicular lymph node was CD5 and c-Kit positive, confirming the diagnosis of thymic carcinoma with squamous differentiation. According to the Masaoka-Koga classification system, this patient's malignancy is classified as IVb, indicating hematogenous metastasis to distant sites (Figs 1–4).

Pain management was consulted, and the patient was followed throughout his admission. To control pain, our patient was given 10 mg oxycontin q6 h and 10 mg oxycodone q6 h prn. To control our patient's neuropathic pain, he was given 300 mg gabapentin qhs. Strengthening of core (abdominal muscles),

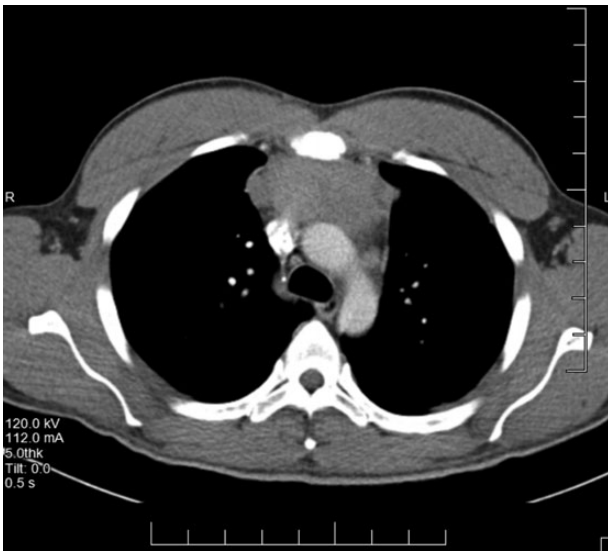


Figure 1: Thymic mass.

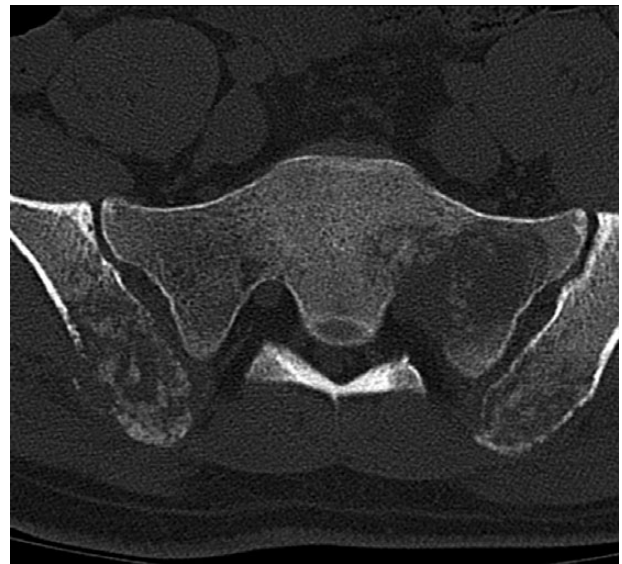

Figure 3: Iliac crest metastasis.

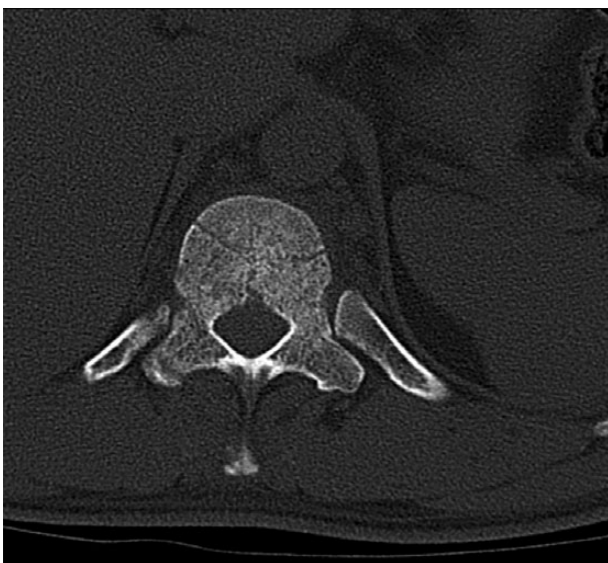

Figure 2: T11–T12 metastasis.

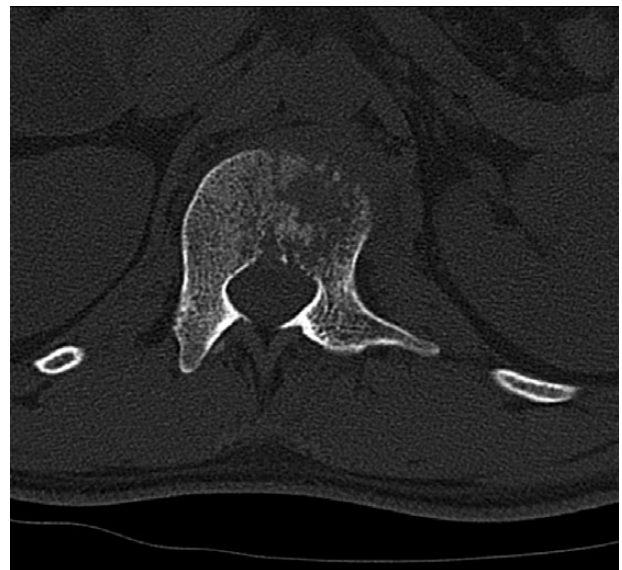

Figure 4: L1 metastasis.

gluteal muscles, quadriceps and hamstrings were emphasized during closed-chain exercises. Minimizing back extension and application of heat and ice during physical therapy reduced back pain. Our patient's lower extremity motor strength improved from 2-/5 on left and 2/5 on right to 4-/5 on left and 4/5 on right. He was able to improve his ambulation through the use of parallel bars during therapy and a rolling walker. He eventually progressed to walking with the assistance of only a cane. New imaging studies are scheduled to review tumor regression 3 months following radiation treatment.

## DISCUSSION

Our patient was deemed a good candidate for Inpatient Rehabilitation Facility (IRF) to improve activities of daily living (ADL), instrumental activities of daily living (iADLs), strength, endurance, balance and gait training. In addition, our patient needed physical therapy to build his strength to prepare for additional chemo and radiation therapies. The patient was unable to demonstrate a full range of motion passively and was unable to maintain these positions with resistance added. These deficits were prominent because of the combination of severe back pain and weakness following chemotherapy prior to admission to our rehab unit. With better control of his pain, our patient was immediately able to participate in therapy sessions. He was highly motivated during therapy sessions and was focused on improving his deficits.

Follow-up appointments with oncology were scheduled and attended by the patient for further planning of radiation and chemotherapy. After being discharged from our acute IRF, the patient is set to start radiation therapy followed by chemotherapy a week after. He will undergo three rounds of chemotherapy and radiation followed by repeat CT scan of the chest and MRI of the spine for tumor size regression. His current rehab stay has been uncomplicated, and the patient reports that his lower extremity weakness and back pain have improved since admission. The patient has a positive outlook, is motivated to get stronger to prepare for chemotherapy and radiation therapy and has strong family support. He reports that his ambulation, balance and overall strength have improved dramatically since starting rehab.

Although such extensive metastasis can be devastating, our patient has many positive factors that can help improve his outcome. These factors include young age of patient, early tumor metastasis detection, immediate treatment with chemotherapy, rehabilitation, radiation therapy and pain control. The combination of these factors in a motivated 29-year-old patient may improve outcome if treatment is continued. We will continue to monitor our patient as an outpatient in our Physical Medicine and Rehabilitation clinic following his radiation treatments.

## CONFLICT OF INTEREST STATEMENT

None declared.

## FUNDING

No sources of funding.

## ETHICAL APPROVAL

No ethical approval required.

## CONSENT

Informed consent by the patient was obtained.

## GUARANTOR

K.A. is the guarantor of this study.

## REFERENCES

- Greene MA, Malias MA. Aggressive multimodality treatment of invasive thymic carcinoma. *J Thorac Cardiovasc Surg* 2003;125:434-6.
- Weksler B, Dhupar R, Parikh V, Nason K, Pennathur A, Ferson P. Thymic carcinoma: a multivariate analysis of factors predictive of survival in 290 patients. *Ann Thorac Surg* 2013;95:299-304.
- Engels EA. Epidemiology of thymoma and associated malignancies. *J Thorac Oncol* 2010;5:260-5.
- Sasaki S, Fukushima T, Maruyama Y, Gomi D, Kobayashi T, Sekiguchi N, et al. Two cases of thymic carcinoma initially presenting as bone metastasis: a clinical report and the usefulness of CD5 immunohistochemistry for assessing bone lesions. *Intern Med* 2015;54:1781-5.
- Ogawa K, Toita T, Uno T, Fuwa N, Kakinohana Y, Kamata M, et al. Treatment and prognosis of thymic carcinoma: a retrospective analysis of 40 cases. *Cancer* 2002;94:3115-9.
- Blumberg D, Burt ME, Bains MS, Downey RJ, Martini N, Rusch V, et al. Thymic carcinoma: current staging does not predict prognosis. *J Thorac Cardiovasc Surg* 1998;115:303-9.
- Detterbeck FC, Nicholson AG, Kondo K, Van Schil P, Moran C. The masaoka-koga stage classification for thymic malignancies: clarification and definition of terms. *J Thorac Oncol* 2011;6:1710-6.
- Agatsuma T, Koizumi T, Kanda S, Ito M, Urushihata K, Yamamoto H, et al. Combination chemotherapy with doxorubicin, vincristine, cyclophosphamide, and platinum compounds for advanced thymic carcinoma. *J Thorac Oncol* 2011;6:2130-4.