

# Bilateral myelinated nerve fiber layers, high hyperopia, and amblyopia

Saad H. Alenezi<sup>1,2</sup>, Rawan Al-Shabeeb<sup>2</sup>, Hani B. AlBalawi<sup>3</sup>, Samar A. Al-Swailem<sup>2</sup>

<b>Access this article online</b>
Quick Response Code:

Website: www.saudijophthalmol.org
DOI: 10.4103/1319-4534.310413

## Abstract:

We report a case of bilateral myelinated nerve fiber layer (MNFL) in a 24-year-old male with high hyperopia and amblyopia. He presented with poor vision bilaterally since childhood and was evaluated for ophthalmic and systemic diseases. Retinal examination indicated MNFLs in both eyes. The presence of bilateral MNFL associated with axial hypermetropia is rare. Ametropia seems to have a stronger influence on the relative visual acuity than the presence of retinal nerve fiber myelination. Early detection of ametropia and correction with glasses might prevent further deterioration of vision.

## Keywords:

Amblyopia, hypermetropia, myelinated nerve fiber layers, ametropia

## INTRODUCTION

First described by Virchow in 1856, myelinated retinal nerve fiber layers (MNFLs) appear as white striated patches with feathery borders in the inner retinal layers.<sup>[1]</sup> Myelinated nerve fiber layers (MNFLs) are considered a developmental anomaly due to an acquired insult to the functional integrity of the lamina cribrosa.<sup>[2]</sup>

Patients with MNFL may be completely asymptomatic or may have significant visual defects, especially those with marked axial myopia and amblyopia in the affected eye.<sup>[2]</sup> In previous reports, the eye with myelinated nerve fibers was often highly myopic,<sup>[1-3]</sup> or, if hyperopic, less so than the fellow eye.<sup>[4]</sup> We report a case of bilateral myelinated nerve fibers associated with axial hyperopia and amblyopia in both eyes.

## CASE REPORT

A 24-year-old male presented to the cornea clinic with a history of poor vision since childhood and interested to get rid of glasses. He underwent a detailed ophthalmic examination.

This is an open access journal, and articles are distributed under the terms of the Creative Commons Attribution-NonCommercial-ShareAlike 4.0 License, which allows others to remix, tweak, and build upon the work non-commercially, as long as appropriate credit is given and the new creations are licensed under the identical terms.

For reprints contact: WKHLRPMedknow\_reprints@wolterskluwer.com

The uncorrected distance visual acuity was 20/300 in the right eye and 20/200 in the left eye.

Subjective refraction was +8.25 -2.50 × 10 in the right eye and +5.75 -1.50 × 170 in the left eye. The cycloplegic refraction was +10 -2.50 X 10 in the right eye and +9 -1.50 × 170 in the left eye with the best corrected visual acuity of 20/40 in both eyes. Intraocular pressure (pneumotometry) was 16 mmHg in the right eye and 13 mmHg in the left eye. The patient was orthophoric for distance and Nature. Slit-lamp examination revealed normal anterior segments. Fundus examination revealed myelinated fibers bilaterally, contiguous with optic discs [Figures 1a and 2a]. The blood vessels and fovea were normal. The macula and nasal retina were not myelinated. Optical coherence tomography (Spectralis; Heidelberg Engineering GmbH, Heidelberg, Germany) indicated thickened retinal nerve fiber layer in the myelinated area of both eyes [Figures 1b and 2b]. The anterior chamber depth was 2.82 in the right eye and 2.94 in the left eye (IOLMaster) he patient is unknown to have systemic diseases. The mean keratometry reading was 44 in the right eye and 44.1 in the left eye, and the corneal diameter was 12 in the right eye and 12.1 in the left eye (Pentacam®). A-scan biometry revealed

<sup>1</sup>Department of Ophthalmology, College of Medicine, Majmaah University, Al Majma'ah, <sup>2</sup>Anterior Segment Division, King Khaled Eye Specialist Hospital, Riyadh, <sup>3</sup>Department of Ophthalmology, College of Medicine, Tabuk University, Tabuk, Saudi Arabia

**Address for correspondence:**  
Dr. Saad H. Alenezi,  
Department of Ophthalmology,  
College of Medicine, Majmaah  
University, P.O. Box 66,  
Majmaah 11952, Saudi Arabia.  
E-mail: dr.saadhamdan@gmail.com

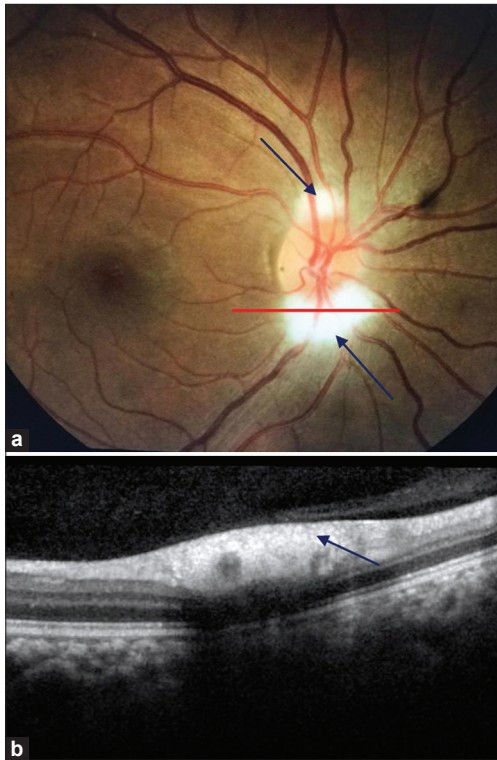
Submitted: 29-Dec-2019

Revised: 06-Jun-2020

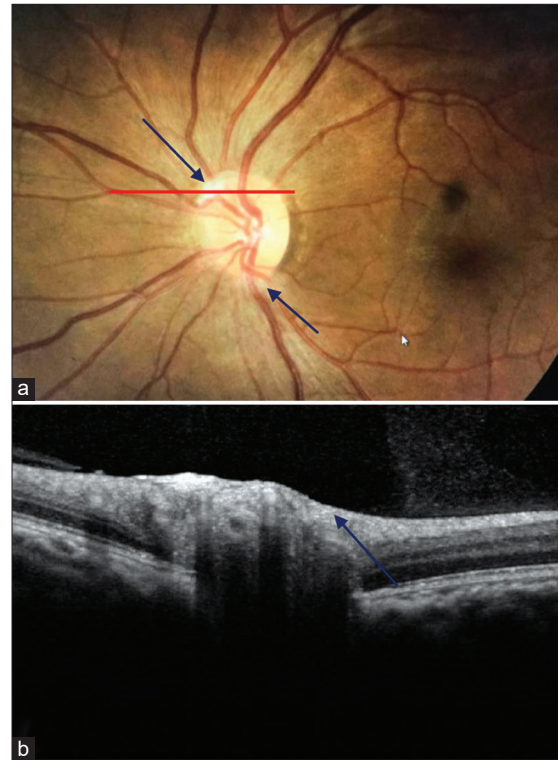
Accepted: 17-Aug-2020

Published: 27-Feb-2021

**How to cite this article:** Alenezi SH, Al-Shabeeb R, AlBalawi HB, Al-Swailem SA. Bilateral myelinated nerve fiber layers, high hyperopia, and amblyopia. Saudi J Ophthalmol 2020;34:209-11.



**Figure 1:** (a) Right eye showing myelinated nerve fiber layers (arrow) at the superior and inferior poles of the optic disc; (b) optical coherence tomographic image of the right eye (Spectralis) showing a thickened retinal nerve fiber layer in areas of myelination



**Figure 2:** (a) Left eye showing myelinated nerve fiber layers (arrow), superior more than inferior of the optic disc; (b) optical coherence tomographic image of the left eye (Spectralis) showing a thickened retinal nerve fiber layer in areas of myelination

an axial length of 19.36 mm in the right eye and 19.46 mm in the left eye.

## DISCUSSION

In a series of 3968 consecutive autopsies, myelinated nerve fibers of the retina were noted in 39 (0.98%) cases and bilateral in three (7.7%) affected cases.<sup>[1]</sup> MNFL is a congenital anomaly consisting of abnormal myelination with ectopic oligodendrocyte-like cells in the retina.<sup>[2]</sup>

The pathogenesis of myelinated nerve fibers is unknown.<sup>[1]</sup> Some authors proposed that the imbalance between myelination and the formation of the lamina cribrosa results in extended myelination to intraocular optic nerve fiber and retina.<sup>[3]</sup> According to these authors, myopic eyes are predisposed to develop myelinated nerve fibers more than emmetropic eye due to blurring of retinal image which induces visual deprivation that prolongs lamina cribrosa development. However, it should be noted that based on large autopsy series, myelinated nerve fibers were not contiguous with the optic disc in 66% of eyes.<sup>[1]</sup> Furthermore, several reported cases of myelinated fibers do not have visual deprivation or significant myopia.<sup>[4,5]</sup> In the current case, the patient had axial hyperopia and myelinated nerve fibers in both eyes, which were contiguous with the optic disc. This case supports the theory of anomalous distribution of oligodendrocytes as an etiologic factor.<sup>[1,6]</sup>

MNFLs are more common in myopic eyes.<sup>[1,2,7]</sup> The presence of MNFL with hyperopia and amblyopia is rare. Previous reported cases of MNFL and hyperopia had axial length within the normal range (AL ranged between 21.3 and 23).<sup>[5,6,8]</sup> However, our patient had high hyperopia which was axial in nature (AL OD: 19.36; OS: 19.46) with normal anterior chamber depth and corneal diameter. This finding may refute the existing relationship between myelinated nerve fibers and myopia. Amblyopia associated with the presence of MNFL could be functional, anisometric, or organic due to associated macular or ocular anomalies.<sup>[7,8]</sup>

Hittner and Antoszyk<sup>[9]</sup> observed that in the presence of MNFL and anisometropia, the most critical factor for predicting visual acuity was the appearance of the macula; abnormal maculae were found in eyes that responded poorly to amblyopia treatment. Our patient did not have myopia, and the myelinated nerve fibers were around the optic disc with normal macula.

Lempert<sup>[10]</sup> reported that eyes with amblyopia have shorter axial length and smaller optic disc when compared with that of nonamblyopic fellow eyes. This was observed in our patient in both eyes, indicating that the ametropia was axial in nature. Our case suggests that ametropia can be a more powerful influence on visual acuity than the presence of MNFL.

In conclusion, the presence of bilateral MNFL associated with axial hyperopia is rare. Ametropia seems to have a stronger influence on the relative visual acuity of each patient's eyes than the presence of retinal nerve fiber myelination. Early detection of ametropia and correction with glasses might prevent further deterioration of vision.

### Financial support and sponsorship

Nil.

### Conflicts of interest

There are no conflicts of interest.

### REFERENCES

1. Straatsma BR, Foos RY, Heckenlively JR, Taylor GN. Myelinated retinal nerve fibers. *Am J Ophthalmol* 1981;91:25-38.
2. Tarabishy AB, Alexandrou TJ, Traboulsi EI. Syndrome of myelinated retinal nerve fibers, myopia, and amblyopia: A review. *Surv Ophthalmol* 2007;52:588-96.
3. Lee MS, Gonzalez C. Unilateral peripapillary myelinated retinal nerve fibers associated with strabismus, amblyopia, and myopia. *Am J Ophthalmol* 1998;125:554-6.
4. Ruttum MS, Poll J. Unilateral retinal nerve fiber myelination with contralateral amblyopia. *Arch Ophthalmol* 2006;124:128-30.
5. Shenoy R, Bialasiewicz AA, Al Barwani B. Bilateral hypermetropia, myelinated retinal nerve fibers, and amblyopia. *Middle East Afr J Ophthalmol* 2011;18:65-6.
6. Lee JC, Salchow DJ. Myelinated retinal nerve fibers associated with hyperopia and amblyopia. *J AAPOS* 2008;12:418-9.
7. Munteanu M, Zolog I, Giuri S, Gamaniuc E. Unilateral myelinated nerve fibers associated with myopia or amblyopia. *Oftalmologia* 2002;53:61-6.
8. Wang Y, Gonzalez C. Unilateral myelinated nerve fibers associated with hypertropia, strabismus and amblyopia? Reverse Straatsma Syndrome. *Binocul Vis Strabismus Q* 2008;23:235-7.
9. Hittner HM, Antoszyk JH. Unilateral peripapillary myelinated nerve fibers with myopia and/or amblyopia. *Arch Ophthalmol* 1987;105:943-8.
10. Lempert P. Optic nerve hypoplasia and small eyes in presumed amblyopia. *J AAPOS* 2000;4:258-66.