

# Lichenoid Drug Eruption following Intravenous Application of Orally Formulated Diamorphine, a Semisynthetic Heroin

I. Kolm N. Eggmann J. Kamarashev K. Kerl L.E. French  
G.F.L. Hofbauer

Department of Dermatology, University Hospital Zurich, Zurich, Switzerland

## Key Words

Lichen planus · Drug eruption · Diamorphine · Synthetic heroin

## Abstract

**Background:** Lichen planus is a common skin disorder of unknown etiology. Most cases are idiopathic, but substances such as gold, antimalarials, penicillamine, thiazide diuretics,  $\beta$ -blockers, arsenic and nonsteroidal anti-inflammatory drugs have been implicated as trigger factors. **Case Presentation:** We report the case of a lichenoid eruption in a male drug addict who administered oral heroin (diamorphine) intravenously. Diamorphine was stopped immediately. Following topical steroids, phototherapy and oral acitretin, the lesions gradually disappeared. A lymphocyte transformation test was negative for pure morphine and codeine. **Discussion:** A coincidental association between the intravenous application of orally formulated semisynthetic heroin and the lichenoid eruption cannot be completely ruled out. However, the diagnosis of a lichenoid drug eruption is favoured over idiopathic lichen planus because of the clear chronological correlation between drug use and appearance as well as drug withdrawal and disappearance of the skin lesions, and because of a flare-up following repeated intravenous application of diamorphine.

© 2013 S. Karger AG, Basel

## Case Presentation

We report the case of a 40-year-old male intravenous drug abuser who presented to our outpatient clinic with a 2-week history of pruritic skin eruption on his palms and soles. The patient worked part-time as a carpenter and related the appearance of the skin lesions to

Isabel Kolm, MD  
Department of Dermatology, University Hospital Zurich  
Gloriastrasse 31  
CH-8091 Zurich (Switzerland)  
E-Mail [Isabel.Kolm@usz.ch](mailto:Isabel.Kolm@usz.ch)

exposure to a cleaning agent the previous day when he was working barefoot and with ungloved hands. On clinical examination, he presented with multiple, erythematous, flat-topped, lightly scaly, pruritic papules on his palms and soles, with a predilection for the wrists (fig. 1). Painless, white, nonremovable streaks (leukokeratosis) were also seen on the mucosa of the cheeks. A rash consisting of small polygonal papules affecting the rest of the body's surface was additionally observed (fig. 2).

The patient had been an intravenous heroin abuser for many years and had enrolled in an outpatient opiate-based support program. In this context, he was dispensed oral semisynthetic diamorphine (Diaphin®) under supervision. On repeated questioning, he revealed that he had administered the provided synthetic oral heroin intravenously for the last 6 months on a regular basis. He used to dissolve the tablets in water and heat the mixture before injecting it intravenously. He stated that he was additionally using 'street' heroin from time to time. Apart from diamorphine and street heroin, he was not taking any other illegal drugs or medication.

Our clinical differential diagnosis included a contact allergy to a cleaning agent, a sudden aggravation of an underlying atopic dermatitis, palmoplantar psoriasis, and lichen planus. The histopathologic examination of the samples taken from the right sole showed hyperkeratosis and irregular acanthosis with a band-like dermal infiltrate at the dermo-epidermal junction with eosinophilic colloid bodies and melanophages, consistent with a diagnosis of lichen planus (fig. 3). A biopsy taken from the patient's back also revealed lichenoid changes showing focal interface dermatitis with lymphocytes at the dermo-epidermal junction and slight vacuolization of keratinocytes (fig. 4).

Extensive blood workup, including screening for HIV, HBV, HCV and syphilis, was within normal limits except for slightly elevated liver transaminases. Total IgE was moderately elevated at 565 kU/l. Urine drug screening was negative except for methadone and opioids.

A contact allergy to disinfectants, metals and resins was excluded by patch testing. Because of the possible relationship of lichen planus with drugs, Diaphin was discontinued and replaced by orally formulated methadone and morphine. A lymphocyte transformation test to measure drug-specific T cells was performed. Oral Diaphin was not available for testing. The lymphocyte transformation test was thus performed using pure morphine and codeine and was negative. An allergic reaction to Diaphin could not be excluded or confirmed by testing. Nevertheless, in a self-experiment the patient once again administered the oral formulation of diamorphine intravenously and noticed immediate worsening of the skin lesions and swelling of the hands.

The patient was treated with topical steroids, phototherapy with narrowband UVB (311 nm) and oral antihistamines. Because of the intense skin involvement, systemic therapy with acitretin (Neotigason®) was initiated. Due to side effects (headache and nausea), the initial daily acitretin dose of 25 mg was reduced to 10 mg per day. All treatments (acitretin, phototherapy and topical steroids) were discontinued by the patient after 2–3 months and replaced by emollients only. The lichenoid skin changes on his body, palms and soles completely resolved within the following 6 months.

## Discussion

Diamorphine (diacetylmorphine) is a semisynthetic opioid drug synthesized from morphine. Diamorphine tablets seem to be an effective and safe mode of application of diamorphine in the context of heroin substitution [1]. In Switzerland, diamorphine is dispensed to a highly selected, registered group of severely addicted, long-term intravenous

opioid abusers. Diamorphine frequently causes hypersensitivity reactions like urticarial reactions (hives) or itching due to histamine liberation.

Lichen planus is a common skin disorder of unknown etiology. Most cases of lichen planus are idiopathic, but a wide range of substances such as gold, antimalarials, penicillamine, thiazide diuretics,  $\beta$ -blockers, arsenic and nonsteroidal anti-inflammatory drugs have been implicated as triggering agents [2]. A latency period of several months from introduction of the causative drug to presentation of lichenoid skin lesions usually occurs. The time course from drug cessation to resolution of the skin lesions ranges from several weeks to months.

Differentiating drug-induced lichen planus from the idiopathic form is difficult. In idiopathic lichen planus, flat-topped, shiny, violaceous papules with Wickham's striae and a predilection for the wrists, flexures, genitalia and mucous membranes are seen. It has been described that drug-induced lichen planus may appear psoriasiform or eczematous, rarely involves the mucosae and affects older patients and photoexposed areas [1, 3]. Histopathologic findings including the presence of plasma cells, neutrophils and eosinophils in the cellular infiltrate, focal eosinophils with a thin epidermis and hypogranulosis, and a superficial and deep perivascular infiltrate are features associated more commonly with drug-induced lichen planus [1, 4].

We lack specific allergy tests supporting our clinical diagnosis of a lichenoid drug eruption in our patient. A coincidental association between the intake of the semi-synthetic heroin and the lichenoid eruption cannot be completely ruled out. However, the diagnosis of a lichenoid drug eruption is favoured over idiopathic lichen planus because of the closely linked onset of the disease and the complete resolution after withdrawal of drug as well as the flare-up after repeated intravenous application of oral diamorphine. The presence of eosinophils and neutrophils in the dermal perivascular infiltrate in the histopathologic specimens is another finding in favour of a lichenoid drug eruption.

Potential eliciting agents comprise diamorphine itself, another component of the preparation, contaminating agents of the self-made intravenous formulation or possibly another illicit drug intake [5, 6]. As the repeated intravenous application of oral diamorphine caused a flare-up of the lichenoid eruption, we conclude that this particular oral formulation of diamorphine is most likely to have caused the lichenoid drug eruption in our patient following intravenous application. In conclusion, drugs should be strictly applied as formulated, and routes of administration should not be interchanged.

### Disclosure Statement

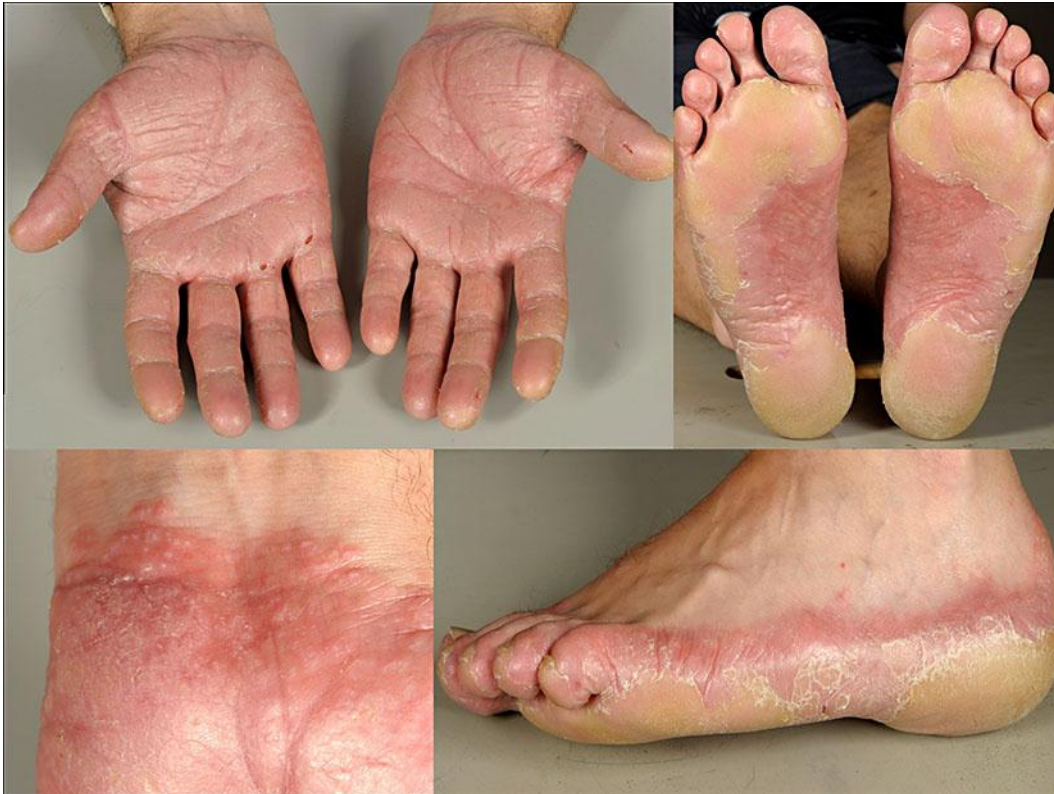None.

### References

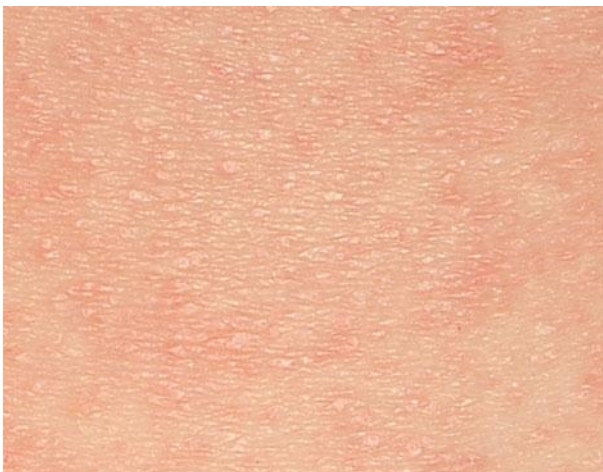- 1 Powell ML, Ehrlich A, Belsito DV: Lichenoid drug eruption to salsalate. *J Am Acad Dermatol* 2001;45:616–619.
- 2 Thompson DF, Skaehill PA: Drug-induced lichen planus. *Pharmacotherapy* 1994;14:561–571.
- 3 Majmudar V, Al-Dulaimi H, Dodd H: Lichenoid drug eruption secondary to treatment with nicorandil? *Clin Exp Dermatol* 2008;33:193–194.
- 4 Van den Haute V, Antoine JL, Lachapelle JM: Histopathological discriminant criteria between lichenoid drug eruptions and idiopathic lichen planus: retrospective study on selected samples. *Dermatologica* 1989;179:10–13.
- 5 Hofbauer GF, Burg G, Nestle FO: Cocaine-related Stevens-Johnson syndrome. *Dermatology* 2000;201:258–260.

Kolm et al.: Lichenoid Drug Eruption following Intravenous Application of Orally Formulated Diamorphine, a Semisynthetic Heroin

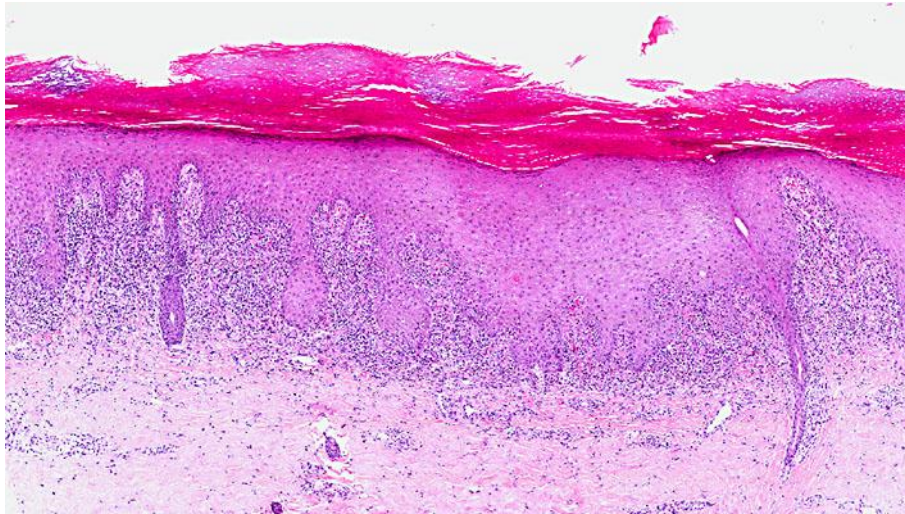
- 6 Hofbauer GF, Hafner J, Trüeb RM: Urticarial vasculitis following cocaine use. *Br J Dermatol* 1999;141:600–601.



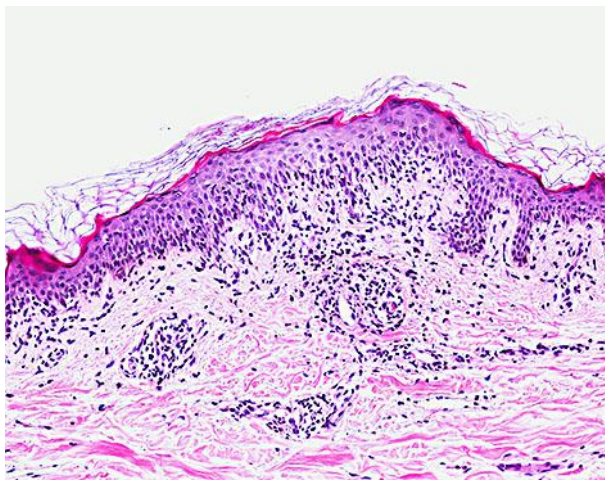
**Fig. 1.** Swollen palms and soles with thick, infiltrated hyperkeratotic plaques; at the borders red-violaceous, well-circumscribed papules are covered with superficial fine white lines.



**Fig. 2.** Multiple, small, erythematous, flat-topped papules cover the entire surface of the body, sparing the head.



**Fig. 3.** A biopsy taken from the right sole shows acanthosis, hyperkeratosis, hypergranulosis and a band-like lymphocytic infiltrate at the dermo-epidermal junction with eosinophilic colloid bodies and melanophages, consistent with a diagnosis of lichen planus.



**Fig. 4.** A biopsy taken from the patient's back shows focal interface dermatitis with lymphocytes at the dermo-epidermal junction and vacuolization of keratinocytes.