

Modified Double-Eyelid Blepharoplasty Using the Single-Knot Continuous Buried Non-Incisional Technique

Kyung-Chul Moon, Eul-Sik Yoon, Jun-Mun Lee

Department of Plastic and Reconstructive Surgery, Korea University Anam Hospital, Korea University College of Medicine, Seoul, Korea

Background Buried non-incisional double-eyelid blepharoplasty is a popular aesthetic procedure. Although various modified continuous suture techniques have been used to create a more natural appearance and to reduce downtime, complications such as loosening of the double fold, asymmetry, and foreign body reactions have been observed.

Methods This study included 250 patients who underwent double-eyelid blepharoplasty between March 1997 and November 2012 using a modified single-knot continuous buried non-incisional technique. With 4 stab incisions in the upper eyelids, one of two needles loaded with double-armed 7-0 nylon was passed in one direction alternately through the dermis and the conjunctiva, while the other needle was passed subconjunctivally in the opposite direction. Both ends of the sutures were knotted within a lateral stab incision of the upper eyelids and were buried in the orbicularis oculi muscle.

Results Most patients displayed satisfactory aesthetic results, and no significant complications occurred. There was no obvious regression of the double fold; however, 3 patients required reoperation to correct loosening of the fold on one side during the follow-up period. One patient presented with the suture knot subcutaneously, and the knot was removed in the clinic.

Conclusions The modified single-knot continuous buried non-incisional technique is a simple and less time-consuming method for a durable double fold and provides satisfactory aesthetic results.

Keywords Eyelids / Blepharoplasty / Sutures

Correspondence: Eul-Sik Yoon
Department of Plastic and Reconstructive Surgery, Korea University Anam Hospital, Korea University College of Medicine, 73 Incheon-ro, Seongbuk-gu, Seoul 136-705, Korea
Tel: +82-2-920-5440
Fax +82-2-922-7437
E-mail: yesanam2@korea.ac.kr

No potential conflict of interest relevant to this article was reported.

Received: 1 Mar 2013 • Revised: 13 May 2013 • Accepted: 17 Jun 2013
pISSN: 2234-6163 • eISSN: 2234-6171 • <http://dx.doi.org/10.5999/aps.2013.40.4.409> • Arch Plast Surg 2013;40:409-413

INTRODUCTION

Eyelids have a large impact on first impressions based on appearance and contribute to an individual's expression of emotion. The double-eyelid blepharoplasty trend has changed in recent years, and it is difficult to define absolute criteria for aesthetically pleasing eyelids. However, double-eyelid blepha-

roplasty is continuing to gain popularity among Asian women. Consequently, in Asia, this surgery has been used to create a more natural appearance and bright eyes, rather than large eyes like those of Caucasians.

Non-incisional surgery is the preferred method for double-eyelid blepharoplasty because of advantages such as its inconspicuous scar, and it is simple, more easily revised, causes

less edema, and allows for a faster recovery. However, it has common complications such as loosening of the double fold, asymmetry, and inclusion cyst due to a buried stitch. To reduce the impact of these disadvantages, various modified suture techniques have been developed, such as continuous buried suture double-eyelid blepharoplasty. The purpose of this study is to introduce a modified single-knot continuous buried non-incisional technique.

METHODS

This study included a total of 250 patients who visited Korea University Hospital between March 1997 and November 2012 and underwent the modified single-knot continuous buried non-incisional technique. The mean age of the patients was 25.1 ± 8.3 years (range, 9 to 44 years); 229 patients were women, and 21 patients were men. In this series, 98 out of 250 patients underwent long-term follow-up ranging from 1 week to 5 years.

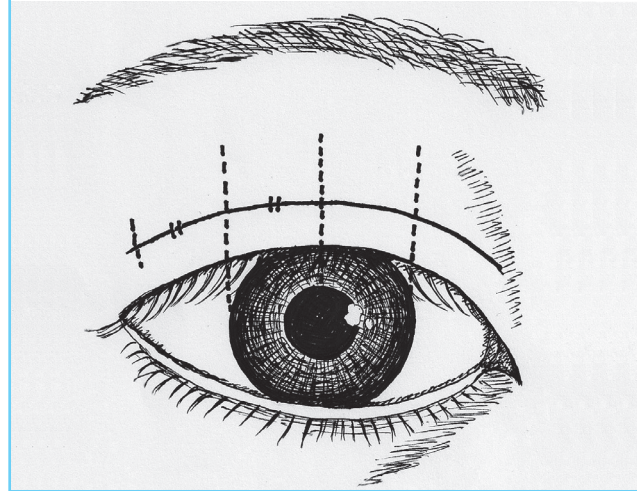
The primary criteria for this modified technique were as follows: 1) no drooping of the eyelid skin or muscles, 2) small fat pads anterior to the tarsal plate, and 3) the desire for early recovery and natural double eyelids. Exclusion criteria were 1) dermatochalasis or blepharoptosis of the upper eyelids, 2) obvious skin redundancy, and 3) excessively puffy eyelids. All of the patients provided written informed consent before the surgical procedures and outcome analysis.

Surgical technique

The operation was performed under local anesthesia. The preoperative design was based on the potential upper eyelid crease line, and the height and shape of the double fold were determined during a consultation by using a lacrimal probe in the sitting position. First, 3 vertical lines were marked on the upper eyelids: at the medial limbus, mid-pupil, and lateral limbus. In addition, an imaginary fourth vertical line was marked at the same interval laterally. Thereafter, 4 entry points at the intersections between the vertical lines and the imaginary crease were marked using gentian violet with minor modification to ensure symmetry. The design was based on the patient's favored eyelid position, and the height of the double fold was generally defined at approximately 6-8 mm from the upper lid margin (Fig. 1). After the double fold line was designed, topical proparacaine hydrochloride drops were administered 3 times on both corneas, a solution of 2% lidocaine containing 1:100,000 epinephrine was injected into the dermal and conjunctival layers at the 4 entry points, and the eyelids were compressed mildly to prevent hematoma. At each of the 4 points, a 1-mm stab incision extending from the skin to the orbicularis oculi muscle was made, using a

Fig. 1. Four entry points during the design

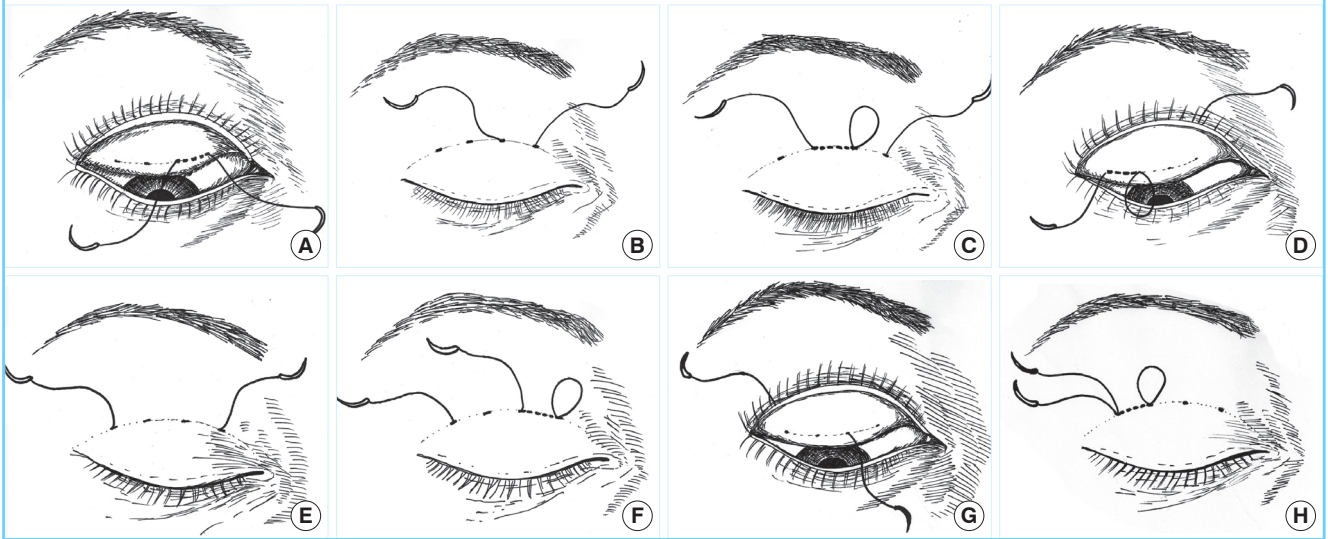
Vertical dotted lines indicate the medial limbus, mid-pupil, and lateral limbus positions, and the fourth vertical line is marked at the same distance laterally. The points of intersection between the vertical line and the imaginary crease are marked with gentian violet.




No. 11 blade. A small amount of the periorbital fat pad was removed from the lateral stab incision at the surgeon's discretion. Regardless of whether fat was removed or not, the most lateral side of the stab incision was made deep into the muscle layer to bury the knot. With 4 stab incisions on the upper eyelids, one of two double-armed needles loaded with 7-0 nylon (Ethilon, Ethicon, Somerville, NJ, USA) was continuously passed through the dermis and the conjunctiva alternately from the medial side to the lateral side. First, the upper eyelid was everted, and one end of the needle was passed through the full thickness of the upper eyelid to the conjunctiva corresponding to the medial stab incision and subsequently through the conjunctiva horizontally above the upper border of the tarsal plate (Fig. 2A); the needle was then withdrawn to the second stab incision (Fig. 2B). It was passed through the subdermal layer of the upper eyelid and pulled out to the third stab incision (Fig. 2C), and subsequently through the conjunctiva corresponding to the third stab incision. The needle was again passed subconjunctivally to the conjunctival point corresponding to the fourth lateral stab incision (Fig. 2D). The needle was passed through the eyelid to exit through the lateral stab incision (Fig. 2E). The other needle was passed subdermally from the medial skin incision to the second stab incision (Fig. 2F), and through the conjunctiva (Fig. 2G). The needle was passed through subconjunctivally in the mirror route in the same manner. After the two arms of the needle exited above the fourth lateral stab incision (fixation point), the surgeon pulled them with controlled tension and decided on the appropriate tension for the double fold (Fig. 2H). The two ends of the suture were true-tied with appropriate tension using

Fig. 2. Serial illustration of the double-eyelid blepharoplasty

(A) The lid is everted, and one end of the suture is inserted at the conjunctiva corresponding to the medial skin incision and passed subconjunctivally above the superior tarsal border; then the needle is withdrawn at the point on the conjunctiva on the opposite side of the second skin incision. (B) Through the same points (conjunctival opening), each arm of the suture is passed through the lid and exits the skin through the second stab incisions. (C) The needle is passed through the dermal layer to exit through the next stab incision. (D) The needle is passed back through the lid, entering through the same points on the conjunctival surface. (E) The needle is passed through the lid to exit through the lateral stab incision. (F) The other needle is passed through the dermis from the medial stab incision to the second stab incision. (G) The other needle is passed through the lid in the same manner. (H) The two ends are tied in the lateral stab incision, and the knot is buried within the orbicularis oculi muscle.

**Fig. 3. Cross-sectional view of the suture**

After true-tying of the two arms of the needle, the knot is buried within the orbicularis oculi muscle.



a 26-gauge needle on the lateral side of the stab incision, and the knot was buried within the orbicularis oculi muscle (Fig. 3). When the knot was placed on the superficial layer of the orbicularis oculi muscle after removal of a 26-gauge needle, the appropriate tension was determined. The lateral stab incision sites were repaired with the remaining 7-0 nylon, and eye ointment was applied at the incision sites. One day postoperatively, the patient was checked for complications such as hematoma, infection, and asymmetry. The patients visited the clinic 1 week and again 1 month postoperation, and photographs were taken on each visit. Photographs were taken at 1 month for 81 patients, and 18 patients were followed up at more than 1 month postoperatively.

RESULTS

During the past 15 years, most of the patients in our series have displayed satisfactory aesthetic results, and no significant complications have occurred (Figs. 4, 5). Of these patients, 51 underwent double-eyelid blepharoplasty with simultaneous medial epicanthoplasty, and 34 patients had periorbital fat removed from the lateral stab incision site. The mean surgical time was 20 ± 7 minutes. There was no obvious regression of the double fold line; however, revisions were performed on 3 patients (1.2%) to correct loosening of a unilateral fold. During the follow-up period, asymmetry was found in 5 patients (2.0%); however, the patients did not complain about the asymmetry, and no revisions were needed. There were no potential complications such as chalazion-like suture granuloma or inclusion cyst caused by foreign material. In 1 patient, the knot could be observed subcutaneously; therefore, it was removed in the clinic during the follow-up period. The double fold was maintained after the removal of the knot; thus, there was no need for a second procedure.

DISCUSSION

A double fold is established during contraction of the levator palpebrae superioris muscle by which the levator aponeurosis

Fig. 4. Before and 2 months after the procedure

(A) Appearance before the procedure. (B) Appearance 2 months after the procedure.

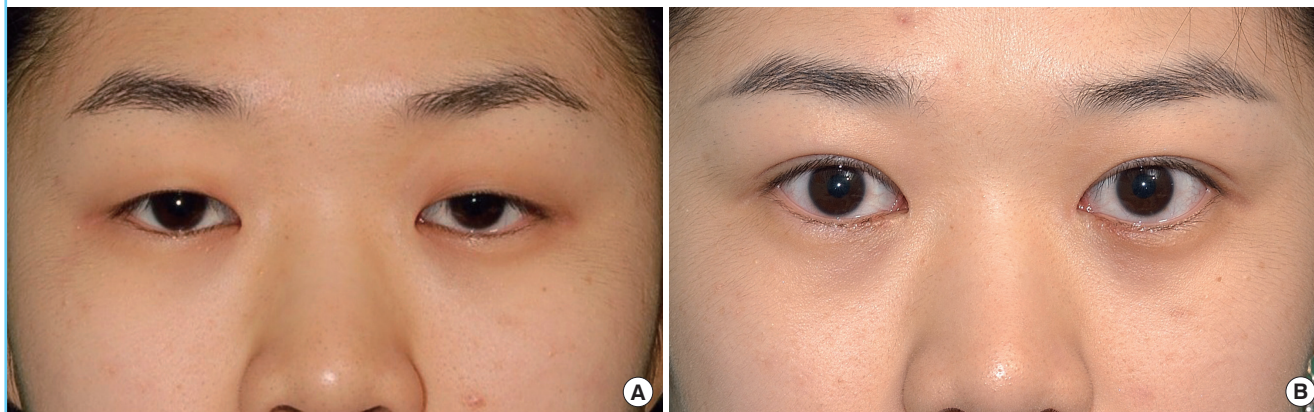
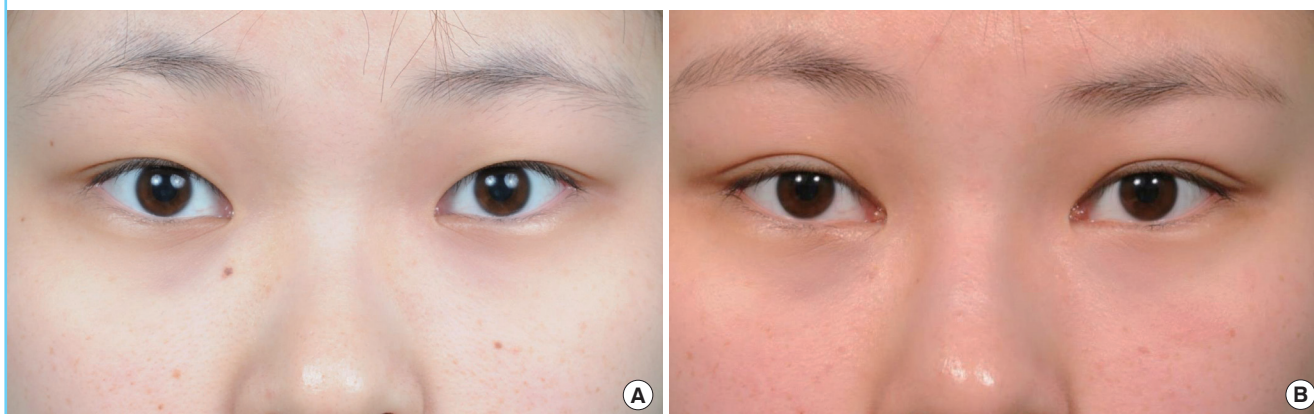


Fig. 5. Before and 2 years after the procedure

(A) Appearance before the procedure. (B) Appearance 2 years after the procedure.



penetrates the orbicularis oculi muscle, advancing to the dermal area anterior to the tarsal plate [1]. Generally, ethnic East Asians do not have double folds because the levator aponeurosis does not reach the skin of the upper eyelid. Although the incidence of the double fold is controversial, it is known to be 30% to 60% in the Republic of Korea [2]. Therefore, double-eyelid blepharoplasty is one of the most popular aesthetic surgeries in East Asia, including Korea.

Non-incisional double-eyelid blepharoplasty was introduced by Mikamo [3], who used a 3-suture method in 1896. This method used silk sutures placed 6 to 8 mm superior to the upper eyelid margin and the depth of the double fold depended on the day of suture removal 2-6 days postoperatively because in this procedure, the knot was not buried [3]. In 1926, Uchida used catgut in 3-suture buried double-eyelid blepharoplasty [4], and in 1929, Maruo reported a 2-way continuous buried suture method [5]. Non-incisional double-eyelid blepharoplasty has been modified gradually since then, and various methods have

been reported in the literature. In the non-buried method, the suture is placed through the skin to the tarsal plate or to the upper border of the tarsal plate, tied above the skin, and removed after a few days; this method is simple. However, the double fold may appear loose after the sutures are removed. In contrast, the buried non-incisional technique is widely used because it does not require suture removal and causes less scarring [1].

The continuous buried method using double-arm suture is adapted from the Maruo method; one of 2 arms of the suture is passed through the dermis and conjunctiva alternately in an S-shaped course; the other arm of the needle is passed in the same manner, and both arms are tied on the lateral side. Thus, 4 loop sutures create the double fold. This method was used only in the 1940s [1,6]. The authors' method is the same concept as the Maruo method up to the point of the continuous buried method through the upper eyelid. In addition, the authors' method is similar to Boo-Chai's full-thickness suture technique up to the point of the formation of 1 loop. Hwang et al. [7] reported that

the distortion of the continuous suture method was significantly less than that with the interrupted suture method. The authors' method is more substantial and stable compared with the previous figure 8-shaped continuous methods and the single-knot is definitely buried in the orbicularis oculi muscle to reduce knot-related complications.

One of the main complications of the buried-knot method is loosening of the double fold. Homma et al. [8] reported that the incidence varied (1.31% to 16.8%); the incidence was 1.31% using a 2-suture method and 3.43% using a 1-suture method. Ko et al. [9] reported that there was no difference in the reoperation rate due to the loss of the double eyelid among the 1-, 2-, and 3-suture methods. In addition, the incidence of inclusion cysts was 3.2% with the 2-suture method and 1.7% with the 1-suture method [8]. In summary, the 1-suture method increases the double fold loosening rate but decreases the inclusion cyst rate. Therefore, the authors' single knot decreases the cystoma and inclusion cyst rate, and there were no cystomas or inclusion cysts reported in our series.

The advantage of the authors' method is the ability to remove fat and orbicularis oculi muscle tissue through the stab incision, if needed. Lee et al. [10] reported good results with the continuous buried 3-looped method wherein the soft tissues, such as orbicularis oculi muscle tissue anterior to the tarsal plate and periorbital fat, were removed through 3 stab incisions. In addition, removal of pretarsal tissue such as orbicularis, pretarsal fat, and orbital fat enhances the durability of the double fold after buried double-eyelid blepharoplasty because it results in direct contact between the dermis and the tarsal plate [11-13]. However, adhesion and inappropriate volume result in unwanted triple folds, and excessive excision of the orbicularis oculi muscle may result in the development of a triple-fold line; thus, the authors excise the lateral pretarsal fat, and unnecessary manipulations are never performed [14].

In conclusion, the single-knot continuous buried non-incisional technique creates a more natural appearing double-eyelid line, even when patients close their eyes. In addition, the number of buried sutures should be minimized because this decreases suture-associated complications and surgical time. Further, this technique may correct the double fold line with the second suture after one of the needles passes through the double fold line and the author predicts the line. The authors' 12-years of experience with the modified single-knot continuous buried non-incisional technique shows that it is a simple and less time-consuming method for producing a durable double fold and provides better surgical outcomes with no serious complications.

REFERENCES

1. Baik BS, Park DH. Cosmetic and reconstructive oculoplastic surgery. Seoul: Koonja; 2003.
2. Baek SM, Kim SS, Tokunaga S, et al. Oriental blepharoplasty: single-stitch, nonincision technique. *Plast Reconstr Surg* 1989;83:236-42.
3. Mikamo M. Mikamo's double-eyelid operation: the advent of Japanese aesthetic surgery. 1896. *Plast Reconstr Surg* 1997;99:664.
4. Shirakabe Y, Kinugasa T, Kawata M, et al. The double-eyelid operation in Japan: its evolution as related to cultural changes. *Ann Plast Surg* 1985;15:224-41.
5. Wu W. A two-way continuous buried-suture approach. *Aesthetic Plast Surg* 2009;33:426-9.
6. Song RY, Song YG. On double eyelid operation. *Zhonghua Zheng Xing Shao Shang Wai Ke Za Zhi* 1985;1:3-8.
7. Hwang K, Kim DH, Huan F. Tension and distortion of the upper double eyelid by a nonincision method. *J Craniofac Surg* 2012;23:886-9.
8. Homma K, Mutou Y, Mutou H, et al. Intradermal stitch blepharoplasty for orientals: does it disappear? *Aesthetic Plast Surg* 2000;24:289-91.
9. Ko RY, Baek RM, Oh KS, et al. Complication of non-incision oriental blepharoplasty: is disappearance of the lid crease a fearful complication? *J Korean Soc Plast Reconstr Surg* 2000;27:199-203.
10. Lee YJ, Baek RM, Chung WJ. Nonincisional blepharoplasty using the debulking method. *Aesthetic Plast Surg* 2003;27:434-7.
11. Zhang MY, Yang H, Ding SL, et al. Construction of a double eyelid: an uncut strip of orbicularis removed through three mini-incisions. *Aesthetic Plast Surg* 2013;37:22-8.
12. Zhang MY, Yang H, Li CY, et al. Removal of a large amount of pretarsal tissue through three mini incisions in the construction of a double eyelid. *Aesthetic Plast Surg* 2012;36:1039-46.
13. Mizuno T. Two modified techniques to decrease complications of buried suture double-eyelid blepharoplasty. *J Plast Reconstr Aesthet Surg* 2013;66:e95-100.
14. Lew DH, Kang JH, Cho IC. Surgical correction of multiple upper eyelid folds in East Asians. *Plast Reconstr Surg* 2011;127:1323-31.