



Since January 2020 Elsevier has created a COVID-19 resource centre with free information in English and Mandarin on the novel coronavirus COVID-19. The COVID-19 resource centre is hosted on Elsevier Connect, the company's public news and information website.

Elsevier hereby grants permission to make all its COVID-19-related research that is available on the COVID-19 resource centre - including this research content - immediately available in PubMed Central and other publicly funded repositories, such as the WHO COVID database with rights for unrestricted research re-use and analyses in any form or by any means with acknowledgement of the original source. These permissions are granted for free by Elsevier for as long as the COVID-19 resource centre remains active.

Rare and Unusual Follow-up Sequelae of Coronavirus Disease 2019: Splenic Mucormycosis in a Renal Transplant Recipient

Hari Shankar Meshram^a, Deepak Kumar^{b*}, and Vivek B. Kute^a

^aDepartment of Nephrology, Institute of Kidney Diseases and Research Centre, Dr H.L. Trivedi Institute of Transplantation Sciences, Ahmedabad, Gujarat, India; and ^bDepartment of Nephrology, Paras HMRI Hospital, Patna, Bihar, India

ABSTRACT

Background. Coronavirus disease 2019 (COVID-19) is associated with adverse outcomes in transplantation communities. Mucormycosis, although a rare infection, has been classically linked to organ transplantation and is associated with exceptionally high morbidity and mortality rates. In this pandemic era, the double infection of mucormycosis and COVID-19 is a lethal combination but is rarely described in the literature on organ transplantation.

Case presentation. This article presents the case of a young kidney transplant recipient with diabetes who acquired severe COVID-19, followed by disseminated mucormycosis. The patient was a health care worker who developed severe COVID-19, for which he received remdesivir, anticoagulation, and dexamethasone. No immunomodulatory therapy was used. His maximum oxygen support was bilevel positive airway pressure ventilation. His sugar levels were frequently deranged during the stay. He developed secondary sepsis with *Klebsiella*, followed by nonhealing lung consolidation. He later developed pleural effusion and splenic abscess, which was detected incidentally. He underwent an emergency splenectomy, the culture of which yielded mucormycosis. Liposomal amphotericin B 5 mg/kg was administered. The patient deteriorated, and a repeat laparotomy yielded gastric perforation, with pus culture showing mucormycosis. The patient died after a long hospital stay.

Conclusions. The diagnosis and management of this dual infection during the pandemic is extremely challenging. In this case, the unusual location of mucormycosis complicating COVID-19 calls for a meticulous approach to opportunistic fungal infections in organ transplant recipients who are positive for COVID-19, especially in those patients with diabetes.

Organ transplantation is an established risk factor for coronavirus disease 2019 (COVID-19) morbidity and mortality [1]. Mucormycosis is well described as an opportunistic infection that is exclusive to individuals who are immunosuppressed and therefore more prone to the dual infection of COVID-19 and mucormycosis during the pandemic. COVID-19 outcomes in organ transplantation have been extensively reviewed, but data about mucormycosis complicating the COVID-19 course are majorly limited to the general population. In addition, there are only a few such reports on organ transplant recipients [2,3]. The logistics, diagnosis, and management of this dual infection are enormous, and so is the linked fatality. A multidisciplinary approach to the problem is required to improve the outcomes in such cases, but during the pandemic, this is a difficult task to accomplish. Recently, the Indian subcontinent dealt with the twin

crisis of mucormycosis and COVID-19 in the second wave of the pandemic [4,5]. This article describes the case of a patient with severe COVID-19 who developed disseminated mucormycosis in the follow-up period. This report aims to create awareness for such COVID-19 complications among transplant physicians, because the presentation of this entity was camouflaged.

CASE DESCRIPTION

A 41-year-old man with IgA nephropathy was transplanted 2 years previously with a brother donor and thymoglobulin

*Address correspondence to Dr Deepak Kumar, Department of Nephrology, Paras HMRI Hospital, Patna, Bihar, India. Tel: +91 8758688291. E-mail: deepak2k4sim@gmail.com

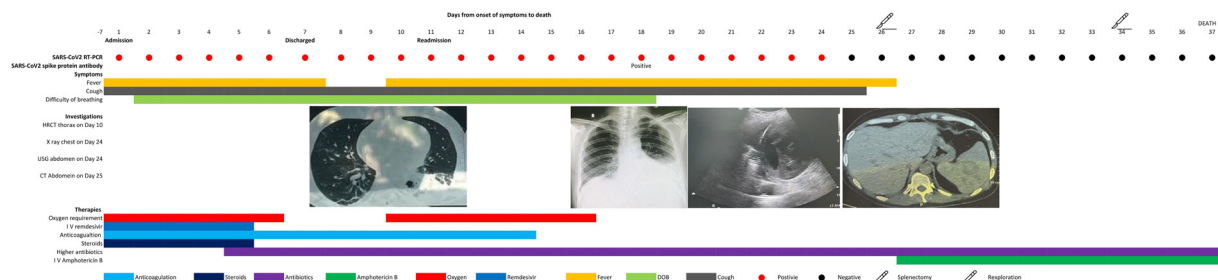


Fig 1. Detailed summary of the case.

induction (3 mg/kg). He had excellent graft function (baseline serum creatinine of 1.01 m/dL) and was on a combination of steroid 5 mg, mycophenolate 360 mg 3 times daily, and tacrolimus 0.05 mg/kg. He had developed post-transplant diabetes mellitus and had good glycemic control before COVID-19.

He was unvaccinated for COVID-19 and was admitted with symptoms of fever, cough, and breathlessness and was diagnosed with severe COVID-19. The mainstay of COVID-19 therapy was oxygen support (bilevel positive airway pressure was the highest oxygen support required), intravenous (IV) remdesivir, anticoagulation, and dexamethasone (8 mg once daily for 5 days). His blood sugars were frequently high during the stay. Laboratory markers indicated lymphopenia (300 cells/mm³), thrombopenia (80,000 cells/mm³), high ferritin levels (1239 ng/mL), high D-dimers (3400 mmol/L), high interleukin-6 levels (67 ng/mL), and high C-reactive protein (102 mg/L). Figure 1 shows the detailed summary of the case.

He developed secondary sepsis, evidenced by blood culture on day 6 of admission with *Klebsiella* sensitive to meropenem and colistin. He was discharged and had a homestay of 3 days before his readmission for persistent breathing difficulty. He had also been maintained on IV antibiotics at home. His repeat chest scans during this readmission reported necrotizing left lobe pneumonia, for which IV colistin was added. No prophylactic antifungal was added. Fever and dyspnea persisted even after appropriate antibiotics, so a chest radiography was repeated, which showed large left-sided effusion along with splenic abscess in concurrent abdominal sonography. He underwent emergency splenectomy, and the pus culture showed *Rhizopus* mucormycosis. He was started with IV liposomal amphotericin B 5 mg/kg for mucormycosis, but he developed secondary sepsis, fever, and abdominal tenderness, and so he was re-explored, which showed stomach perforation and pus drainage of around 500 mL. He died 2 days after surgery. The pus culture reported the same species of mucormycosis.

DISCUSSION

COVID-19 outcomes in renal transplantation patients have been vastly studied, but few data exist about the dual infection of mucormycosis and COVID-19 in transplant patients. The world has seen a surprisingly high number of this dual infection during the pandemic [6]. Multiple reasons exist for the surge of mucormycosis after COVID-19, but chronic

immunosuppression and diabetes are considered some possible reasons for this lethal combination in this case [7]. The delay in diagnosis also contributed to this patient's death. But, the unusual location of infection was unexpected in this case, and splenic mucormycosis is more difficult to diagnose than rhino cerebral mucormycosis, which has some obvious signs and symptoms. The nonremitting nature of fever in COVID-19, despite good antibiotic coverage, would have prompted us to look for an underlying fungal infection. Another important point is that that patient was unvaccinated for COVID-19. This underscores the importance of vaccination, especially for such high-risk patients. The novelty of this report is that there are no previously reported cases of splenic mucormycosis in a transplant patient with COVID-19. The most common presentation of mucormycosis during this pandemic is rhino-orbital. The unusual occurrence of mucormycosis in our report emphasizes the need for a meticulous approach in cases with persistent fever after COVID-19. We also suggest controlling sugars in a standardized manner, as steroids and stress from infection may lead to further deranged sugars in patients with COVID-19 patient. This step is important because some published literature of this dual infection lists diabetes as a comorbidity. The exact dosing of liposomal amphotericin B and tailoring of immunosuppression in such cases is not known, but the goal is to maintain a balance between infection and rejection. We consider older adults and patients with diabetes and severe COVID-19 to be most at risk for developing this dual infection during the pandemic. Therefore, we suggest screening for mucormycosis to all such organ transplant patients with COVID-19. The screening must include symptoms such as eye swelling, diplopia, face swelling, abdominal pain, black discharge from nose or mouth, and breathlessness after discharge. We also suggest all such prone discharged patients be properly informed about the danger signs of developing mucormycosis and look for any signs postdischarge.

CONCLUSIONS

In conclusion, mucormycosis in patients with COVID-19 is associated with high morbidity and mortality. A multidisciplinary approach to transplant patients with post-COVID-19 sequelae is required to avoid any undesirable consequences. Increasing awareness and timely treatment are the key steps in managing this dual infection.

REFERENCES

- [1] Kute VB, Bhalla AK, Guleria S, Ray DS, Bahadur MM, Shingare A, et al. Clinical profile and outcome of COVID-19 in 250 kidney transplant recipients: a multicenter cohort study from India. *Transplantation* 2021;105:851–60.
- [2] Meshram HS, Kute VB, Chauhan S, Desai S. Mucormycosis in post-COVID-19 renal transplant patients: a lethal complication in follow-up. *Transpl Infect Dis* 2021;23:e13663.
- [3] Arana C, Cuevas Ramírez RE, Xipell M, Casals J, Moreno A, Herrera S, et al. Mucormycosis associated with COVID-19 in two kidney transplant patients. *Transpl Infect Dis* 2021;23:e13652.
- [4] BBC. Mucormycosis: the black fungus hitting COVID-19 patients, <https://www.bbc.com/future/article/20210519-mucormycosis-the-black-fungus-hitting-indias-covid-patients>; 2021 [accessed 5.6.2021].
- [5] Patel A, Agarwal R, Rudramurthy SM, Shevkani M, Xess I, Sharma R, et al. Multicenter epidemiologic study of coronavirus disease –associated mucormycosis. India. *Emerg Infect Dis* 2021;27:2349–59.
- [6] Sen M, Lahane S, Lahane TP, Parekh R, Honavar SG. Mucor in a viral land: a tale of two pathogens. *Indian J Ophthalmol* 2021;69:244–52.
- [7] Song Y, Qiao J, Giovanni G, Liu G, Yang H, Wu J, et al. Mucormycosis in renal transplant recipients: review of 174 reported cases. *BMC Infect Dis* 2017;17:283.