

Case Report

Pure Autonomic Failure with Asymptomatic Hypertensive Urgency: A Case Report and Literature Review

Alwaleed Aljohar^a Taim Muayqil^b Abdulrahman Aldeeri^a
Anwar Jammah^a Ahmad Hersi^c Khalid Alhabib^c

^aDepartment of Internal Medicine, King Khalid University Hospital, King Saud University, Riyadh, Saudi Arabia; ^bDivision of Neurology, Department of Internal Medicine, King Khalid University Hospital, King Saud University, Riyadh, Saudi Arabia; ^cDepartment of Adult Cardiology, King Fahad Cardiac Center, King Saud University, Riyadh, Saudi Arabia

Keywords

Orthostatic hypotension · Pure autonomic failure · Supine hypertension · Ambulatory blood pressure monitoring · Saudi Arabia

Abstract

We report the case study of a 70-year-old gentleman who presented with isolated, slowly progressive dizziness after prolonged standing and was eventually diagnosed with pure autonomic failure. Initially, his symptoms improved with the use of midodrine and fludrocortisone, but gradually became refractory and disabling. Despite multiple therapeutic interventions, his symptoms persisted along with worsening supine hypertension. We discuss the challenges faced in the treatment of an uncommon condition and discuss the clinical utility of performing serial 24-h ambulatory monitoring to detect subclinical blood pressure fluctuations.

© 2018 The Author(s)
Published by S. Karger AG, Basel

Introduction

Pure autonomic failure (PAF) is a slowly progressive neurodegenerative disorder characterized by isolated autonomic nervous system dysfunction in the absence of other neurological abnormalities [1]. Establishing the diagnosis of PAF is challenging and can only be made if other causes of autonomic failure were excluded, usually of the α -synucleinopathy group, such as multiple system atrophy (MSA), Parkinson's disease, and Lewy body dementia [2, 3].

Currently, there is no specific treatment to cure or reverse the disease course of PAF. General therapeutic goals are aimed at providing adequate symptomatic relief and optimizing quality of life [4, 5]. Supine hypertension (SH) is seen in almost half of autonomic failure patients [6]. In addition, it is a well-known side effect of the first-line therapies – midodrine and fludrocortisone – further complicating management [1]. Pyridostigmine, a cholinesterase inhibitor, may provide additional benefit in PAF without worsening SH [7, 8].

We present a patient diagnosed with PAF in whom midodrine and fludrocortisone provided symptomatic relief with acceptable blood pressure (BP) control steadily for 3 years. However, his hypotensive symptoms gradually worsened together with clinically silent hypertensive urgencies detected on serial 24-h ambulatory BP monitoring (ABPM).

Case Report

A 70-year-old gentleman presented with a 1-year history of recurrent dizziness triggered by prolonged standing and relieved by moving his upper limbs. Later, these attacks progressed to presyncopal episodes constraining him to sit for a couple of minutes with crossing the thighs. He denied having impotence, tremors, gait disturbance, bowel dysfunction, or urinary incontinence. His previous medical and surgical history was only significant for an L2 vertebral compression fracture following trauma that had been managed conservatively 9 years prior to this presentation. Physical examination confirmed orthostatic hypotension (OH) with a significant drop in systolic BP (SBP), from 120 mm Hg in the supine position to 86 and 76 mm Hg immediately and 5 min after standing, respectively. The remainder of the examination was unremarkable. Initial blood investigations showed normal hemoglobin and hemoglobin A1c levels. Thyroid and adrenal testing revealed no abnormalities. Throughout the follow-up period, all ABPMs were done using the TONOPORT™ V device manufactured by General Electric Healthcare. Data were analyzed using the CardioSoft™ diagnostic system provided by the manufacturer, and measurements were reported in numeric values split into wake and sleep periods. The baseline ABPM showed frequent hypotensive episodes, with 4 out of 25 recorded BP readings displaying an SBP <90 mm Hg and a diastolic BP (DBP) <50 mm Hg (all while awake). Holter monitoring, transthoracic echocardiogram, exercise stress test, ultrasound of the upper limb vessels, and a coronary angiogram were all within normal limits. An angiogram of the thoracic aorta revealed mild diffuse thoracoabdominal aortic atherosclerosis and was negative for subclavian stenosis. The patient also had a bilateral, insignificant (5–10%) internal carotid artery stenosis. Brain magnetic resonant imaging, apart from age-related atrophic changes, was unremarkable.

The patient traveled abroad for a second opinion and underwent autonomic nervous system testing approximately 1 year after his initial presentation. A 60-degree tilt via head-up tilt testing resulted in asymptomatic OH with a significant fall in SBP (Δ SBP = 117 mm Hg and Δ DBP = 37 mm Hg with insufficient tachycardia). The heart rate to deep breathing test showed reduced response via mean heart rate range but normal via expiratory to inspiratory ratio,

suggesting significant cardiovagal impairment. The heart rate response to the Valsalva maneuver was normal, but the BP drop in response to phase II was excessive while the response to phase IV was absent, suggesting significant adrenergic impairment. Quantitative sudomotor axon reflex testing showed a reduced response at the proximal foot, borderline reduced at the leg, and normal at the forearm, consistent with postganglionic abnormalities seen in autonomic and small fiber neuropathy. Thermoregulatory sweat test revealed normal sweating in the chest and abdomen corresponding to T4–T8 segments, hypohidrosis to anhidrosis in the upper chest, lower abdomen, forehead, shoulders, arms, and legs, and patchy modest sweating in the forearms and fingers representing a regional pattern. Finally, nicotinic acetylcholine ganglionic receptor antibody was negative. Based on these findings along with the absence of other neurological system involvement, a diagnosis of PAF was established.

Nonpharmacological measures such as increasing fluid and salt intake and wearing compression stockings had failed to alleviate the patient's symptoms. Initiation of midodrine hydrochloride eye drops and fludrocortisone tablets provided reasonable control of his symptoms. Serial annual ABPM measurements over the following 3 years were free of hypotensive readings, but showed significant SH (average SBP = 168 ± 24 mm Hg and SBP readings >180 mm Hg = 17% after 2 years and average SBP = 170 ± 25 mm Hg and SBP readings >180 mm Hg = 39.5% after 3 years) (Fig. 1). Gradually, symptoms of autonomic failure started worsening in the form of disturbance of vision induced by postural change, left upper limb and neck pain and numbness, and worsening postural dizziness. A repeated ABPM was significant for a wide range of SBP readings, mostly on the hypertensive side (average SBP = 163 ± 26 mm Hg and SBP readings >180 mm Hg = 30%) (Fig. 1). Brain imaging revealed no interval changes from his baseline investigations. Pyridostigmine was added to his regimen but was not beneficial. Further, his ABPM while on pyridostigmine showed worsening SH with an average SBP of 178 ± 30 mm Hg. In addition, almost half (54%) of his SBP readings were >180 mm Hg, with frequent readings >210 mm Hg (21% of total readings) observed for the first time over 5 years of follow-up, although he was asymptomatic to this regard. Pyridostigmine and fludrocortisone were both discontinued, and a subsequent ABPM showed a persistently worsening SH (average SBP = 188 ± 30 mm Hg and SBP readings >180 mm Hg = 50%) with concomitant deterioration in his hypotensive symptoms. Eventually, the long-term plan agreed upon with the patient was to continue midodrine during the day, along with enhancing coping strategies and performing physical maneuvers prior to postural change.

Discussion

We report a patient diagnosed with PAF whose symptoms were poorly controlled with nonpharmacological maneuvers but relatively improved with first-line therapies. Years later, he experienced progression in his hypotensive symptoms, and his ABPM showed worsening SH despite multiple drug adjustments.

The management of PAF begins with simple, nonpharmacological measures. Increasing water and salt intake, cross-leg maneuvers prior to standing, and the use of custom-fitted abdominal binders and lower limb compression stockings have all been shown to be beneficial in PAF. However, the majority of patients eventually require a combination of both pharmacological and nonpharmacological interventions [5]. The mechanisms through which drug therapies achieve symptomatic relief in PAF are volume expansion and vasoconstriction. Midodrine is an α 1-adrenergic agonist that works by systemic vasoconstriction and is considered the first-line treatment in PAF. Fludrocortisone is a synthetic mineralocorticoid that is

usually used in combination with midodrine for volume expansion. Unfortunately, both these medications are known to cause or aggravate an already existing SH [1]. It is believed that the inhibition of acetylcholinesterase enhances the transmission of neurohormones across the pre- and postganglionic junction, which in turn improves orthostatic tolerance [3]. Hence, pyridostigmine has been shown to provide additional benefit with the advantage of not worsening SH [7, 8]. A promising drug that recently received an accelerated approval by the Food and Drug Administration for the management of neurogenic OH is droxidopa [9]. It is a prodrug that works via the metabolic conversion to norepinephrine through aromatic amino acid decarboxylase, an enzyme that is widely expressed intracellularly in the liver, kidneys, and gastrointestinal tract [10]. However, it is not yet widely available and the long-term safety profile remains unclear.

The prognosis of PAF is better than that of other synucleinopathies. In a 10-year longitudinal observational study, the mortality rate was 10-fold higher in MSA when compared to PAF [11]. Phenoconversion to other synucleinopathies is not uncommon. In a prospective study that enrolled 74 subjects initially diagnosed with PAF, 34% progressed to other disorders within a 4-year follow-up period, most commonly Lewy body dementia [12]. The long-term prognosis of PAF with regards to symptomatic deterioration and the need for escalation of therapy is unclear as, to the best of our knowledge, this outcome has never been considered an endpoint in prospective studies. One limitation in our report is that the autonomic testing was performed overseas and the exact numerical values of the results were not available for review. Also, catecholamine levels were not measured in varying body positions as this test may help distinguish PAF from MSA. In our patient, however, the absence of clinical parkinsonism, autoantibodies, or signs of neurodegeneration on magnetic resonant imaging after more than 5 years of follow-up make an alternative diagnosis less likely [1].

Nearly half of neurogenic OH patients in general experience SH [6]. Patients who have nighttime SH develop pressure diuresis causing volume depletion which subsequently aggravates early morning orthostatic symptoms [2]. Since PAF patients have a normal life expectancy [5], it is crucial to have SH addressed in the management to prevent its related complications, such as left ventricular hypertrophy and renal impairment [2]. Significant BP alterations may not be detected in a routine office visit. For instance, a study on 45 patients with autonomic failure revealed that office tilt testing, when compared to ABPM, detected hypotension in only one-third of the patients, rendering clinical examination insufficient to replace ABPM [13]. In addition, it is widely endorsed by several scientific societies to incorporate ABPM in the management of hypertension to detect diurnal patterns and guide therapies [14]. Therefore, it is worthwhile to perform surveillance ABPM in patients with significant autonomic dysfunction, regardless of their clinical status.

Conclusion

The management of PAF is complicated due to the difficulties in achieving acceptable symptomatic relief along with aiming for tight BP control to prevent SH. Individualized management in a case-by-case fashion is the preferred therapeutic approach in PAF and synucleinopathies in general, since these disease entities are rare, with little literature on their treatments. Serial ABPMs are crucial and irreplaceable by clinical assessment, as significant hypertensive urgencies may not manifest overtly, similar to what we observed in our patient.

Acknowledgment

We thank the staff of the Deanship of Scientific Research at King Saud University, Riyadh, Saudi Arabia (research group number: RG-1436-013) for their valuable input and editing of this article.

Statement of Ethics

Oral consent was obtained from the patient to publish the material in this report.

Disclosure Statement

The authors have no conflicts of interest to declare.

Funding Sources

No funding agencies were involved in the production of this report.

Author Contributions

Writing of the manuscript was primarily done by A. Aljohar. A. Aldeeri aided in the literature review and in interviewing the patient. T. Muayqil contributed in revising the manuscript, especially the section on neurological assessment. A. Hersi and A. Jammah revised the final version and provided valuable contributions in their fields (cardiac electrophysiology and endocrinology). K. Alhabib is the patient's primary physician and supervised the whole process of this report's production.

References

- 1 Thaisetthawatkul P. Pure Autonomic Failure. *Curr Neurol Neurosci Rep*. 2016 Aug;16(8):74.
- 2 Low PA. Neurogenic orthostatic hypotension: pathophysiology and diagnosis. *Am J Manag Care*. 2015 Oct;21(13 Suppl):s248–57.
- 3 Freeman R. Clinical practice. Neurogenic orthostatic hypotension. *N Engl J Med*. 2008 Feb;358(6):615–24.
- 4 Ricci F, De Caterina R, Fedorowski A. Orthostatic Hypotension: Epidemiology, Prognosis, and Treatment. *J Am Coll Cardiol*. 2015 Aug;66(7):848–60.
- 5 Shibao C, Okamoto L, Biaggioni I. Pharmacotherapy of autonomic failure. *Pharmacol Ther*. 2012 Jun;134(3):279–86.
- 6 Biaggioni I, Robertson RM. Hypertension in orthostatic hypotension and autonomic dysfunction. *Cardiol Clin*. 2002 May;20(2):291–301, vii.
- 7 Shibao C, Okamoto LE, Gamboa A, Yu C, Diedrich A, Raj SR, et al. Comparative efficacy of yohimbine against pyridostigmine for the treatment of orthostatic hypotension in autonomic failure. *Hypertension*. 2010 Nov;56(5):847–51.
- 8 Singer W, Sandroni P, Opfer-Gehrking TL, Suarez GA, Klein CM, Hines S, et al. Pyridostigmine treatment trial in neurogenic orthostatic hypotension. *Arch Neurol*. 2006 Apr;63(4):513–8.
- 9 Kaufmann H, Freeman R, Biaggioni I, Low P, Pedder S, Hewitt LA, et al.; NOH301 Investigators. Droxidopa for neurogenic orthostatic hypotension: a randomized, placebo-controlled, phase 3 trial. *Neurology*. 2014 Jul;83(4):328–35.

- 10 Keating GM. Droxidopa: a review of its use in symptomatic neurogenic orthostatic hypotension. *Drugs*. 2015 Feb;75(2):197–206.
- 11 Goldstein DS, Holmes C, Sharabi Y, Wu T. Survival in synucleinopathies: A prospective cohort study. *Neurology*. 2015 Nov;85(18):1554–61.
- 12 Kaufmann H, Norcliffe-Kaufmann L, Palma JA, Biaggioni I, Low PA, Singer W, et al.; Autonomic Disorders Consortium. Natural history of pure autonomic failure: A United States prospective cohort. *Ann Neurol*. 2017 Feb;81(2):287–97.
- 13 Norcliffe-Kaufmann L, Kaufmann H. Is ambulatory blood pressure monitoring useful in patients with chronic autonomic failure? *Clin Auton Res*. 2014 Aug;24(4):189–92.
- 14 Turner JR, Viera AJ, Shimbo D. Ambulatory blood pressure monitoring in clinical practice: a review. *Am J Med*. 2015 Jan;128(1):14–20.

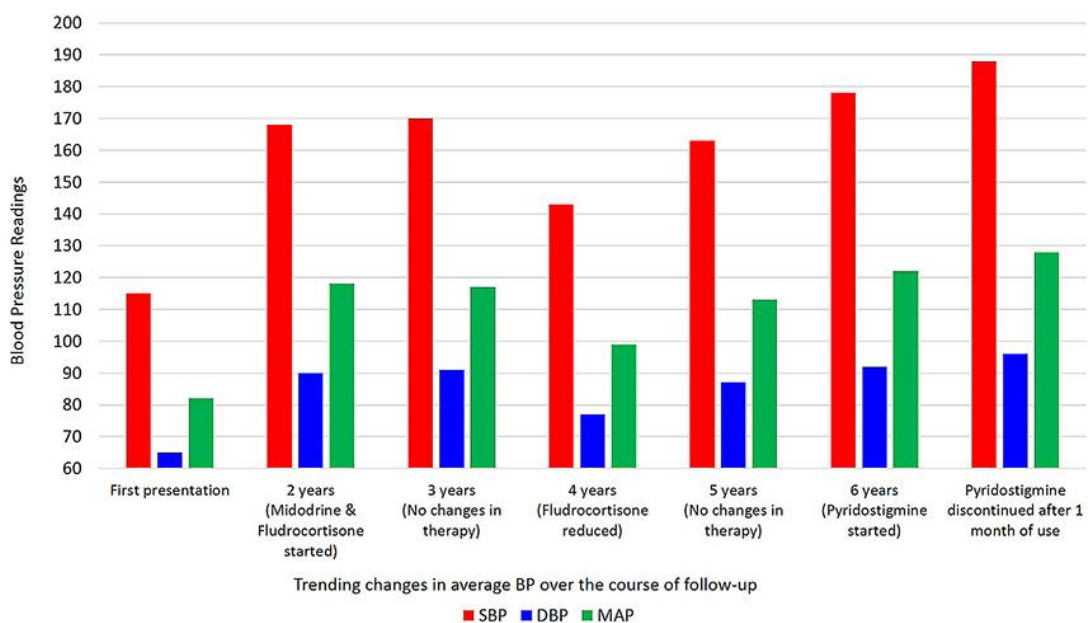


Fig. 1. BP variability over the course of follow-up based on serial ABPMs. The figure demonstrates the significant elevation in average supine BP after 2 and 3 years of follow-up attributed to the use of midodrine and fludrocortisone. With multiple dosage adjustments, the patient had an improvement in his average BP seen after 4 years with reasonable tolerability in his orthostatic symptoms. However, he experienced worsening SH after 5 years despite further reductions in midodrine and fludrocortisone doses. In addition, his serial monitoring after adding and then subsequently discontinuing pyridostigmine showed persistently worsening BP readings along with worsening orthostatic symptoms. ABPMs, ambulatory blood pressure monitorings; BP, blood pressure; DBP, diastolic blood pressure; MAP, mean arterial pressure; SBP, systolic blood pressure; SH, supine hypertension.