



Contents lists available at ScienceDirect

International Journal of Surgery Case Reports

journal homepage: www.casereports.com

An irreducible left scrotal hernia containing a sigmoid colon tumor (adenocarcinoma) – Case report

Jarosław Gnaś^{a,*}, Marek Bulsa^b, Grażyna Czaja-Bulsa^c^a Hospital Medical Center in Goleniow, Surgery Department, str. Nowogardzka 2, 72-100 Goleniow, Poland^b Hospital Medical Center in Goleniow, Gynecological and Obstetric Department, str. Nowogardzka 2, 72-100 Goleniow, Poland^c Independent Public Specialist Health Care “ZDROJE”, Pediatrics, Gastroenterology and Rheumatology Department, str. Wojciecha 7, 70-410 Szczecin, Poland

ARTICLE INFO

Article history:

Received 7 November 2013

Received in revised form 30 January 2014

Accepted 9 April 2014

Available online 11 June 2014

Keywords:

Sigmoid

Adenocarcinoma

Inguinal

Scrotal

Hernia

ABSTRACT

INTRODUCTION: In relation to all inguinal hernias, large irreducible scrotal hernias are quite rare, while such hernias containing colon tumors in the sac have so far been described in fewer than 30 cases.

PRESENTATION OF CASE: A 61-year-old patient was admitted for a planned surgery because of a large irreducible left-sided scrotal hernia. Intraoperatively, a large tumor of the sigmoid colon was found in the hernial sac. In a histopathological examination it was diagnosed as adenocarcinoma. A palliative operation was performed and he was referred to further systemic and palliative treatment (because of numerous coexisting liver metastases).

DISCUSSION: Until now, only about 30 cases of colon tumor in inguinal hernia sac have been reported.

CONCLUSION: It should be remembered that even the most obvious preoperative diagnosis may be verified intraoperatively.

© 2014 The Authors. Published by Elsevier Ltd. on behalf of Surgical Associates Ltd. This is an open access article under the CC BY-NC-ND license (<http://creativecommons.org/licenses/by-nc-nd/3.0/>).

1. Introduction

In relation to all inguinal hernias, large irreducible scrotal hernias are quite rare, while such hernias containing colon tumors in the sac have so far been described in fewer than 30 cases.

A 61-year-old patient was admitted for a planned surgery because of a large irreducible left-sided scrotal hernia. Intraoperatively, a large tumor of the sigmoid colon was found in the hernial sac. In a histopathological examination it was diagnosed as adenocarcinoma.

A palliative operation was performed and he was referred to further systemic and palliative treatment (because of numerous coexisting liver metastases).

2. Presentation of case

A 61-year-old patient was admitted to a surgery department because of a large left-sided irreducible scrotal hernia. Except for a slight loss of weight over the past few months and periodically repeated left abdominal pains, he had had no other accompanying symptoms, including no symptoms of a bowel obstruction.

In the physical examination, a large left-sided irreducible scrotal hernia, with a quite rigid consistency, together with the

testis constituting an indivisible cell conglomerate; otherwise, in the physical examination no abdomen abnormalities. Right inguinal canal without characteristic signs of hernia. In laboratory tests, the patient was anemic and had a leucocytosis.

In a chest X-ray: lung fields, diaphragm and heart normal.

The patient was prepared for the operation in a typical way.

The operation began in a classic way: a cut above the Poupart's ligament opened the left inguinal canal. Separation of hernial sac from the spermatic cord was initiated, however, due to a very large infiltration, it turned out to be impossible (Fig. 1). On opening the sac, there appeared a very much changed sigmoid with a tumor infiltrating beyond the hernial sac onto the left testis and spermatic cord, locally including inflammation with necrosis. The tumor significantly narrowed the intestinal lumen. In a later histopathological test, adenocarcinoma was diagnosed.

For a proper evaluation of the entire peritoneal cavity, laparotomy was performed from a separate cutting. Multiple nodular changes in the liver were found, most probably of a metastatic nature. Transfer of the sigmoid tumor into the peritoneal cavity was impossible, so sigmoid was excised from the side of the inguinal canal, with manual anastomosis “end to end”. The release of the testis and spermatic cord from the infiltration was impossible to conduct, so it was necessary to excise both structures in one block (Fig. 2).

Subsequently, the posterior wall of the inguinal canal was closed by Halsted's method. Lavage and drainage of the peritoneal cavity were performed. Abdomen wall was closed in a conventional

* Corresponding author. Tel.: +48 501 367 197; fax: +48 91 4664 301.
E-mail address: sq1euo@gmail.com (J. Gnaś).

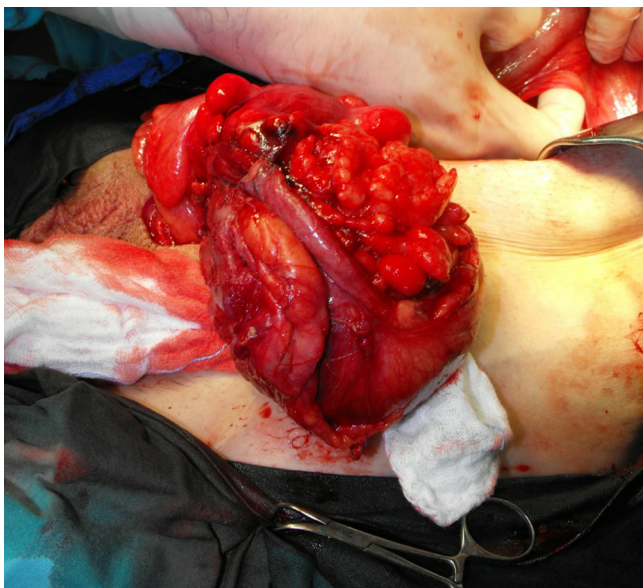


Fig. 1. Tumor, after opening the inguinal canal.

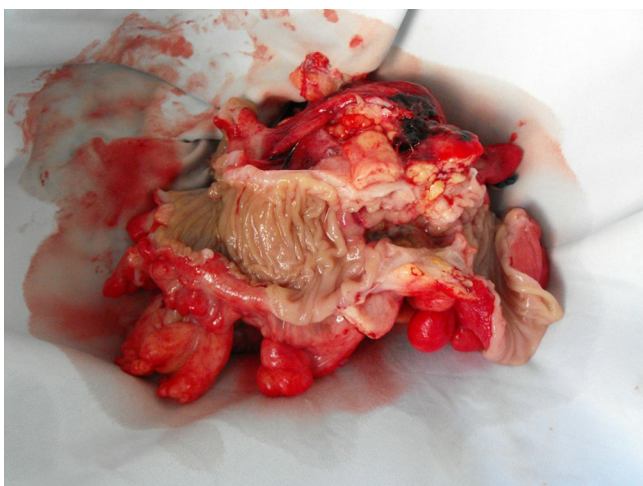

Fig. 2. Intestinal lumen narrowed by the tumor.

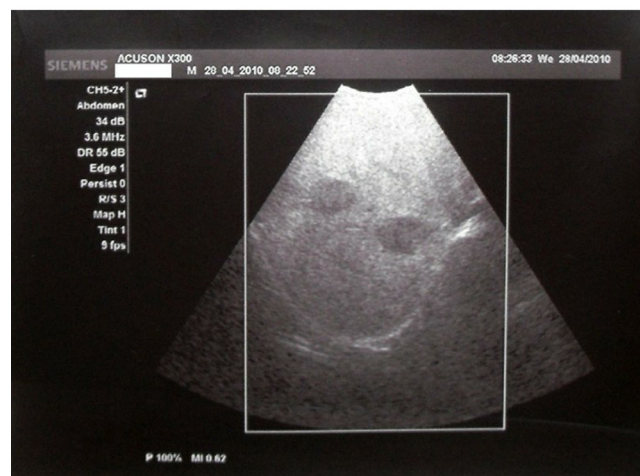
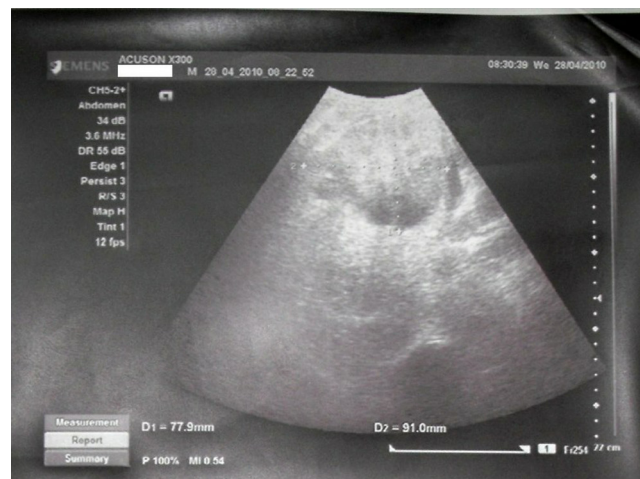
Fig. 3. Metastases in ultrasonography.

way and with the use of ventrofil stitches. The wounds healed per primam.

The postoperative abdominal ultrasound examination revealed multiple nodules changes in the liver with suspicion of a central necrosis (Fig. 3), most likely of a metastatic nature. During his hospital stay, the patient received two units of PRBCs, two units of FFP, Fraxiparine 0.6 and antibiotic cover.

The patient was discharged after a week, in a good general condition, for further systemic therapy and palliative care.

In the received histopathological test: Adenocarcinoma G2, Astler-Coller stage B2, AJCC stage 2, histological type N, pT3NxM1. The cancer infiltrates the entire thickness of the intestinal wall and crosses the serous membrane. Cuttings borders: sine laesionibus.

Six months after the surgery, the patient is in a good general condition. He has interrupted the treatment and taken up physical work; he has not reported for a check-up examination at the Department of Surgery.

3. Discussion

Until now, about 30 cases of colon tumor in inguinal hernia sac have been reported. In the Southern Medical Journal 1991 October, vol. 84, No. 10, p. 1280–81, Maj Douglas and co. described 15 such cases. In three of them, the tumor was in the inguinal hernia sac on the right side, while in other cases – on the left one. All the right-sided hernias contained cecum, while the left-sided ones had sigmoid. Six patients demonstrated symptoms of obstruction, and all the patients were males, as in the case presented by us. Just like in the case of our patient, all the cases described were diagnosed intra-operatively and laparotomy was performed from a separate cut for the purpose of resection of part of the colon and a full evaluation of the peritoneum cavity.¹

Salemans et al. describe the case of a 93-year old patient who was preoperatively diagnosed with sigmoid cancer. Because of the advanced age, they decided to perform a “one cut” procedure. The sigmoid resection with anastomosis and the hernioplasty were performed in one procedure.² Carr et al. described a patient who should have been operated because of the left-sided inguinal hernia. Preoperative, the laboratory tests showed anemia (as in our patient's case). They decided to make a diagnostics of anemia. Routine colonoscopy revealed a sigmoid cancer. Simultaneously sigmoid colon resection and hernioplasty were made by laparoscopy technique.³ Bezniczka et al. present four patients with concomitant inguinal hernia and colon cancer. They conclude that in the cases of large hernias, especially those rapidly growing, colonoscopy should

be a routine diagnostic procedure, applied to assess the colon and the possible detection of the tumor.⁴

4. Conclusion

It should be remembered that even the most obvious preoperative diagnosis may be verified intraoperatively. In some centers, ultrasound examination of each surgical patient is a routine preoperative action. To a large extent, the ultrasound evaluation allows to avoid such surprises during the operation. Stephen King used to say: “When you hear hoof beats, think horses, not zebras.” However, as seen in our example and other ones, it sometimes happens that we do see the zebras.

Conflict of interest

None.

Funding

None.

Ethical approval

Written informed consent was obtained from the patient for publication of this case report and case series and accompanying images. A copy of the written consent is available for review by the Editor-in-Chief of this journal on request.

Author contributions

All authors have equal share.

References

1. Hale DA, Solla JA. Complete colonic obstruction caused by a sigmoid colon cancer incarcerated in an inguinal hernia sac. *South Med J* 1991;**84**(October (10)): 1280–1.
2. Salemans PB, Vles GF, Fransen SA, Smeenk RM. Sigmoid carcinoma in an inguinal hernia: a blessing in disguise? *Case Rep Surg* 2013;**2013**:94–3143.
3. Carr WR, O'Dair G. A laparoscopic high anterior resection for sigmoid cancer with extraction through incarcerated left inguinal hernia repaired with Permacol mesh. *BMJ Case Rep* 2012;**2012**.
4. Beznicza H, Simon E, Vizsy L. The simultaneous occurrence of inguinal hernia and colorectal cancer – case reports. *Magy Seb* 2004;**57**(October (5)):262–6.

Open Access

This article is published Open Access at sciedirect.com. It is distributed under the [IJSCR Supplemental terms and conditions](#), which permits unrestricted non commercial use, distribution, and reproduction in any medium, provided the original authors and source are credited.