

Percutaneous tracheostomy

Sirak Petros

Background: Percutaneous tracheostomy (PT) has gained an increasing acceptance as an alternative to the conventional surgical tracheostomy (ST). In experienced hands, and with proper patient selection, it is safe, easy and quick.

Complications: Perioperative complications are comparable with those of ST and these are mostly minor. An important advantage of PT over ST is that there is no need to move a critically ill patient to the operating room and the rate of stomal infection is very low. Although data on late complications of PT are not yet sufficient, available reports show a favourable result.

Techniques: Ciaglia's method is the most commonly applied, but no study has shown superiority of any of the percutaneous techniques described. The decision on which method to use should solely be made depending on the clinical situation and the experience of the operator. The learning curve demands caution, attention to detail and adequate experience on the part of the intensive care physician. Although PT is unfortunately declared 'easy', it must be left in the hands of experienced physicians to avoid unnecessary complications, and the risk of overimplementation should be kept in mind.

Addresses: Universität Leipzig, Medizinische Klinik und Poliklinik I, Abteilung für Intensivmedizin, Leipzig, Germany

Correspondence: Dr Sirak Petros, Universität Leipzig, Medizinische Klinik und Poliklinik I, Abteilung für Intensivmedizin, Philipp-Rosenthal-Strasse 27a, 04103 Leipzig, Germany.
Tel: +49 0341 9712706;
fax +49 0341 2615456;
e-mail: pets@medizin.uni-leipzig.de

Keywords: percutaneous tracheostomy, surgical tracheostomy, complications, techniques, comparison, learning curve

Received: 7 August 1998

Accepted: 15 April 1999

Published: 18 May 1999

Crit Care 1999, **3**:R5–R10

The original version of this paper is the electronic version which can be seen on the Internet (<http://ccforum.com>). The electronic version may contain additional information to that appearing in the paper version.

© Current Science Ltd ISSN 1364-8535

History

Tracheostomy is one of the oldest surgical procedures. The origin of percutaneous tracheostomy (PT) is not certain, although the Italian surgeon Sanctorius was probably the first to describe the technique in the 16th century. Sheldon *et al.* [1] used the term percutaneous tracheotomy in 1955 and described the method as an alternative to the surgical route. Toyne and Weinstein [2,3] introduced the technique using the Seldinger guidewire and it has since been refined with various modifications [4–7]. The percutaneous dilatational tracheostomy (PDT) introduced by Ciaglia *et al.* [4] in 1985, which involves progressive dilatation with blunt-tipped dilators, is the most frequently used and evaluated in the literature [8–18]. In 1989, Schachner *et al.* [5] introduced a rapid PT technique, Rapitrac, which did not get considerable acceptance because of complications associated with, and reservations towards, the sharp edges of the dilating forceps. In 1990, Griggs *et al.* [6] reported on a PT technique using a modified Howard-Kelly forceps with a blunt edge and Fantoni *et al.* [7] reported the translaryngeal tracheostomy technique (TLT).

Indications and timing

Tracheostomy is indicated for prolonged ventilatory support, long-term airway maintenance, and to prevent the complications of long-term translaryngeal intubation. It also eases patient care and the process of weaning from mechanical ventilation. The timing of tracheostomy is still controversial [19–23]. In 1989, a Consensus Conference on Artificial Airways in Patients Receiving Mechanical Ventilation [21] recommended translaryngeal intubation for an anticipated need of up to 10 days and a tracheostomy if an artificial airway for more than 21 days is anticipated. However, the decision on the time point of tracheostomy should be made on an individual basis and should depend on prognostic evaluations and not on 'calendar watching' [24]. Although early tracheostomy is preferred by some authors [25–28], there is no adequate comparative study as to the advantages of this approach [23].

Techniques

Currently, the technique by Ciaglia *et al.* [4] (Cook® Critical Care, Bjaeverskov, Denmark) is the most widely applied, followed by that of Griggs *et al.* [6] (Portex®,

Smiths Industries Medical Systems, Hythe, Kent, UK). The TLT method (Mallinckrodt Medical®, Mirandola, Italy), with the tracheal cannula being inserted through the translaryngeal route, has been reported particularly in Italy and is now under evaluation in several clinics across Europe. The key procedure in all these methods is needle puncture of the trachea and insertion of the Seldinger guidewire. Though the procedure may be carried out under local anesthesia, experience shows that it is safer to perform this under adequate analgesedation and, if necessary, neuromuscular relaxation. The latter is particularly important to suppress the cough reflex which may increase the risk of damage to the posterior tracheal wall with either the puncture needle or dilators. Additionally, infiltration of the proposed site with lidocaine/epinephrine solution may be useful to reduce the risk of bleeding. Hyperextension of the neck for anterior displacement of the trachea is crucial. Therefore, PT is not recommended when manipulation of the cervical spine is contraindicated. There is no study on the implementation of any of these techniques in emergency situations. Furthermore, their use should be weighed carefully in patients with a large goiter, recent neck surgery or inflammatory changes at the proposed site of skin incision.

Ciaglia's technique (percutaneous dilatational tracheostomy)

Serial dilatation of the trachea is the hallmark of this technique. Originally, Ciaglia *et al.* [4] described the point of entry to be subcricoid; however, this was found to be too high, with a risk of subglottic stenosis [29–31]. Therefore, the preferred site of entry is now between the first and the second or the second and third tracheal rings [9,12,17,18,31]. Initial skin incision and blunt preparation of the pretracheal tissue may be helpful to identify the tracheal rings, thus avoiding either too high or too low tracheal puncture. After dilatation with the maximal available dilator, a tracheal cannula (inner diameter up to 9 mm) can be inserted whilst mounted on a corresponding dilator.

The routine use of bronchoscopy during PT, apart from TLT, is not yet settled. There are reports of lower rates of acute complications under endoscopic guidance [8,13,32]. However, there is no adequate controlled study showing that endoscopic-guided tracheostomy is superior to the 'blind' one. Furthermore, the significance of operator experience, anatomical consideration and individualization in decision making is not discussed in these studies. Additionally, resultant hypercarbia should be considered when choosing endoscopic-guided PT for the critically ill and/or patients with head injuries [33]. However, endoscopic guidance plays a decisive role in the training of physicians, during PT on patients with a difficult anatomy, and to remove aspirated blood.

Another controversial issue is whether bronchoscopy can better define the exact location of tracheal puncture. A cadaver study by Dexter [34] showed that correct 'blind' puncture in the intended intercartilaginous space was achieved in only 45% of cases. Another post-mortem study [35] reported accurate placement of the tracheal cannulas in 76% of cases. Until now, studies using bronchoscopic guidance during PDT have concentrated on the confirmation of the initial airway puncture. Therefore, a controlled study is necessary to settle these issues. In any case, a bronchoscope must be readily available in case of an emergency.

The average time required to perform the dilatational tracheostomy is 10–15 min [12,14,17,18,36]. Although Ciaglia's technique has already been carried out successfully on children [37], there are still reservations on its use in this age group due to the marked elasticity of the tracheal tissue.

Griggs' technique

The distinctive feature of this technique is the use of a pair of modified Howard-Kelly forceps for blunt dilatation of the pretracheal and intercartilaginous tissue after insertion of the guidewire into the trachea and skin incision. The average time required for a tracheostomy is about 5 min, but it can also be accomplished in about 1 min [38,39] (unpublished personal observation). Applying this method on patients with a short and/or thick neck may be difficult, if not dangerous, particularly while attempting to perform intercartilaginous dilatation. Although none of these percutaneous techniques have been evaluated for emergency use, this method could possibly be applied in such a situation following proper patient selection.

Translaryngeal tracheostomy (Fantoni's technique)

For translaryngeal tracheostomy, in contrast to the other techniques, the initial puncture of the trachea is carried out with the needle directed cranially and the tracheal cannula inserted with a pull-through technique along the orotracheal route. The cannula is then rotated downward using a plastic obturator. The main advantage of TLT is that there is hardly any skin incision required, and therefore practically no bleeding is observed. Furthermore, there is minimum pressure on the trachea and pretracheal tissue. It has also been successfully carried out on infants and children [7]. It may be particularly useful in patients with bleeding diathesis and goiter. The procedure can be carried out under endoscopic guidance only, and rotating the tracheal cannula downward may pose a problem, thus demanding more experience. There is also an apnea phase of about 60–90s during the procedure [7,40]; this technique should therefore be contraindicated in patients with severe respiratory insufficiency requiring extreme forms of mechanical ventilation (high positive end-expiratory pressure, high inspiratory oxygen concentration). Additionally, since the tracheal cannula is pulled through the oropharynx, the significance of contamination of the cannula with

Table 1**Perioperative complications (%) during percutaneous dilatational tracheostomy**

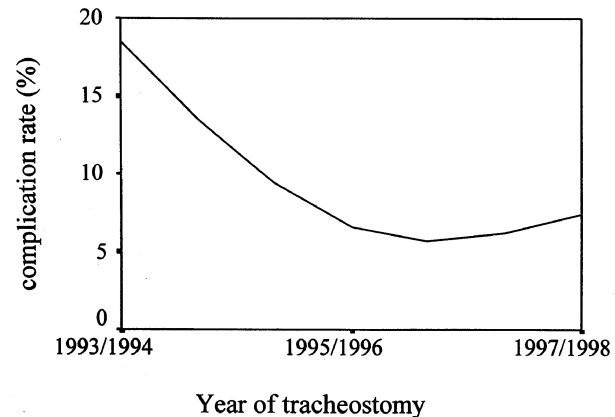
Author	<i>n</i>	Major bleeding	subcutaneous emphysema	Pneumothorax	Tracheal lesions	Death
Marelli <i>et al.</i> [8]	61	1.6	0	0	0	1.6
Ciaglia and Graniero [9]	170	0	1.2	0	0	0
Friedman and Mayer [10]	100	4.0	2.0	0	?	1.0
Manara [11]	77	2.6	0	0	0	0
Fernandez <i>et al.</i> [13]	162	0.6	0	0.6	2.5	0
Hill <i>et al.</i> [14]	356	1.4	0	0.6	0	0.3
van Heurn <i>et al.</i> [15]	150	3.3	1.3	0	0	0
Petros and Engelmann [17]	137	0.7	2.2	0	2.9	0
Walz <i>et al.</i> [18]	326	0.6	0.6	0	0.9	0.3

oropharyngeal bacterial flora in the development of (aspiration) pneumonia or other airway infections should be investigated.

Complications

The advantages of PT are that it is a simple, fast, and minimally invasive bedside procedure leading to less stress to the patient compared with surgical tracheostomy (ST). Although there are differences between authors as to what is considered worth reporting, the rate of perioperative complications for Ciaglia's technique is between 4.1% and 12%, the majority of these being minor with the rate decreasing with experience [8,9,13–18]. Bleeding is the most common perioperative complication (Table 1). A rare and life threatening complication of tracheostomy is a tracheo-innominate artery fistula which has also been reported after PDT [10,41]. This may occur with a tracheostomy below the third or fourth tracheal ring. Another important complication is damage to the posterior tracheal wall due to the puncture needle or dilators, which is usually minimal but may have serious consequences in a few cases. As in any other invasive procedure, the rate of complications depends not only on the inherent problems of the technique but also on the experience of the operating physician [14,17], as well as on a proper patient selection. Our prospective observation on 234 PDTs demonstrates the learning curve which should be taken into consideration when discussing complication rates (Fig. 1; unpublished data).

Mortality due to PT is rare and this is reported to be due to bleeding [10,15,18], bronchospasm [14], cardiac arrhythmia [8], and premature decannulation [42]. Stomal infection is rare (0–3.3%) and mostly minor, since the stoma fits snugly around the cannula and there is hardly any tissue devitalization [8,9,11,13–17,36,38,43].

Figure 1

The learning curve: perioperative complications during percutaneous dilatational tracheostomy.

Figures on late complications after decannulation, including tracheal stenosis, hoarseness and tracheomalacia, are difficult to analyze since the criteria applied by the authors differ and the diagnostic intensity varies. Ciaglia and Graniero [9] reported only one case of mild voice change among 52 decannulated patients, whereas Hill *et al.* [14] observed symptomatic tracheal stenosis in 3.7%. Marx *et al.* [16] reported two cases of tracheal stenosis that required tracheoplasty among their 254 patients. In a detailed analysis using tomography of the trachea on 54 decannulated patients, van Heurn *et al.* [30] reported a tracheal stenosis of 10–25% in 11 patients, between 25–50% in two patients, and more than 50% in one patient. In 41 patients examined at least 6 months after decannulation, Law *et al.* [44] found a tracheal stenosis of 10% in four asymptomatic patients by means of laryngotracheoscopy

and spirometry. Walz *et al.* [18] also reported a tracheal stenosis of at least 10% in about 40% of their follow-up patients.

Data for the Griggs' technique are few. The rate of perioperative complications is about 4% [38,39]. Late complication, particularly tracheal stenosis, was observed by Griggs *et al.* [38] in one out of 153 cases.

For TLT, Fantoni and Ripamonti [7] reported bleeding in 2.8%, although this was attributed to ample skin incision in the initial experimentation phase. Another prospective study on a small group of patients also showed only minimal complications [40]. No late complication was observed by Fantoni and Ripamonti [7] in nine autopsies and 20 adults after decannulation. However, the duration of cannulation was not mentioned. An adequate comparative study is necessary to investigate whether the rate of late complications is indeed lower than that for the other percutaneous techniques.

Pathological studies on the trachea after PT are scarce. In an autopsy study of 12 cases with PDT, van Heurn *et al.* [45] reported a fracture of one or more tracheal rings in 11 cases, two of whom had a fracture of the cricoid. Destruction and necrosis of one or more tracheal rings was also observed in those cases cannulated for more than 10 days. Transverse rupture of the anterior tracheal wall with or without fracture of neighboring rings is considered as the typical lesion following PDT by Walz and Schmidt [35]. As these authors have already pointed out, certain complications, particularly too high tracheostomy and ring fracture, can be avoided by attention to detail during the procedure. Exact palpation of the tracheal rings is crucial before starting the percutaneous technique, and this can be improved by blunt dissection of the pretracheal tissue when using the Cook and Portex kits and, in case of difficult anatomy, by applying endoscopic guidance. Furthermore, too much pressure on the trachea during cannulation must be avoided.

Percutaneous tracheostomy versus surgical tracheostomy

Comparing PT with historical data of complications for ST is erroneous and may give a biased picture. Furthermore, due to different definitions of complications used by authors, these figures should be interpreted cautiously. Nevertheless, comparative studies have shown that PT has certain advantages [36,38]. Firstly, it can be performed immediately once the decision is made and few personnel are needed. In contrast, ST requires more organization and, if it is to be done in the operating room, time scheduling. ST involves the transport of mostly critically ill patients out of the intensive care unit to the operating room, which is often a complex co-ordinated effort and may endanger the patient. The time required for PT is

about one-quarter that for the surgical route [36,38], which implies less stress to the patient and better use of available resources.

The rate of perioperative complications for ST does not generally differ from that for PT. A prospective study by Stock *et al.* [20] revealed a rate of 6.0%. Two large retrospective studies reported rates between 5.4% and 6.3% for acute complications [46,47]. In a prospective comparison of Griggs' technique with standard ST, Griggs *et al.* [38] reported rates of 3.9% and 8.1%, respectively, for perioperative complications.

However, the rate of stomal infection for ST is significantly higher (6.8–22.2%) [36,38,48], which has been associated with the larger wound surface and tissue devitalization. Late complications of ST, particularly tracheal stenosis, are reported to be low, ranging between 0–1.1% [46,48–50].

Although cost analysis between PT and ST is not easy because of varying reimbursement systems and hospital structures, available studies show that PT is considerably cheaper than the surgical route [8,13,14,36,41,51]. It is common sense that if fewer personnel and no operating room time are required, and the patient need not be moved, then the overall cost of PT has to be lower than that of ST.

Conclusion

Percutaneous tracheostomy has already replaced the surgical route in several intensive care units and it is indeed the procedure of choice in the majority of cases. This is attributable to the fact that, in experienced hands, it is safe, easy and quick, and there is no need to move the patient to the operating room. Perioperative complications are at least comparable with those of surgical tracheostomy and most of them are minor. With proper patient selection, operator experience and attention to detail, complication rates can be reduced that may have an influence on late complications.

An important advantage of PT over the surgical route is the very low rate of stomal infection. Several reports have also shown that PT is cheaper than ST, which is of course important at a time when resources are limited. Despite all the virtues of the percutaneous technique, the role of ST in cases with contraindications for PT, difficult anatomies and failed PTs remains unchallenged. The decision on which method to use should solely be made depending on the clinical situation and the experience of the operator. The fact that a technique is declared 'easy' should not lead to an attitude that every physician may get a chance to try it. PT must be left in the hands of physicians with enough experience, although at the moment there are no criteria to define this quality.

The discussion on the routine use of bronchoscopy during PT is not yet settled. Although this is a requirement during TLT, there is no adequate controlled study on the superiority of routine endoscopic guidance during dilatational tracheostomy. However, it is indispensable for training purposes and during PT on patients with difficult anatomy. Moreover, a bronchoscope must be at hand during PT in case an emergency situation arises.

No study has shown superiority of any of the three methods reported, although TLT is still under evaluation and not widely in use. These techniques must be judged by their safety, ease of performance and long-term effects, not merely by the rapidity with which they can be performed. Finally, in our enthusiasm to embrace new techniques, we must not get lured into their overimplementation.

References

- Sheldon CH, Pudenz RH, Freshwater DB, Cure BL: **A new method for tracheostomy.** *J Neurosurg* 1955, **12**:428-431.
- Toye FJ, Weinstein JD: **A percutaneous tracheostomy device.** *Surgery* 1969, **65**:384-389.
- Toye FJ, Weinstein JD: **Clinical experience with percutaneous tracheostomy and cricothyroidotomy in 100 patients.** *J Trauma* 1986, **26**:1034-1040.
- Ciaglia P, Firsching R, Syniec C: **Elective percutaneous dilatational tracheostomy: a new simple bedside procedure; preliminary report.** *Chest* 1985, **87**:715-719.
- Schachner A, Ovil Y, Sidi J, Rogev M, Heilbronn Y, Levy MJ: **Percutaneous tracheostomy: a new method.** *Crit Care Med* 1989, **17**:1052-1056.
- Griggs WM, Worthley LIG, Gilligan JE, Thomas PD, Myburg JA: **A simple percutaneous tracheostomy technique.** *Surg Gynecol Obstet* 1990, **170**:543-545.
- Fantoni A, Ripamonti D: **A non-derivative, non-surgical tracheostomy: the translaryngeal method.** *Intensive Care Med* 1997, **23**:386-392.
- Marelli D, Paul A, Manolidis S, et al.: **Endoscopic guided percutaneous tracheostomy: early results of a consecutive trial.** *J Trauma* 1990, **30**:433-435.
- Ciaglia P, Graniero KD: **Percutaneous dilatational tracheostomy. Results and long-term follow-up.** *Chest* 1992, **101**:464-467.
- Friedman Y, Mayer AD: **Bedside percutaneous tracheostomy in critically ill patients.** *Chest* 1993, **104**:532-535.
- Manara AR: **Experience with percutaneous tracheostomy in intensive care: the technique of choice?** *Br J Oral Maxillofac Surg* 1994, **32**:155-160.
- Bause H, Prause A, Schulte am Esch J: **Indication and technique of percutaneous dilatation tracheostomy for the intensive care patient [in German].** *Anästhesiol Intensivmed Notfallmed Schmerzther* 1995, **30**:492-496.
- Fernandez L, Norwood S, Roettger R, Gass D, Wilkins III H: **Bedside percutaneous tracheostomy with bronchoscopic guidance in critically ill patients.** *Arch Surg* 1996, **131**:129-132.
- Hill BB, Zweng TN, Maley RH, Charash WE, Toursarkissian B, Kearney PA: **Percutaneous dilatational tracheostomy: report of 356 cases.** *J Trauma* 1996, **40**:238-243.
- van Heurn LWE, van Geffen GJ, Brink PRG: **Clinical experience with percutaneous dilatational tracheostomy. Report of 150 cases.** *Eur J Surg* 1996, **162**:531-535.
- Marx WH, Ciaglia P, Graniero KD: **Some important details in the technique of percutaneous dilatational tracheostomy via the modified Seldinger technique.** *Chest* 1996, **110**:762-766.
- Petros S, Engelmann L: **Percutaneous dilatational tracheostomy in a medical ICU.** *Intensive Care Med* 1997, **23**:630-634.
- Walz MK, Peitgen K, Thuerauf N, et al.: **Percutaneous dilatational tracheostomy - early results and long-term outcome of 326 critically ill patients.** *Intensive Care Med* 1998, **24**:685-690.
- Whited RE: **A prospective study of laryngotracheal sequelae in long-term intubation.** *Laryngoscope* 1984, **94**:367-377.
- Stock MC, Woodward CG, Shapiro BA, Cane RD, Lewis V, Pecaro B: **Perioperative complications of elective tracheostomy in critically ill patients.** *Crit Care Med* 1986, **14**:861-863.
- Plummer AL, Gracey DR: **Consensus Conference on Artificial Airways in Patients Receiving Mechanical Ventilation.** *Chest* 1989, **96**:178-180.
- Heffner JE: **Timing of tracheostomy in ventilator-dependent patients.** *Clin Chest Med* 1991, **12**:611-625.
- Maziak DE, Meade MO, Todd TRJ: **The timing of tracheostomy. A systematic review.** *Chest* 1998, **114**:605-609.
- Heffner JE: **Timing tracheostomy: calendar watching or individualization of care?** *Chest* 1998, **114**:361-363.
- Rodriguez JL, Steinberg SM, Luchetti FA, Gibbons KJ, Taheri PA, Flint LM: **Early tracheostomy for primary airway management in the surgical critical care setting.** *Surgery* 1990, **108**:655-659.
- Lesnik I, Rappaport W, Fulginiti J, Witzke D: **The role of early tracheostomy in blunt, multiple organ trauma.** *Am Surg* 1992, **58**:346-349.
- Kluger Y, Paul DB, Lucke J, et al.: **Early tracheostomy in trauma patients.** *Eur J Emerg Med* 1996, **3**:95-101.
- Kane TD, Rodriguez JL, Luchetti FA: **Early versus late tracheostomy in the trauma patient.** *Respir Care Clin N Am* 1997, **3**:1-20.
- McFarlane C, Denholm SW, Sudlow CLM, Moralee SJ, Grant IS, Lee A: **Laryngotracheal stenosis: a serious complication of percutaneous tracheostomy.** *Anaesthesia* 1994, **49**:38-40.
- van Heurn LWE, Goei R, de Ploeg I, Ramsay G, Brink PRG: **Late complications of percutaneous dilatational tracheostomy.** *Chest* 1996, **110**:1572-1576.
- van Heurn LWE, Theunissen PHMH, Ramsay G, Brink PRG: **Pathologic changes of the trachea after percutaneous dilatational tracheostomy.** *Chest* 1996, **109**:1466-1469.
- Barba CA, Angood PB, Kauder DR, et al.: **Bronchoscopic guidance makes percutaneous tracheostomy a safe, cost-effective, and easy-to-teach procedure.** *Surgery* 1995, **118**:879-883.
- Reilly PM, Sing RF, Giberson FA, et al.: **Hypercarbia during tracheostomy: a comparison of percutaneous endoscopic, percutaneous Doppler, and standard surgical tracheostomy.** *Intensive Care Med* 1997, **23**:859-864.
- Dexter TJ: **A cadaver study appraising accuracy of blind placement of percutaneous tracheostomy.** *Anaesthesia* 1995, **50**:863-864.
- Walz MK, Schmidt U: **Tracheal lesion caused by percutaneous dilatational tracheostomy: a clinico-pathological study.** *Intensive Care Med* 1999, **25**:102-105.
- Friedman Y, Fildes J, Mizock B, et al.: **Comparison of percutaneous and surgical tracheostomies.** *Chest* 1996, **110**:480-485.
- Toursarkissian B, Fowler CL, Zweng TN, Kearney PA: **Percutaneous dilatational tracheostomy in children and teenagers.** *J Pediatr Surg* 1994, **29**:1421-1424.
- Griggs WM, Myburgh JA, Worthley LI: **A prospective comparison of a percutaneous tracheostomy technique with standard surgical tracheostomy.** *Intensive Care Med* 1991, **17**:261-263.
- Caldicott LD, Oldroyd GJ, Bodenham AR: **An evaluation of a new percutaneous tracheostomy kit.** *Anaesthesia* 1995, **50**:49-51.
- Walz MK, Hellinger A, Walz MV, Nimitz K, Peitgen K: **Translaryngeal tracheostomy: technique and early experience [in German].** *Chirurg* 1997, **68**:531-535.
- Imami E, Hogans L, Komer K, Martin M: **Percutaneous dilatational tracheostomy. Risks and benefits of bronchoscopy. A prospective, randomized study [abstract].** *Crit Care Med* 1994, **22**:A67
- Cobean R, Beals M, Moss C, Bredenberg CE: **Percutaneous dilatational tracheostomy. A safe, cost-effective bedside procedure.** *Arch Surg* 1996, **131**:265-271.
- Mohammedi I, Vedrinne JM, Ceruse P, Duperré S, Allaouchiche B, Motin J: **Major cellulitis following percutaneous tracheostomy.** *Intensive Care Med* 1997, **23**:443-444.
- Law RC, Carney AS, Manara AR: **Long-term outcome after percutaneous dilatational tracheostomy. Endoscopic and spirometry findings.** *Anaesthesia* 1997, **52**:51-56.
- van Heurn LWE, Theunissen PHMH, Ramsay G, Brink PRG: **Pathologic changes of the trachea after percutaneous dilatational tracheostomy.** *Chest* 1996, **109**:1466-1469.
- Upadhyay A, Maurer J, Turner J, Tiszenkel H, Rosengart T: **Elective bedside tracheostomy in the intensive care unit.** *J Am Coll Surg* 1996, **182**:51-55.
- Wease GL, Frikker M, Villalba M, Glover J: **Bedside tracheostomy in the intensive care unit.** *Arch Surg* 1996, **131**:552-555.

R10 **Critical Care** 1999, Vol 3 No 2

48. Stoeckli SJ, Breitbach T, Schmid S: **A clinical and histologic comparison of percutaneous dilational versus conventional surgical tracheostomy.** *Laryngoscope* 1997, **107**:1643-1646.
49. Arola MK: **Tracheostomy and its complications. A retrospective study of 794 tracheostomized patients.** *Ann Chir Gynaecol* 1981, **70**:96-106.
50. Waldron J, Padgham ND, Hurley SE: **Complications of emergency and elective tracheostomy: a retrospective study of 150 consecutive cases.** *J R Coll Surg Eng* 1990, **72**:218-220.
51. Rosenbower TJ, Morris JA Jr., Eddy VA, Ries WR: **The long-term complications of percutaneous dilatational tracheostomy.** *Am Surg* 1998, **64**:82-86.