

Case Report

Modified Whipple on an 18-month-old with traumatic pancreatic transection and duodenal rupture^{☆, ☆ ☆}

Elise Hyser^{a,*}, Hanna S. Sahhar^{a,b}, Claude Woollen^b

^a Edward Via College of Osteopathic Medicine (VCOM)-Carolinas Campus, United States of America

^b Spartanburg Regional Healthcare System, United States of America

ARTICLE INFO

Keywords:

Pylorus-preserving pancreaticoduodenectomy (PPPD)
 Traditional or pylorus-resecting pancreaticoduodenectomy (PRPD)
 Pancreatic transection
 Duodenal rupture
 Paediatric abdominal trauma

ABSTRACT

The emergence of the Whipple procedure revolutionized operative management of pancreatic disease since its introduction (Fernandez-del Castillo et al., 2012 [1]). This operation classically involves removal of the head of the pancreas along with the duodenum, gallbladder, a portion of the bile duct, and part of the stomach (Warshaw and Thayer, 2004; Evans et al., 2007 [2,3]). We report a beneficial outcome of a modified Whipple on a paediatric trauma patient post-motor vehicle accident (MVA). After Advanced Trauma Life Support (ATLS) was initiated and haemodynamic stability was achieved, exploratory laparotomy revealed pancreatic transection and duodenal rupture. Partial pancreaticoduodenectomy, pancreaticoduodenostomy, cholecystojejunostomy, and pyloric-sparing gastrojejunostomy were performed. Post-operative acute pancreatitis resolved with antibiotics and supportive care.

While paediatric abdominal trauma does not typically warrant a Whipple, patients with severe injury to the pancreas and neighboring organs with major vascular injury may offer no other intra-operative choice (Adams, 2014; Thatte and Vaze, 2014; Debi et al., 2013 [4–6]). Our patient's growth was followed post-operatively. At a 20-year post-operative follow-up, he reported no further hospitalizations or complications such as diabetes, biliary stricture, gallstones, or growth retardation. We review the literature to expose the novelty of using a Whipple to treat paediatric abdominal trauma, and the advantages of a pylorus-preserving Whipple. Indications for damage control surgery and non-operative management were contrasted with those for definitive surgery to reconstruct the biliary tree to further elucidate why the latter option was chosen.

Introduction

Trauma constitutes a major global cause of childhood morbidity and mortality [7]. Children are more susceptible to multi-organ injury from abdominal trauma due to their larger surface area to volume ratio, reduced muscle mass and fat in the abdominal wall, and greater thoracic cage compliance versus adults [7]. Pancreatic injuries comprise 3–12% of cases of blunt abdominal trauma among children [8]. According to guidelines from The American Association for the Surgery of Trauma (AAST), pancreatic injury

* Institutions to which work was attributed: Edward Via College of Osteopathic Medicine (VCOM)- Carolinas Campus, 350 Howard St., Spartanburg, SC, 29303; Spartanburg Regional Healthcare System, 101 E. Wood St., Spartanburg, SC, 29303.

** Meetings where this topic was presented: American College of Osteopathic Pediatricians (ACOP) Conference: April 2017; Virginia Osteopathic Medical Association (VOMA) Conference: September 2018; VCOM Research Day: April 2017.

* Corresponding author at: 147 Oakmont Dr., Deerfield, IL 60015, United States of America.

E-mail addresses: ehyser@carolinas.vcom.edu (E. Hyser), hsahhar@carolinas.vcom.edu (H.S. Sahhar), cwoollen@srhs.com (C. Woollen).

classified as grade III or higher necessitates operative management due to involvement of the main pancreatic duct [6,8]. Early surgery in cases of main pancreatic duct transection curbs local and systemic side effects of pancreatic secretion which follow [9]. The presence of concurrent injuries may also prompt surgical intervention [9,10].

AAST guidelines are not specific to paediatrics. Some studies support non-operative management for paediatric pancreatic injuries classified as grade III. A retrospective study from 1998 examined the role of non-operative management for pancreatic transections and contusions in children [11]. 28 of 35 paediatric pancreatic trauma cases treated over a 10-year period were treated non-operatively [11]. Fourteen of them had pancreatic contusion while 11 had pancreatic transection [11]. Enteral feedings were withheld and total parenteral nutrition was delivered until clinical, laboratory, and radiographic findings improved [11]. Surgical exploration was used for associated injuries [11]. Another retrospective study in 2008 described a role for non-operative management in blunt paediatric pancreatic injuries, but in this case only five patients suffered injury to the main pancreatic duct [12]. While these studies elucidate a role for non-operative management in paediatric patients with pancreatic contusion or transection, patients with concomitant injuries to surrounding organs benefit from definitive operative management.

We report a case of pancreatic transection and duodenal rupture which was treated with a PPPD. We review 2 retrospective studies, a meta-analysis, a prospective study, a comparative study, a review article, and three randomized controlled trials to compare operative outcomes for PRPD vs. PPPD [13–19]. We also explore the historical use of pancreaticoduodenectomies on paediatric trauma cases by reviewing two case reports and one case series [4,5,20]. There is also an analysis of 2 retrospective studies as well as a review article on indications for damage control surgery [21–23]. Finally, we examine a prospective and a retrospective study which explore general indications for pancreaticoduodenectomies in trauma patients [24,25]. Most surgical cases utilize a traditional Whipple to treat periampullary tumors rather than abdominal trauma. Few paediatric trauma cases are managed with a PPPD, and most lack the long-term favourable outcome observed in our patient.

Case report

An 18-month-old male presented to the hospital as an unrestrained MVA victim. Prior to admission, he was in a semi-comatose state with decreased respirations and vomiting. He was transported to the hospital with cervical collar, long spine board, and non-rebreather mask with assisted respirations. Upon arrival, physical exam revealed an afebrile 18-month-old with the following paediatric vitals: blood pressure 95/70 mm Hg, pulse 132 beats per minute, respiratory rate 8 breaths per minute, and oxygen saturation 0.88. Altered mental status and decreased lower extremity tone were observed, and the Glasgow Coma Score was 8. ATLS was instituted. Admission labs demonstrated a blood glucose of 12.0 mmol/L, AST 9.64 μ kat/L, haemoglobin 97 g/L, and urine dipstick revealed 2+ blood. The child was resuscitated prior to obtaining imaging. Head CT ruled out haemorrhage and abdominal CT confirmed free fluid in the abdomen. At this point, the child was haemodynamically stable and taken to surgery where a transected pancreas and ruptured duodenum were identified at exploratory laparotomy. The severity and extent of damage prompted the use of a pylorus-preserving Whipple variant to reconstruct and repair his injuries. This involved a partial pancreaticoduodenectomy with 1) pancreaticoduodenostomy, 2) cholecystojejunostomy, and 3) pyloric-sparing gastrojejunostomy (Figs. 1 and 2). A Jackson-Pratt drain and feeding tube were placed as well.

Post-operatively, he developed pancreatitis which resolved with antibiotics and supportive care. Insulin was used to control serum glucose. The Jackson-Pratt drain was removed once amylase and lipase levels normalized. The feeding tube was eventually removed once GI tract function returned, and he was discharged on the 25th post-operative day.

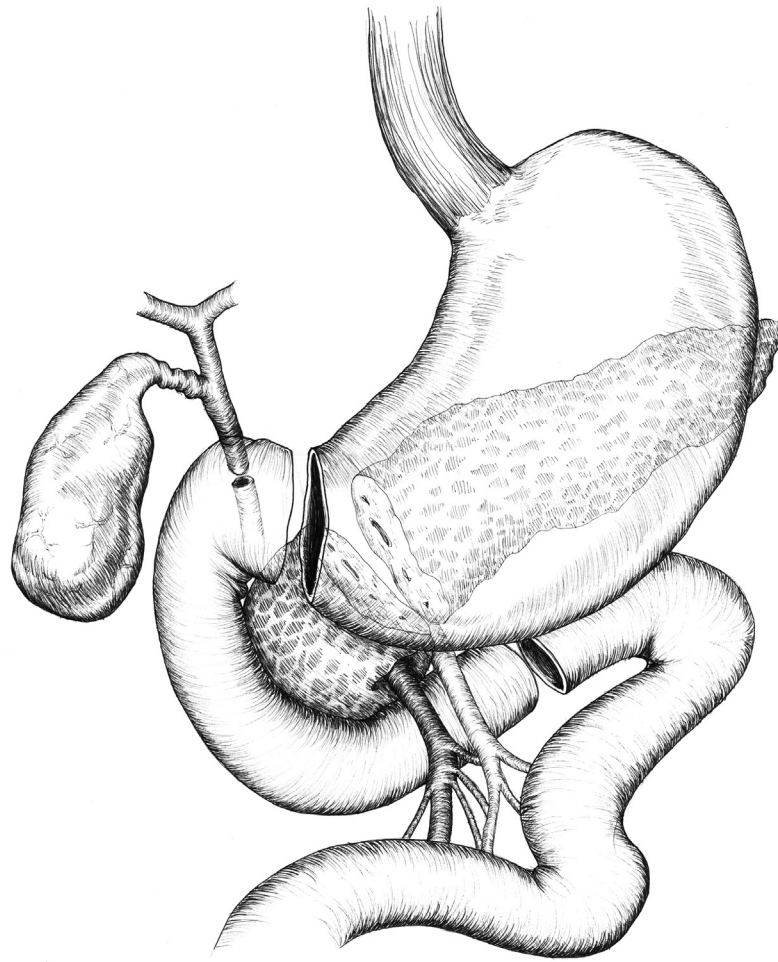
At a follow-up visit 20 years after the procedure, the patient reported no diabetes, jaundice, gallstones, or further hospitalizations, and he achieved a normal height (1.78 m) and weight (78.47 kg). He reported a mild intolerance to fatty foods. Childhood records indicate he was at or above the 50th percentile for height and weight.

Discussion

In 1918, surgical exploration for abdominal injuries became widely accepted as a mainstay of treatment [26]. However, non-operative management became a stronger consideration in treating paediatric abdominal injuries in the 1990s based on a study from Toronto where a series of paediatric patients with splenic injuries were managed non-operatively [26]. Certain liver injuries were also found amenable to observation [26]. The advent of CT scanning brought about this evolution in treatment. The decision about whether or not to operate is driven by the type and extent of the injury in addition to patient stability [10,26].

Damage control surgery was described in the 1980s as an option for haemodynamically unstable abdominal trauma patients with severe exsanguinating injuries [21]. Patients who demonstrate the triad of coagulopathy, hypothermia, and acidosis in emergency situations are candidates for it [22]. It is accomplished by initial abbreviated laparotomy, correction of abnormal physiological parameters, and later definitive injury repair during a second operation [21]. A 3 ½ year retrospective study evaluated the medical records of 46 patients who suffered penetrating abdominal trauma which necessitated laparotomy and urgent transfusion of over 10 units of packed red blood cells [22]. A subset of 22 patients who had major vascular injury plus at least two visceral injuries showed improved survival when managed with damage control surgery [22]. Definitive laparotomy was preferable to damage control surgery in our case because ATLS was successful and haemodynamic stability was restored prior to the patient's arrival in the operating room. A PPPD facilitated an optimal recovery in our case by addressing each of the patient's various injuries simultaneously.

A retrospective study conducted from 1996 to 2010 represents one of the largest series of patients managed with damage control surgery or staged-Whipple for complex pancreaticoduodenal trauma [23]. Of 15 patients who had a pancreaticoduodenectomy, 12



Caroline Dillard
3/31/17

Fig. 1. Partial pancreaticoduodenectomy with the following transections was performed on our patient with a damaged pancreas and duodenum.

had damage control surgery \pm the initial stage of Whipple resection as a first operation, and 3 had a complete standard Whipple as a first operation [23]. Thirteen patients demonstrated the coagulopathy-hypothermia-acidosis triad at first operation [23]. There were no statistically significant differences in complication rates between damage control surgery and pancreaticoduodenectomy [23]. This study confirms damage control surgery allows time to resolve the hypothermia-coagulopathy-acidosis triad. In addition, it leads to a reduction in bowel oedema and allows an initially transected bile duct to dilate and facilitate a staged reconstruction process [23]. Our patient did not present with this lethal triad and thus was a candidate for definitive operative management following stabilization by ATLS.

In 1943, Dr. Watson performed the first pylorus-preserving Whipple two years following the first traditional Whipple [27]. This modified procedure gained more public attention by Traverso and Longmire in the 1970s [13]. These surgeons consistently left the distal stomach and pylorus intact and subsequently restored continuity via duodenojejunostomy [13]. They reasoned a pylorus-preserving Whipple would optimize outcomes by promoting controlled release of gastric contents, avoiding dumping syndrome, and maintaining more normal GI tract function [13]. More specifically, it was intended to reduce the incidence of early satiety, marginal ulceration, bile reflux gastritis, and diarrhea [16].

A retrospective study, meta-analysis, and prospective study examined post-operative outcomes for PPPD vs. PRPD [13–15]. In all three studies, patients who underwent PPPD had a statistically significant decrease in operating time and blood loss compared to those who underwent PRPD [13–15]. The retrospective and prospective study showed the PPPD group had a reduced rate of delayed gastric emptying (DGE), and in the retrospective study this finding was statistically significant [13,14]. The meta-analysis showed the PRPD group had a statistically significant reduction in rate of DGE which has historically been observed but with a need for further exploration [15,16,19]. No significant difference in morbidity was observed between PPPD and PRPD [13–15].

It is suspected that sympathetic denervation of the antral and pyloric regions, coupled with relative devascularization from division of the right gastric vessels could explain DGE following PPPD [17]. This complication is transient when it occurs [16]. The

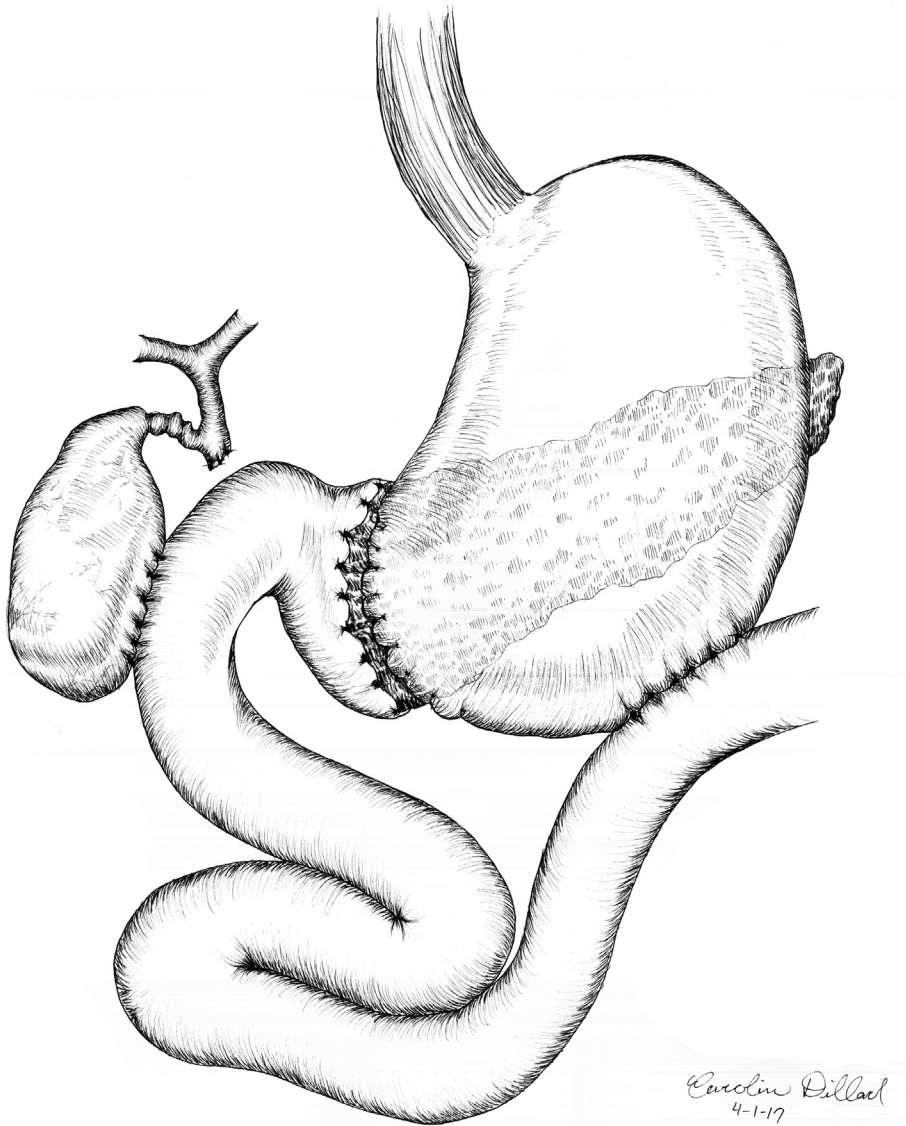


Fig. 2. Surgical reconstruction included the following three anastomoses: 1) pancreaticoduodenostomy, 2) cholecystojejunostomy, and 3) pyloric-sparing gastrojejunostomy.

PPPD is not associated with a diminished nutritional outcome [18]. Some studies show body weight and several nutritional parameters are improved with the PPPD compared to PRPD [16]. Preserving the pylorus does not lead to significant changes in the secretory/functional capacity of the upper GI tract [18]. Three randomized controlled trials comparing outcomes for PPPD vs. PRPD revealed no significant differences in quality of life in the weeks and months following surgery [19]. The PPPD group was superior to the PRPD group in one trial in the domains of appetite loss, nausea, vomiting, diarrhea, and weight gain [19].

While paediatric blunt abdominal trauma is common, pancreaticoduodenectomy is not normally used to manage it [20]. In fact, few PPPDs of the type used in this case have treated paediatric abdominal injuries without significant short and long term complications [4,5]. One case report of a PPPD on a paediatric trauma patient described the need for five abdominal surgeries before discharge [4]. Another case report of a PPPD performed on a paediatric trauma patient involved a post-operative biloma, but no other complications [5]. A case series involving operative management of 51 paediatric pancreatic injuries was associated with several post-operative complications not experienced by our patient, including 11 pancreatic fistulas, 3 pseudocysts, and 4 deaths [20].

Two studies launched in the early 1990s sought to determine indications for operative management of pancreaticoduodenal injuries. While their focus was not to compare outcomes for PPPD vs. PRPD, they facilitated operative decision-making among surgeons managing pancreaticoduodenal injuries.

A single-centre prospective study conducted over a 22-year period by Krige and his colleagues described indications for

pancreaticoduodenectomy in trauma patients. Post-operative outcomes were examined for trauma patients suffering grade 5 injuries to the pancreas and duodenum [24]. Nineteen out of 426 patients who suffered pancreatic injuries were treated with some form of pancreaticoduodenectomy, 12 of which were PPPD and 7 of which were PRPD [24]. A PPPD was utilized unless the pylorus was found to be irretrievably damaged, thereby necessitating a PRPD. Pancreaticoduodenectomy survivors suffered complications of varying levels of severity [24]. The study concluded that a pancreaticoduodenectomy, whether it is a PPPD or PRPD, can benefit a small cohort of haemodynamically stable patients whose injuries to the pancreas and surrounding organs are otherwise non-reconstructable [24].

A retrospective study from 1992 to 2002 also defined indications for pancreaticoduodenectomy in trauma patients. In this study, 18 patients with complex injuries to the pancreas and duodenum necessitating pancreaticoduodenectomy were analyzed [25]. Their indications for pancreaticoduodenectomy included the following: massive uncontrollable retropancreatic haemorrhage, massive unreconstructable trauma to the pancreatic head/main pancreatic duct as well as intrapancreatic portion/distal common bile duct, and massive unreconstructable injury in general [25]. This study revealed that significant pancreaticoduodenal injuries that call for a pancreaticoduodenectomy often involve massive disruption of the duodenopancreatic complex [25].

Another unique technical pearl involved use of the gallbladder for biliary reconstruction rather than the common bile duct. Attempting to anastomose a 2–3 mm common duct may lead to stricture and biliary cirrhosis, but the larger gallbladder conduit avoided this complication. In fact, in the 2014 study published by Krige and his colleagues, the gallbladder was used as a conduit for biliary enteric anastomosis when the bile duct measured under 3 mm and oedema precluded the use of a bile duct to jejunum anastomosis [24].

Several risk factors place certain patients with complex pancreaticoduodenal injuries at higher risk for early or late mortality. Uncontrolled vascular injuries or major associated injuries can increase the risk of early mortality, while infection or multi-organ failure can lead to late mortality [24]. The surgical technique used to manage our patient's multiple injuries, coupled with the recognition and treatment of his post-operative pancreatitis, contributed to his good outcome.

Conclusion

While the Whipple has been historically used to manage periampullary cancers, we describe the use of a modified Whipple on a paediatric trauma patient [1]. Judicious use of PPPD over non-operative management or damage control surgery in a small cohort of haemodynamically stable patients is advantageous. Aggressive management with early surgery for these patients with severe trauma, which may involve transection and/or devascularization of the pancreas as well as surrounding organs, is advised to curb long-term sequelae [10].

We believe preserving the pylorus led to our patient's long-term success because the PPPD is linked to good nutritional and functional status after the immediate post-operative period [14,16]. Additional use of the gallbladder as a conduit avoided anastomotic biliary stricture. Future paediatric trauma studies could explore the natural progression of a patient's condition when operative management includes decompression of the biliary tree into the gallbladder. Future experiments could also track long-term effects of a PPPD on growth and development.

Declaration of competing interest

The authors have no conflicts of interest to disclose. No funding was provided.

Acknowledgements

Jennifer Arnold, BS was involved in critical revision of the manuscript. Medical student Madison McKinney, BS worked with Dr. Claude Woollen, MD during the data gathering process. Caroline Dillard, BA created illustrations of the modified Whipple procedure used in our manuscript.

References

- [1] C. Fernandez-del Castillo, V. Morales-Oyarvide, D. McGrath, et al., Evolution of the Whipple procedure at the Massachusetts General Hospital, *Surgery* 152 (2012) S56–S63.
- [2] A.L. Warshaw, S.P. Thayer, Pancreaticoduodenectomy, *J. Gastrointest. Surg.* 8 (2004) 733–741.
- [3] D.B. Evans, J.E. Lee, E.P. Tamm, P.W.T. Pisters, Pancreaticoduodenectomy (Whipple operation) and total pancreatectomy for cancer, in: J.E. Fischer, K.I. Bland (Eds.), *Mastery of Surgery*, Lippincott Williams & Wilkins, Philadelphia (PA), 2007, pp. 1299–1317.
- [4] E. Adams, In rare procedure, doctors team up to control 12-year-old's injuries following car accident, *KY Forward*, 2014.
- [5] M.D. Thatte, D. Vaze, Pancreaticoduodenectomy for paediatric pancreatic trauma with a decade of follow-up, *Afr. J. Paediatr. Surg.* 11 (2014) 62–64.
- [6] U. Debi, R. Kaur, K.K. Prasad, S.J. Sinha, A. Sinha, K. Singh, Pancreatic trauma: a concise review, *World J. Gastroenterol.* 19 (2013) 9003–9011.
- [7] S. Guralnick, Blunt abdominal trauma, *Pediatr. Rev.* 29 (2008) 294–295.
- [8] C.W. Iqbal SD St, K. Tsao Peter, et al., Operative vs. nonoperative management for blunt pancreatic transection in children: multi-institutional outcomes, *J. Am. Coll. Surg.* 218 (2014) 157–162.
- [9] P. Wind, E. Turet, C. Cunningham, P. Frileux, P.H. Cugnenc, R. Parc, Contribution of endoscopic retrograde pancreatography in management of complications following distal pancreatic trauma, *Am. Surg.* 65 (1999) 777–783.
- [10] M. Nikfarjam, M. Rosen, T. Ponsky, Early management of traumatic pancreatic transection by spleen-preserving laparoscopic distal pancreatectomy, *J. Pediatr. Surg.* 44 (2009) 455–458.
- [11] J. Shilyansky, L.M. Sena, M. Kreller, P. Chait, P.S. Babyn, R.M. Filler, et al., Nonoperative management of pancreatic injuries in children, *J. Pediatr. Surg.* 33

- (1998) 343–349.
- [12] I. de Blaauw, J.T. Winkelhorst, P.N. Rieu, F.H. van der Staak, M.H. Wijnen, R.S. Severijnen, et al., Pancreatic injury in children: good outcome of nonoperative treatment, *J. Pediatr. Surg.* 43 (2008) 1640–1643.
 - [13] S.P. Dineen, C.L. Roland, R.E. Schwarz, Pancreaticoduodenectomy with or without pyloric preservation: a clinical outcomes comparison, *HPB Surg.* (2008) (8 pages).
 - [14] M. Niedgerthmann, E. Shang, M. Farag Soliman, et al., Early and enduring nutritional and functional results of pylorus preservation vs. classic Whipple procedure for pancreatic cancer, *Langenbeck's Arch. Surg.* 391 (2006) 195–202.
 - [15] C. Yang, Wu HS, X.L. Chen, et al., Pylorus-preserving versus pylorus-resecting pancreaticoduodenectomy for periampullary and pancreatic carcinoma: a meta-analysis, *PLoS One* 9 (2014) e90316.
 - [16] Y. Ogata, S. Hishinuma, The impact of pylorus-preserving pancreaticoduodenectomy on surgical treatment for cancer of the pancreatic head, *J. Hepato-Biliary-Pancreat. Surg.* 9 (2002) 223–232.
 - [17] J. Gagnière, B. Le Roy, J. Veziat, et al., Pancreaticoduodenectomy with right gastric vessels preservation: impact on intraoperative and postoperative outcomes, *ANZ J. Surg.* 89 (2019) E147–E152.
 - [18] W. Kozuschek, H.B. Reith, H. Waleczek, W. Haarmann, M. Edelmann, D. Sonntag, A comparison of long term results of the standard Whipple procedure and the pylorus preserving pancreaticoduodenectomy, *J. Am. Coll. Surg.* 178 (1994) 443–453.
 - [19] F.J. Hüttner, C. Fitzmaurice, G. Schwarzer, et al., Pylorus-preserving pancreaticoduodenectomy (pp Whipple) versus pancreaticoduodenectomy (classic Whipple) for surgical treatment of periampullary and pancreatic carcinoma, *Cochrane Database Syst. Rev.* (2) (2016).
 - [20] J.M. Graham, W.J. Pokorny, K.L. Mattox, G.L. Jordan Jr, Surgical management of acute pancreatic injuries in children, *J. Pediatr. Surg.* 13 (1978) 693–697.
 - [21] R. Chaudhry, VSM, G.L. Tiwari, VSM, Y. Singh, VSM, Damage control surgery for abdominal trauma, *Med. J. Armed Forces India* 62 (2006) 259–262.
 - [22] M.F. Rotondo, C.W. Schwab, M.D. McGonigal, G.R. Phillips 3rd, T.M. Fruchterman, D.R. Kauder, et al., 'Damage control': an approach for improved survival in exsanguinating penetrating abdominal injury, *J. Trauma* 35 (1993) 375–382.
 - [23] C.M. Thompson, S. Shalhub, Z.M. DeBoard, R.V. Maier, Revisiting the pancreaticoduodenectomy for trauma: a single institution's experience, *J. Trauma Acute Care Surg.* 75 (2013) 225–228.
 - [24] J.E. Krige, A.J. Nicol, P.H. Navsaria, Emergency pancreaticoduodenectomy for complex injuries of the pancreas and duodenum, *HPB (Oxford)* 16 (2014) 1043–1049.
 - [25] J.A. Asensio, P. Petrone, G. Roldán, E. Kuncir, D. Demetriades, Pancreaticoduodenectomy: a rare procedure for the management of complex pancreaticoduodenal injuries, *J. Am. Coll. Surg.* 197 (2003) 937–942.
 - [26] A. Stoffan, D.P. Mooney, Abdominal trauma, in: M.M. Ziegler, R.G. Azizkhan, D. von Allmen, T.R. Weber (Eds.), *Operative Pediatric Surgery*, McGraw-Hill Education, China, 2014(Chapter 81).
 - [27] K. Watson, Carcinoma of the ampulla of Vater successful radical resection, *BJS* 31 (1944) 368–373.