

Case Report

Open Access

Simon Thönnnes*, Heiko Sorg, Jörg Hauser and Daniel J. Tilkorn

Localized eosinophilic fasciitis (Shulman's disease) as a differential diagnosis of nerve compression syndrome

DOI 10.1515/iss-2016-0203

Received December 6, 2016; accepted February 20, 2017; previously published online March 7, 2017

Abstract: A 46-year-old man presented with clinical signs of nerve compression syndrome of his right ulnar nerve as confirmed by nerve conduction studies. Unexpectedly, clinical examination and magnetic resonance imaging (MRI) revealed a subcutaneous tumor of 5×2 cm above the ulnar groove. Surgical exploration and histopathology of biopsies demonstrated the nerve distended and entrapped into an eosinophilic, inflammatory tissue. This rare condition is consistent with localized eosinophilic fasciitis, with no systemic manifestations. There are reports of isolated forearm versions of the disease. However, none occurred with the entrapment of a peripheral nerve appearing as a peripheral nerve tumor, yet. Consequently, the presented patient would not have benefited from further surgical neurolysis or tumor debulking, as eosinophilic fasciitis is an inflammatory and systemic disease. The patient's symptoms decreased spontaneously after 4 weeks of postsurgical treatment, including non-steroidal anti-inflammatory drugs (NSAIDs). Altogether, this case proved the necessity to regard even rare diseases as a potential cause of entrapment of peripheral nerves. This should lead surgeons to critical, differential diagnostic thinking and suggest that systemic diseases may be encountered during surgery due to their capability to mimic peripheral nerve tumors.

Keywords: eosinophilic fasciitis; nerve compression syndrome; peripheral nerve tumor; Shulman's disease.

Case report

We present the case of a 46-year-old man suffering from pain and dysesthesia over the ulnar nerve of his right arm for a duration of about 7 weeks. The presenting symptoms were tingling sensations in the lateral forearm and pain on palpation between the distal bicipital sulcus and the ulnar sulcus of the elbow. Electrodiagnostic examination showed a reduced nerve conduction velocity of 34.1 m/s over the affected cubital tunnel and 46 m/s distally in the forearm. The synopsis of the clinical signs leads to the patient's referral to our department with the diagnosis of nerve compression syndrome of the ulnar nerve.

Clinical evaluation showed no muscle atrophy of the upper extremity but dysesthesia in the palmar area of the fourth and fifth fingers of his right hand. The pain over the ulnar nerve was triggered by palpation of the nerve between the distal bicipital sulcus and the ulnar sulcus of the elbow, where unexpectedly a subcutaneous tumor of 5×2 cm was palpable as a pathologic correlate. Magnetic resonance imaging (MRI) revealed a tumorous malformation of the ulnar nerve proximal to the ulnar groove matching the palpated size and most likely a schwannoma (Figure 1). This supported the indication for an exploration of the ulnar nerve due to the nerve compression, most likely caused by a peripheral nerve tumor.

Surgical exploration demonstrated the ulnar nerve distended over a length of 5 cm, indurated and entrapped into an inflammatory tissue (Figure 2). The perineurium was dissected and a sample of one fascicle of the ulnar nerve was obtained. Histopathology and immunohistochemistry with S100 and cytokeratin showed a localized and granulating inflammatory process in the perineurium and the ulnar nerve itself accompanied by substantial eosinophilia in the tissue (Figure 3). In summary, the patient's ulnar nerve was compressed by a tumor of inflammatory origin, which was characterized by a substantial eosinophilia.

A literature search regarding inflammatory processes with an eosinophilic component was performed.

*Corresponding author: Simon Thönnnes, Department of Plastic, Reconstructive and Aesthetic Surgery, Hand Surgery, Alfried Krupp Krankenhaus Essen, Hellweg 100, 45276 Essen, Germany, E-mail: simonthoennes@gmx.de; simon.thoennes@krupp-krankenhaus.de

Heiko Sorg, Jörg Hauser and Daniel J. Tilkorn: Department of Plastic, Reconstructive and Aesthetic Surgery, Hand Surgery, Alfried Krupp Krankenhaus Essen, Essen, Germany

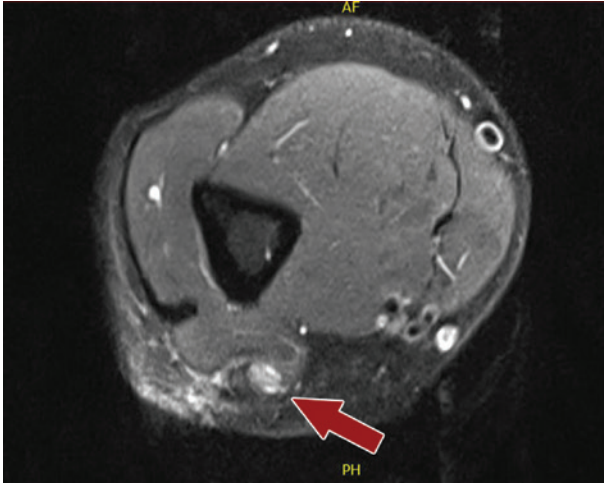


Figure 1: MRI of the right upper arm, axial section, TSE sequence. Red arrow points to the distended right ulnar nerve, which shows significant signal enhancement.

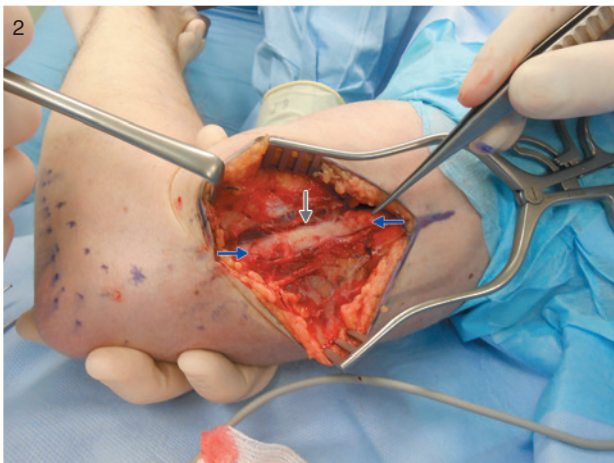

Figure 2: Intraoperative situs during surgical exploration of the patient's right ulnar nerve. Incision of the right arm between the distal bicipital sulcus and the cubital tunnel. The ulnar nerve appears distended (gray arrow) and entrapped in inflammatory tissue (blue arrows).

Especially, histopathologic details directed the attention to eosinophilic fasciitis as a potential underlying disease. This rare systemic disease was reported in the first instance by Shulman in 1984 [1]. He diagnosed a diffuse fasciitis resulting in sclerodermiform skin indurations and joint contractures accompanied by hypergammaglobulinemia and the name-giving eosinophilia in the blood.

A comparison of our case to the current case series of eosinophilic fasciitis indicated that the here presented patient's age is typical for the primary appearance of the disease [1–3]. On the contrary, none of the described associated factors, such as arthropod-induced diseases

(e.g. borreliosis), medication with statins or phenytoin, and severe disease of the thyroid or bone marrow (Table 1) [2, 4], were identified in our case. Laboratory diagnostics showed typical eosinophilia of the disease neither initially nor in the 6-month follow-up examination. Typical sclerodermiform signs such as skin indurations or negative vein patterns [2] were not observed in any examination. Furthermore, there was no suggestion that the disease developed in its typical symmetric manifestation.

Because our patient presented a particularly localized process, we decided to consult with the Clinic for Rheumatology of the University of Münster, Germany. Their evaluation as well as repeated blood examinations showed no further sign of a generalized disease and supported our diagnosis of a localized process. Therefore, the evaluation of treatment options showed the following findings.

In our case, the pathology of the nerve's entrapment revealed the diagnosis of eosinophilic fasciitis. As eosinophilic fasciitis is an inflammatory and usually systemic disease, the general treatment consists of immunosuppression with common drugs, especially corticosteroids, in compliance with the actual literature [3]. Any further surgical procedure such as tumor debulking or neurolysis was considered to be unrewarding in this special situation. Furthermore, in the author's opinion, an additional surgical event would have the possible side effect of extensive scarring and could cause an even more severe entrapment of the nerve. However, in the patient's good state of health with no systemic affection by the disease, there was currently no indication for a systemic therapy with corticosteroids. After a period of 4 weeks of intensive follow-ups combined with nonsteroidal anti-inflammatory drug (NSAID) treatment (diclofenac and later ibuprofen in reducing doses), the patient reported strongly attenuating neurologic symptoms over time.

In conclusion, the ulnar nerve of a 46-year-old male patient was entrapped by inflammatory tissue with substantial eosinophilia resulting in nerve compression syndrome. As eosinophilia and eosinophilic fasciitis known as Shulman's disease are rare conditions, however, this might be a potential differential diagnosis for the underlying disease by first instance. Interestingly, there are reports in the literature that eosinophilic fasciitis occurs with isolated hand or forearm involvement and may cause carpal tunnel syndrome [2, 3] and in one case even an ulnar neuropathy [2, 3, 5] (Table 2). However, there is not yet a description of nerve compression syndrome with a localized entrapping of a peripheral nerve appearing as a peripheral nerve tumor like in our case. Altogether, this case proved the necessity to regard even rare diseases as a potential cause of an entrapment of peripheral nerves.

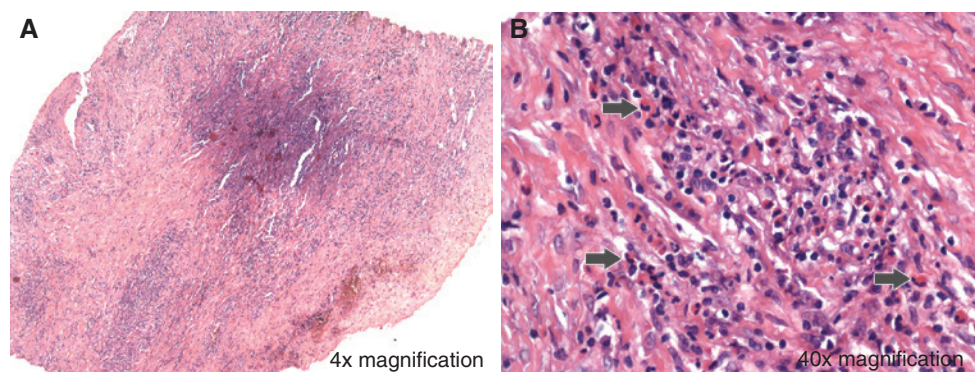


Figure 3: Histopathologic sections of the ulnar nerve (hematoxylin-and-eosin stain). (A) Overview of a transversal section of the nerve fascicle. (B) Details of the inflammatory invasion of the nerve tissue accompanied by substantial eosinophilia (gray arrows mark representative eosinophilic granulocytes).

Table 1: Factors associated with the development of eosinophilic fasciitis.

Medication	Severe diseases	Infections	Activity
Simvastatin	Myeloproliferative illnesses	Arthropod bites	Extreme physical exertion
Atorvastatin	Bone marrow transplantation	<i>Borrelia</i> infection	
Lansoprazol	Hemodialysis		
Phenytoin	Thyroid diseases		

Table 2: Differential diagnosis of eosinophilic fasciitis.

Generalized eosinophilic fasciitis	Isolated version of eosinophilic fasciitis
Scleroderma	Tendonitis
Pseudoscleroderma	Carpal tunnel syndrome
Fibromyalgia	
Toxic oil syndrome	
Lyme disease	

This should lead surgeons to critical, differential diagnostic thinking and suggest that systemic diseases may be encountered during surgery due to their capability to mimic peripheral nerve tumors.

Author Statement

Funding: Authors state no funding involved. Conflict of interest: Authors state no conflict of interest. Informed consent: Informed consent has been obtained from all individuals. Ethical approval: The research related to human use complies with all the relevant national regulations and institutional policies and was performed in accordance the tenets of the Helsinki Declaration.

Author Contributions

Simon Thönnnes: Design of the study; Data retrieval; Data analysis; Writing of the manuscript; Revision of the

manuscript; Approval of the manuscript. Heiko Sorg: Design of the study; Data retrieval; Data analysis; Writing of the manuscript; Revision of the manuscript; Approval of the manuscript. Jörg Hauser: Design of the study; Revision of the manuscript; Approval of the manuscript; Analysis of literature. Daniel J. Tilkorn: Design of the study; Data retrieval; Writing of the manuscript; Revision of the manuscript; Approval of the manuscript; Data analysis; Analysis of literature.

References

- [1] Shulman LE. Diffuse fasciitis with hypergammaglobulinemia and eosinophilia: a new syndrome? *J Rheumatol* 1984;11:569–570.
- [2] Bischoff L, Derk CT. Eosinophilic fasciitis: demographics, disease pattern and response to treatment: report of 12 cases and review of the literature. *Int J Dermatol* 2008;47:29–35.
- [3] Berianu F, Cohen MD, Abril A, Ginsburg WW. Eosinophilic fasciitis: clinical characteristics and response to methotrexate. *Int J Rheum Dis* 2015;18:91–98.
- [4] Horacek E, Sator PG, Gschnait F. ‘Venous furrowing’: a clue to the diagnosis of eosinophilic fasciitis. A case of eosinophilic fasciitis ultimately treated with oral PUVA therapy. *Dermatology* 2007;215:89–90.
- [5] Fabri M, Hunzelmann N. Differential diagnosis of scleroderma and pseudoscleroderma. *J Dtsch Dermatol Ges* 2007;5:977–984.

Supplemental Material: The article (DOI: 10.1515/iss-2016-0203) offers reviewer assessments as supplementary material.

Reviewer Assessment

Open Access

Simon Thönnnes*, Heiko Sorg, Jörg Hauser and Daniel J. Tilkorn

Localized eosinophilic fasciitis (Shulman's disease) as a differential diagnosis of nerve compression syndrome

DOI 10.1515/iss-2016-0203

Received December 6, 2016; accepted February 20, 2017

*Corresponding author: Simon Thönnnes,

Department of Plastic, Reconstructive and Aesthetic Surgery, Hand Surgery, Alfried Krupp Krankenhaus Essen, Hellweg 100, 45276 Essen, Germany, E-mail: simonthoennes@gmx.de; simon.thoennes@krupp-krankenhaus.de

Reviewers' Comments to Original Submission

Reviewer 1: Holger Bannasch

Jan 09, 2017

Reviewer Recommendation Term: Accept with Minor Revision
Overall Reviewer Manuscript Rating: 65

Custom Review Questions

Custom Review Questions	Response
Is the subject area appropriate for you?	4
Does the title clearly reflect the paper's content?	4
Does the abstract clearly reflect the paper's content?	5 - High/Yes
Do the keywords clearly reflect the paper's content?	4
Does the introduction present the problem clearly?	4
Are the results/conclusions justified?	4
How comprehensive and up-to-date is the subject matter presented?	3
How adequate is the data presentation?	4
Are units and terminology used correctly?	5 - High/Yes
Is the number of cases adequate?	4
Are the experimental methods/clinical studies adequate?	4
Is the length appropriate in relation to the content?	4
Does the reader get new insights from the article?	4
Please rate the practical significance.	2
Please rate the accuracy of methods.	3
Please rate the statistical evaluation and quality control.	N/A
Please rate the appropriateness of the figures and tables.	3
Please rate the appropriateness of the references.	4
Please evaluate the writing style and use of language.	5 - High/Yes
Please judge the overall scientific quality of the manuscript.	3
Are you willing to review the revision of this manuscript?	Yes

Comments to Authors:

This is an interesting case report on a rare disease as a differential diagnosis of a nerve compression syndrome.
The article is written comprehensive and concise.
The quality of figures 2A and 2B is low, therefore one of them can be omitted.

I have a question regarding the MRI interpretation: Can the radiologist retrospectively comment on the totally different diagnosis?

Reviewer 2: Thomas Kremer

Jan 16, 2017

Reviewer Recommendation Term:

Accept with Minor Revision

Overall Reviewer Manuscript Rating:

N/A

Custom Review Questions**Response**

Is the subject area appropriate for you?	5 - High/Yes
Does the title clearly reflect the paper's content?	5 - High/Yes
Does the abstract clearly reflect the paper's content?	5 - High/Yes
Do the keywords clearly reflect the paper's content?	5 - High/Yes
Does the introduction present the problem clearly?	4
Are the results/conclusions justified?	5 - High/Yes
How comprehensive and up-to-date is the subject matter presented?	4
How adequate is the data presentation?	N/A
Are units and terminology used correctly?	N/A
Is the number of cases adequate?	N/A
Are the experimental methods/clinical studies adequate?	N/A
Is the length appropriate in relation to the content?	4
Does the reader get new insights from the article?	4
Please rate the practical significance.	3
Please rate the accuracy of methods.	N/A
Please rate the statistical evaluation and quality control.	N/A
Please rate the appropriateness of the figures and tables.	4
Please rate the appropriateness of the references.	4
Please evaluate the writing style and use of language.	2
Please judge the overall scientific quality of the manuscript.	4
Are you willing to review the revision of this manuscript?	Yes

Comments to Authors:

The authors describe an interesting case of a rare disease and provide a very good overview on differential diagnoses. Overall the manuscript merits publication in ISS. However, a few issues should be addressed.

General: Overall, the manuscript is written well. However, some of the paragraphs should be edited by a native English Speaker to improve the English-

Abstract: As I understand, the authors did not perform any surgical procedure in Addition to the Biopsy and the patients# symptoms resolved spontaneously over time. This should be made more clear.

Case Report: The preoperative Evaluation is well presented in paragraphs 1 and 2. Likewise, the surgical procedure (biopsy) is well presented. However, I do not really understand why the authors did not perform a „Tumor“ debulking in a second procedure. Why did the authors not open the cubital tunnel, secondarily? The authors should describe the different Treatment Option in more Detail and justify their choice. „Further surgical neurolysis or tumor debulking would not have been of a benefit either,...“ is not enough. What else did the authors do (e.g. antiinflammatory drugs [NSAIDs], physical therapy). Overall, the authors provide good Information on differential diagnoses but should also provide more Information on different Treatment Options.

Conclusion: I agree with the authors' conclusion.

Literature: Only a few citations are provided by the authors. However, Literature selection and relevance is appropriate and related to the rarity of the disease.

Figures: The figures and legends are appropriate. However, the Definition of figures 2A and B should be improved.

Authors' Response to Reviewer Comments

Jan 23, 2017

REVIEWER #1:

Thank you very much for appreciating the value of our case report elucidating the appearance of a rare disease and its differential diagnosis.

1. "The quality of figures 2A and 2B is low, therefore one of them can be omitted."

We thank the reviewer for his comment. In the revised version of the manuscript the quality of the given figure is increased and reduced to only on image.

2. "Can the radiologist retrospectively comment on the totally different diagnosis?"

We have discussed this case with different radiologists which have all be uncertain and were unable to allow a clear unambiguous diagnosis by first instance. However, they rated the case most likely as a tumorous process. After the description of the diagnosis with the current knowledge the radiologists did not changed their initial statement, however, weakened it that this kind of process might also be of inflammatory origin. None of the contacted radiologists had ever seen such a rare disease at this particular part of the body.

REVIEWER #2:

The authors very much appreciate that the manuscript transported the interest in this rare case and its differential diagnosis. That is the exact intention of this case report.

1. "...some of the paragraphs should be edited by a native English Speaker to improve the English "

The revised version of the manuscript was proof-read by a native speaker to address this issue in general. Please see all corrections given by orange font and underlining throughout the manuscript.

2. "Abstract: As I understand, the authors did not perform any surgical procedure in Addition to the Biopsy and the patients# symptoms resolved spontaneously over time. This should be made more clear."

The reviewer is completely right. There was no additional surgical procedure performed other than the biopsy. We changed this by adding a new paragraph which reads now as follows:

Consequentially, the presented patient would not have benefitted from further surgical neuolysis or tumor debulking since the eosinophilic fasciitis is an inflammatory and systemic disease. The patient's symptoms decreased spontaneously, after four week of post-surgical treatment including NSAIDs.

3. "Case report: However, I do not really understand, why the authors did not perform a "Tumor" debulking in a second procedure. Why did the authors not open the cubital tunnel, secondarily?"

Since the pathology revealed the diagnosis of a localized eosinophilic fasciitis there was no indication for a second surgical procedure. The reason is that this disease is treated solely by immunomodulation /-suppression. Therefore, a second surgical procedure wouldn't have been of any benefit. Most probably it would have led to an extensive scaring with a small chance of relief of the symptoms. In addition, a dissection of the cubital tunnel was and is not needed in the author's opinion because the "pseudo"-tumor was located above the cubital tunnel and was most likely the reason for the patient's clinical symptoms.

The new paragraph in the manuscript reads now as follows:

Therefore, the evaluation of treatment options showed the following:

In our case the pathology of the nerve's entrapment revealed the diagnosis of an eosinophilic fasciitis. Since the eosinophilic fasciitis is an inflammatory and usually systemic disease the general treatment consists of immune suppression with common drugs, especially corticosteroids in compliance with the actual literature [3]. Any further surgical procedure like tumor debulking or neurolysis was considered to be unrewarding in this special situation. Furthermore, in the author's opinion an additional surgical event would have the possible side effect of extensive scaring and could cause an even more severe entrapment of the nerve. However, in the patient's good state of health with no systemic affection by the disease there was currently no indication for a systemic therapy with corticosteroids. After a period of four weeks of intensive follow-ups combined with a NSAID-treatment (diclofenac and later ibuprofen in reducing doses) the patient reported of strongly attenuating neurologic symptoms over time.

4. "Case report: The authors should describe the different treatment option in more detail and justify their choice."

The authors agree with the reviewer's critique and therefore the paragraph about the treatment was edited and should now provide more information about the different treatment options in this case and why we have chosen the described one in the manuscript. This is now added in the revised version of the manuscript, marked by orange font and underlining and reads as follows:

Therefore, the evaluation of treatment options showed the following:

In our case the pathology of the nerve's entrapment revealed the diagnosis of an eosinophilic fasciitis. Since the eosinophilic fasciitis is an inflammatory and usually systemic disease the general treatment consists of immune suppression with common drugs, especially corticosteroids in compliance with the actual literature [3]. Any further surgical procedure like tumor debulking or neurolysis was considered to be unrewarding in this special situation. Furthermore, in the author's opinion an additional surgical event would have the possible side effect of extensive scarring and could cause an even more severe entrapment of the nerve. However, in the patient's good state of health with no systemic affection by the disease there was no currently indication for a systemic therapy with corticosteroids. After a period of four weeks of intensive follow-ups combined with a NSAID-treatment (diclofenac and later ibuprofen in reducing doses) the patient reported of strongly attenuating neurologic symptoms over time.

5. "Literature: Only a few citations are provided by the authors. However, Literature selection and relevance is appropriate and related to the rarity of the disease."

The reviewer points out an important fact when research is performed about rare diseases: There is only a rare number of reports in literature to the one described in the here presented case report as well. Therefore, the authors tried to highlight the background and initial description of the disease. Unfortunately, there are no big epidemiology reports about the eosinophilic fasciitis at all. The most valuable reports are larger case series. Regarding the circumstances of a localized appearance – like in our case – there are only a few reports in the literature at all, which have been cited throughout the manuscript. We hope that we could still fulfill the reviewer's reasonable claim for references regarding our report.

6. "Figures: The figures and legends are appropriate. However, the Definition of figures 2A and B should be improved."

We thank the reviewer for his comment. In the revised version of the manuscript the quality of the given figure is increased and reduced to only one image.

Reviewers' Comments to Revision

Reviewer 1: Holger Bannasch

Jan 30, 2017

Reviewer Recommendation Term:	Accept
Overall Reviewer Manuscript Rating:	70
Custom Review Questions	Response
Is the subject area appropriate for you?	4
Does the title clearly reflect the paper's content?	4
Does the abstract clearly reflect the paper's content?	4
Do the keywords clearly reflect the paper's content?	3
Does the introduction present the problem clearly?	3
Are the results/conclusions justified?	4
How comprehensive and up-to-date is the subject matter presented?	4
How adequate is the data presentation?	4
Are units and terminology used correctly?	4
Is the number of cases adequate?	N/A
Are the experimental methods/clinical studies adequate?	N/A
Is the length appropriate in relation to the content?	4

Does the reader get new insights from the article?	4
Please rate the practical significance.	3
Please rate the accuracy of methods.	2
Please rate the statistical evaluation and quality control.	N/A
Please rate the appropriateness of the figures and tables.	3
Please rate the appropriateness of the references.	4
Please evaluate the writing style and use of language.	4
Please judge the overall scientific quality of the manuscript.	3
Are you willing to review the revision of this manuscript?	Yes

Comments to Authors:

-

Reviewer 2: Thomas Kremer

Feb 17, 2017

Reviewer Recommendation Term: Accept
Overall Reviewer Manuscript Rating: 80

Custom Review Questions

	Response
Is the subject area appropriate for you?	5 - High/Yes
Does the title clearly reflect the paper's content?	5 - High/Yes
Does the abstract clearly reflect the paper's content?	5 - High/Yes
Do the keywords clearly reflect the paper's content?	5 - High/Yes
Does the introduction present the problem clearly?	5 - High/Yes
Are the results/conclusions justified?	5 - High/Yes
How comprehensive and up-to-date is the subject matter presented?	5 - High/Yes
How adequate is the data presentation?	5 - High/Yes
Are units and terminology used correctly?	N/A
Is the number of cases adequate?	N/A
Are the experimental methods/clinical studies adequate?	N/A
Is the length appropriate in relation to the content?	5 - High/Yes
Does the reader get new insights from the article?	5 - High/Yes
Please rate the practical significance.	3
Please rate the accuracy of methods.	N/A
Please rate the statistical evaluation and quality control.	N/A
Please rate the appropriateness of the figures and tables.	5 - High/Yes
Please rate the appropriateness of the references.	5 - High/Yes
Please evaluate the writing style and use of language.	5 - High/Yes
Please judge the overall scientific quality of the manuscript.	3
Are you willing to review the revision of this manuscript?	Yes

Comments to Authors:

The revised manuscript is now appropriate for publication!