

Value of CT-derived fractional flow reserve in identifying patients with acute myocardial infarction based on coronary computed tomography angiography

FEI YANG¹, ZHIYING PANG¹, ZHIXIANG YANG², YUE YANG²,
YANFEI WANG¹, PENG JIA³, DAWEI WANG⁴ and SHUJUN CUI¹

¹Department of Medical Imaging, The First Affiliated Hospital of Hebei North University; ²Graduate School, Hebei North University, Zhangjiakou, Hebei 075000; ³Department of Medical Imaging, Beijing Huairou Hospital, Beijing 101400; ⁴Department of Cardiothoracic Surgery, The First Affiliated Hospital of Hebei North University, Zhangjiakou, Hebei 075000, P.R. China

Received January 28, 2023; Accepted September 7, 2023

DOI: 10.3892/etm.2023.12258

Abstract. The aim of the present study was to determine whether coronary stenosis and computed tomography-derived fractional flow reserve (CT-FFR), detected by coronary computed tomography angiography (CCTA), can potentially contribute to distinguish acute myocardial infarction (AMI) from unstable angina (UA). The study retrospectively collected data from consecutive patients who were admitted with obstructive coronary artery disease (CAD) and who received CCTA and invasive coronary angiography (ICA) as part of their clinical workup. According to the inclusion criteria, the patients were divided into the AMI group and UA group, and the basic clinical data, CCTA stenosis degree and CT-FFR values were compared between the two groups. Univariate and multivariate logistic regression methods were used to analyze the association between $\geq 70\%$ CCTA stenosis, ≤ 0.80 CT-FFR and AMI. A diagnostic model of AMI was established (model 1, ≤ 0.80 CT-FFR; model 2, $\geq 70\%$ CCTA stenosis; and model 3, ≤ 0.80 CT-FFR combined with $\geq 70\%$ CCTA stenosis), and the diagnostic efficacy of the three models for AMI was compared. The significance level was set at $P < 0.05$. A total of 116 participants were finally enrolled in this study. There were 37 patients in the AMI group, with an average age of 62.06 ± 7.74 years, and 79 patients in the UA group, with an average age of 58.11 ± 10.0 years; there was no significant difference in age ($P > 0.05$). The multivariate

regression analysis revealed that ≤ 0.80 CT-FFR (HR=28.074; 95% CI: 5.712-137.973; $P < 0.001$), and $\geq 70\%$ CCTA stenosis (HR=10.796; 95% CI: 2.566-45.425; $P = 0.001$) were independent risk factors for AMI. The diagnostic model of ≤ 0.80 CT-FFR combined with $\geq 70\%$ CCTA stenosis (AUC=0.914; 95% CI: 0.847-0.958) exhibited increased diagnosis performance than the ≤ 0.80 CT-FFR model (AUC=0.865; 95% CI: 0.790-0.922; $P = 0.0060$) and the $\geq 70\%$ CCTA stenosis model (AUC=0.827; 95% CI: 0.745-0.891; $P = 0.0008$). Collectively, it was demonstrated that ≤ 0.80 CT-FFR and $\geq 70\%$ CCTA stenosis were independent risk factors for the diagnosis of AMI, and the combination of CT-FFR and CCTA stenosis further improved AMI diagnosis performance.

Introduction

Acute coronary syndromes (ACS) represent a spectrum of events ranging from unstable angina (UA) to acute myocardial infarction (AMI) with or without ST elevation, (1) which is the most common manifestation of coronary artery disease (CAD) and the main cause of mortality worldwide (2,3). The timely identification of AMI is crucial for determining the prognosis of a patient. In contrast to the relatively clear-cut diagnosis of AMI with ST segment elevation through electrocardiogram (ECG) analysis, the identification of patients with AMI without ST segment elevation from UA poses a significant diagnostic dilemma (4). Clinical assessment and ECG alone are insufficient for definitive confirmation or excluding the diagnosis of AMI in most patients. Consequently, troponin continues to serve as the fundamental element for promptly establishing a diagnosis and facilitating appropriate treatment (5). However, a substantial percentage of these patients will ultimately have a 'normal' invasive angiography. Therefore, there is an urgent need for alternative diagnostic strategies to avoid multiple unnecessary and invasive examinations.

Coronary computed tomography angiography (CCTA) has become a fast, accurate, reliable and noninvasive method for assessing CAD in recent decades. Compared with invasive coronary angiography (ICA), CCTA is highly accurate in

Correspondence to: Dr Dawei Wang, Department of Cardiothoracic Surgery, The First Affiliated Hospital of Hebei North University, 12 Changqing Road, Zhangjiakou, Hebei 075000, P.R. China
E-mail: 15530392140@163.com

Key words: coronary computed tomography angiography, CT-derived fractional flow reserve, acute myocardial infarction, unstable angina obstructive, coronary heart disease

assessing coronary stenosis. However, the presence of obstructive CAD on CCTA does not always result in myocardial ischemia. Numerous studies have revealed that the degree of stenosis of lesions and their effects on myocardial ischemia are often inconsistent (6,7). The ROMICAT-I trial demonstrated that only 46% of patients with obstructive CAD who were diagnosed via CCTA had abnormal single photon emission computed tomography (SPECT) perfusion findings during stress testing. Therefore, CCTA revealing >50% stenosis has limited diagnostic value for ACS (8).

CT-derived fractional flow reserve (CT-FFR) is a method that was developed for noninvasive calculation of the hemodynamic consequences of stenosis. This can be explained in the same manner as the invasive fractional flow reserve (FFR), which is the gold standard clinical method for determining the functional significance of coronary stenosis (9). CT-FFR has combined the advantages of non-invasive CCTA and traditional invasive FFR. This processing technology derives hemodynamic parameters from CCTA image data, in order to quantify the hemodynamic impact of coronary artery stenosis (10,11). A previous study revealed that CT-FFR can detect the absence of hemodynamically significant lesions in patients with high-risk ACS without ST segment elevation who are admitted to the emergency department due to chest pain (5). To date, the use of CT-FFR for risk stratification in patients with ACS has not been evaluated in any studies. Therefore, the present study aimed to assess the ability of CT-FFR to identify patients with AMI and to develop a comprehensive multiparameter AMI model with 'one-stop' CCTA.

Patients and methods

Study population. The present study involving human participants was reviewed and approved by the Institutional Review Board of the First Affiliated Hospital of Hebei North University (Zhangjiakou, China). In view of the retrospective nature of the present study, the local institutional review board waived the informed consent requirements in accordance with the national legislation and institutional requirements.

Patients admitted with suspected ACS who underwent CCTA examinations followed by ICA at the First Affiliated Hospital of Hebei North University (Zhangjiakou, China) from January 2019 to July 2020 were included in the present study. ICA is widely recognized as the gold standard in imaging for CAD. A total of 116 participants were finally enrolled in this study. The AMI group comprised 37 patients (27 males; 10 females), with an average age of 62.06 ± 7.74 years, whereas the UA group comprised 79 patients (59 males; 20 females), with an average age of 58.11 ± 10.0 years.

Adjudication of AMI and UA was performed by a panel of two cardiologists. AMI was defined as an increase and/or decrease in cardiac troponin (cTnI) levels with at least 1 value above the 99th percentile and more than one of the following clinical evidence criteria: i) Symptoms of acute myocardial ischemia (e.g., chest pain or dyspnea); ii) new ischemic ECG changes; iii) development of pathological Q waves; iv) imaging evidence of new loss of viable myocardium or new regional wall motion abnormality in a pattern consistent with an ischemic etiology; and v) identification of a coronary thrombus by angiography including intracoronary imaging or

by autopsy (12). UA was described as a symptom of myocardial ischemia, and ischemia-related ECG abnormalities were identified at rest or with minimal exertion without cardiomyocyte necrosis (13). Patients with UA had no abnormalities in their myocardial enzymes until they were discharged. In both groups, fasting blood samples were collected within 24 h of admission, followed by CCTA examinations which were performed within 3 days. cTnI was verified at admission and rechecked at 2-h intervals if negative. cTnI levels with at least one value above the 99th percentile were considered positive.

The exclusion criteria were as follows: Percutaneous coronary intervention or coronary artery bypass graft (CABG) prior to CCTA; previous AMI or UA; patients who directly underwent invasive angiography without CCTA examinations; incomplete clinical data; poor CCTA image quality; and failed CT-FFR analyses.

Based on medical records, the risk factors and baseline characteristics of patients were determined. The present study design and method for patient selection are described in Fig. 1.

CCTA acquisition. In the present study, the CCTA procedure was performed using Aquilion One 320-row volume CT (Canon Medical Systems Corporation). The ECG data of each patient was continuously monitored throughout the process. Patients with heart rate values of 75 beats/min or greater before scanning were orally administered 20–60 mg of metoprolol tartrate tablets at 1 h prior to the scanning. All of the patients were injected with 0.8 ml/kg isotonic contrast agent (iodixanol, 320 mg iodine per ml; Yangtze River Pharmaceutical Group) at a flow rate of 5.0 ml/sec with a dual-shot injector (OptiVantage DH; Mallinckrodt Tyco Healthcare). The tube current was determined by using automatic exposure control on the basis of X-ray attenuation on anterior-posterior and lateral scout images and the reconstruction kernel. By default, the tube voltage was set at 100 kVp and was manually increased to 120 kVp when the maximum automatic current was reached. With a rotation time of 350 msec and a z-coverage value of 140–160 mm, the scan range included the whole heart. In addition, the scan plan of low-dose retrospective ECG-gated technology was performed.

Two doctors with expertise in cardiovascular imaging diagnoses who were blinded to the information of the participants assessed the data to assure objectivity. In cases of disagreement, the third senior chief physician made the final evaluation. The degree of luminal stenosis was visually estimated by using a vascular diameter percentage. The degree of stenosis was noted as follows: 1–24%, minimal; 25–49%, mild; 50–69%, moderate; 70–99%, severe; and 100%, total obstruction.

The CT-FFR values were calculated from diastolic CCTA images based on the online DEEPVESSEL-FFR platform by applying the deep learning technique (Keya Medical). Coronary stenosis was deemed to be hemodynamically significant if CT-FFR was ≤ 0.80 , which was similar to invasive FFR results (14).

The following criteria were used for determination of a culprit vessel. i) A single significant stenosis that was treated by ICA was identified as the culprit vessel. ii) The revascularization treatment vessel was the culprit vessel if multiple vessels had $\geq 50\%$ luminal stenosis on the ICA. iii) The culprit lesions were located based on ECG findings, aberrant wall motion on

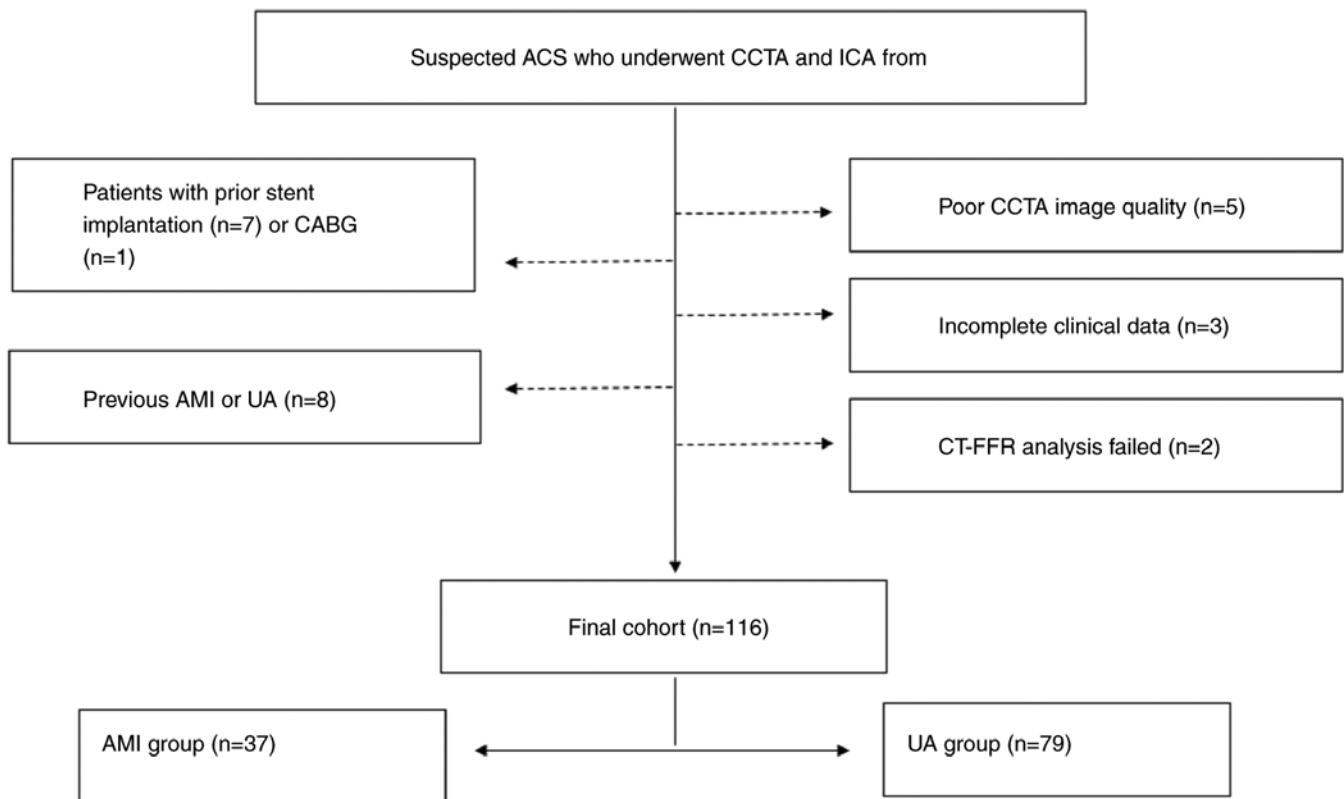


Figure 1. Flowchart diagram of the present study. ACS, acute coronary syndromes; CCTA, coronary computed tomography angiography; ICA, invasive coronary angiography; CABG, coronary artery bypass graft; AMI, acute myocardial infarction; UA, unstable angina; CT-FFR, computed tomography-derived fractional flow reserve.

echocardiography, or angiographic appearance during ICA, as previously documented (15).

Statistical analysis. The SPSS software program (version 25.0; SPSS, Inc.) and MedCalc for Windows (version 20.113; MedCalc Software) were used for all of the statistical analyses, with $P < 0.05$, considered to indicate a statistically significant difference. Continuous data are expressed as the mean \pm standard deviation. To compare the baseline characteristics, CCTA stenosis, and CT-FFR between the AMI group and UA group, an independent-samples unpaired Student's *t*-test was employed for continuous variables, while a Fisher's exact test was utilized for categorical variables. Univariate and multivariate logistic regressions were used to analyze the independent influencing factors of AMI, and the degree of association was expressed by odds ratios (ORs) and 95% confidence intervals (95% CIs). Three diagnostic models of AMI were established: Model 1, CCTA stenosis; model 2, CT-FFR; and model 3, CCTA stenosis combined with CT-FFR. The effectiveness of the three models for differentiating between AMI and UA was assessed by using the receiver operating characteristic (ROC) curve and Hosmer-Lemeshow goodness-of-fit test. The difference in the area under the ROC curve (AUC) of the three models was compared via the DeLong method (16).

Results

Patient characteristics. A total of 116 patients were finally included in the analysis. There were 37 cases in the AMI

group (27 males and 10 females), with an average age of 62.06 ± 7.74 years. There were 79 cases in the UA group (59 males and 20 females), with an average age of 58.11 ± 10.0 years. There was no significant difference in age or sex ($P > 0.05$). Moreover, there was no significant difference in smoking history, hypertension, diabetes history, hyperlipidemia history or CAD family history between the AMI group and the UA group ($P > 0.05$). There was no significant difference in chest tightness, difficulty breathing, or chest pain between the AMI group and the UA group ($P > 0.05$). In the AMI group, more patients exhibited myocardial ischemia on the ECG than in the UA group, and the difference was statistically significant ($P < 0.001$). The number of patients undergoing percutaneous coronary intervention was greater in the AMI group than in the UA group, and the difference was statistically significant ($P < 0.001$). Patient demographics and baseline characteristics are presented in Table I. The CCTA and CT-FFR images of a 67-year-old male patient are shown in Fig. 2. The CCTA revealed a hypodense plaque with severe luminal stenosis at the second turn of the right coronary artery (RCA). The CT-FFR value measured at the distal end of the plaque was 0.78.

Comparison of CCTA stenosis and CT-FFR between the AMI group and UA group. There were 34 patients (34/37) with $\geq 70\%$ CCTA stenosis in the AMI group and 21 patients (21/79) in the UA group. Statistical analyses demonstrated a disparity between the two groups ($\chi^2 = 43.107$; $P < 0.001$) (data not shown).

Table I. Baseline characteristics and clinical details of the study population.

Parameters	AMI group (n=37)	UA group (n=79)	t/χ^2	P-value
Male	27 (72.97)	59 (74.68)	0.038	0.845
Age, years	58.65±9.53	61.75±7.42	1.909	0.059
Smoking	20 (54.05)	42 (53.16)	0.008	0.929
Diabetes	11 (29.73)	24 (30.38)	0.005	0.943
Hypertension	20 (54.05)	43 (54.43)	0.001	0.97
Hyperlipidemia	9 (24.32)	15 (18.99)	0.437	0.508
CAD family	3 (8.11)	10 (12.66)	0.167	0.683
ECG suggests myocardial ischemia	15 (40.54)	5 (6.33)	20.669	<0.001
Chest tightness/difficulty breathing	13 (35.14)	42 (53.16)	3.285	0.070
Chest pain	22 (59.46)	32 (40.51)	3.638	0.056
Percutaneous coronary intervention	26 (70.27)	26 (32.91)	14.220	<0.001

Values are expressed as the mean ± standard deviation or n (%). AMI, acute myocardial infarction; UA, unstable angina; CAD, coronary artery disease; ECG, electrocardiogram.

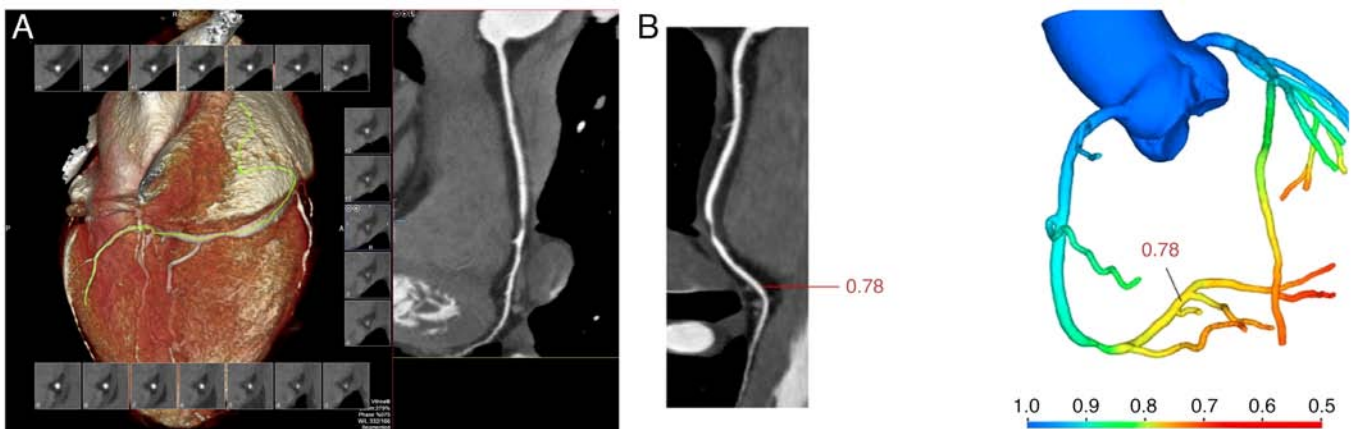


Figure 2. CCTA and CT-FFR of a male, 67-year-old patient. (A) The CCTA revealed a hypodense plaque with severe luminal stenosis at the second turn of the right coronary artery. (B) The CT-FFR value measured at the distal end of the plaque was 0.78. CCTA, coronary computed tomography angiography; CT-FFR, computed tomography-derived fractional flow reserve.

The overall CT-FFR value of the AMI group was 0.713 ± 0.079 , whereas for the UA group it was 0.833 ± 0.061 . There was a statistically significant difference between the two groups ($t=8.925$; $P<0.001$) (data not shown).

Correlations between $\geq 70\%$ CCTA stenosis, ≤ 0.80 CT-FFR and AMI. The univariate logistic regression analysis showed that $\geq 70\%$ CCTA stenosis and ≤ 0.80 CT-FFR affected the diagnosis of AMI. Among these factors, the effect of ≤ 0.80 CT-FFR was the most significant (OR=4.156; $P<0.001$). When considering all of these factors, the multivariate logistic regression analysis found that $\geq 70\%$ CCTA stenosis and ≤ 0.80 CT-FFR were independent predictors of AMI (Table II).

Comparison of the diagnostic efficacy of $\geq 70\%$ CCTA stenosis, ≤ 0.80 CT-FFR and their combined application in AMI. The

discrimination performance of each prediction model was demonstrated by the ROC curves (Fig. 3). The Hosmer-Lemeshow test showed that the model fit was good ($P>0.05$). Additionally, the combined application of $\geq 70\%$ CCTA stenosis and ≤ 0.80 CT-FFR had a significantly higher diagnostic performance for AMI than either factor alone ($P<0.001$), which was mainly due to the improvement of specificity (Table III). The pairwise comparison revealed that the AUC of the combined application model of $\geq 70\%$ CCTA stenosis and ≤ 0.80 CT-FFR was the highest (AUC=0.914; 95% CI: 0.847-0.958), which was greater than that of the $\geq 70\%$ CCTA stenosis model (AUC=0.827; 95% CI: 0.745-0.891; $P=0.0008$) and the ≤ 0.80 CT-FFR model (AUC=0.865; 95% CI: 0.790-0.922; $P=0.0060$). Moreover, there was no significant difference between the $\geq 70\%$ CCTA stenosis model and the ≤ 0.80 CT-FFR model ($P=0.2926$) (data not shown).

Table II. Univariate and multivariable logistic regression analyses of clinical characteristics, $\geq 70\%$ CCTA stenosis and ≤ 0.80 CT-FFR for AMI.

Parameters	Univariate logistic regression		Multivariable logistic regression	
	OR (95% CI)	P-value	OR (95% CI)	P-value
CCTA stenosis, $\geq 70\%$	31.302 (8.689, 112.767)	<0.001	10.796 (2.566, 45.425)	0.001
CT-FFR, ≤ 0.80	4.156 (13.922, 292.585)	<0.001	28.074 (5.712, 137.973)	<0.001
Sex	0.915 (0.378, 2.218)	0.915	N/A	N/A
Age	0.956 (0.911, 1.002)	0.062	N/A	N/A
Smoking	1.036 (0.474, 2.268)	0.929	N/A	N/A
Hypertension	0.985 (0.450, 2.156)	0.985	N/A	N/A
Diabetes	0.970 (0.413, 2.274)	0.970	N/A	N/A
Hyperlipidemia	1.371 (0.537, 3.504)	0.509	N/A	N/A

CCTA, coronary computed tomography angiography; CT-FFR, computed tomography-derived fractional flow reserve; AMI, acute myocardial infarction; OR, odds ratio; CI, confidence interval; N/A, not applicable.

Table III. Diagnostic efficacy of $\geq 70\%$ CCTA stenosis, ≤ 0.80 CT-FFR and their combined model for AMI.

Model	AUC	Sensitivity, %	Specificity, %	P-value
CCTA stenosis, $\geq 70\%$	0.827	91.89	73.42	<0.001
CT-FFR, ≤ 0.80	0.865	94.59	78.48	<0.001
CCTA stenosis + CT-FFR	0.914	89.19	88.61	<0.001

CCTA, coronary computed tomography angiography; CT-FFR, computed tomography-derived fractional flow reserve; AMI, acute myocardial infarction; AUC, area under the curve.

Discussion

The present brief study developed the diagnostic utility of CCTA stenosis and hemodynamic CT-FFR for AMI and explored a corresponding combination model. According to the findings, significant risk factors for AMI included a CT-FFR of 0.80 and a CCTA stenosis of 70%. A reliable diagnostic model for AMI with independent risk factors for $\geq 70\%$ CCTA stenosis (OR: 10.796; $P=0.001$) and ≤ 0.80 CT-FFR (OR: 28.074; $P<0.001$) could be achieved by using a combined model, which increased the diagnostic efficacy (AUC=0.914; $P<0.001$) of single parameters.

The present study found that $\geq 70\%$ CCTA stenosis was an independent predictor of AMI. Multiple relevant studies have demonstrated that the utilization of CCTA can effectively rule out AMI in patients presenting with suspected ACS in the emergency department. These studies have consistently shown that normal CCTA findings possess a remarkably high negative predictive value in excluding AMI during the initial hospitalization (17-19). However, this strategy is being challenged by the increasing recognition of the limitations of coronary stenosis severity in recent years. A threshold of $\geq 50\%$ exhibits limited sensitivity in identifying patients and lesions that will ultimately lead to AMI (20). Moreover, despite the utilization of quantitative methodologies, the efficacy of coronary stenosis severity in accurately detecting lesion-specific ischemia has not been significantly

enhanced (21). More importantly, in addition to coronary stenosis severity, numerous other factors may collectively influence flow dynamics in the vessel. Thus, it has become necessary to identify additional or improved markers to aid in the risk assessment of AMI.

In addition to coronary stenosis, CCTA can also obtain plaque characteristics, pericoronary adipose tissue (PCAT), and various parameters of hemodynamics, which may also affect the diagnosis and prognosis of patients; however, further research on this aspect is required. The SCOT-HEART study showed that low-attenuation plaque burden was the most potent predictor of AMI [adjusted hazard ratio: 1.60 (95% CI: 1.10-2.34) per doubling; $P=0.014$], regardless of coronary artery calcium score, coronary artery area stenosis, or cardiovascular risk score (22). These results elicit doubts about the dominance of the traditional risk factors for myocardial infarction, such as the degree of coronary stenosis. A recent study reported that the fat attenuation index (FAI) could not distinguish patients with AMI from patients with UA. In addition, the CCTA-based radiomics phenotype of PCAT performed better than the FAI model in differentiating AMI from UA. The combined model of PCAT radiomics and FAI can improve the effectiveness of AMI identification (23). Therefore, the radiomic characteristics of PCAT may enhance the diagnostic utility of AMI (23,24). However, the hemodynamic parameter of CT-FFR was not used in the aforementioned studies.

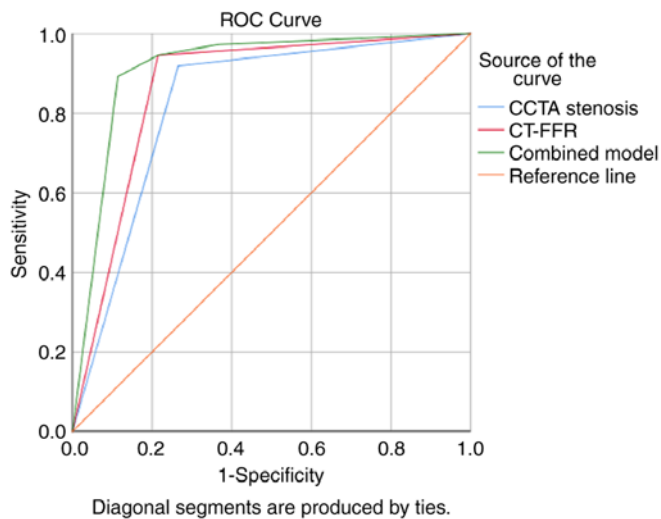


Figure 3. ROC curves of $\geq 70\%$ CCTA stenosis, ≤ 0.80 CT-FFR, and their combined model for AMI. ROC, receiver operating characteristic; CCTA, coronary computed tomography angiography; CT-FFR, computed tomography-derived fractional flow reserve; AMI, acute myocardial infarction.

CT-FFR utilizes computational fluid dynamics or machine learning to derive noninvasive FFR and assesses the hemodynamic importance of coronary artery stenosis in a noninvasive manner (25,26). Previous research has confirmed that noninvasive CT-FFR is a feasible alternative to invasive FFR for detecting and excluding ischemic coronary artery lesions (27). In multiple clinical studies, CT-FFR has demonstrated high diagnostic accuracy for myocardial ischemia caused by coronary stenosis (28,29). However, there are few reports on the application of CT-FFR for evaluating AMI. The present study demonstrated that the CT-FFR value of the AMI group was lower than that of the UA group ($P < 0.001$), and ≤ 0.80 CT-FFR was an independent predictor of AMI. As in the study by Meier *et al* (5), patients with high-risk ACS without ST segment elevation (NSTEMI-ACS) could be noninvasively identified by CCTA and CT-FFR, avoiding the need for coronary angiography and thereby reducing surgery-related risks and medical costs. Furthermore, Arena *et al* (30) assessed a combined strategy of FFR and angiography in stratifying cardiovascular risk in patients with type I myocardial infarction (TIMI) or T2MI non-ST elevation acute myocardial infarction, and they found that the combined strategy allowed the treatment of nonfunctional significant lesions to be safely deferred and patient cardiovascular risk to be identified. Therefore, it was deduced that CT-FFR is valuable in predicting risk stratification of patients with ACS.

However, the clinical value of the combined application of CCTA stenosis and CT-FFR in the diagnosis of AMI is not very clear. The results of the present study revealed that the CT-FFR of the AMI group was lower than that of the UA group, and its AUC for diagnosing AMI was 0.865. Additionally, the AUC for diagnosing AMI via CCTA stenosis was 0.827. In the present study, CT-FFR and CCTA stenosis were combined to evaluate their diagnostic efficacy for AMI, and it was found that the combined model of CT-FFR and CCTA stenosis was superior to the CT-FFR model and CCTA stenosis model, as well as the fact that the AUC increased to 0.914, suggesting

that combining anatomical, morphological, and functional data may improve its ability to diagnose AMI, guide the diagnosis and treatment strategy of patients with suspected or confirmed CAD and reduce unnecessary invasive examinations. Compared to using CT-based anatomical evaluation, adding CT-FFR further improves the model performance for identifying patients with AMI. It consequently helps to guide an appropriate therapeutic strategy and reduce unfavorable outcomes.

There were certain limitations to the present study. First, it was a single-center, retrospective case-control study with a small positive sample size, which may have resulted in a selection bias; therefore, studies with larger sample sizes are needed in the future. Second, due to the fact that this study investigated a cohort planning ICA, the incidence rate of CAD in this population was high. To validate the findings of the present study, it is necessary to conduct prospective studies in a larger study cohort. Finally, there was no invasive FFR as a control, but it has been widely confirmed that CT-FFR has a good correlation with FFR (31).

In short, the present study revealed that ≤ 0.80 CT-FFR and $\geq 70\%$ CCTA stenosis are independent risk factors for AMI, and that the combined model of CT-FFR and CCTA stenosis could further improve the performance of AMI identification, which may guide the diagnosis and treatment strategy of patients with suspected or confirmed CAD and reduce unnecessary invasive examinations.

Acknowledgements

Not applicable.

Funding

The present study was supported by the Project of Hebei Medical Science Research (grant no. 20210342) and the Project of Zhangjiakou Science and Technology Bureau of Hebei Province (grant no. 2021030D).

Availability of data and materials

The datasets used and/or analyzed during the current study are available from the corresponding author on reasonable request.

Authors' contributions

FY and DW contributed to the conception and design of the study. YY, ZY, ZP, PJ and YW conducted the data collection and the statistical analysis. FY wrote the first draft of the manuscript. SC revised the manuscript, managed the project, coordinated the study and gave final approval of the version to be published. All of the authors contributed to manuscript revision, and read and approved the final version of the manuscript. FY and DW confirm the authenticity of all the raw data.

Ethics approval and consent to participate

The present study involving human participants was reviewed and approved by the Institutional Review Board of the First Affiliated Hospital of Hebei North University (approval

no. k2020274; Zhangjiakou, China). In view of the retrospective nature of the present study, the local institutional review board waived the informed consent requirements in accordance with the national legislation and institutional requirements.

Patient consent for publication

Not applicable.

Competing interests

The authors declare that they have no competing interests.

References

- Dudas K, Björck L, Jernberg T, Lappas G, Wallentin L and Rosengren A: Differences between acute myocardial infarction and unstable angina: A longitudinal cohort study reporting findings from the register of information and knowledge about swedish heart intensive care admissions (RIKS-HIA). *BMJ Open* 3: e002155, 2013.
- Benjamin EJ, Virani SS, Callaway CW, Chamberlain AM, Chang AR, Cheng S, Chiuve SE, Cushman M, Delling FN, Deo R, *et al*: Heart disease and stroke statistics-2018 update: A Report from the american heart association. *Circulation* 137: e67-e492, 2018.
- Koskinas KC, Ughi GJ, Windecker S, Tearney GJ and Räber L: Intracoronary imaging of coronary atherosclerosis: Validation for diagnosis, prognosis and treatment. *Eur Heart J* 37: 524-535a-c, 2016.
- Grech ED and Ramsdale DR: Acute coronary syndrome: Unstable angina and non-ST segment elevation myocardial infarction. *BMJ* 326: 1259-1261, 2003.
- Meier D, Skolidis I, De Bruyne B, Qanadli SD, Rotzinger D, Eeckhout E, Collet C, Muller O and Fournier S: Ability of FFR-CT to detect the absence of hemodynamically significant lesions in patients with high-risk NSTEMI-ACS admitted in the emergency department with chest pain, study design and rationale. *Int J Cardiol Heart Vasc* 27: 100496, 2020.
- Ahmadi A, Stone GW, Leipsic J, Serruys PW, Shaw L, Hecht H, Wong G, Nørgaard BL, O'Gara PT, Chandrasekhar Y and Narula J: Association of coronary stenosis and plaque morphology with fractional flow reserve and outcomes. *JAMA Cardiol* 1: 350-357, 2016.
- Ciccarelli G, Barbato E, Toth GG, Gahl B, Xaplanteris P, Fournier S, Milkas A, Bartunek J, Vanderheyden M, Pijls N, *et al*: Angiography versus hemodynamics to predict the natural history of coronary stenoses: fractional flow reserve versus angiography in multivessel evaluation 2 substudy. *Circulation* 137: 1475-1485, 2018.
- Ahmed W, Schlett CL, Uthamalingam S, Truong QA, Koenig W, Rogers IS, Blankstein R, Nagurney JT, Tawakol A, Januzzi JL and Hoffmann U: Single resting hsTnT level predicts abnormal myocardial stress test in acute chest pain patients with normal initial standard troponin. *JACC Cardiovasc Imaging* 6: 72-82, 2013.
- Raza S and Efstathiou M: CT coronary angiogram with FFR CT-A revolution in the diagnostic flow of coronary artery disease. *J Ayub Med Coll Abbottabad* 33: 376-381, 2021.
- De Bruyne B, Fearon WF, Pijls NH, Barbato E, Tonino P, Piroth Z, Jagic N, Mobius-Winckler S, Rioufol G, Witt N, *et al*: Fractional flow reserve-guided PCI for stable coronary artery disease. *N Engl J Med* 371: 1208-1217, 2014.
- Fairbairn TA, Nieman K, Akasaka T, Nørgaard BL, Berman DS, Raff G, Hurwitz-Kowec LM, Pontone G, Kawasaki T, Sand NP, *et al*: Real-world clinical utility and impact on clinical decision-making of coronary computed tomography angiography-derived fractional flow reserve: Lessons from the ADVANCE registry. *Eur Heart J* 39: 3701-3711, 2018.
- Thygesen K, Alpert JS, Jaffe AS, Chaitman BR, Bax JJ, Morrow DA and White HD; Executive Group on behalf of the Joint European Society of Cardiology (ESC)/American College of Cardiology (ACC)/American Heart Association (AHA)/World Heart Federation (WHF) Task Force for the Universal Definition of Myocardial Infarction. Fourth universal definition of myocardial infarction (2018). *J Am Coll Cardiol* 72: 2231-2264, 2018.
- Collet JP, Thiele H, Barbato E, Barthélémy O, Bauersachs J, Bhatt DL, Dendale P, Dorobantu M, Edvardsen T, Folliguet T, *et al*: 2020 ESC guidelines for the management of acute coronary syndromes in patients presenting without persistent ST-segment elevation. *Eur Heart J* 42: 1289-1367, 2021.
- Matsumura-Nakano Y, Kawaji T, Shiomi H, Kawai-Miyake K, Kataoka M, Koizumi K, Matsuda A, Kitano K, Yoshida M, Watanabe H, *et al*: Optimal cutoff value of fractional flow reserve derived from coronary computed tomography angiography for predicting hemodynamically significant coronary artery disease. *Circ Cardiovasc Imaging* 12: e008905, 2019.
- Dey D, Achenbach S, Schuhbaeck A, Pflederer T, Nakazato R, Slomka PJ, Berman DS and Marwan M: Comparison of quantitative atherosclerotic plaque burden from coronary CT angiography in patients with first acute coronary syndrome and stable coronary artery disease. *J Cardiovasc Comput Tomogr* 8: 368-374, 2014.
- DeLong ER, DeLong DM and Clarke-Pearson DL: Comparing the areas under two or more correlated receiver operating characteristic curves: A nonparametric approach. *Biometrics* 44: 837-845, 1988.
- Hoffmann U, Bamberg F, Chae CU, Nichols JH, Rogers IS, Seneviratne SK, Truong QA, Cury RC, Abbata S, Shapiro MD, *et al*: Coronary computed tomography angiography for early triage of patients with acute chest pain: The ROMICAT (rule out myocardial infarction using computer assisted tomography) trial. *J Am Coll Cardiol* 53: 1642-1650, 2009.
- Hollander JE, Chang AM, Shofer FS, Collin MJ, Walsh KM, McCusker CM, Baxt WG and Litt HI: One-year outcomes following coronary computerized tomographic angiography for evaluation of emergency department patients with potential acute coronary syndrome. *Acad Emerg Med* 16: 693-698, 2009.
- Rubinshtein R, Halon DA, Gaspar T, Jaffe R, Karkabi B, Flugelman MY, Kogan A, Shapira R, Peled N and Lewis BS: Usefulness of 64-slice cardiac computed tomographic angiography for diagnosing acute coronary syndromes and predicting clinical outcome in emergency department patients with chest pain of uncertain origin. *Circulation* 115: 1762-1768, 2007.
- Chang HJ, Lin FY, Lee SE, Andreini D, Bax J, Cademartiri F, Chinnaiyan K, Chow BJW, Conte E, Cury RC, *et al*: Coronary atherosclerotic precursors of acute coronary syndromes. *J Am Coll Cardiol* 71: 2511-2522, 2018.
- Tonino PAL, De Bruyne B, Pijls NH, Siebert U, Ikeno F, van't Veer M, Klauss V, Manoharan G, Engström T, Oldroyd KG, *et al*: Fractional flow reserve versus angiography for guiding percutaneous coronary intervention. *N Engl J Med* 360: 213-224, 2009.
- Williams MC, Kwiecinski J, Doris M, McElhinney P, D'Souza MS, Cadet S, Adamson PD, Moss AJ, Alam S, Hunter A, *et al*: Low-attenuation noncalcified plaque on coronary computed tomography angiography predicts myocardial infarction: Results from the multicenter SCOT-HEART trial (scottish computed tomography of the HEART). *Circulation* 141: 1452-1462, 2020.
- Si N, Shi K, Li N, Dong X, Zhu C, Guo Y, Hu J, Cui J, Yang F and Zhang T: Identification of patients with acute myocardial infarction based on coronary CT angiography: The value of pericoronary adipose tissue radiomics. *Eur Radiol* 32: 6868-6877, 2022.
- Lin A, Kolossváry M, Yuvaraj J, Cadet S, McElhinney PA, Jiang C, Nerlekar N, Nicholls SJ, Slomka PJ, Maurovich-Horvat P, *et al*: Myocardial infarction associates with a distinct pericoronary adipose tissue radiomic phenotype: A prospective case-control study. *JACC Cardiovasc Imaging* 13: 2371-2383, 2020.
- Benton SM Jr, Tesche C, De Cecco CN, Duguay TM, Schoepf UJ and Bayer RR II: Noninvasive derivation of fractional flow reserve from coronary computed tomographic angiography: A review. *J Thorac Imaging* 33: 88-96, 2018.
- Tang CX, Wang YN, Zhou F, Schoepf UJ, Assen MV, Stroud RE, Li JH, Zhang XL, Lu MJ, Zhou CS, *et al*: Diagnostic performance of fractional flow reserve derived from coronary CT angiography for detection of lesion-specific ischemia: A multi-center study and meta-analysis. *Eur J Radiol* 116: 90-97, 2019.
- Zhuang B, Wang S, Zhao S and Lu M: Computed tomography angiography-derived fractional flow reserve (CT-FFR) for the detection of myocardial ischemia with invasive fractional flow reserve as reference: Systematic review and meta-analysis. *Eur Radiol* 30: 712-725, 2020.
- Liu X, Wang Y, Zhang H, Yin Y, Cao K, Gao Z, Liu H, Hau WK, Gao L, Chen Y, *et al*: Evaluation of fractional flow reserve in patients with stable angina: Can CT compete with angiography? *Eur Radiol* 29: 3669-3677, 2019.

29. Liu X, Mo X, Zhang H, Yang G, Shi C and Hau WK: A 2-year investigation of the impact of the computed tomography-derived fractional flow reserve calculated using a deep learning algorithm on routine decision-making for coronary artery disease management. *Eur Radiol* 31: 7039-7046, 2021.
30. Arena M, Caretta G, Gistri R, Tonelli G, Scardigli V, Rezzaghi M, Ragazzini A and Menozzi A: Fractional flow reserve in patients with type 1 or type 2 non-ST elevation acute myocardial infarction. *J Cardiovasc Med (Hagerstown)* 23: 119-126, 2022.
31. Tesche C, De Cecco CN, Albrecht MH, Duguay TM, Bayer RR II, Litwin SE, Steinberg DH and Schoepf UJ: Coronary CT angiography-derived fractional flow reserve. *Radiology* 285: 17-33, 2017.



Copyright © 2023 Yang et al. This work is licensed under a Creative Commons Attribution-NonCommercial-NoDerivatives 4.0 International (CC BY-NC-ND 4.0) License.