

Case Report

Cannabis arteritis: A case report and brief review of the literature

Youssef Banana^{a,*}, Husam Bashir^a, Sara Boukabous^a, Abdellah Rezziki^{a,b}, Adnane Benzirar^{a,b}, Omar El Mahi^{a,b}

^a Department of Vascular Surgery, Mohammed VI University Hospital of Oujda, Mohammed First University of Oujda, Morocco

^b Laboratory of Epidemiology, Clinical Research and Public Health, Faculty of Medicine and Pharmacy, Mohammed the First University of Oujda, Morocco

ARTICLE INFO

Keywords:

Cannabis
Severe arteritis
Iloprost
Amputation
Weaning

ABSTRACT

Introduction: Cannabis is commonly misused psychoactive drug which is known to be associated with a number of psychotic and somatic side-effects. Cannabis arteritis is a rare vascular disorder, since only about fifty cases have been reported in the literature.

Case presentation: We report a case of a 40-year-old chronic cannabis user male, who was admitted for painful necrosis of the fifth toe of the right foot. The etiological investigation ruled out the main causes of juvenile arterial disease. Therefore cannabis was the only causative factor found in this patient. An amputation of the fifth toe was performed 20 days later of administrating Prostacyclin (Iloprost), with a good postoperative improvement.

Discussion: The main causes of juvenile arterial disease are: atheromatous arterial disease, thromboangiitis obliterans (Buerger's disease), systemic or autoimmune diseases. The diagnosis of cannabis arteritis remains a diagnosis of exclusion. It remains a rare phenomenon which is responsible for various symptoms, which can go as far as the amputation of the limb. Several authors have classified cannabis arteritis as a clinical form of Buerger's disease, due to similar clinical semiology and similar appearance at arteriography. Nowadays, we don't know exactly the histopathologic patterns of this pathology.

Conclusion: Although several therapeutic options exist, Cannabis weaning still the main part of cannabis arteritis treatment.

1. Introduction

Cannabis is widely the most illicit psychoactive substance consumed all over the world [1], which is responsible for various complications as well as psychotic and somatic disorders, for instance cardiovascular disorders [2] and neoplasia [1].

Cannabis arteritis is a rare vascular disorder, which was first described by Sterne and Ducastaingt in the 1960s [3]. Only above fifty cases have been reported in the literature [4].

We report a case of severe arteritis in a cannabis smoker with digital necrosis.

Our case report was written according to SCARE guidelines [5].

2. Presentation of case

We report the case of a 40-year-old male patient with no relevant medical history, especially no history of diabetes, hypertension, familial

thrombophilia, heart dysfunction and didn't smoke tobacco. He is known to be a chronic cannabis user for over 25 years. He didn't use other drugs.

He was admitted to the emergency room with painful necrosis of the fifth toe of the right foot evolving for a month. On physical examination, femoral and popliteal pulses were present with absence of distal pulses, without motor and sensitive deficit. We have not objectified signs of gas gangrene, in particular no subcutaneous crepitations. Blood analysis showed: white blood cells at 12110/mm³, C-reactive protein at 22mg/L, hemoglobin at 13 g/dl, serum creatinine at 9 mg/l, blood urea nitrogen at 0,3 g/l. The immunological investigation did not reveal antinuclear antibodies, antiphospholipid antibodies, anticardiolipin antibodies or rheumatoid factor. The thrombophilia assessment (including proteins S and C, antithrombin III, resistance to activated C protein factor V) was negative. Test result for cryoglobulinemia was also negative and complement study was normal. The glycemic and lipid balance were within the standards. Accordingly, Cannabis was the only causative factor

* Corresponding author.

E-mail address: yousef.bana18@gmail.com (Y. Banana).

<https://doi.org/10.1016/j.amsu.2022.103523>

Received 25 January 2022; Received in revised form 14 March 2022; Accepted 26 March 2022

Available online 28 March 2022

2049-0801/© 2022 The Authors. Published by Elsevier Ltd on behalf of IJS Publishing Group Ltd. This is an open access article under the CC BY-NC-ND license (<http://creativecommons.org/licenses/by-nc-nd/4.0/>).

found in this patient.

Indeed, we performed an arteriography of the right lower limb by antegrade puncture of the right common femoral artery, that objectified a femoropopliteal axis without abnormalities (Fig. 1), with a long occlusion of the anterior tibial artery from the upper third of the leg (Fig. 2). The posterior tibial artery which is not visualized, is reinjected at the level of medial ankle by the peroneal artery (Fig. 3). We note the presence of a rich collateral vascularization in the leg with good plantar arch.

Therefore, the patient was put on 1 ng/kg/min vasodilator treatment with Prostacyclin (Iloprost) for 28 days, associated with a treatment based on platelet antiaggregant, antibiotic and analgesic.

Due to the persistence of pain, a right lumbar sympathectomy has been performed with good results. An amputation of the fifth toe was performed 3 weeks of Iloprost therapy, with a good postoperative improvement (Fig. 4). The surgical management of this case was performed by an experienced professor of vascular surgery with the aid of an assistant professor and 2 junior residents in the same speciality.

Moreover, we have recommended to the patient who was referred to a rehabilitation service, the systematic withdrawal of cannabis consumption.

3. Discussion

The main causes of juvenile arterial disease are: atheromatous arterial disease, thromboangiitis obliterans (Buerger's disease), systemic or autoimmune diseases. In this patient, the diagnosis of atherosclerotic pathology was ruled out since the patient has neither diabetes nor dyslipidemia. Furthermore the patient did not smoke tobacco, hence the Buerger's disease is unlikely. we note that all the etiological assessments in favor of systemic or autoimmune diseases returned without anomalies. The arteriography of the right lower limb revealed distal segmental

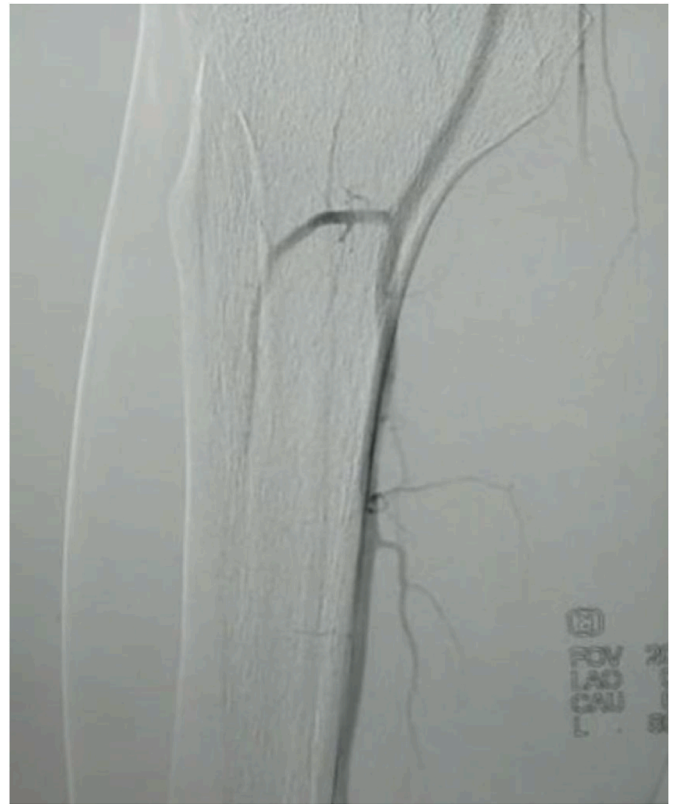


Fig. 2. arteriography frontal section showing a long occlusion of the anterior tibial artery from the upper third of the leg.

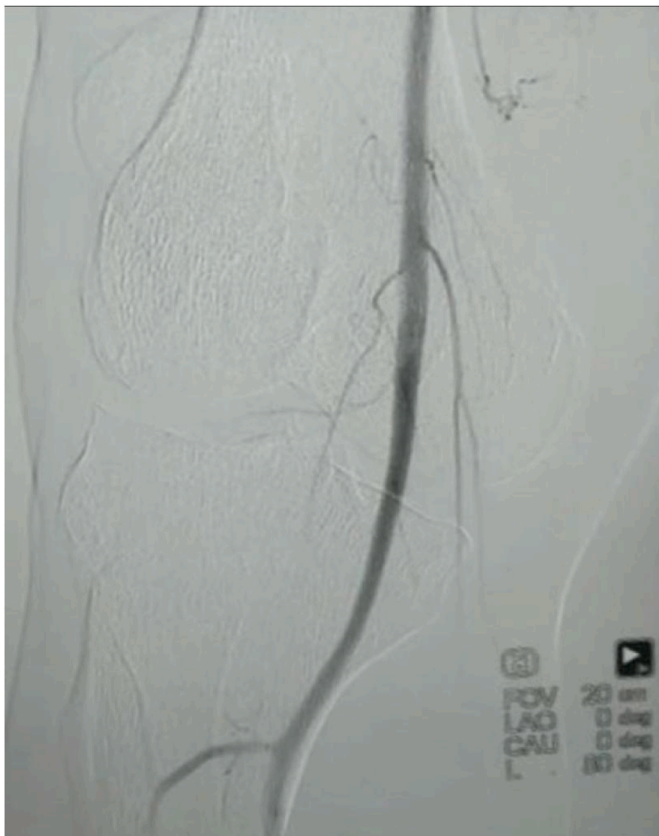

Fig. 1. arteriography frontal section showing a femoropopliteal axis without abnormalities.

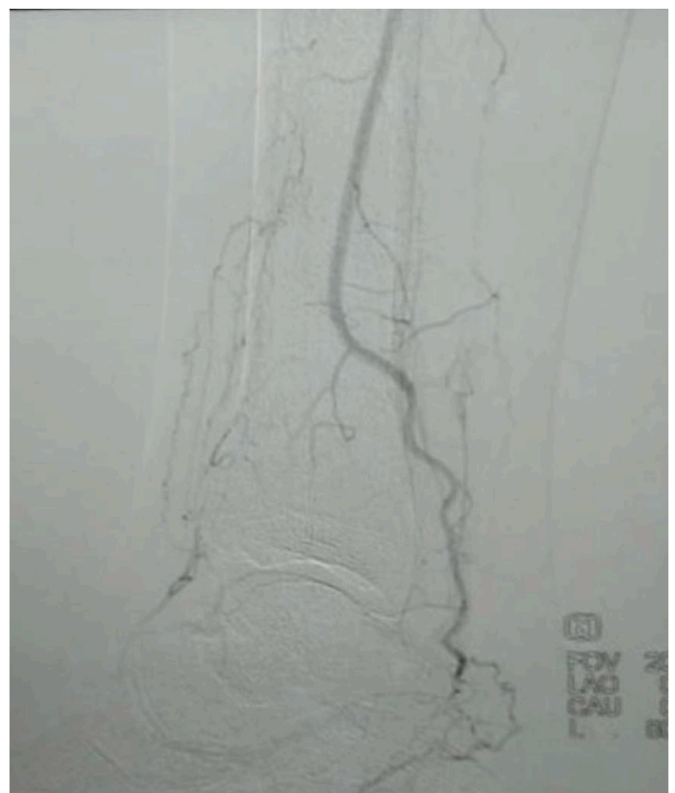


Fig. 3. arteriography section showing the reinjection of tibial posterior artery at the level of medial ankle by the peroneal artery.

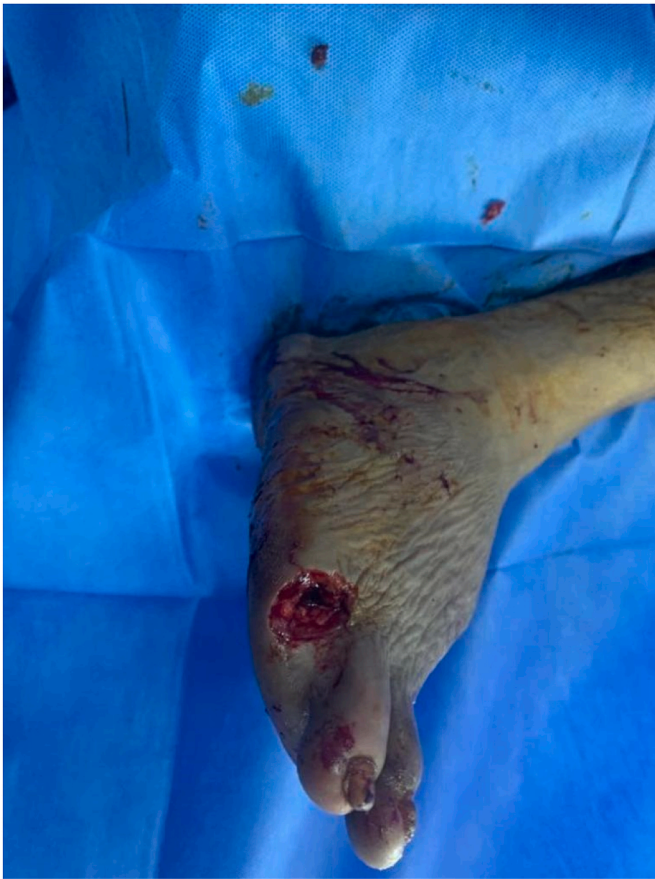

Fig. 4. amputation of the fifth toe with satisfactory bleeding.

lesions without proximal lesions or embolism. Since the cannabis was the only causative factor found in this patient, we retained the diagnosis of cannabis arteritis.

In the literature, we found 55 cases of cannabis arteritis [4]. Most are young males, and only 3 female cases have been reported [6,7]. Most of patients are regular cannabis smokers and didn't have any cardiovascular risk factor. In 11 cases, six patients had hypercholesterolemia, hypertriglyceridemia, or diabetes [7,8] five patients had Raynaud's syndrome and four patients had thrombophilia [6–9]. For these patients, cannabis was considered to be a cofactor aggravating arteriopathy.

The different symptoms reported in cannabis arteritis are: claudication [7], Raynaud's phenomenon [6], sub-acute distal ischemia of the lower limbs [9], distal necrosis or gangrene of lower limbs [3–6], absence of distal pulses (all cases) and venous thrombosis [9].

The lesions found in arteriography are: distal segmental lesions in all cases, sometimes in association with proximal lesions [11], or vascular occlusion [11,12]. In our case we found a femoropopliteal axis without abnormalities, with a long occlusion of the anterior tibial artery, the posterior tibial artery was not visualized. we note the presence of a rich collateral vascularization in the leg.

Several authors have classified cannabis arteritis as a clinical form of Buerger's disease [7–11], due to similar clinical semiology, besides these 2 entities have a similar appearance at arteriography with segmental distal lesions and a rich collateral vascularization.

In Buerger's disease, anatomopathological examination find at acute phase an arterial vascular lumen which is completely occluded by a thrombus very rich in inflammatory cells. Polynuclear leukocytes, micro-abscesses and giant cells may be present. Older lesions are characterized by an organized thrombus, associated with adventitial and periadventitial sclerosis [14]. Regarding cannabis arteritis, we don't know the histopathologic patterns. Sterne and Ducastaingt made

histopathological studies in late lesions which showed thrombosis but no inflammation of the vascular wall [3]. Only one case of arterial biopsy in patient with cannabis arteritis has been reported and showed thrombosis and endarteritis associated with a mild inflammation involving the media, with fragmentation of the internal elastic lamina [9].

The only effective strategy to prevent disease progression and avoid amputation is cannabis weaning. Combemale et al. reports the case of a patient with a good evolution during his incarceration, as he stopped cannabis but did not discontinued tobacco [11].

The reliability of prostanoids, which have an antiaggregating and vasodilating action has been shown by Fiessinger and Schafer in a prospective study: After 28 days of infusion, Prostacyclin (Iloprost) is superior to Aspirin in terms of pain relief and complete healing, after 6 months of follow –up, 88% of patients still had a positive response to Prostacyclin (Iloprost), compared to 21% in the Aspirin group, and only 6% of patients in the Prostacyclin group versus 18% in the aspirin group required amputation [15].

Surgical treatment is rarely possible due to disease spread, We can propose a distal vein bypass for limb salvage or for trophic disorders healing.

4. Conclusion

cannabis arteritis is a rare vascular disorder which is probably underdiagnosed.

The diagnosis is retained after elimination of other causes of juvenile arteriopathy. A number of therapeutic options exist. This case was successfully managed with an extended course of intravenous vasodilator therapy combined with amputation of the necrotic toe. Long term treatment consists of cessation of Cannabis use to prevent recurrence.

Ethical approval

applicable.

Sources of funding for your research

There is no financial support

Author contributions

Y. Banana: Conception, literature review, analysis, data collection, writing- review & editing.

H. Bashir: Conception, literature review, analysis, data collection, writing- review & editing.

S. Boukabous: Conception, literature review, analysis, data collection, writing- review & editing.

A. Rezziki: Conception, methodology, supervision.

A. Benzirar: Conception, methodology, supervision.

O. El Mahi: Conception, methodology, supervision.

Registration of research studies

This is not an original research project involving human participants in an interventional or an observational study but a case report. This registration is not required.

Consent

Written informed consent was obtained from the patient for publication of this case report and accompanying images.

Guarantor

Dr. Youssef Banana (corresponding author): 00212658641363/yousef.bana18@gmail.com.

(Department of vascular surgery, Mohammed VI University Hospital of Oujda, Mohammed First University of Oujda, Morocco).

Provenance and peer review

Not commissioned, externally peer-reviewed.

Declaration of competing interest

All authors are consent for the final version.

There is no conflicts of interest between the authors.

Acknowledgments

We would like to thank the team of cardiology of university hospital for their management and availability.

References

- [1] J.M. Costes, F. Beck, S. Legleye, C. Palle, [Epidemiology of cannabis use], *Rev. Prat.* 55 (2005) 17e22.
- [2] S. Sidney, Cardiovascular consequences of marijuana use, *J. Clin. Pharmacol.* 42 (Suppl) (2002), 64Se70S.
- [3] J. Sterne, G. Ducastaingt, Les artérites du cannabis indica, *Arch Mal Coeur* 53 (1960) 143–147.
- [4] I. Peyrot, A.M. Garsaud, I. Saint-Cyr, O. Quitman, B. Sanchez, D. Quist, Cannabis arteritis: a new case report and a review of literature, *J. Eur. Acad. Dermatol. Venereol.* 21 (3) (2007) 388–391.
- [5] R.A. Agha, T. Franchi, C. Sohrabi, G. Mathew, for the Scare Group, The SCARE 2020 guideline: updating consensus surgical CAse REport (SCARE) guidelines, *Int. J. Surg.* 84 (2020) 226–230.
- [6] A. Gröger, A. Aslani, T. Wolter, E.M. Noah, N. Pallua, Ein seltener fall von cannabis arteritis, *Vasa* 32 (2003) 95–97.
- [7] F. Schneider, N. Abdoucheli-Baudot, M. Tassart, F. Boudghène, P. Gouny, Cannabis and tobacco: cofactors favoring juvenile obstructive arteriopathy, *J. Mal. Vasc.* 25 (2000) 388–389.
- [8] M. Sauvagner, J. Constans, S. Skoponski, et al., Les arteriopathies des membres inférieurs débutant avant 50 ans. Analyse rétrospective de 73 patients, *J. Mal. Vasc.* 27 (2002) 69–76.
- [9] P. Disdier, B. Granel, J. Serratrice, et al., Cannabis arteritis revisited. Ten new cases reports, *Angiology* 52 (2001) 1–5.
- [10] C. Cazalets, E. Laurat, B. Cador, et al., Cannabis arteritis: four new cases, *Rev. Med. Interne* 24 (2003) 127–130.
- [11] P. Combemale, T. Consort, L. Denis-Thelis, J.-L. Estival, M. Dupin, J. Kanitakis, Cannabis arteritis, *Br. J. Dermatol.* 152 (2005) 166–169.
- [12] C. Cazalets, E. Laurat, B. Cador, et al., Cannabis arteritis: four new cases, *Rev. Med. Interne* 24 (2003) 127–130.
- [13] L. Karila, T. Danel, S. Coscas, J.P. Chambon, M. Reynaud, [Progressive cannabis-induced arteritis: a clinical thromboangiitis obliterans sub-group? *Presse Med.* 33 (18 Suppl) (2004) 21–23.
- [14] J.T. Lie, Diagnostic histopathology of major systemic and pulmonary vasculitic syndromes, *Rheum. Dis. Clin. N. Am.* 16 (1990) 269–292.
- [15] J.N. Fiessinger, M. Schafer, Trial of iloprost versus aspirin treatment for critical limb ischaemia of thromboangiitis obliterans: the TAO Study, *Lancet* 335 (1990) 555–557.