



Toxic effects of Lambda-cyhalothrin, on the rat thyroid: Involvement of oxidative stress and ameliorative effect of ginger extract



Wael M. Al-Amoudi

Department of Biology, Faculty of Applied Sciences, Umm Al-Qura University, Makkah 21955, Saudi Arabia

ARTICLE INFO

Keywords:

Lambda-cyhalothrin
Ginger
Thyroid
Histochemistry
Antioxidant

ABSTRACT

Lambda-cyhalothrin (LCT) is a synthetic pyrethroid that is widely used to control insecticide. Ginger is a traditional plant that is widely used as a spice or folk medicine. This study evaluates the antioxidant effect of ginger extract on thyroid toxicity induced by LCT in albino rats. Adult Rats were divided into 4 experimental groups: Group 1: control, Group 2: oral ginger treatment (24 mg/ml, 3 days/week for 4 weeks), Group 3: oral LCT treatment (1/100 LD₅₀, 3 days/week for 4 weeks), Group 4: oral LCT and ginger mixture treatment. The histological results of LCT group showed degenerated follicles with reduced colloids, congestion of blood vessels and hyperaemia between the follicles. Histochemically, depletion of glycogen and proteins was recorded in follicular cells and colloids. The biochemical results of LCT treated group revealed a decrease in T3, T4, SOD and CAT, while TSH and MDA were increased. The comet assay showed that LCT significantly induced DNA damage in the thyroid gland. However, treating rats with LCT plus ginger led to an improvement in the histological structure of the thyroid, with noticeable increases in glycogen and protein deposition. Also, LCT plus ginger increase in T3, T4 and the antioxidant enzymes SOD and COT were detected concomitantly with a decrease in TSH and MDA as well as a significant reduction in DNA damage. LCT affected the thyroid function and structure. On the other hand, ginger has a preventative effect against the histological damage and biochemical toxicity caused by the (LCT) insecticide.

1. Introduction

Pyrethroid pesticides are used worldwide as insecticides in pest control by disrupting the normal function of sodium channels. Pyrethroid pesticides are known to be less harmful to mammals, birds and less toxic to the environment than other insecticides [40]. Based on the mechanism of action chemical structure, we have two classification of pyrethroid pesticides namely: type I and type II. Type I pyrethroids have been reported to influence sodium channels in nerve membranes thereby causing a continuous neuronal discharge and leading to an after-potential in a prolonged negative way [40,50,77]. Type II pyrethroids are a modified version of type I pyrethroids that are formed by adding an α -cyano to phenoxybenzoic constituents in order to enhance their photostability [90]. These pyrethroids causes a longer delay in sodium channel inactivation and inhibit sodium channel-dependent activity of rat cortical neurons *in vitro* [45,67]. In addition, pyrethroid pesticides have been found in environmental samples, such as water and

sediments [66,85,86]; food [95]; and they can also be found in Urine and breast milk under human samples, metabolites of pyrethroids have also been shown to exert adverse effects on different physiological functions in the body [21,65]. In connection to the exposure of this pesticide, it was reported that diseases such as reproductive disorders, cancer, neurological disorders, allergies, mental disorders could be connected [61,87,93].

Moreover, it has been revealed that many pyrethroids and other insecticides are potential endocrine-disrupting chemicals. They have been shown to develop a negative impact on the reproductive, immune and hormonesystems of humans and animals [10,63,87]. Normal secretion of thyroid hormones is essential for some physiological processes as a controller of metabolic activity, including bone remodeling, cardiovascular activities, and abnormal behaviour. Hence, maintaining normal activities of thyroid is imperative for normal physiological and psychological health [10,49]. It has been reported that opening to thyroid-disrupting chemicals can cause a reduction of serum hormone

Abbreviations: LCT, Lambda-cyhalothrin; SOD, superoxide dismutase; CAT, catalase; TSH, thyroid-stimulating hormone; MDA, malondialdehyde; AD, Alzheimer's disease; PD, Parkinson's disease; PCO, protein carbonyl; T3, triiodothyronine, T4, thyroxine; PAS, Periodic acid-Schiff; ALT, plasma alanine aminotransferase; AST, aspartate aminotransferase; GPx, glutathione peroxidase; GR, glutathione reductase; GST, glutathione-S-transferase; CC14, carbon tetrachloride; DMBA, 7,12-dimethylbenz(a)anthracene; DMA, lipid peroxidation marker; ALK-P, alkaline phosphatase; GSH, glutathione; ROS, reactive oxygen species; TL, distance of DNA migration from the center to the nuclear core; TI, percent of genomic DNA that migrated during electrophoresis from the nuclear core to the tail

E-mail address: wmamoudi@uqu.edu.sa.

<https://doi.org/10.1016/j.toxrep.2018.06.005>

Received 28 March 2018; Received in revised form 31 May 2018; Accepted 11 June 2018
Available online 12 June 2018

2214-7500/© 2018 The Author. Published by Elsevier B.V. This is an open access article under the CC BY-NC-ND license (<http://creativecommons.org/licenses/by-nc-nd/4.0/>).

levels leading to unusual activities of the thyroid gland by disrupting the TSH receptor since normal diffusion of thyroid-stimulating hormone (TSH) invigorates all the steps of hormone secretion [49]. In turn, this may have substantial consequences for the healthy metabolic function of the biosystem. Some clinical studies have demonstrated that pyrethroids hamper endocrine functions [76]. Furthermore, oxidative stress effects of pyrethroid-induced toxicity have been reported by some investigators [64,94]. A growing number of studies have indicated that oxidative stress plays critical roles in various toxicities associated with pyrethroid insecticides [84].

Lambda-cyhalothrin (LCT) is a manufactured pyrethroid insecticide that is being used in home pest control, agriculture, protection of food production and disease vector control [33,88]. LCT has been widely used to control pests, including aphids, Colorado beetles and lepidopteran larvae, [81] and was detected in milk, the blood of dairy cows [17] and cattle meat [43]. It has been reported that exposing rats to LCT leads to hepatotoxicity and severe renal structure injury due to its toxicity in rats [83]. Another study indicated that renal activities, tissue malondialdehyde (MDA), histopathology, protein carbonyl (PCO) levels, reduced glutathione (GSH) levels and antioxidant enzyme activities were significantly affected by LCT [33]. The use of LCT to treat rats can result to an uprising in the number of structural chromosomal aberrations and frequency of micronucleated erythrocytes [19]. LCT expanded the generation of reactive oxygen species and DNA damaged levels, inducing adverse immune effects [96]. In addition, other results revealed that LCT caused significant increases in the kidney, brain and liver weight as well as plasma alanine aminotransferase (ALT) and aspartate aminotransferase (AST) levels. Additionally, the decreased ALP and brain activity has been found in rats. However, the plasma content of bilirubin, urea, creatinine, and glucose were significantly increased. By contrast, plasma total protein and albumin was decreased [91]. The aim of this study is to investigate the propensity of Lambda-cyhalothrin (LCT) to prompt oxidative pressure and changes in the biochemical parameters and the movement of enzyme in the thyroid gland of male rats as well as its conceivable weakening by Ginger extract.

Synthetic chemical drugs are expensive and cause genetic and metabolic alterations in biosystems. Botanical medicines have traditionally been used to treat disease development and progression. In this regard, medicinal plants and their components have important roles in disease control by modulating the activity of biological systems [37,51]. Ginger, the rhizome of the *Zingiber officinale*, a standout amongst the most commonly utilized traditional food types and has been shown to have a therapeutic role in overall health and well-being. Many studies have shown that ginger plays a noteworthy part in the avoidance of many diseases by means of a tweak of hereditary and metabolic activities in human and animal model [24,36,97].

Ginger is publicly described and has been used for thousands of years as an anti-vomiting, diabetes mellitus, and cancer treatment, especially in Asian and other Eastern cultures [22,51]. It likewise has anti-inflammatory and anti-oxidative properties for controlling the way towards maturity [37,56]. The analyzed chemical composition of aqueous extracts of ginger root includes polyphenols, vitamin C, B, C, β carotene, flavonoids and tannins [60,70]. It has at least 14 bioactive compounds, including [4]-gingerol [6],-gingerol [8],-gingerol [10],-gingerol [6],-paradol [14],-shogaol [6],-shogaol, 1-dehydro- [10]-gingerdione [10],-gingerdione, hexahydrocurcumin, tetrahydrocurcumin, gingerone A, 1,7-bis-(4'hydroxyl-3'methoxyphenyl)-5-methoxyheptan-3-one, and methoxy- [10]-gingerol [16,46,83]. HPLC analysis of *Zingiber officinale* ethanolic extracts showed that shogaol and gingerol were the most abundant phenolic components [12].

Furthermore, other investigators have reported that ginger extract has hypolipidaemic [78] and anti-hypercholesterolemic [35] effects, hepatoprotective [31] and antioxidant properties [28,83] and it is protected against dyslipidaemia in diabetic rats [15]. It has been revealed that ginger extract has a protective effect against

cyclophosphamide, which induces chromosomal abnormalities in the somatic cells of mice [89], and also has chemopreventive and chemotherapeutic activities against cancer development [59]. It has been showed that ginger has anti-mutagenic effects against genotoxicity induced by the anti-cancer drug Taxol [9]. Recent studies have suggested that Ginger can reduce the risk of some chronic diseases, such as fatty liver disease, asthma, cancer growth and arthritis through its anti-inflammatory, immunoregulatory and antioxidative properties [8,69]. The present work was designed to evaluate the preventive effect of aqueous extracts of *Zingiber officinale* on thyroid toxicity and oxidative pressure initiated by Lambda-cyhalothrin in albino rats. Evaluating the bioactivity and histopathological alterations of ginger are necessary to completely understand its potential therapeutic effects.

2. Materials and methods

2.1. Lambda-cyhalothrin

Lambda-cyhalothrin (α -cyano-3-phenoxy -benzyl-3-(2-chloro-3, 3, 3-trifluoro-1-propenyl)-2, 2-dimethylcyclopropanecarboxylate) is a synthetic pyrethroid that is 99.8% active. The product was obtained from the faculty of Agriculture, King Abdulaziz University, Jeddah, KSA. Water was added to the chemical to dilute it for a final concentration that was appropriate for dosing. LCT was used at a dosage of $1/100^{\text{th}}$ LD₅₀ (0.79 mg/kg b.wt), 3 days/week for 4 weeks, diluted in water according to a previous report [27].

2.2. Ginger extract

Ginger (*Z. officinale* Roscoe) rhizome was purchased from a local market. One kilogram of ginger rhizome was cleaned, washed under running water, cut into small pieces and air dried. The dried rhizomes were powdered and stored at lab temperature (20–23 °C) for oral feeding. One-hundred-twenty-four grams of this powder was macerated in 1000 ml of distilled water (dH₂O) for 12 h at room temperature and filtered. The concentration of the concentrate was 24 mg/ml. The rats under study were given 1 ml of this fluid concentrate orally [42].

2.3. Experimental animals

The ethics committee of Umm Al-Qura University approved the animal under experiments. In this study, male albino rats (Wistar) were used, they were seven-week old rats with an average body weight of 160–180 g were used. The cages that rats were housed was (23–25 °C) under identical laboratory conditions. Food and water were provided ad libitum amid the trial/experimental time frame (30 days). Animals were provided with monetarily accessible dry food pellets. Animals were kept up in a controlled climate with a 12-hour dark/light cycle at an encompassing temperature of 22 ± 2 °C. Following one week of acclimation, animals were divided randomly into four experimental groups (n = 10 in each group).

Group I: was used as a control and got the standard diet and water *ad libitum*.

Group II: was used to study the effect of ginger and was orally given ginger extract (powder) dissolved in water at a measurement level of 24 mg/ml 3 days/week for 4 weeks by using the intragastric gavage technique.

Group III: was utilized to evaluate the impact of a low oral dose of Lambda-cyhalothrin (0.79 mg/kg b.wt. $1/100^{\text{th}}$ of the LD₅₀) and was orally given Lambda-cyhalothrin 3 days/week for 4 weeks by using the intragastric gavage technique.

Group IIII: was utilized to evaluate the impact of the mixture of a low dose of Lambda-cyhalothrin of $1/100^{\text{th}}$ of the LD₅₀ and ginger (24 mg/ml) and was orally administered 3 days/week for 4 weeks by using the intragastric gavage technique.

the total body weight of each animal was recorded at the end of the

experimental period. The animals were sacrificed by inhalation of 70% CO₂, followed by cervical decapitation and dissected

2.4. Histological and histochemical study

For histopathological examination, animals were dissected and the thyroid glands were removed and fixed. Each thyroid was placed in 10% buffered formalin for 24 h and implanted in paraffin wax making use of standard methods. Thyroid glands were washed in tap water and got dried in rising grades of ethanol, cleared in xylene, and fixed firmly in paraffin wax (melting point 55–60 °C). For histological analysis, which included follicle shape and size, follicular cell height, and characteristics of the cytoplasm and intrafollicular colloid, paraffin sections with a thickness of 5 µm were set up by a rotary microtome and stained with haematoxylin and eosin. For histochemical measurement of total carbohydrates in follicular cells and colloids, the periodic acid Schiff's technique (PAS) was utilized [44]. Total proteins of thyroid gland were seen in follicular cells and colloids using the mercury bromophenol blue method [58]. Histochemical staining was evaluated using a high-powered light microscope (BX51; Olympus, Tokyo, Japan).

2.5. Morphometric study

The diameters of thyroid follicles were estimated in H and E sections using an ocular micrometer gauge calibrated with phase micrometer to acquire the estimate of these parameters under a light microscope at ×400 magnification. Photomicrographs were prepared by using Axiom Vision® digital camera (Germany) attached to a microscope. The level of follicles with colloid content was estimated in PAS-stained sections. These measurements were performed in 10 fields for each specimen. Sections of the thyroid gland were used to estimate the area of the follicles. The inner area of the thyroid gland in the longitudinal planes was considered as the central zone, and the surrounding area to the central zone was considered as the peripheral zone. The size of the follicles in the central area was compared with the size of the follicles in the peripheral area.

2.6. Biochemical analysis

For biochemical analysis, blood samples were collected in clean centrifuge tubes during dissection and directly placed on ice. Heparin was used as an anticoagulant. Plasma was obtained by centrifugation of samples at 3000 rpm for 15 min, and samples were stored at –60 °C until analysis. The plasma concentrations of triiodothyronine (T3), thyroxine (T4) and thyroid stimulating hormone (TSH) were measured by a radioimmunoassay [30]. Lipid peroxidation was estimated by measuring malondialdehyde [57], superoxide dismutase [62], and Catalase activity was determined [3].

2.7. Single cell gel electrophoresis assay for the detection of DNA damage

This assay, also called the comet assay, was completed as portrayed by [72]. Thyroid tissue was cut into small pieces, the tissues were homogenized in cold sodium phosphate buffer (50 mmol/L, pH 7.0) containing ethylenediamine tetra-acetic acid (EDTA), (0.1 mmol/L). The homogenates tissues were centrifuged at 1000 rpm (6149g) for 15 min at 4 °C. Two hundred microliters of the obtained supernatant was embedded in low-melting agarose (0.65%) that was layered onto frosted microscope slides coated with a layer of 0.75% normal agarose (diluted in Ca²⁺- and Mg²⁺-free PBS buffer). A layer of 0.65% low-melting agarose was placed on top. The slides were immersed in cold lysate solution containing cold lysate solution containing (1% Triton X-100; 10% DMSO; 89% of 10 mmol/L Tris; 1% sodium lauryl sarcosine; 2.5 mol/L NaCl; 100 mmol/L Na²⁺; and EDTA, pH 10) at 4 °C for 1–2 h. The slides were pretreated with electrophoresis buffer (300 mmol/L NaOH; 1 mmol/L Na²⁺; EDTA, pH 12) for 20 min and then exposed to

25 V/300 mA for 20 min. The slides were neutralized for 5 min in 0.4 M Tris (pH 7.5), and the DNA was stained with 50 µL of ethidium bromide (20 µg/mL) onto each slide. After staining with ethidium bromide for 10 min, the slides were washed in distilled water and used for microscopic examination. All methods were performed under dimmed light to avoid additional DNA degradation. The slides were examined under a Leitz Orthoplan fluorescence microscope equipped with a 515–560 nm filter and a 590 nm barrier filter. The obtained images were analyzed using the Comet Assay IV-Perceptive Instruments software. The slides were analyzed and scored at a range of 100 cells. DNA damage of cells was measured using the ratio of tail DNA content to the whole cellular DNA content. DNA damage was calculated as tail length (TL) and tail intensity (TI).

2.8. Statistical analysis

The results were communicated as mean ± SEM., and the statistical calculation was performed using the one-way ANOVA to evaluate significant differences among treated groups. Differences with P < 0.01 were viewed as highly/factual statistically significant and P < 0.05 as statistically significant. Every single statistical analysis were carried out using the SPSS statistical version 16 software package (SPSS® 4 Inc., USA) and multiple comparisons between means were analyzed by the Tukey–Kramer test.

3. Results

3.1. Effect of Lambda-cyhalothrin on body weight

All rats survived the whole experimental period. Only rats that were orally treated with a low oral dose (1/100th of LD₅₀) of Lambda-cyhalothrin showed a significant decrease (ANOVA, Duncan's test, (p < 0.05) in body weight in comparison to control rats (Fig. 1). Treatment with a combination of Lambda-cyhalothrin and ginger extract resulted in a body weight that was higher than that of the groups that were only treated with Lambda-cyhalothrin. However, no significant differences in body weight were observed between the control and ginger-treated groups (Fig. 1).

3.2. Histological results

Sections of thyroids from control rats showed a systematic histological structure. The thyroid follicles appeared normal with an arrangement of various sizes. They were mainly lined by cubical follicular

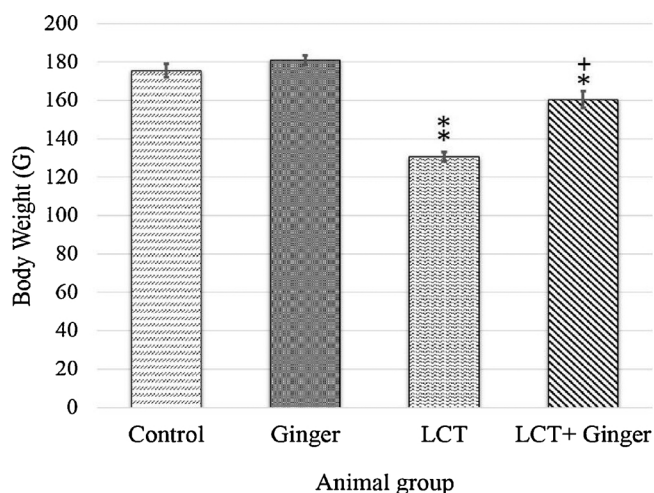


Fig. 1. Body weights of male rats treated with lambda-cyhalothrin, ginger and their combination. The results are expressed as mean ± SEM, n = 5 rats/group.

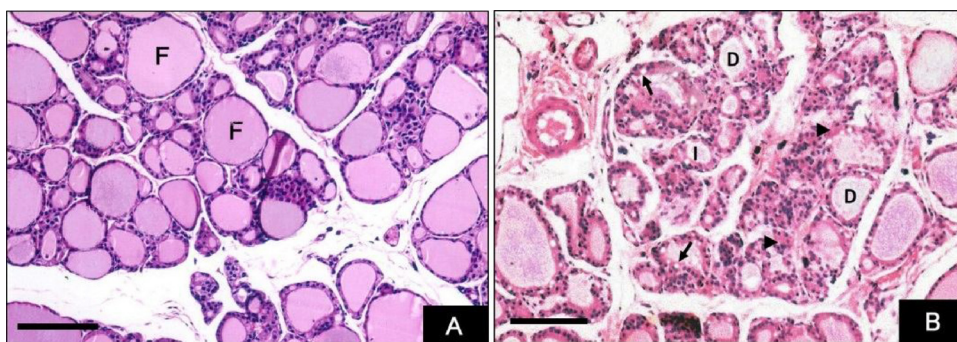


Fig. 2. (A) Photomicrograph of a section of the thyroid gland of a control rat showing normal thyroid follicles (F) lined with simple cuboidal epithelium and filled with homogenous acidophilic colloid (H&E). (B) Photomicrograph of a section of the thyroid gland of a rat treated with lambda-cyhalothrin showing vacuolization (arrows) in the lining of the epithelium of the follicles and hyperaemia between the follicles (head arrow). Notice that the thyroid follicles appear to have variable forms, where some follicles appear distended (D) and other follicles appear involuted with minimal amount of colloid (I). (H&E), bar = 20 µm.

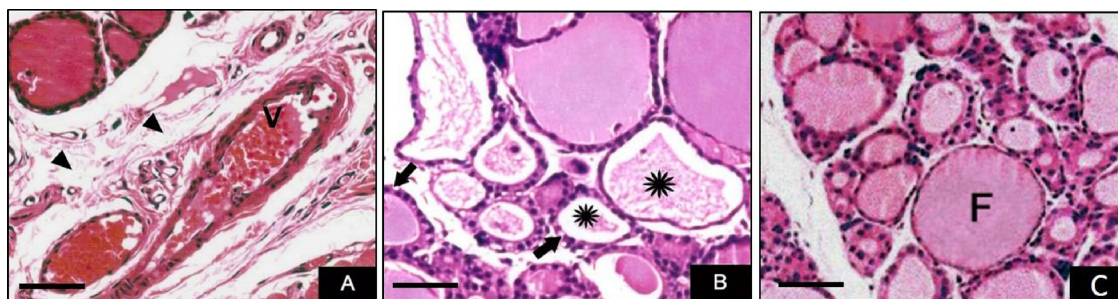


Fig. 3. (A) Photomicrograph of a section of the thyroid gland of a rat treated with lambda-cyhalothrin showing an enlarged and congested vein (V), hyperaemia in the blood vessels and degenerated connective tissue (head arrow), (H&E). (B) Degenerated follicles with reduced colloids (*), (H&E), (C) Thyroid of a rat treated with lambda-cyhalothrin and ginger showing marked improvement of the thyroid follicles (F) structures with few hyperaemia between the follicles. (H&E), bar = 40 µm.

cells with rounded vesicular nuclei as well as few para follicular cells and contained an acidophilic homogenous colloid in their centre. Between follicles, intermolecular interactions of follicular cells and blood capillaries were healthy. In addition, the interfollicular spaces indicated blood vessels and connective tissue (Fig. 2A). However, the thyroids of rats treated with LCT showed a different histopathological structure in comparison with that of control rats. The sizes of the follicles were reduced, and some follicles showed cell exfoliation within their lumen (Fig. 2B). The blood vessels were enlarged and congested, and the connective tissue structure was degenerated (Fig. 3A). The follicles degenerated and follicular cells appeared with cytoplasmic vacuolation and a smaller colloid (Fig. 3B). An improvement was observed in thyroids of rats treated with LCT and ginger. In these specimens, the histological structures of the follicles appeared normal and contained healthy follicle cells with a marked increase of colloid (Fig. 3C).

3.3. Histochemical observations

Thyroids from control rats stained with Periodic acid–Schiff (PAS) for total carbohydrates showed a moderate reaction in follicular cells, whereas the colloids showed a strong reaction (Fig. 4A). A weak PAS reaction was seen in the thyroids of rats treated with LCT (Fig. 4B), while the thyroid of rats given LCT and ginger showed an increase in the PAS reaction (Fig. 4C). Examination of thyroid sections from control rats stained with mercuric bromphenol blue showed normal protein contents in follicular cells and the colloid (Fig. 5A). By contrast, a noticeable decline in protein content was seen in follicular cells and the colloid of the thyroids of animals treated with LCT (Fig. 5B). On the other hand, rats given LCT and ginger showed an increase in the protein content of their thyroids (Fig. 5C).

3.4. Morphometric results

Observing the treatments given to rats from the group treated with LCT, there was a significant impact which caused a significant decrease

in the follicles diameter when compared with the control group. However, rats treated with LCT and ginger demonstrated a critical increment in the mean follicular diameter (Fig. 6). The level of follicles with an ordinary colloid content diminished in animals treated with LCT and increased after treatment with LCT and ginger (Fig. 7).

3.5. Biochemical results

3.5.1. Changes in T3, T4, and TSH

Treating rats with LCT led to a significant decrease in triiodothyronine (T3) (Fig. 8A) and thyroxine (T4) as well as a significant increase of thyroid-stimulating hormone (TSH) (Fig. 8B). Administration of LCT and ginger caused an increase in T3 and T4 and a decrease in TSH, whereas no significant differences were recorded between the control and ginger-treated groups.

3.5.2. Change in the lipid peroxidation marker and antioxidant enzymes

The data in Table 1 showed that LCT administration significantly increased the level of malondialdehyde (MDA) over the normal value. The activities of the antioxidant enzymes superoxide dismutase (SOD) and catalase (CAT) decreased significantly in the sera of rats from the group treated with LCT. When compared to the control and LCT groups, MDA decreased remarkably and SOD and CAT activities increased in rats treated with LCT and ginger.

3.6. Effect of ginger treatment on lambda-cyhalothrin (LCT)-induced DNA damage

The comet assay showed that LCT significantly induced DNA was harmed/damaged in the thyroid gland (Fig. 9B). The result also showed that the LCT group had significantly increased tail lengths ($2.472 \pm 0.257 \mu\text{m}$) compared to those of control rats ($P < 0.05$) (Table 2). Moreover, the percentage of DNA damage in the LCT group was significantly higher ($2.143 \pm 0.178 \mu\text{m}$) when compared to that in the control rats (Table 2). However, LCT in combination with ginger reduced the amount of DNA damage in thyroid cells, which caused a

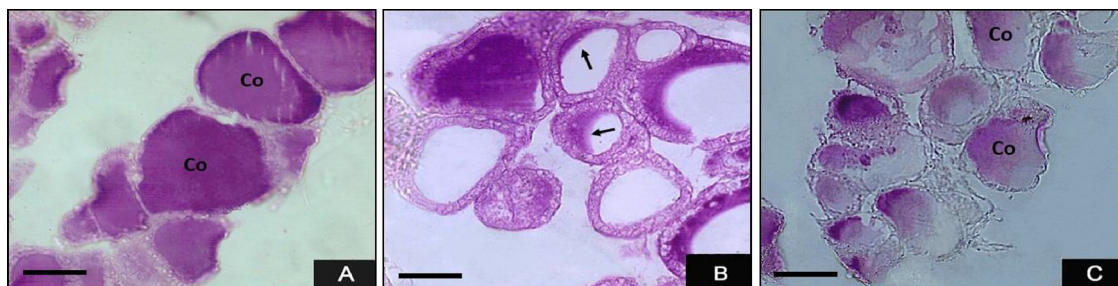

Fig. 4. (A) Photomicrograph of a section of a thyroid gland showing a normal distribution of glycogen in follicular cells and colloids with a marked PAS reaction in the colloid (Co). (B) Photomicrograph of a section of the thyroid gland of a rat treated with lambda-cyhalothrin showing depletion of glycogen and a weak PAS reaction in the colloid (arrow). (C) The thyroid of a rat treated with lambda-cyhalothrin plus ginger showing an increase of the glycogen content and a strong PAS reaction, leading to marked restoration of PAS positive materials in the colloid (Co) of the thyroid gland compared to that of the lambda-cyhalothrin treated group, bar = 40 μ m.

significant decrease in tail length and percentage of DNA damage in comparison to those in the LCT group ($1.736 \pm 0.153 \mu$ m and $1.655 \pm 0.244 \mu$ m, respectively; Table 2; Fig. 9B,C).

4. Discussion

In considering human and animal health, there are so many chemicals that are suspected to be harmful. Some natural chemicals have been accounted for to have thyroid-disrupting properties [4,49]. This study investigated the adverse effects of the insecticide Lambda-cyhalothrin at dosages that were extensively beneath the level of acute oral toxicity ($1/100^{\text{th}}$ the LD_{50}). However, there is not enough evidence to confirm that LCT has thyroid-disrupting effects in rats, the histological and biochemical results obtained in this investigation showed that LCT has negative side effect on thyroid gland and ginger has reduced these effect caused by LCT. The observed effects are indicative of severe oxidative stress in the thyroid of rats. Also, the results affirmed that LCT decreases the body weight of rats. This result is in concurrence with a past report showing that LCT caused a decrease in body weight in addition to an increase in the weights of the liver and spleen [27].

Histologically, smaller colloids, blockage of blood vessels and degeneration of follicular cells where some abnormal changes observed. These observations were consistent with similar results of the thyroid and reproductive system of male rats intoxicated by the pyrethroid deltamethrin [2,5]. Effects of other insecticides on the thyroid were studied by other investigators. It has been reported that chlorpyrifos insecticide-treated rats demonstrated hypothyroidism, which was confirmed biochemically by huge decline in serum T3 and T4 levels and histologically by a diminished measure of colloid. Furthermore, chlorpyrifos cause a decrease of PAS response in the colloid and is revealed immunohistochemically by a weak thyroglobulin protein expression in the colloid [29,68].

Concerning the histochemical results, LCT treatment caused

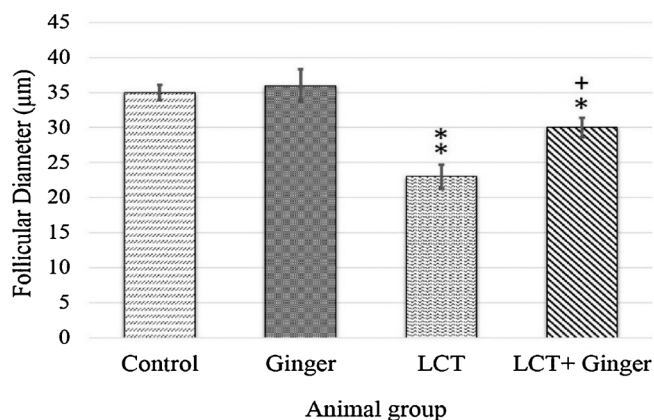


Fig. 6. Effects of different treatments on the diameters of follicles. The results are expressed as mean \pm SEM, $n = 5$ rats/group.

depletion of glycogen and total proteins in follicular cells and the colloid. Glycogen content depletion, hepatocyte degeneration and loss of integrity of the cell wall were found in the liver tissue of *Oreochromis mossambicus* after treatment with a sublethal dose of Lambda-cyhalothrin [23,54]. Similar results were obtained in human lymphocytes intoxicated with chlorpyrifos [38,49]. It was suggested that the reduction in glycogen is probably due to its more rapid breakdown (glycogenolysis), which discharges glucose into the circulatory system to meet the expanded energy requirements under stress [49]. It has been shown that noticeable histological lesions were observed, including liver parenchyma, fatty degeneration, necrosis, granularity and ballooning [74].

In analysing the result, it was seen that LCT caused a reduction in the total protein. Also, in mice treated with LCT, it was recorded that the protein level decreased. However, it was shown that exposure of

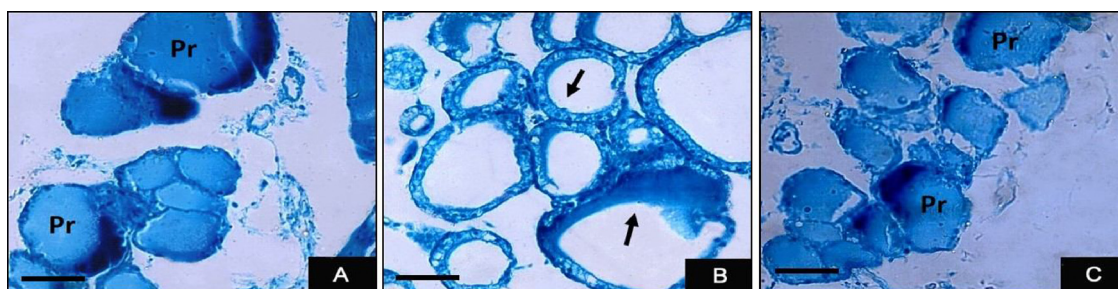


Fig. 5. (A) Photomicrograph of a section of thyroid gland showing a normal distribution of proteins (Pr) in follicular cells and colloids (Mercury bromophenol blue). (B) Photomicrograph of a section of the thyroid gland of a rat treated with lambda-cyhalothrin showing a decrease of proteins (arrow) (Mercury bromophenol blue). (C) Thyroid of a rat treated with lambda-cyhalothrin plus ginger showing an increase of proteins (Pr) in follicular cells and colloids (Mercury bromophenol blue), bar = 40 μ m.

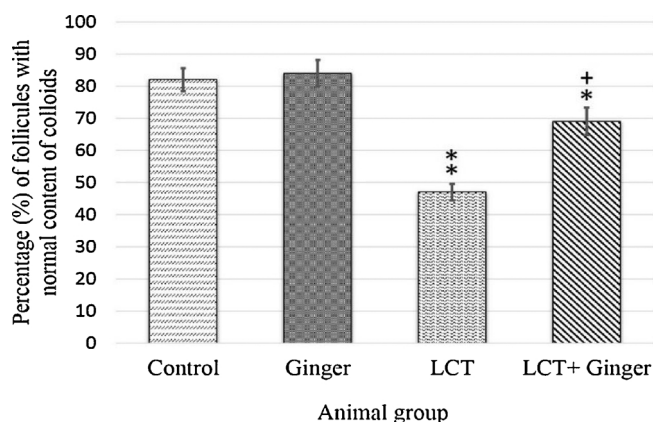


Fig. 7. Effects of different treatments on the percentage (%) of follicles with a normal content of colloid in different rat groups. The results are expressed as mean \pm SEM, $n = 5$ rats/group.

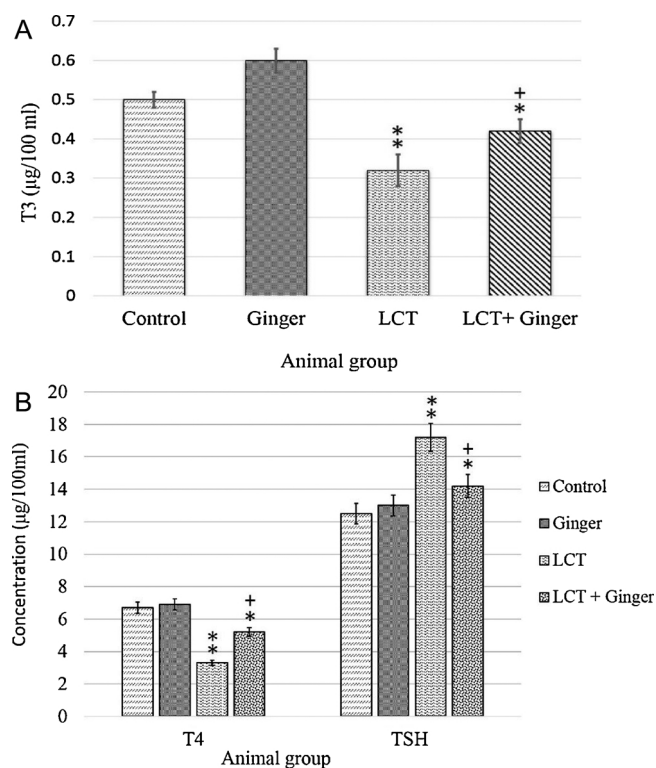


Fig. 8. A. Concentrations of triiodothyronine (T3) in the blood of rats treated with Lambda-cyhalothrin, ginger and their combination. The results are expressed as mean \pm SEM, $n = 5$ rats/group. B. Concentrations of thyroxine (T4) and Thyroid-Stimulating Hormone (TSH) in the blood of rats treated with Lambda-cyhalothrin, ginger and their combination. The results are expressed as mean \pm SEM, $n = 5$ rats/group.

rats to LCT prompted a noteworthy increment in kidney MDA and protein levels. It was also seen that the activities of catalase (CAT), superoxide dismutase (SOD), glutathione peroxidase (GPx), glutathione reductase (GR) and glutathione-S-transferase (GST) were significantly decreased due to Lambda-cyhalothrin exposure [33,34].

The results of thyroid hormones analysis showed that treating animals with LCT induced a decrease in T3 and T4, while TSH was increased. Similarly, other studies reported that relatively high measurements of LCT prompted a stamped decrease in the concentration of thyroxine (T4) and triiodothyronine (T3), which was accompanied by an increase in thyroid-stimulating hormone (TSH) [4,10,27]. A similar result was obtained by [2], who investigated the toxicity of

Table 1

Plasma MDA level and CAT and SOD activities in the blood of rats of different experimental groups, including LCT treated, Ginger treated and their combination. The results are expressed as mean \pm SEM, $n = 5$ rats/group.

	MDA (n mol/ml)	CAT (μ mol /sec/ml)	SOD (n mol /ml)
Control	5.80 \pm 0.5	28.6 \pm 1.7	88.7 \pm 1.4
Ginger	5.30 \pm 1.2	30.4 \pm 0.9	90.4 \pm 0.5
LCT	9.14 \pm 1.3 **	16.5 \pm 1.25 **	50.7 \pm 1.8 **
LCT + ginger	6.7 \pm 0.9 *+	21.9 \pm 1.3 *+	73.4 \pm 1.9 **++

*, **: Significant difference in comparison to the control, $p < 0.05$, $p < 0.01$. +, ++ : Significant difference in comparison to the LCT group, $p < 0.05$, $p < 0.01$.

Deltamethrin on thyroid function. He reported that exposure to low doses of LCT significantly disturbed thyroid function in the offspring. There was a decrease in the concentrations of both T4 and T3 in all the experimental periods of the offspring of rats that received LCT, while the TSH levels were significantly higher than rats in the controls groups [80]. It is assumed that the reduction in thyroid hormones may be the result of increased hepatic enzyme activity [47], or the consequence of a direct cytotoxic impact on the thyroid gland of the toxic results of oxidative pressure [1]. This result is in agreement with other results, it shows that significant increases were observed in a few biochemical pointers of oxidative pressure, such as thiobarbiturate-reactive substances in the blood and liver, additionally the concentrations of reduced glutathione in the liver, testis, brain and kidney [25,27].

Ginger was used in this investigation as an anti toxic agent against LCT negative effect. The results of this study showed that ginger ameliorated the toxic effects in the thyroid caused by LCT. A change in the histological and histochemical appearance of thyroid tissue was observed in animals treated with LCT and ginger as well as glycogen and protein content. Moreover, T3 and T4 increased while TSH decreased after treatment with ginger extract. These findings confirmed that ginger could be used as an antioxidant agent against LCT and other chemical. Similar results were reported by [11], who showed that ginger ameliorated the histological and histochemical alterations induced by the insecticide Mancozeb in the thyroids of rats. It has been reported that ginger administration improved the histopathological changes and increased the glycogen and proteins contents in the liver of rats treated with 7,12-dimethylbenz(a)anthracene (DMBA) and fungicide Metalaxyl benzenoid. [6,26].

According to this study result, a lipid peroxidation marker (MDA) decreased, and the antioxidant enzymes superoxide dismutase (SOD) and catalase (CAT) increased in the thyroid gland following treatment with ginger extract. So many studies defined the antioxidative and free radical scavenging potential of *Zingiber officinale* extracts and their various segments [18]. It was reported that there was a significant decrease in lipid peroxidation in animals treated with *Zingiber officinale* when compared with animals treated with immunosuppressor 7,12-Dimethylbenz[a]anthracene (DMBA) alone [18]. Also, it was found that when diabetic rats are treated with ginger for 20 consecutive days the viability and motility of their sperm will increase significantly and the lipid peroxidation will decrease. [55]. Additionally, exact mechanism of action of ginger as an anti-oxidant agent is not clear but it is assumed that such type of effect due to constituents present in ginger including gingerols, shogaols, and galanolactone and diterpenoid of ginger [7]. In addition, ginger extracts exhibited free radical scavenging, inhibited lipid peroxidation, protected DNA damage, indicating that ginger extracts have strong antioxidant properties [71]. Ginger has been reported to contain at least 14 bioactive compounds [46,92]. The most well-known bioactive component of ginger is [6]-gingerol [75]. Some evidence showed that the compounds found in ginger, including [6]-gingerol and arsenic, led to significant increase in the activities of the antioxidant enzymes CAT, SOD, glutathione peroxidase GPx and glutathione (GSH) in rats. In addition [6],-gingerol reduced elevated blood

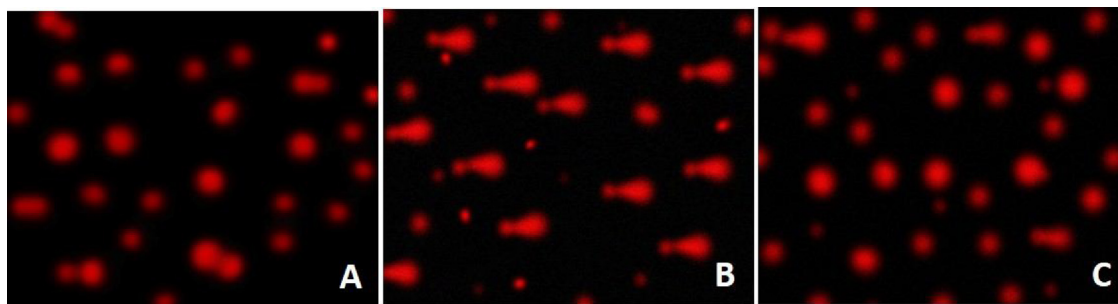


Fig. 9. (A) Photomicrograph of a thyroid gland showing a normal DNA sample from a rat as measured by the comet assay. (B) Photomicrograph of a section of a rat treated with lambda-cyhalothrin (LCT) showing DNA damage. (C) The thyroid of a rat treated with LCT plus ginger showing a decrease in DNA damage. All images are shown at 200x magnification.

Table 2

Comet assay results for the thyroid gland for the control, LCT, and LCT in combination with ginger group. The results are expressed as mean \pm SEM, $n = 5$ rats/group.

	Tail length (μm)	DNA (%)
Control	1.688 \pm 0.145	1.568 \pm 0.184
Lambda-cyhalothrin	2.472 \pm 0.257 **	2.143 \pm 0.178 **
LCT + Ginger	1.736 \pm 0.153 ***	1.655 \pm 0.244** +
F-Value	31.768	14.543
LCD at 5%	0.236	0.296
LCD at 1%	0.367	0.413

*, ** : Significant difference in comparison to the control, $p < 0.05$, $p < 0.01$.
+, ++ : Significant difference in comparison to the LCT group, $p < 0.05$, $p < 0.01$.

(LCD) Least significant difference.

glucose levels, increased plasma insulin levels [20], and inhibited adipogenic differentiation and lipid accumulation [48].

The comet assay is a sensitive process utilized in the measurement and identification of DNA condemned at the cellular level. It has been documented that toxicity causes significant DNA damage, leading to abnormal changes in cellular mechanisms [73]. The percentage of DNA in the tail (tail intensity) shown to be proportionate to the incidence of DNA strand-breaks; the results can be expressed by categorizing cell damage according to the amount of DNA in the tail [14,79]. The outcome of this study confirmed that the administration of LCT induced DNA was damaged as indicated by the comet assay. These results are in agreement with the previously reported results, which showed that LCT induced DNA fragmentation in rat lymphocytes and by cypermethrin in the liver of rat [53]. Also, it was demonstrated that deltamethrin administration causes testicular DNA damage in rats [39]. In a previous study, it was reported that DNA damage in humans is associated with pyrethroid insecticide concentrations [52]. This may be partially due to the generation of oxidative lesions, which are indicators of oxidized purine and pyrimidine [13]. Ginger-supplemented LCT-treated group demonstrated less DNA breakdown in comparison to the LCT-treated group. Ginger may, therefore, be beneficial in minimizing the risk of DNA fragmentation caused by LCT toxicity. This finding is similar to that of [41], who stated that curcumin inhibits the generation of reactive oxygen species (ROS) that causes DNA damage.

5. Conclusion

In this study, we focused on the medicinal impacts of ginger and its components in the oxidative stress management activities. The results of this study showed that LCT affected the thyroid function and structure by disrupting the normal levels of antioxidant enzymes, thyroid hormones level and by causing an abnormal histological arrangement and DNA damage in the thyroid gland. Therefore, the use of this insecticide should be controlled. However, Ginger shows an important

effect in the suppression of LCT side effect, leading to a noticeable improvement in the histological and biochemical activity; including anti-oxidant enzymes, thyroid hormone level. Ginger extract and its effective components can be used as a suitable agent for controlling and preventing Lambda-cyhalothrin toxicity and genotoxicity-induced DNA damage. This investigation confirmed that ginger reduced the effect caused by LCT. Additional studies should investigate the mechanisms of action of the natural components of ginger and its antioxidant effects.

Conflict of interest statement

The author declares that there are no conflicts of interest.

Acknowledgments

Not applicable.

References

- [1] M. Abdollahi, A. Ranjbar, S. Shadina, S. Nikfar, A. Rezaie, Pesticides and oxidative stress: a review, *Med. Sci. Monit.* 10 (6) (2004) 141–147.
- [2] M. Abdul-Hamid, M. Salah, Lycopene reduces deltamethrin effects induced thyroid toxicity and DNA damage in albino rats, *J. Basic. Appl. Zool.* 66 (4) (2013) 155–163.
- [3] H. Aebi, S.R. Wyss, B. Scherz, F. Skvaril, Heterogeneity of erythrocyte catalase II. Isolation and characterization of normal and variant erythrocyte catalase and their subunits, *Eur. J. Biochem.* 48 (1) (1974) 137–145.
- [4] N. Akhtar, S.A. Kayani, M.M. Ahmad, M. Shahab, Insecticide-induced changes in secretory activity of the thyroid gland in rats, *J. Appl. Toxicol.* 16 (5) (1996) 397–400.
- [5] W.M. Al-Amoudi, Effect of propolis on the reproductive toxicity of deltamethrin in male albino rats, *Anat. Physiol.* 5 (s5) (2015), <http://dx.doi.org/10.4172/2161-0940.S5-004>.
- [6] D.A. Ali, M.F. Ismail, H.A. Badr, Hepatoprotective effect of ginger extract against the toxicity of 7, 12-dimethylbenz (a) anthracene (DMBA) in albino rats, *World J. Pharm. Sci.* 1 (3) (2013) 61–71.
- [7] H.R. Arshad, M.A. Fahad, M.A. Salah, Active ingredients of ginger as potential candidates in the prevention and treatment of diseases via modulation of biological activities, *Int. J. Physiol. Pathophysiol. Pharmacol.* 6 (2) (2014) 125–136.
- [8] N. Aryaeian, H. Tavakkoli, Ginger and its effects on inflammatory diseases, *Adv. Food Technol. Nutr. Sci. Open J.* 1 (4) (2015) 97–101.
- [9] M.M.Z. AL-Sharif, Effect of therapeutic ginger on genotoxic of taxol drug (anti-cancer) in bone marrow cell of male mice, *J. Life Sci.* 5 (2011) 897–905.
- [10] E. Auso, R. Lavado-Autric, E. Cuevas, F.E. Del Rey, E. Morreale, P. Berbel, A moderate and transient deficiency of maternal thyroid function at the beginning of fetal neocortigenesis alters neuronal migration, *Endocrinology* 145 (2014) 4037–4047.
- [11] M. Axelstad, J. Boberg, C. Nellesmann, M. Kiersgaard, P.R. Jacobsen, S. Christiansen, K.S. Hougaard, U. Hass, Exposure to the widely used fungicide mancozeb causes thyroid hormone disruption in rat dams but no behavioral effects in the offspring, *Toxicol. Sci.* 120 (2) (2011) 439–446.
- [12] M.J. Bak, S. Ok, M. Jun, W.S. Jeong, 6-shogaol-rich extract from ginger up-regulates the antioxidant defense systems in cells and mice, *Molecules* 17 (7) (2012) 8037–8055.
- [13] A. Bedir, Y. Aliyazicioglu, B. Bilgici, Z. Yurdakul, M. Uysal, D. Suvaci, A. Okuyucu, H. Kahrama, M. Hokelek, M. Alvr, Assessment of genotoxicity in ratseated with the antidiabetic agent, Pioglitazone 49 (3) (2008) 185–191.
- [14] C. Betti, R. Barale, B.L. Pool-Zobel, Comparative studies on cytotoxic and genotoxic effects of two organic mercury compounds in lymphocytes and gastric mucosa cells of Sprague-Dawley rats, *Environ. Mol. Mutagen.* 22 (1993) 172–180.

- [15] U. Bhandari, R. Kanojia, K.K. Pillai, Effect of ethanolic extract of *Zingiber officinale* on dyslipidaemia in diabetic rats, *J. Ethnopharmacol.* 97 (2) (2005) 227–230.
- [16] Y.A. Bailey-Shaw, L.A. Williams, G.A. Junor, C.E. Green, S.L. Hibbert, C.N. Salmon, A.M. Smith, Changes in the contents of oleoresin and pungent bioactive principles of Jamaican ginger (*Zingiber officinale* Roscoe) during maturation, *J. Agric. Food Chem.* 56 (14) (2008) 5564–5571.
- [17] D.Z. Bissacot, I. Vassilief, Pyrethroid residues in milk and blood of dairy cows following single topical applications, *Vet. Hum. Toxicol.* 39 (1) (1997) 6–8.
- [18] D. Blessy, K. Suresh, M.A. Vijayanand, G. Sugunadevi, Evaluation of chemopreventive potential of *Zingiber officinale* Roscoe ethanolic root extract on 7, 12-dimethyl benz[*a*]anthracene induced oral carcinogenesis, *Res. J. Agric. Biol. Sci.* 5 (2009) 775–781.
- [19] A. Celik, B. Mazmanci, Y. Cannlca, Ü. Comeleköglu, A.H. Askin, Evaluation of cytogenetic effects of Lambda-cyhalothrin on Wistar rat bone marrow by gavage administration, *Ecotoxicol. Environ. Saf.* 61 (1) (2005) 128–133.
- [20] D. Chakraborty, A. Mukherjee, S. Sikdar, A. Paul, S. Ghosh, A.R. Khuda-Bukhsh, [6]-gingerol isolated from ginger attenuates sodium arsenite induced oxidative stress and plays a corrective role in improving insulin signalling in mice, *Toxicol. Lett.* 210 (1) (2012) 34–43.
- [21] C. Corcellas, F.M. Luisa, T.J. Paulo, O. Malm, W. Ocampo-Duque, E. Eljarrat, D. Barcelo, Pyrethroids in human breast milk: occurrence and nursing daily intake estimation, *Environ. Int.* 47 (2012) 17–22.
- [22] J.W. Daily, B.M. Yang, B.D. Sol Kim, B.S. Park, Efficacy of ginger for treating Type 2 diabetes: a systematic review and meta-analysis of randomized clinical trials, *J. Ethn. Foods.* 2 (2015) 36–43.
- [23] C. Dey, S. KumarSaha, Histological alteration in different tissues of freshwater Teleost *Labeo rohita* (Hamilton) induced by Lambda-cyhalothrin 5% EC and Marshal (Carbosulfan 25%EC), *J. Biol. Today's World* 5 (7) (2016) 107–112.
- [24] S. Dugasani, M.R. Pichika, V.D. Nadarajah, M.K. Balijepalli, S. Tandra, J.N. Korlakunta, Comparative antioxidant and anti-inflammatory effects of [6]-gingerol, [8]-gingerol, [10]-gingerol and [6]-shogaol, *J. Ethnopharmacol.* 127 (2010) 515–520.
- [25] F.M. El-Demerdash, Lambda-cyhalothrin-induced changes in oxidative stress biomarkers in rabbit erythrocytes and alleviation effect of some antioxidants, *Toxicol. In Vitro* 21 (2007) 392–397.
- [26] N.M. El-Ghonaimy, Role of ginger (*zingiber officinale*) against metalaxyl induced hepatotoxicity in male albino rats: a histological and immunohistochemical study, *J. Histol. Histopathol.* 2 (9) (2015) 1–10, <http://dx.doi.org/10.7243/2055-091X-2-9>.
- [27] A.A. El-Masry, M.I. Yousef, H.K. Hussein, N.A. Khairallah, N.M. van Straalen, L-carnitine protects against oxidative stress induced by sublethal exposure to the synthetic pyrethroid, lambda-cyhalothrin, in rats, *Glob. Adv. Res. J.* 3 (2) (2014) 12–24.
- [28] M.A. El Shemy, A.O. Abdalla, K.M. Fararh, Antioxidant and hepatoprotective effects of ginger in rats, *Benha Vet. Med. J.* 22 (2) (2011) 9–16.
- [29] A.A. El-Sheikh, H.M. Ibrahim, The propolis effect on chlorpyrifos induced thyroid toxicity in male albino rats, *J. Med. Toxicol. Clin. Forensic Med.* 3 (1–3) (2017), <http://dx.doi.org/10.21767/2471-8505.100023>.
- [30] D.C. Evered, B.C. Osrnmon, P.A. Smith, R. Hail, T. Bird, Grades of hypothyroidism, *Br. Med. J.* 1 (5854) (1973) 657–662.
- [31] C.S. Ezeonu, P.A.C. Egbuna, L.U.S. Ezeanyika, C.G. Nkwonta, N.D. Idoko, Antihepatotoxicity studies of crude extract of *Zingiber officinale* on CCl₄ induced toxicity and comparison of the extract's fraction D hepatoprotective capacity, *Res. J. Med. Sci.* 5 (2011) 102–107.
- [32] H. Fetoui, M. Makni, M. Garouiel, N. Zeghal, Toxic effects of Lambda-cyhalothrin, a synthetic pyrethroid pesticide, on the rat kidney: involvement of oxidative stress and protective role of ascorbic acid, *Exp. Toxicol. Pathol.* 62 (6) (2010) 593–599.
- [33] H. Fetoui, A. Feki, G. Ben Salah, H. Kamoun, F. Fakhfakh, R. Gdoura, Exposure to Lambda-cyhalothrin, a synthetic pyrethroid, increases reactive oxygen species production and induces genotoxicity in rat peripheral blood, *Toxicol. Ind. Health* 31 (5) (2015) 433–441.
- [34] B. Fuhrman, M. Rosenblatt, T. Hayek, R. Coleman, M. Aviram, Ginger extract consumption reduces plasma cholesterol, inhibits LDL oxidation and attenuates development of atherosclerosis in atherosclerotic, apolipoprotein E-deficient mice, *J. Nutr.* 130 (5) (2000) 1124–1131.
- [35] A. Giriraju, G.Y. Yunus, Assessment of antimicrobial potential of 10% ginger extract against *Streptococcus mutans*, *Candida albicans*, and *Enterococcus faecalis*: an in vitro study, *Indian J. Dent. Res.* 24 (2013) 397–400.
- [36] S.K. Gupta, A. Sharma, Medicinal properties of *Zingiber officinale* Roscoe - a review, *J. Pharm. Biol. Sci.* 9 (5) (2014) 124–129.
- [37] V. Heydari, M. Navaei-Nigeh, M. Rahimifard, A. Azadeh Mohammadrad, M. Baeeri, M. Abdollahi, Biochemical and molecular evidences on the protection by magnesium oxide nanoparticles of chlorpyrifos-induced apoptosis in human lymphocytes, *J. Res. Med. Sci.* 20 (11) (2015) 1021–1031.
- [38] M.F. Ismail, H.M. Mohamed, Deltamethrin-induced genotoxicity and testicular injury in rats: comparison with biopesticide, *Food Chem. Toxicol.* 50 (2012) 3421–3425.
- [39] C. Jing, W. Yinghuan, W. Huili, Li. Jianzhong, Xu. Peng, Bioaccumulation and enantioselectivity of type I and type II pyrethroid pesticides in earthworm, *Chemosphere.* 144 (2016) 1351–1357.
- [40] C. Jeong, S. Joo, Downregulation of reactive oxygen species in apoptosis, *J. Cancer Prev.* 12 (1) (2016) 13–20.
- [41] P. Kamtchoung, G.Y. Mbongue Fandio, T. Dimo, H.B. Jatsa, Evaluation of androgenic activity of *Zingiber officinale* and *Pentadiplandra brazzeana* in male rats, *Asian J. Androl.* 4 (2002) 299–301.
- [42] H.T. Khashan, Determination of a pyrethroid insecticide deltamethrin residues in cattle meat in Baghdad Province/Al-Rusafa, *Int. J. Adv. Res. Biol. Sci.* 3 (11) (2016) 193–199.
- [43] J.A. Kiernan, *Histological and Histochemical Methods - Theory and Practice*, Scion Publishing Ltd, Banbury, UK, 2016 ISBN 978 1 907904 32 5; P:571.
- [44] D. Kim, J. Moon, B. Chun, The initial hyperglycemia in acute type II pyrethroid poisoning, *J. Korean Med. Sci.* 30 (2015) 365–370.
- [45] E.M. Koh, H.J. Kim, S. Kim, W.H. Choi, Y.H. Choi, S.Y. Ryu, Y.S. Kim, W.S. Koh, S.Y. Park, Modulation of macrophage functions by compounds isolated from *Zingiber officinale*, *Planta Med.* 2009 75 (2) (2009) 148–151.
- [46] J. Leghait, V. Gayrard, N. Picard-Hagen, M. Camp, E. Perdu, P. Toutain, C. Viguié, Fipronil-induced disruption of thyroid function in rats is mediated by increased total and free thyroxine clearances concomitantly to increased activity of hepatic enzymes, *Toxicology* 255 (1–2) (2009) 38–44.
- [47] C. Li, L. Zhou, Inhibitory effect 6-geringol on adipogenesis through activation of Wnt/ β -catenin signaling pathway in 3T3-L1 adipocytes, *Toxicol. In Vitro* 30 (1) (2015) 394–401.
- [48] B. Malene, F.R. Ulla, M. Katharina, A. Main, Thyroid effects of endocrine disrupting chemicals, *Mol. Cell. Endocrinol.* 355 (2) (2012) 240–248.
- [49] M. Marković, S. Cupać, R. Durović, J. Milinović, P. Kljajić, Assessment of heavy metal and pesticide levels in soil and plant products in agricultural area of Belgrade, Serbia, *Arch. Environ. Contam. Toxicol.* 58 (2010) 341–351.
- [50] N.S. Mashhadi, G.R. Reza, G. Askari, H.M. Mitra, D.L. Leila, R.M. Mohammad, Anti-oxidative and anti-inflammatory effects of ginger in health and physical activity: review of current evidence, *Int. J. Prev. Med.* 4 (1) (2013) S36–S42.
- [51] J.D. Meeker, D.B. Barr, R. Hauser, Human semen quality and sperm DNA damage in relation to urinary metabolites of pyrethroid insecticides, *Hum. Reprod.* 23 (19) (2008) 32–40.
- [52] N.K. Madkour, Protective effect of curcumin on oxidative stress and DNA fragmentation against lambda cyhalothrin-induced liver damage in rats, *J. Appl. Pharm. Sci.* 2 (12) (2012) 076–081.
- [53] K. Muthukumaravel, O. Sathick, S. Raveendran, Lambda-cyhalothrin induced biochemical and histological changes in the liver of *Oreochromis mossambicus* (peeters), *Int. J. Pure Appl. Zool.* 1 (1) (2013) 80–85.
- [54] M. Nassiri, A. Khaki, H.R. Ahmadi-Ashtiani, S.H. Rezazadeh, H. Rastgar, Sh. Gharachurlu, Effects of ginger on spermatogenesis in streptozotocin-induced diabetic rat, *J. Medicinal Plants.* 8 (31) (2009) 118–124.
- [55] R. Nicoll, M.Y. Henein, Ginger (*Zingiber officinale* Roscoe): a hot remedy for cardiovascular disease? *Int. J. Cardiol.* 131 (2009) 408–409.
- [56] H. Ohkawa, N. Ohishi, K. Yagi, Assay for lipid peroxidation in animal tissues by thiobarbituric acid reaction, *Anal. Biochem.* 95 (1979) 351–358.
- [57] A.G.E. Pearce, P.J. Stoward, *Histochemistry, Theoretical and Applied Science*, fourth edition, Churchill Livingstone, The University of Michigan, USA, 1980.
- [58] S. Prasad, A.K. Tyagi, Ginger and its constituents: role in prevention and treatment of gastrointestinal cancer, *Gastroenterol. Res. Pract.* (2015) 11 ID 142979.
- [59] A.H. Rahmani, F.M. Al shabmi, S.M. Aly, Active ingredients of ginger as potential candidates in the prevention and treatment of diseases via modulation of biological activities, *Int. J. Physiol. Pathophysiol. Pharmacol.* 6 (2) (2014) 125–136.
- [60] W.B. Reini, M.G.T. Chris, T.J.S. Paul, A.Z. Gerhard, R. Nel, Pesticide exposure: the hormonal function of the female reproductive system disrupted? *Reprod Biol Endocrinol.* 4 (30) (2006), <http://dx.doi.org/10.1186/1477-7827-4-30>.
- [61] R.F. Rest, J.K. Spitznagel, Subcellular distribution of superoxide dismutases in human neutrophils. Influence of myeloperoxidase measurement of superoxide dismutase activity, *Biochem J.* 166 (1977) 145–153.
- [62] M.D. Pine, J.K. Hiney, B. Lee, W.L. Dees, The pyrethroid pesticide fenvalerate suppresses the afternoon rise of luteinizing hormone and delays puberty in female rats, *Environ. Health Perspect.* 116 (9) (2008) 1243–1247.
- [63] K. Prasanthi Muralidhara, P.S. Rajini, Fenvalerate-induced oxidative damage in rat tissues and its attenuation by dietary sesame oil, *Food Chem. Toxicol.* 43 (2005) 299–306.
- [64] B. Sereida, H. Bouwman, H. Kylin, Comparing water, bovine milk, and indoor residual spraying as possible sources of DDT and pyrethroid residues in breast milk, *J. Toxicol. Environ. Health Part A* 72 (2009) 842–851.
- [65] D. Schlenk, R. Lavado, J.E. Loyo-Rosales, W. Jones, L. Maryoung, N. Riar, I. Werner, D. Sedlak, Reconstitution studies of pesticides and surfactants exploring the cause of estrogenic activity observed in surface waters of the San Francisco Bay Delta, *Environ. Sci. Technol.* 46 (2012) 9106–9111.
- [66] J.J. Schleier, R.K.D. Peterson, The joint toxicity of Type I, II, and nonester pyrethroid insecticides, *J. Econ. Entomol.* 105 (1) (2012) 85–91.
- [67] A.M. Shady, F.I. Noor El-Deen, Effect of chlorpyrifos on thyroid gland of adult male albino rats, *Egypt. J. Histol.* 33 (3) (2010) 441–450.
- [68] K.R. Shanmugam, K. Mallikarjuna, N. Kesireddy, K.S. Reddy, Neuroprotective effect of ginger on anti-oxidant enzymes in streptozotocin-induced diabetic rats, *Food Chem. Toxicol.* 49 (4) (2011) 893–897.
- [69] P.R. Shirin, P. Jamuna, Chemical composition and antioxidant properties of ginger root (*Zingiber officinale*), *J. Med. Plants Res.* 4 (24) (2010) 2674–2679.
- [70] M.N. Siddaraju, S.M. Dharmesh, Inhibition of gastric H.k + +, ATPase and helicobacter pylori growth by phenolic antioxidants of *Zingiber officinale*, *Mol. Nutr. Food Res.* 51 (3) (2007) 324–332.
- [71] N.P. Singh, M.T. McCoy, R.R. Tice, E.L. Schneider, A simple technique for quantitation of low levels of DNA damage in individual cells, *Exp. Cell Res.* 175 (1988) 184–191.
- [72] R. Sreekumaran, R. Paulmurugan, V. Wilsanand, Genotoxic effects of commonly used pesticides of south India in human lymphocytes, *Poll. Res.* 24 (1988) 7–12.
- [73] S. Stoyanova, V. Yancheva, I. Iliev, T. Vasileva, V. Bivolarski, I. Velcheva, E. Georgieva, Biochemical, histological and histochemical changes in *aristichthys nobilis* rich liver exposed to thiamethoxam, *Periodic Biologorum* 118 (1) (2016)

- 29–36.
- [75] Y.J. Surh, Molecular mechanisms of chemopreventive effects of selected dietary and medicinal phenolic substances, *Mutat. Res.* 428 (1-2) (1999) 305–327.
- [76] S. Sun, X.L. Xu, L.C. Xu, L. Song, X. Hong, J.F. Chen, L.B. Cui, X.R. Wang, Antiandrogenic activity of pyrethroid pesticides and their metabolite in reporter gene assay, *Chemosphere* 66 (2007) 474–479.
- [77] S.B. Symington, R.K. Frisbie, K.D. Lu, J.M. Clark, Action of cismethrin and deltamethrin on functional attributes of isolated presynaptic nerve terminals from rat brain, *Pestic. Biochem. Physiol.* 87 (2007) 172–181.
- [78] M. Thomson, K.K. Al-Qattan, S.M. Al-Sawan, M.A. Alnaqeeb, I. Khan, M. Ali, The use of ginger (*Zingiber officinale* Rosc.) as a potential anti-inflammatory and antithrombotic agent, *Prostagl Leukotr Essen Fat. Acids* 67 (2002) 475–478.
- [79] R.R. Tice, G.G. Hook, M. Donner, D.I. McRee, A.W. Guy, Genotoxicity of radio-frequency signals I. Investigation of DNA damage and micronuclei induction in cultured human blood cells, *Bioelectromagnetics* 23 (2002) 113–126.
- [80] K. Tukhtaev, M. Zokirova, S. Tulemetov, N. Tukhtaev, Effect of prolonged exposure of low doses of Lambda-cyhalothrin on the thyroid function of the pregnant rats and their offspring, *Med. Health Sci. J.* 13 (2012) 86–92.
- [81] C. Turgut, H. Ornek, T.J. Cutright, Determination of pesticide residues in Turkey's table grapes: the effect of integrated pest management organic farming and conventional farming, *Environ. Monit. Assess.* 173 (2011) 315–323.
- [83] S. Wang, C. Zhang, G. Yang, Y. Yang, Biological properties of 6-gingerol: a brief review, *Nat. Prod. Commun.* 9 (7) (2014) 1027–1030.
- [84] X. Wang, M.A. Martínez, M. Dai, D. Chen, I. Ares, A. Romero, V. Castellano, M. Martínez, J.L. Rodríguez, M.R. Martínez-Larrañaga, A. Anadón, Z. Yuan, Permethrin-induced oxidative stress and toxicity and metabolism. A review, *Environ. Res.* 149 (2016) 86–104.
- [85] D.P. Weston, M.J. Lydy, Urban and agricultural sources of pyrethroid insecticides to the Sacramento-San Joaquin Delta of California, *Environ. Sci. Technol.* 44 (2010) 1833–1840.
- [86] D.P. Weston, H.L. Ramil, M.J. Lydy, Pyrethroid insecticides in municipal wastewater, *Environ. Toxicol. Chem.* 32 (2013) 2460–2468.
- [87] M. Wissem, I.H. Aziza, B. Aicha, B. Aghleb, T. Olivier, R. Benoit, Effect of endocrine disruptor pesticides: a review, *Int. J. Environ. Res. Public Health* 8 (6) (2011) 2265–2303.
- [88] World Health Organization, Lambda-Cyhalothrin, International Program on Chemical Safety, Geneva, Switzerland (2003) http://www.who.int/whopes/quality/en/Lambdacyhalothrin_eval_specs_WHO_2003.pdf.
- [89] K. Yadamma, K.R. Devi, In vivo protective effects of ginger extract on cyclophosphamide induced chromosomal aberrations in bone marrow cells of swiss mice, *Int. J. Pharm. Pharm. Sci.* 1 (12) (2014) 124–131.
- [90] H.Z. Yang, M. Nishimura, K. Nishimura, S. Kuroda, T. Fujita, Quantitative structure-activity studies of pyrethroids. 12. Physicochemical substituent effects of meta-phenoxybenzyl alpha, alpha-disubstituted acetates on insecticidal activity, *Pestic. Biochem. Physiol.* 29 (1987) 217–232.
- [91] E.A. Yasmin, A.A. Emam, Toxicological influences of Lambda-cyhalothrin and evaluation of the toxicity ameliorative effect of pomegranate in albino rats, *Glob. Vet.* 14 (6) (2015) 913–921.
- [92] M. Yegambaram, M. Bhagyashree, G.B. Thomas, U.H. Rolf, Role of environmental contaminants in the etiology of Alzheimer's disease: a review, *Curr. Alzheimer Res.* 12 (2) (2015) 116–146.
- [93] M.I. Yousef, T.I. Awad, E.H. Mohamed, Deltamethrin-induced oxidative damage and biochemical alterations in rat and its attenuation by vitamin E, *Toxicology* 227 (2006) 240–247.
- [94] S. Zafar, A. Ahmed, R. Ahmad, M.A. Randhawa, M. Gulfraz, A. Ahmad, F. Siddique, Chemical residues of some pyrethroid insecticides in eggplant and okra fruits: effect of processing and chemical solutions, *J. Chem. Soc. Pak.* 34 (2012) 1169–1175.
- [95] Q. Zhang, C. Wang, L. Sun, L. Li, M. Zhao, Cytotoxicity of Lambda-cyhalothrin on the macrophage cell line RAW 264.7, *J. Environ. Sci. (China)* 22 (3) (2010) 428–432.
- [96] S.M. Zick, Z. Djuri, M.T. Ruffin, A.J. Litzinger, D.P. Normolle, S. Alrawi, M.R. Feng, D.E. Brenner, Pharmacokinetics of 6-gingerol, 8-gingerol, 10-gingerol, and 6-shogaol and conjugate metabolites in healthy human subjects, *Cancer Epidemiol Biomarkers Prev.* 17 (2008) 1930–1936.