




Prospective, Multicenter, Clinical and Radiographic Evaluation of a Biointegrative, Fiber-Reinforced Implant for Proximal Interphalangeal Joint Arthrodesis

Luke D. Cicchinelli, DPM^{1,2} , Jurij Štalc, MD³,
Martinus Richter, MD, PhD⁴ , and Stuart Miller, MD⁵ 

Abstract

Background: A novel biointegrative implant was developed for proximal interphalangeal joint (PIPJ) arthrodesis to treat hammertoe deformity. Composed of continuous reinforcing mineral fibers bound by bioabsorbable polymer matrix, the implant demonstrated quiescent, gradual degradation with complete elimination at 104 weeks in animal models. This prospective trial assessed the implant's safety, clinical performance, and fusion rate of PIPJ arthrodesis for hammertoe correction.

Methods: Twenty-five patients (mean age 63.9 ± 7.5 years) who required PIPJ arthrodesis were enrolled at 3 centers. Outcomes included radiographic joint fusion, adverse events, pain visual analog scale (VAS) score, Foot and Ankle Ability Measure (FAAM) Activities of Daily Living (ADL) score, and patient satisfaction. Patients were evaluated 2, 4, 6, 12, and 26 weeks postoperatively.

Results: Twenty-two patients (88%) achieved radiographic fusion at 26 weeks. All joints (100%) were considered clinically stable, with no complications or serious adverse events. Pain VAS improved from 5.3 ± 2.5 preoperatively to 0.5 ± 1.4 at 26 weeks postoperatively. FAAM-ADL total scores and level of functioning improved by mean 19.5 ± 19.0 points and 24.4 ± 15.7 percentage points, respectively, from preoperation to 26 weeks postoperation. Improvements in pain VAS and FAAM scores surpassed established minimal clinically important differences. All patients were very satisfied (84%) or satisfied (16%) with the surgery. Patient-reported postoperative results greatly exceeded (72%), exceeded (20%), or matched (8%) expectations.

Conclusion: This prospective, multicenter, first-in-human clinical trial of a novel biointegrative fiber-reinforced implant in PIPJ arthrodesis of hammertoe deformity demonstrated a favorable rate of radiographic fusion at 12 and 26 weeks, with no complications and good patient-reported clinical outcomes.

Level of Evidence: Level IV, prospective case series.

Keywords: arthrodesis, bioabsorbable, continuous mineral fibers, deformity, fusion, hammertoe

¹ Clínica Cándido Guillén, Vigo, Spain

² Clínica Pereira, Vigo, Spain

³ Service for Foot and Ankle Orthopaedics, Valdoltra Orthopedic Hospital, Ankaran, Slovenia

⁴ Department for Foot and Ankle Surgery, Rummelsberg and Nuremberg, Germany

⁵ Department of Orthopaedic Surgery, MedStar Union Memorial Hospital, Baltimore, MD, USA

Corresponding Author:

Luke D. Cicchinelli, DPM, Consultant Foot and Ankle Surgeon, Rua Isaac Diaz Pardo 59, Vigo, 36210, Spain.

Email: loked.cicchinelli@gmail.com



Introduction

Hammertoe deformity results from biomechanical dysfunction,^{4,15} leading to flexion deformity of the proximal interphalangeal (PIP) joint and hyperextension of the metatarsophalangeal (MTP) joint. When nonoperative treatment fails, surgery is considered to relieve pain, realign the toe, and correct deformity, primarily by PIP joint arthrodesis.^{19,43} However, consensus on optimal fixation is lacking.¹⁴

Kirschner wire (K-wire) fixation is considered the standard treatment for correction of hammertoe deformity.^{21,28,44} Although inexpensive and easy to insert, percutaneous K-wires protrude from the toe during the initial 6-week recovery period and require removal.²⁴ Complications include wire site infection, wire migration, wire breakage, and nonunion or malunion.^{24,28,44,46} Additionally, K-wire fixation with only 1 wire does not provide rotational stability, which can lead to malalignment, relapse of deformity, and a need for revision surgery.^{21,24} To address the limitations of K-wire fixation, a variety of intramedullary internal fixation devices that do not require removal have been developed to improve the standard of care. These PIP joint fixation devices include permanent implants made from a variety of metals (eg, steel, titanium)^{10,12,16,17,22} or polyetheretherketone (PEEK).³ Allograft implants have also been developed.^{25,31,34} Most of these implants have not demonstrated improved complication and revision rates when compared to K-wire fixation.^{14,19,21,33,34,44,45}

A novel class of biointegrative fixation implants has been developed to provide strong, secure fixation while gradually integrating into native tissue. These implants are engineered from continuous reinforcing mineral fibers bound together by a bioabsorbable polymer [poly(L-lactide-co-D,L-lactide), PLDLA] matrix.³⁷ The mineral fibers are composed of elements inherent in native bone, including calcium, silica, and magnesium, which have been shown both in vitro and in vivo to promote bone growth and regeneration.^{1,7,8} With their high mineral content, the biointegrative implants have been shown in animal models to maintain strength during bone healing while undergoing a controlled and gradual degradation, with reduced inflammatory response.⁶ This allows the bone to restore its native physiology on full resorption of the implant, avoids a prolonged or adverse inflammatory cell response, and eliminates the need for hardware removal procedures.^{36,37}

A biointegrative fiber-reinforced implant has been designed to operatively treat hammertoe deformity through PIP joint arthrodesis. The implant bridges the proximal phalanx to the middle phalanx to support fusion of the resected joint. An animal model of physiological load-bearing osteotomy fixation demonstrated bone fixation and fusion with the fiber-reinforced implant were equivalent to those of standard stainless-steel implants.⁶ Animal studies also demonstrated gradual, progressive degradation of the fiber-reinforced implant with complete elimination by 104 weeks.⁶

The purpose of this prospective clinical study was to assess the safety, fusion rate, and clinical performance of this novel, biointegrative, fiber-reinforced fixation implant in PIP joint arthrodesis of hammertoe deformity. The primary aim of this clinical investigation was to determine the radiographic fusion rate and serious adverse events. In addition, patient-reported clinical outcomes and satisfaction were assessed.

Methods

Study Design

This multicenter, prospective, single-arm, open-label study was conducted at a hospital in Slovenia and 2 centers in Spain between December 2018 and October 2019. Patients aged 18-75 years who required PIP joint arthrodesis for correction of hammertoe deformity of the second, third, or fourth toe and were able to provide written, informed consent were eligible for inclusion in the study. Further inclusion and exclusion criteria are shown in Table 1. Recruitment lasted until 25 patients were treated with the fiber-reinforced hammertoe fixation implant (Figure 1). This study adhered to the Declaration of Helsinki and was approved by the local ethics committee at each institution.

During the screening visit, the patient demographic data, medical history, medication information, and preoperative laboratory data were recorded. A foot and toe assessment and a pain assessment were performed (ie, "baseline"). Radiographs were taken and evaluated, and computed tomography (CT) scans were ordered at the surgeon's discretion.

Patient Demographics

Twenty-nine patients were screened for this study (Figure 1). Three patients were excluded because of vitamin D deficiency. One patient was excluded as unable to comply with the follow-up schedule. Thus, 25 patients were enrolled, including 24 women (96%). The mean age of the cohort was 63.9 ± 7.5 (range: 48.6-74.2) years (Table 2). The hammertoe deformity affected the second toe in 24 patients (96%) and the third toe in 1 patient (4%). All patients (100%) were available for follow-up at 12 weeks and 26 weeks.

Study Device

The biointegrative hammertoe fixation implant (OSSIOfiber[®] Hammertoe Fixation Implant, OSSIO Ltd, Caesarea, Israel) is composed of continuous, reinforcing, natural mineral fibers (SiO₂, Na₂O, CaO, MgO, B₂O₃, and P₂O₅; approximately 50%), bound with PLDLA polymer matrix (approximately 50%). The implant used in this study has a hexagonal cross section with a nominal dimension of 2.9 mm (Figure 2A). The ribbed design permits implant fixation in the phalangeal canal of the toe. The internal structure of the implant consists of layers of oriented continuous fibers (Figure 2B) that provide mechanical strength

Table 1. Study Inclusion and Exclusion Criteria.

Inclusion Criteria	Exclusion Criteria
Age 18-75 y	Previous ipsilateral forefoot surgery involving the toe to be treated
Requires correction arthrodesis of the PIP joint of the second, third, or fourth toe for correction of hammertoe deformity	Toe intended for surgery is not suitable for the procedure and for the implant dimensions, based on pre- and intra-operative clinical and radiological assessments
Able to provide voluntary, written, informed consent	Pre-existing foot condition (other than the single-digit hammertoe deformity to be corrected) likely to permanently limit good foot function, cause persistent pain, or limit the return to normal ambulation
Able and willing to perform all study procedures, postoperative care, and follow-up visits	Hallux valgus, creating a "crossover toe" with the toe to be treated
Has not participated in another clinical study with the last 30 d and will not participate in any other research protocol during the investigation	Requires osseous procedure for hammertoe deformity correction on any other toes of the study foot
	Requires midfoot, hindfoot, or ankle surgery during the study period
	Requires bilateral foot surgery during the study period
	Has recently undergone, or requires during the study period, an operative procedure that would interfere with postoperative recovery procedures or could affect the study outcomes
	Active or suspected infection in foot
	Open wounds on study toe
	Pre-existing impaired mobility which would hamper postoperative rehabilitation and ambulation
	Unable to walk without an assistive device (custom-made shoes and canes are not considered a walking aid for this study)
	History of peripheral vascular disease or clinical indications of limited blood supply
	History of peripheral or central neurologic disorders causing symptoms such as pain, dysesthesia, or numbness of the operative foot; or active use of medications for neuropathic pain
	Receives treatment for diagnosed osteoporosis or metabolic bone disease, or any evidence of insufficient quantity or quality of bone
	Poor soft tissue envelope in the operative field or absence of musculoligamentous supporting structures
	On immunomodulators or biological response modifiers for rheumatoid arthritis
	Requires chronic anticoagulation medications or used anticoagulants within 10 days of surgery, prior to or following procedure
	Used nonsteroidal anti-inflammatory drugs within 2 wk of surgery, prior to or following procedure
	Does not demonstrate stable glycemic control, ie, HbA1c \geq 6.8 on a blood test within 30 days of surgery
	Vitamin D deficiency, defined as a level $<$ 15 ng/mL or $<$ 37.5 nmol/L on a 25-hydroxy vitamin D blood test performed within 30 days of surgery (a risk factor for nonunion ³²)
	Current tobacco use
	Currently undergoing chemotherapy or in 6 months prior to the study
	Predetermined life expectancy of less than 1 year
	Known allergy to the implant materials
	Metabolic disorder that might interfere with normal breakdown of the implant materials
	Is pregnant or intends to become pregnant during the course of the clinical investigation
	Documented cognitive deficiency
	A major underlying comorbidity (eg, severe respiratory disease, chronic renal insufficiency or failure, skeletal muscle spasticity or paralysis, generalized joint disease)
	Any condition that in the view of the treating physician makes it unsafe for the patient to participate in the clinical investigation

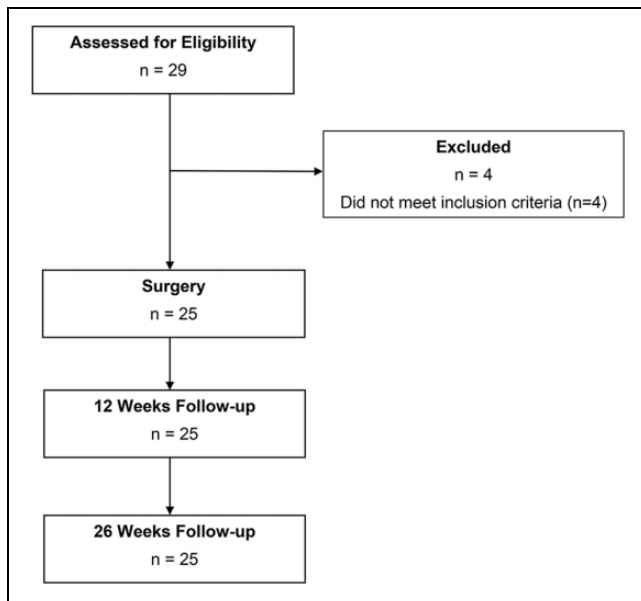


Figure 1. Patient disposition chart.

Table 2. Patient Demographics Preoperatively.

Demographic	Total Cohort (N = 25)
Sex: female ^a	24 (96)
Age, years	63.9 ± 7.5
Body mass index	27.4 ± 4.7
HbA1c, %	5.5 ± 0.4
Vitamin D, nmol/L	45.1 ± 17.7
Side: right ^a	16 (64)
Treated toe ^a	
Second	24 (96)
Third	1 (4)

^aShown as count and percentage.

through the bone healing process. Gradual integration of the implant begins as early as 4 weeks and is completed by 24 months.

Operative Procedure and Postoperative Care

Two foot and ankle surgeons performed all surgeries. On the day of the surgery, patient eligibility was confirmed, medication information was recorded, and a foot and toe assessment was performed. For the surgery, local and/or regional anesthesia was administered. Following the site standard of care, some patients received prophylactic antibiotic.

During the surgery, fluoroscopy imaging was taken as required, based on the surgeon's clinical judgment. The surgeon prepared the PIP joint for arthrodesis in the usual manner, with resection of both sides of the joint surface of the middle and proximal phalanges. The proximal phalanx diaphyseal canal and the middle phalanx diaphyseal canal were

drilled to the appropriate depth. Using the implant holder, the proximal end of the fiber-reinforced hammertoe fixation implant was introduced into the proximal phalanx, parallel to the long axis of the drill hole to prevent bending (Figure 3). The middle phalanx was manually reduced over the distal end of the implant while applying slow, steady pressure until bone-to-bone contact was reached (Figure 3). After confirming that the implant was properly fitted and fixated to the bone, the surgeon completed the procedure using routine soft tissue closure. Any adverse events during the procedures were recorded. Dorsoplantar, lateral, and lateral oblique radiographs were taken immediately following the procedure. All patients were fitted with a protective shoe for 6 weeks.

Nineteen of 25 patients (76%) underwent concomitant procedures for various first ray deformities, including but not limited to scarf, Akin, or Chevron osteotomies²⁰ and first MTP joint fusion.³⁸

Outcomes Measures

The primary performance endpoint was radiographic PIP joint fusion at 12 and 26 weeks, rated as either fusion ($\geq 50\%$ osseous bridging) or no fusion ($< 50\%$ osseous bridging) as assessed on radiographs and CT scans by the 2 surgeons who performed the surgeries and 2 other foot and ankle surgeons who had no direct contact with the patients. Radiographs were taken preoperatively, immediately postoperatively, and at 2, 6, 12, and 26 weeks follow-up. CT scans were taken at the 12- and 26-week follow-ups.

The primary safety endpoint was the rate and nature of serious adverse events throughout the study period. Any adverse events were recorded intraoperatively, immediately postoperatively, and at all follow-up visits.

Secondary endpoints included several patient-reported outcome measures: a visual analog scale (VAS) for pain with 0 representing no pain and 10 representing worst pain; the Foot and Ankle Ability Measure and Activities of Daily Living subscale (FAAM-ADL) questionnaire (total score, and percent level of functioning)³⁰; and a satisfaction questionnaire. When responding to the outcome questionnaires, patients were reminded to report solely based on the afflicted hammertoe, to minimize any bias due to concomitant procedures.

Patients returned for follow-up visits at 2, 4, 6, 12, and 26 weeks postoperatively. Medication information, any adverse events, and pain VAS scores were recorded at each visit. A foot and toe assessment was also performed and healing progress assessed. The FAAM-ADL questionnaire was completed preoperatively (ie, baseline) and at 12 and 26 weeks postoperatively. The satisfaction questionnaire was completed at 26 weeks' follow-up.

Data Collection and Statistical Analysis

A cohort of 25 patients with 26-week follow-up data was determined sufficient to evaluate the safety and




Figure 2. (A) The biointegrative, fiber-reinforced hammertoe fixation implant used in this study has a hexagonal cross-section of 2.9 mm. (B) Scanning electron microscope cross section of implant demonstrates continuous mineral fibers surrounded by polymeric material.

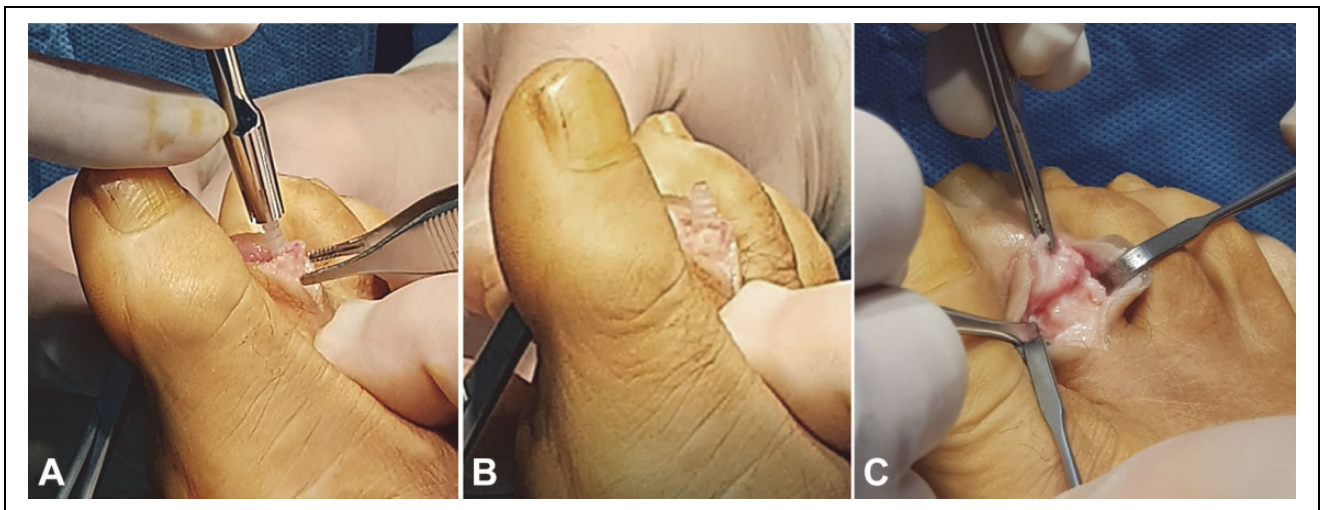


Figure 3. Hammertoe correction procedure. (A) The implant is inserted into the proximal phalanx. (B) Implantation into the proximal phalanx is completed. (C) The middle phalanx is mounted onto the distal end of the implant.

performance of the fiber-reinforced hammertoe fixation implant. The information provided by this cohort provides adequate data to compare with published literature for this indication. As such, this study was not intended to statistically test hypotheses and was not powered for statistical significance.

Data were collected using an electronic data capture system (DataFax DF/Net Research, Inc, Seattle, WA) and analyzed using a Statistical Analysis Software, version 9.4 (SAS Institute Inc, Cary, NC). Continuous variables are recorded as mean, standard deviation (SD), median, and range. Categorical variables are recorded as count and percentage.

Safety analysis was performed on all patients for whom the study procedure was initiated. The performance analysis was performed on all patients who completed at least 1 postprocedure visit and excluded patients with a major entry violation that likely affected outcome, as determined by the Medical Monitoring Board.

Results

Fusion Rate and Safety Parameters

At 12 and 26 weeks, 22 patients achieved radiographic fusion of the PIP joint as defined on radiographs (Figure 4) and CT scans (Figure 5), for an overall fusion rate of 88% at final follow-up. All 25 treated PIP joints were evaluated as clinically stable by the end of the clinical investigation, and none required further clinical intervention.

All 25 patients underwent the hammertoe correction procedure using the fiber-reinforced hammertoe fixation implant, with no observed serious adverse events related to the device or the procedure.

One patient reported swelling at the PIP fusion site 43 days post-procedure, which was assessed clinically as being of mild severity. The period of protective shoe wear was extended to 3 months, and the swelling resolved by the

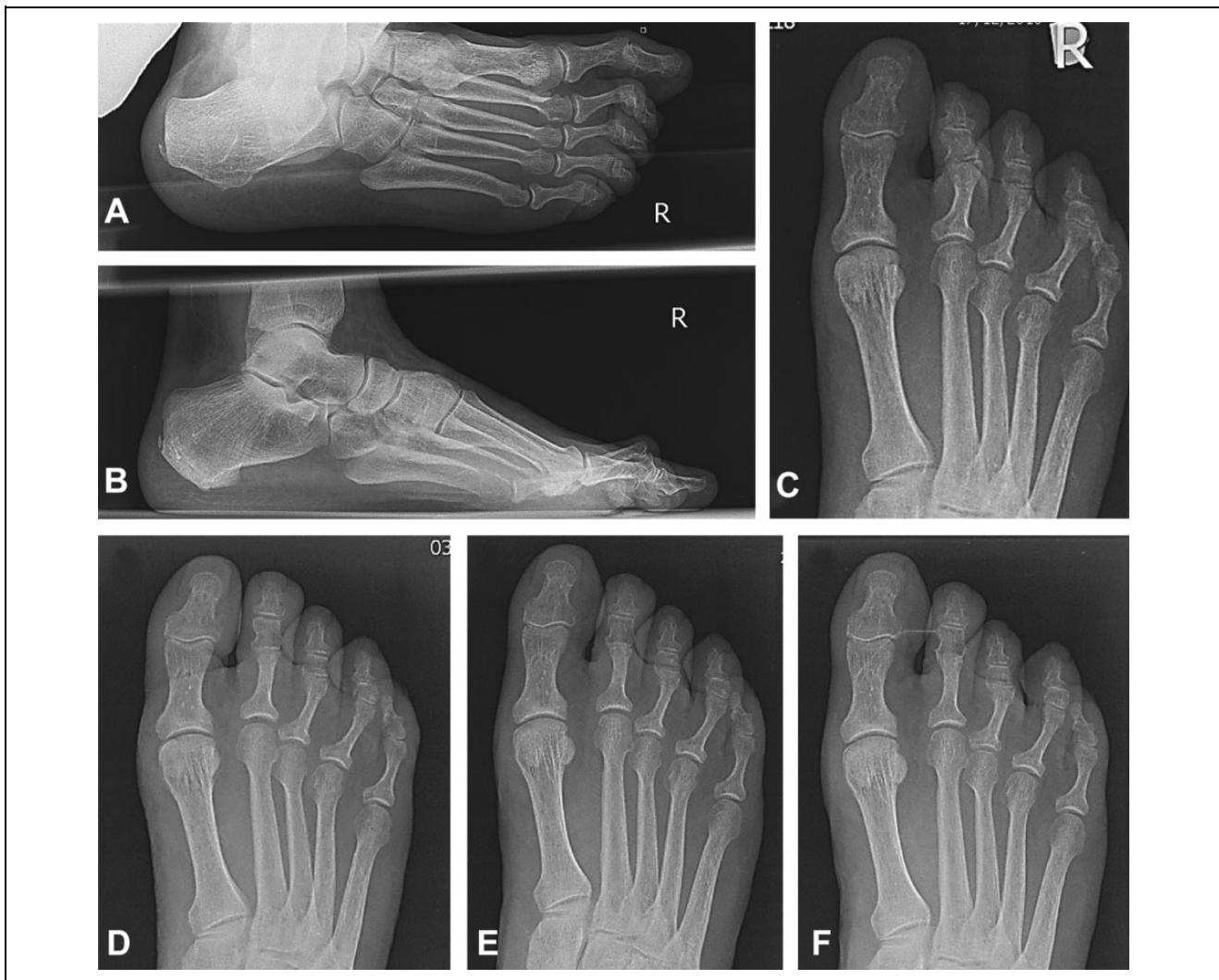

Figure 4. Weightbearing radiographs of a 68-year-old woman presenting with a hammertoe deformity of the second toe in the right foot. Preoperative radiographs: (A) lateral oblique, (B) lateral, and (C) dorsoplantar views. Postoperative radiographs at (D) 2 weeks, (E) 12 weeks, and (F) 26 weeks, demonstrating union.

end of the clinical investigation. The patient had not achieved bony fusion at 26 weeks.

Patient-Reported Outcome Measures

The mean pain VAS score improved from 5.3 ± 2.5 preoperatively to 0.4 ± 0.6 at 6 weeks and 0.5 ± 1.4 at 26 weeks (Figure 6). The protective shoe was discontinued at 6 weeks. A transient slight elevation in pain score was observed in 7 patients at the following visit and was not unexpected as patients returned to full normal activity.

The mean FAAM-ADL total score was 73.8 ± 19.4 preoperatively and improved to 93.3 ± 8.2 at 26 weeks postoperation (Table 3), with a mean change of 19.5 ± 19.0 points. One patient was instructed to keep wearing the postoperative shoe past the 12-week visit, and the FAAM-ADL was therefore not completed by this patient

at this visit. The FAAM-ADL percentage level of functioning also improved, from 69.4 ± 16.9 preoperatively to 93.8 ± 8.7 at 26 weeks, for a mean improvement of 24.4 ± 15.7 percentage points (Table 3).

All patients were either very satisfied (21/25; 84%) or satisfied (4/25; 16%) with the results of the procedure. Eighteen patients (72%) reported that their postoperative results greatly exceeded their expectations, 5 (20%) reported the results exceeded their expectation, and 2 (8%) reported the results matched their expectations. When asked about their ability to be more mobile, the surgery greatly exceeded, exceeded, or matched expectations for 10 (40%), 7 (28%), and 4 (16%) patients, respectively; 4 patients did not identify this as an expectation. Most patients were very likely (23/25; 92%) or likely (1/25; 4%) to choose this implant surgery again; 1 patient was somewhat likely to choose the surgery again.

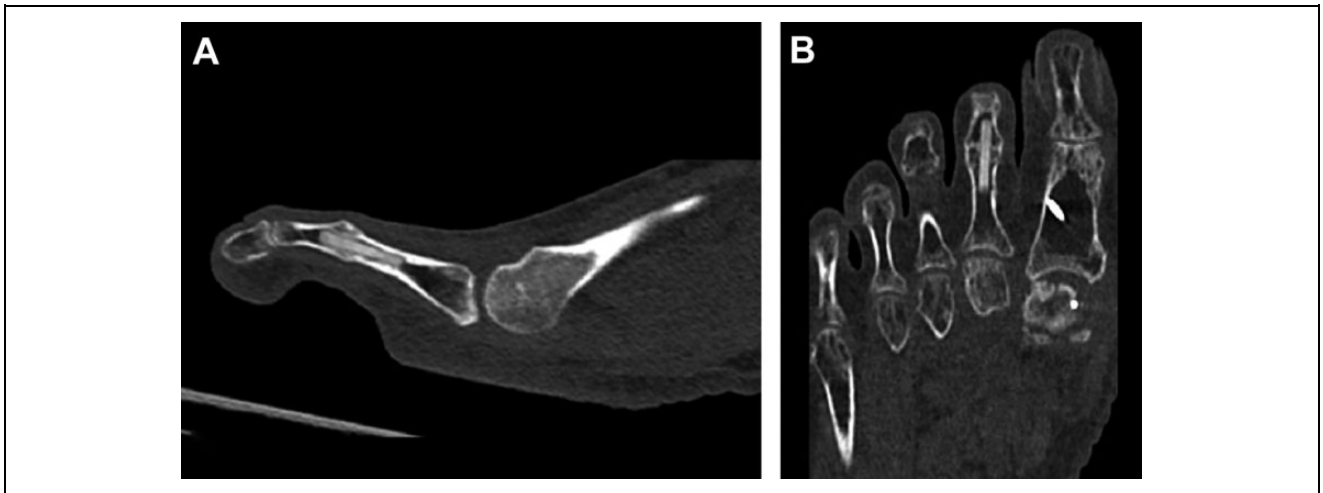


Figure 5. Postoperative computed tomographic scans of the second toe of a 59-year-old woman, at 26 weeks following proximal interphalangeal (PIP) joint arthrodesis, demonstrating union: (A) sagittal and (B) coronal axes.

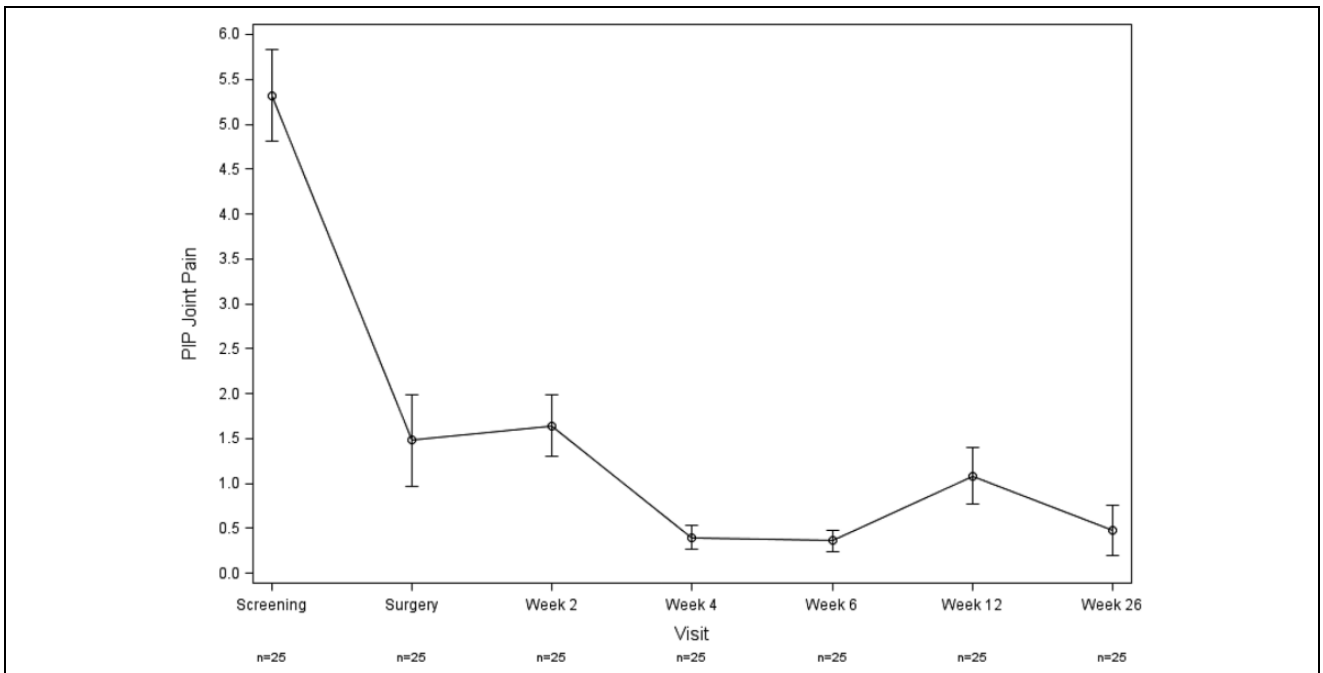


Figure 6. Pain visual analog scale (VAS) scores preoperatively and at weeks 2, 4, 6, 12, and 26 postoperative (n = 25).

Discussion

Use of a novel, biointegrative, fiber-reinforced implant for PIP joint correction arthrodesis in the treatment of hammertoe deformity was safe, with no serious adverse outcomes and an 88% fusion rate at 26 weeks postoperation. Patients reported substantial clinical improvements in pain and function, high satisfaction with the study device and procedure, and fulfilment of their expectations.

The radiographic fusion rate of 88% at 26 weeks' follow-up with the fiber-reinforced implant is consistent with the higher end of published fusion rates for other intramedullary

PIP joint implants.^{2,9,10,12,16-18,22,23,26,27,34,35,39-42,45} Three studies of absorbable intramedullary implants in PIP joint arthrodesis reported fusion rates of 79%,²⁶ 83%,²⁷ and 85%.⁴⁵ In 8 studies of intramedullary nitinol implants for PIP joint arthrodesis to correct hammertoe deformity, fusion rates ranged from 44%³⁴ to 100%,² and averaged around 79%.^{2,9,23,34,35,40-42} Reported fusion rates for 1-piece and 2-piece metal implants ranged from 22%³⁹ to 94%¹⁰ and averaged 74% in 647 toes across 7 studies.^{10,12,16-18,22,39} In studies evaluating the use of allograft bone matrix devices for PIP joint arthrodesis, reported radiographic fusion rates were 37%,³⁴ 96%,³¹ and 97%.²⁵

Table 3. FAAM-ADL Scores.

	Preoperative (n = 25)		Week 12 (n = 24)		Week 26 (n = 25)	
	Mean \pm SD	Median (Range)	Mean \pm SD	Median (Range)	Mean \pm SD	Median (Range)
FAAM-ADL Total score	73.8 \pm 19.4	76.2 (37.5, 100.0)	87.9 \pm 11.3	89.6 (67.1, 100.0)	93.3 \pm 8.2	97.5 (75.0, 100.0)
Change from preoperative	–	–	14.8 \pm 15.8	11.0 (–15.5, 48.8)	19.5 \pm 19.0	19.9 (–13.1, 52.0)
FAAM-ADL Level of functioning	69.4 \pm 16.9	70.0 (40.0, 100.0)	82.4 \pm 17.4	80.0 (30.0, 100.0)	93.8 \pm 8.7	95.0 (70.0, 100.0)
Change from preoperative	–	–	13.5 \pm 20.1	10.0 (–30.0, 50.0)	24.4 \pm 15.7	25.0 (0.0, 55.0)

Abbreviation: FAAM-ADL, Foot and Ankle Ability Measure and Activities of Daily Living subscale.

Reported fusion rates for K-wire fixation are somewhat inconsistent, ranging from 7%³⁹ to 93%¹¹ with an average of 61% in a total of 604 toes across 8 studies of correction of hammertoe deformity.^{2,11,13,22,29,34,39,42} It is important to note that complications of K-wire fixation include wire site infection, wire migration, and wire breakage,^{24,28,44,46} which are not a concern with other implants. Furthermore, the lack of rotational stability with K-wire fixation with only 1 wire can lead to malalignment, relapse of deformity, and a need for revision surgery.^{21,24}

The pain VAS mean score of 0.4 at the 26-week follow-up also compares well with studies of other implants.^{2,39} In a retrospective comparative study of PIP joint fusion for correction of hammertoe deformity, Richman et al³⁹ reported mean pain VAS scores of 1.7 and 1.8 at the 12-month follow-up for 1-piece implant (n=54) and K-wire (n=95) fixation, respectively. Angirasa et al² reported mean pain VAS scores of 0.33 following nitinol implant fixation and 1.6 following K-wire fixation for PIP joint arthrodesis to correct hammertoe deformity.

Patients in this study demonstrated good functional and clinical outcomes, with substantial improvements from preoperative evaluation to final follow-up. As the first study to obtain initial safety and performance data for this device, this study was not powered to determine statistical significance. Nevertheless, the observed changes from preoperative evaluation to 26 weeks surpassed established minimal clinically important differences (MCIDs) for both pain VAS and FAAM-ADL scores. Study patients achieved an approximately 90% reduction in pain VAS scores, where a reduction of $\geq 30\%$ has been considered clinically successful.⁵ The FAAM-ADL total score, which has an MCID of 8 points,⁵ improved a mean of 19.5 ± 19.0 points in this study.

The device demonstrated a good safety profile, with no complications, no serious adverse events, and no safety-related withdrawals from the study. Only 1 patient experienced delayed swelling around the device site, which resolved with an extended period of protective shoe wear.

Quiescent bio-integration is a major challenge for a non-permanent orthopedic fixation implant.^{6,36} The implant must be mechanically strong and robust enough to provide stable fixation, and yet be able to gradually integrate into the surrounding bone.³⁶ The biointegrative implant evaluated in this study is uniquely engineered of continuous reinforcing mineral fibers bound together by a bioabsorbable polymer PLDLA matrix to achieve high mechanical strength and gradual, progressive integration with the surrounding anatomy.⁶ Its mineral content is substantially higher than that of other bioabsorbable implants and is composed entirely of minerals found in native bone.⁷ Animal studies demonstrated the fixation performance of fiber-reinforced implants and fusion results to be comparable to standard stainless steel implants in a physiological load-bearing osteotomy fixation model.⁶ Furthermore, the implant demonstrated a gradual and progressive degradation profile through complete elimination at 104 weeks, with the absence of local or systemic adverse tissue response.⁶

The fiber-reinforced implant also provides safe and artifact-free imaging on radiographs, computed tomography, and magnetic resonance imaging. This newly introduced technology facilitates the use of a well-established operative technique while demonstrating high radiographic fusion rates, with no permanent implant material left behind. Thus, hardware removal procedures, which are quite common with some operative procedures, as well as pin site infection, pin migration, and pin breakage complications of K-wire fixation are avoided.

Limitations of this study include the small sample size and lack of a control group. Concomitant procedures at the great toe may have contributed slightly to the large improvements observed here, although patients were asked to complete the questionnaires based only on the operated hammertoe. Nevertheless, the prospective design of this trial is a strength, and the substantial improvements observed in patient-reported clinical outcome measures far surpassed the MCIDs of these measures.

Conclusion

This prospective, multicenter, first-in-human clinical trial of a novel, fiber-reinforced implant introduces a biointegrative alternative for PIP joint correction arthrodesis for treatment of hammertoe deformity. The implant demonstrated a favorable rate of fusion at 26 weeks, with no complications and substantial patient-reported improvements in pain and function.

Acknowledgments

The authors thank Dagmar Gross for assistance with preparation of this manuscript.

Ethics Approval

Ethical approval for this study was obtained from The National Medical Ethics Committee (NMEC) (Approval number: 0120-607/2017/8) in Slovenia; and Comité Autonómico de ética de la Investigación de Galicia (CAEI de Galicia) (Registration code: 2018/331) in Spain.

Declaration of Conflicting Interests

The author(s) declared the following potential conflicts of interest with respect to the research, authorship, and/or publication of this article: Luke D. Cicchinelli, DPM, reports personal fees from Ossio Ltd. (Israel), grants from Ossio Ltd. (Israel), during the conduct of the study. Juriž Štalc, MD, reports other from OSSIO Ltd. (Israel), during the conduct of the study. Martinus Richter, MD, PhD, and Stuart Miller, MD, report personal fees from OSSIO Ltd. (Israel), during the conduct of the study. ICMJE forms for all authors are available online.


Funding

The author(s) disclosed receipt of the following financial support for the research, authorship, and/or publication of this article: Financial support for this study was provided by OSSIO Ltd (Israel).

ORCID iD

Luke D. Cicchinelli, DPM,  <https://orcid.org/0000-0003-4143-9530>

Martinus Richter, MD, PhD,  <https://orcid.org/0000-0002-7934-6551>

Stuart Miller, MD,  <https://orcid.org/0000-0003-3525-1136>

References

1. Agna JW, Knowles HC Jr, Alverson G. The mineral content of normal human bone. *J Clin Invest.* 1958;37(10):1357-1361.
2. Angirasa AK, Barrett MJ, Silvester D. SmartToe(R) implant compared with Kirschner wire fixation for hammer digit corrective surgery: a review of 28 patients. *J Foot Ankle Surg.* 2012;51(6):711-713.
3. Averous C, Leider F, Rocher H, et al. Interphalangeal arthrodesis of the toe with a new radiolucent intramedullary implant (Toegrip). *Foot Ankle Spec.* 2015;8(6):520-524.
4. Badlissi F, Dunn JE, Link CL, et al. Foot musculoskeletal disorders, pain, and foot-related functional limitation in older persons. *J Am Geriatr Soc.* 2005;53(6):1029-1033.
5. Baumhauer JF, Singh D, Glazebrook M, et al. Prospective, randomized, multi-centered clinical trial assessing safety and efficacy of a synthetic cartilage implant versus first metatarsophalangeal arthrodesis in advanced hallux rigidus. *Foot Ankle Int.* 2016;37(5):457-469.
6. Berlet GC, Nyska M, Jackson ND. The bio-integration and bone fixation performance of continuous mineral fiber-reinforced implants. *Orthop Res Soc Transactions.* 2020;2020:334.
7. Buddhachat K, Klinhom S, Siengdee P, et al. Elemental analysis of bone, teeth, horn and antler in different animal species using non-invasive handheld x-ray fluorescence. *PLoS One.* 2016;11(5):e0155458.
8. Castiglioni S, Cazzaniga A, Albisetti W, Maier JA. Magnesium and osteoporosis: current state of knowledge and future research directions. *Nutrients.* 2013;5(8):3022-3033.
9. Catena F, Doty JF, Jastifer J, Coughlin MJ, Stevens F. Prospective study of hammertoe correction with an intramedullary implant. *Foot Ankle Int.* 2014;35(4):319-325.
10. Caterini R, Farsetti P, Tarantino U, Potenza V, Ippolito E. Arthrodesis of the toe joints with an intramedullary cannulated screw for correction of hammertoe deformity. *Foot Ankle Int.* 2004;25(4):256-261.
11. Ceccarini P, Rinonapoli G, Sebastiani E, et al. Clinical comparison between shortening osteotomy of the proximal phalanx neck and arthrodesis in hammer toe surgery at mid-term follow-up. *J Foot Ankle Surg.* 2019;58(2):221-225.
12. Coillard JY, Petri GJ, van Damme G, Deprez P, Laffenetre O. Stabilization of proximal interphalangeal joint in lesser toe deformities with an angulated intramedullary implant. *Foot Ankle Int.* 2014;35(4):401-407.
13. Coughlin MJ, Dorris J, Polk E. Operative repair of the fixed hammertoe deformity. *Foot Ankle Int.* 2000;21(2):94-104.
14. Doty JF, Fogleman JA. Treatment of rigid hammer-toe deformity: permanent versus removable implant selection. *Foot Ankle Clin.* 2018;23(1):91-101.
15. Dunn JE, Link CL, Felson DT, et al. Prevalence of foot and ankle conditions in a multiethnic community sample of older adults. *Am J Epidemiol.* 2004;159(5):491-498.
16. Ellington JK, Anderson RB, Davis WH, Cohen BE, Jones CP. Radiographic analysis of proximal interphalangeal joint arthrodesis with an intramedullary fusion device for lesser toe deformities. *Foot Ankle Int.* 2010;31(5):372-376.
17. Fazal MA, James L, Williams RL. StayFuse for proximal interphalangeal joint fusion. *Foot Ankle Int.* 2013;34(9):1274-1278.
18. Ferrier M, Mattei JC, Desmarchelier R, Fessy M, Besse JL. Radiographic and clinical comparison of proximal interphalangeal joint arthrodesis between a static and dynamic implant. *J Foot Ankle Surg.* 2019;58(4):657-662.
19. Frey-Ollivier S, Catena F, Helix-Giordanino M, Piclet-Legre B. Treatment of flexible lesser toe deformities. *Foot Ankle Clin.* 2018;23(1):69-90.
20. Frigg A, Zaugg S, Maquieira G, Pellegrino A. Stiffness and range of motion after minimally invasive Chevron-Akin and open Scarf-Akin procedures. *Foot Ankle Int.* 2019;40(5):515-525.

21. Guelfi M, Pantalone A, Cambiaso Daniel J, et al. Arthrodesis of proximal inter-phalangeal joint for hammertoe: intramedullary device options. *J Orthop Traumatol*. 2015;16(4):269-273.
22. Jay RM, Malay DS, Landsman AS, et al. Dual-component intramedullary implant versus Kirschner wire for proximal interphalangeal joint fusion: a randomized controlled clinical trial. *J Foot Ankle Surg*. 2016;55(4):697-708.
23. Khan F, Kimura S, Ahmad T, D'Souza D, D'Souza L. Use of Smart Toe((c)) implant for small toe arthrodesis: a smart concept? *Foot Ankle Surg*. 2015;21(2):108-112.
24. Klammer G, Baumann G, Moor BK, Farshad M, Espinosa N. Early complications and recurrence rates after Kirschner wire transfixion in lesser toe surgery: a prospective randomized study. *Foot Ankle Int*. 2012;33(2):105-112.
25. Kominsky SJ, Bermudez R, Bannerjee A. Using a bone allograft to fixate proximal interphalangeal joint arthrodesis. *Foot Ankle Spec*. 2013;6(2):132-136.
26. Konkel KF, Menger AG, Retzlaff SA. Hammer toe correction using an absorbable intramedullary pin. *Foot Ankle Int*. 2007; 28(8):916-920.
27. Konkel KF, Sover ER, Menger AG, Halberg JM. Hammer toe correction using an absorbable pin. *Foot Ankle Int*. 2011; 32(10):973-978.
28. Kramer WC, Parman M, Marks RM. Hammertoe correction with K-wire fixation. *Foot Ankle Int*. 2015;36(5):494-502.
29. Lamm BM, Ribeiro CE, Vlahovic TC, et al. Lesser proximal interphalangeal joint arthrodesis: a retrospective analysis of the peg-in-hole and end-to-end procedures. *J Am Podiatr Med Assoc*. 2001;91(7):331-336.
30. Martin RL, Irrgang JJ, Burdett RG, Conti SF, Van Swearingen JM. Evidence of validity for the Foot and Ankle Ability Measure (FAAM). *Foot Ankle Int*. 2005;26(11):968-983.
31. Miller SJ. Hammer toe correction by arthrodesis of the proximal interphalangeal joint using a cortical bone allograft pin. *J Am Podiatr Med Assoc*. 2002;92(10):563-569.
32. Moore KR, Howell MA, Saltrick KR, Catanzariti AR. Risk factors associated with nonunion after elective foot and ankle reconstruction: a case-control study. *J Foot Ankle Surg*. 2017; 56(3):457-462.
33. Nielson DL, Young NJ, Zelen CM. Absorbable fixation in forefoot surgery: a viable alternative to metallic hardware. *Clin Podiatr Med Surg*. 2013;30(3):283-293.
34. Obrador C, Losa-Iglesias M, Becerro-de-Bengoa-Vallejo R, Kabbash CA. Comparative study of intramedullary hammertoe fixation. *Foot Ankle Int*. 2018;39(4):415-425.
35. Payo-Ollero J, Casajus-Ortega A, Llombart-Blanco R, Villas C, Alfonso M. The efficacy of an intramedullary nitinol implant in the correction of claw toe or hammertoe deformities. *Arch Orthop Trauma Surg*. 2019;139(12):1681-1690.
36. Pietrzak WS, Sarver D, Verstynten M. Bioresorbable implants—practical considerations. *Bone*. 1996;19(1 suppl): 109s-119s.
37. Preiss-Bloom O, Poreh D, Merchav-Feurmann R, Lindner T. OSSIOfiber(TM) intelligent bone regeneration technology overview. OSSIO. Vol DOC000625. Woburn, MA: OSSIO Inc.; 2019.
38. Rammelt S, Panzner I, Mittlmeier T. Metatarsophalangeal joint fusion: why and how? *Foot Ankle Clin*. 2015;20(3):465-477.
39. Richman SH, Siqueira MB, McCullough KA, Berkowitz MJ. Correction of hammertoe deformity with novel intramedullary PIP fusion device versus K-wire fixation. *Foot Ankle Int*. 2017; 38(2):174-180.
40. Roukis TS. A 1-piece shape-metal nitinol intramedullary internal fixation device for arthrodesis of the proximal interphalangeal joint in neuropathic patients with diabetes. *Foot Ankle Spec*. 2009;2(3):130-134.
41. Sandhu JS, DeCarbo WT, Hofbauer MH. Digital arthrodesis with a one-piece memory nitinol intramedullary fixation device: a retrospective review. *Foot Ankle Spec*. 2013;6(5): 364-366.
42. Scholl A, McCarty J, Scholl D, Mar A. Smart toe(R) implant versus buried Kirschner wire for proximal interphalangeal joint arthrodesis: a comparative study. *J Foot Ankle Surg*. 2013; 52(5):580-583.
43. Shirzad K, Kiesau CD, DeOrio JK, Parekh SG. Lesser toe deformities. *J Am Acad Orthop Surg*. 2011;19(8):505-514.
44. Sullivan JP, Churchill CL. Digital arthrodesis of the lesser toes. *Clin Podiatr Med Surg*. 2017;34(3):289-300.
45. Wendelstein JA, Goger P, Bock P, et al. Bioabsorbable fixation screw for proximal interphalangeal arthrodesis of lesser toe deformities. *Foot Ankle Int*. 2017;38(9):1020-1025.
46. Zingas C, Katcherian DA, Wu KK. Kirschner wire breakage after surgery of the lesser toes. *Foot Ankle Int*. 1995;16(8): 504-509.