



Lessons for the clinical nephrologist: vascular access recirculation during continuous renal replacement therapy and regional citrate anticoagulation

Patricia Faria Scherer^{1,2} · Bruna Gomes Barbeiro³ · Adriano Luiz Ammirati^{1,3} · Bento Fortunato Cardoso dos Santos^{1,3} · Julio Cesar Martins Monte¹ · Marcelo Costa Batista^{1,4} · Marisa Petrucelli Doherty¹ · Oscar Fernando Pavão dos Santos^{1,4} · Thais Nemoto Matsui^{1,3} · Virgilio Pereira Gonçalves Jr¹ · Marcelino de Souza Durão Jr^{1,4,5}

Received: 18 June 2022 / Accepted: 28 July 2022

© The Author(s) under exclusive licence to Italian Society of Nephrology 2022

Keywords Regional citrate anticoagulation · AKI · CRRT · Recirculation · CVVHDF

The cases. Patient 1

Male, 57 years old, presented with SARS-CoV-2 pneumonia acute respiratory distress syndrome (ARDS) requiring invasive mechanical ventilation and extracorporeal membrane oxygenation (V-V ECMO). ECMO cannulas were inserted in the right internal jugular vein and right femoral vein. He developed KDIGO-3 acute kidney injury (AKI) and began continuous veno-venous hemodiafiltration (CVVHDF). The dialysis system was placed out of the ECMO circuit. The left femoral vein was the dialysis catheter site. Fifty-three days after starting CVVHDF, we observed a decrease in post-filter ionized calcium levels and systemic hypercalcemia. We also noticed decreased blood urea levels in the dialysis circuit and loss of dialysis efficiency, demonstrated by increased systemic urea levels and development of metabolic acidosis (laboratory and CVVHDF data are shown in Table 1). We temporarily reduced replacement of calcium

solution and citrate infusion. The hypothesis of recirculation was raised. Furthermore, we changed dialysis access. The tip of the removed catheter is shown in Fig. 1. The patient remained on CVVHDF for 66 days. After 60 days of ECMO, he underwent bilateral lung transplantation, but died in the perioperative period due to refractory shock and multiple organ dysfunction.

Patient 2

Male, 71 years old, presented respiratory failure due to COVID-19 and remained under invasive mechanical ventilation for 10 days. After initial improvement, he presented secondary bacterial pneumonia, new respiratory failure, septic shock, and KDIGO-3 AKI. He required V-V ECMO and was decannulated from ECMO after 18 days. CVVHDF was connected to a newly inserted catheter in the left femoral vein. Anticoagulation with heparin (for ECMO) and regional citrate anticoagulation protocol were used simultaneously. Again, we observed signs of access recirculation 33 days after starting CVVHDF, and we changed the dialysis catheter (laboratory parameters are shown in Table 1). The catheter tip was like the one in Fig. 1. He remained under invasive mechanical ventilation and CVVHDF for 58 days. After numerous infectious complications, the patient died of multiple organ dysfunction.

Patient 3

Male, 59 years old, presented with SARS-CoV-2 pneumonia and ARDS requiring lengthy invasive mechanical ventilation (57 days). He developed KDIGO-3 AKI, and after 7 days of

✉ Marcelino de Souza Durão Jr
marcelino.durao@unifesp.br

¹ Nephrology Division, Hospital Israelita Albert Einstein, São Paulo, Brazil

² Department of Critical Care Medicine, Hospital Israelita Albert Einstein, São Paulo, Brazil

³ Dialysis Center, Hospital Israelita Albert Einstein, São Paulo, Brazil

⁴ Nephrology Division, Escola Paulista de Medicina, Universidade Federal de São Paulo, São Paulo, Brazil

⁵ Kidney Transplant Unit, Hospital Israelita Albert Einstein, São Paulo, Brazil

Table 1 Laboratory and CVVHDF data

Days on CVVHDF	Patient 1					Patient 2					Patient 3							
	D 51	D 52	D 53	D 54	D 55	D 56	D 57	D 31	D 32	D 33	D 34	D 35	D 4	D 5	D 6	D 7	D 8	D 9
Laboratory data																		
Total systemic Ca (mg/dl)	9.2	9.6	11.6	10.1	8.2	8.3	8.4	8.3	7.9	10.1	10.6	9.7	8	9	10.6	11.5	8.3	7.4
Ionized systemic Ca (mmol/l)	1.17	1.24	1.82	1.36	1.13	1.11	1.05	1.08	1.11	1.51	1.28	1.18	1.12	1.16	1.35	1.53	1.06	1.02
Post-filter ionized Ca (mmol/l)	0.35	0.27	<0.2	0.22	0.26	0.23	0.43	0.36	<0.2	<0.2	0.41	0.35	0.29	0.22	<0.2	0.24	0.39	0.36
Total Ca / Ionized Ca	1.96	1.93	1.59	1.86	1.81	1.87	2	1.92	1.78	1.69	2.07	2.05	1.78	1.93	1.96	1.88	1.95	1.81
Plasma systemic urea (mg/dl)	43	69	132	168	133	109	66	43	52	75	117	65	62	78	83	98	71	54
Pre-filter urea (mg/dl)	42	45	32	56	38	47	60	43	31	22	109	64	62	55	39	29	70	54
Effluent urea (mg/dl)	42	43	32	51	35	43	60	43	31	22	107	64	58	55	37	25	63	46
pH	7.32	7.26	7.27	7.28	7.28	7.33	7.46	7.33	7.38	7.29	7.49	7.38	7.37	7.38	7.33	7.18	7.20	7.38
HCO ₃ (mEq/l)	23.7	26.2	21.4	19.9	19.5	21.5	27.3	24.2	24.2	21.1	19.1	27.4	33.4	32.7	30.2	26.4	27.0	27.1
Filter patency % *	100	96	100	91	92	91	100	100	100	100	98	100	93	100	95	86	90	85
CVVHF data																		
Blood (ml/min)	120	120	120	120	120	120	120	120	120	120	120	120	120	120	120	120	120	120
Dialysate (ml/min)	2000	2000	2000	3000	3000	3000	2000	2000	2000	2000	2000	2000	2500	2500	2500	2500	3000	3000
Replacement solution (ml/min)	600	600	600	600	600	600	600	600	600	600	600	600	800	800	800	700	800	800
Dialysis dose (ml/kg/h)	40	40	39	51	52	45	34	41	41	40	36	36	38	38	38	36	42	42
Ultrafiltration (ml/h)	300	320	180	220	300	270	200	150	150	150	120	120	270	270	270	230	260	200
Citrate (mmol/l)	4	4	2.5	2.5	2.5	2.5	4	3.5	3	2.5	4	4	4	3.5	3	3	3.5	4
Ca replacement (%)	100	100	0	30	30	50	100	80	80	65	95	95	85	90	100	75	75	75
Heparin	Full	Full	Full	Full	Full	Full	Full	Full	Full	Full	Full	Full	p	p	p	p	p	p
ECMO	Yes	Yes	Yes	Yes	Yes	Yes	Yes	Yes	Yes	Yes	Yes	Yes	No	No	No	No	No	No
Vascular access	LFV	LFV	LFV	LFV	LFV	Change	LFV	LFV	LFV	Change	RFV	RFV	LFV	LFV	LFV	Change	RFV	RJV

CVVHDF continuous venovenous hemodiafiltration, LFV left femoral vein, RFV right femoral vein, RJV right jugular vein; *Effluent urea/pre-filter urea ratio×100%; p prophylactic

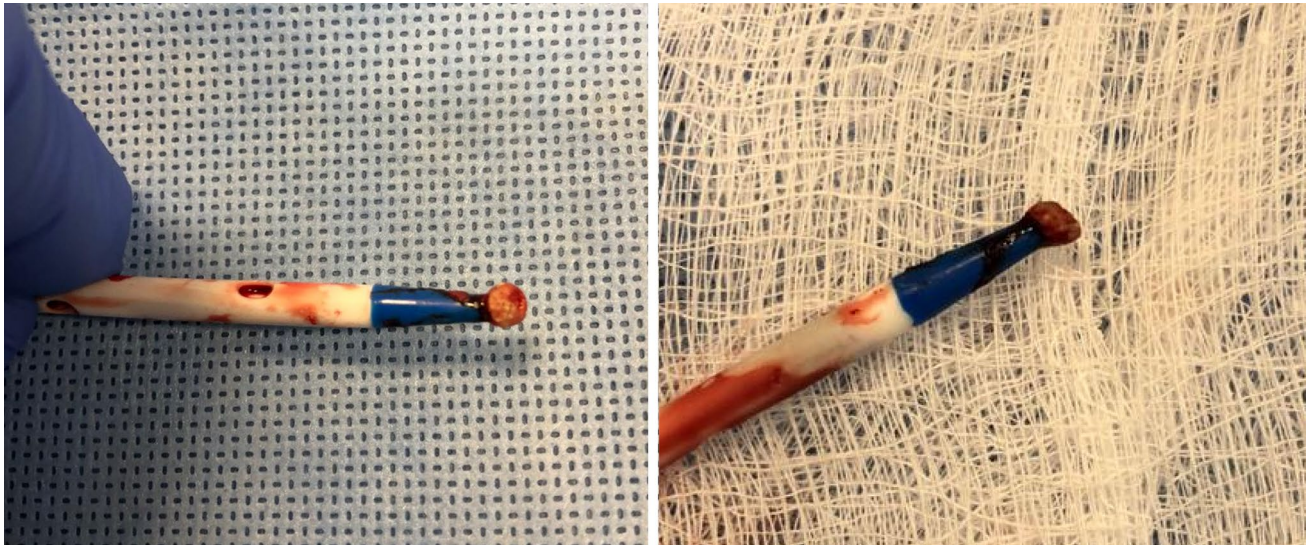


Fig. 1 Thrombus and calcification at the tip of the dialysis catheter

CVVHDF and regional citrate anticoagulation protocol, he presented some signs suggestive of recirculation, as occurred in the two previous cases. The catheter was removed from the left femoral vein and a new one was placed in the right internal jugular vein. The tip of the femoral catheter was also covered by thrombus and calcification. Laboratory data are shown in Table 1. He recovered kidney function after 76 days of dialysis therapy. He was discharged from hospital after 3 months of hospitalization. However, he was readmitted early due to sepsis from an abdominal source. He evolved with multiple organ dysfunction and died 22 days after hospital readmission.

Dialysis protocol

The initial dialysis protocol was previously described [1]. Briefly, we performed CVVHDF using the Prismaflex or Prisma machines, ST150 dialyzer, and AN69 membrane (Baxter Healthcare Corporation, IL, USA). Blood flow was 120 ml/min. Four percent trisodium citrate and calcium solution were infused into the arterial and third line of the dialysis catheter, respectively. The citrate and calcium infusion rates were set to maintain the post-filter and systemic ionized calcium concentration in the range of 0.25–0.30 mmol/l and 1.12–1.20 mmol/l, respectively. Formerly, a CaCl_2 solution (0.75% CaCl_2 ; 8 mg Ca/ml) was used. Since September 2021, with the acquisition of new machines equipped with a syringe pump for calcium infusion, we started using a 10% pure CaCl_2 solution, as suggested by the manufacturer. We began using the target citrate dose of 4 mmol/l of blood. The replacement solution was delivered post-filter. Filter patency was evaluated daily using the dialysate urea/pre-filter urea

ratio (Udial/Upre). Even when there was a clinical indication for systemic anticoagulation with unfractionated heparin, the citrate protocol was maintained.

Lessons for the clinical nephrologist

The proper functioning of the extracorporeal circuit is essential for metabolic control, correction of electrolyte disturbances, and acid–base balance in patients on continuous dialysis (CRRT). Ineffective anticoagulation and vascular access dysfunction compromise the efficiency of dialysis treatment. Regional citrate anticoagulation has become the preferred anticoagulation modality for CRRT. Recirculation does not appear to be a common problem in CRRT (Box 1).

Recirculation, a fraction of blood coming from the dialyzer that is repeatedly passed through the dialyzer membrane, is not commonly detected in patients undergoing CRRT and regional citrate anticoagulation. In our patients, during recirculation, we noticed a local overload of citrate indicated by the decrease in ionized calcium levels within the circuit, sometimes below the lower level of detection (Table 1). Systemic hypercalcemia occurred due to the reduced blood flow coming from circulation in the dialysis circuit caused by the recirculation. Thus, we reduced the citrate infusion rate and replacement of calcium, respectively, until the problem was identified. The total calcium total/ionized calcium ratio remained unchanged, indicating that the accumulation of citrate was only local without a systemic effect. There was also, due to recirculation, a reduction in the levels of urea in the blood of the circuit. Concurrently, the efficiency of dialysis decreased, leading to increased levels of systemic urea and metabolic acidosis, the latter

also determined by the decrease in the systemic delivery of citrate and non-generation of bicarbonate. Two similar cases during CRRT and regional citrate anticoagulation have been described in the literature. The first case was described in a child during the reversal of arterial and venous lines of the dialysis catheter placed in the femoral vein [2]. The second case involved an adult patient when a venous thrombosis was observed close to the tip of the catheter placed in the right femoral vein [3]. In our three patients, when the catheters were changed, we identified the presence of calcified material at the tip of the catheters (Fig. 1). After changing the catheters, disturbances in calcium levels decreased and the efficiency of dialysis was restored.

Our three patients had COVID-19 and two of them (patients 1 and 2) were hospitalized for a long time, using V-V ECMO and multiple vascular accesses. Patients with COVID-19 have coagulation derangement suggesting a hypercoagulable state. The incidence of venous thromboembolic episodes in critically ill COVID-19 patients appears to be higher than historical rates, even under standard prophylaxis. The alterations observed in the coagulation tests seem to result from the intense inflammatory response triggered by the viral infection [4]. A study showed deep vein thrombosis and pulmonary embolism in 19.8% and 18.9% of patients, respectively [5]. Other authors detected dysfunction of venous catheters and early coagulation of extracorporeal circuits [6]. One study showed coagulation of the dialysis circuit in 96% of patients undergoing renal replacement therapy. The average duration of continuous dialysis circuits was 36 h [7].

It does not seem to us that COVID-19 hypercoagulability was the main factor involved in the formation of calcification/thrombus at the tip of catheters. Previously and at the moment when we detected recirculation, the filters presented good performance as can be verified by the values of the U_{dial}/U_{pre} ratio, an indicator of the patency of the filters. In addition, two patients also received a full dose of intravenous unfractionated heparin. RCA seems to work well, even in patients with COVID-19. We recently demonstrated in a cohort of patients with COVID-19 and AKI on CVVHDF that the mean filter life was 80 h and that early clotting of the dialysis circuit (< 72 h) occurred in only 22% of the filters used [8].

Other important issues related to recirculation are the implantation site, the type of catheter, the blood flow used, and the positioning of the catheter tip. The right internal jugular vein is the preferred site when there are no contraindications or urgencies. It allows direct access to the superior vena cava system and the catheter tip must be kept in the transition between the superior vena cava and the right atrium [9]. If the right jugular vein cannot be used, the second option for placing the dialysis access is the

femoral veins or the left jugular vein. Femoral access is used in patients with severe respiratory failure, on mechanical ventilation, and in those with high airway pressures. The right side anatomically has a more direct access to the inferior vena cava and seems to provide a longer lifespan of the CRRT circuit when compared to the left side. When using femoral access, a longer catheter is usually required so that the tip remains in the central lumen of the inferior vena cava. Cannulation of subclavian veins should not be performed because of the increased risk of thrombosis, venous stenosis and pneumothorax.

In this report, the three patients had catheters in the left femoral vein. The long-term use of catheter (patients 1 and 2) could have contributed to the occurrence of thrombus formation and crystallization, but we observed the same problem after only one week of catheter use in the third individual. We have been using CVVHDF with regional citrate anticoagulation and calcium diluted solution replacement infusion in the third line of the catheter since 2000. It was the first time that we observed the occurrence of this phenomenon, and this happened after the change to the concentrated Ca solution. Considering the findings, we hypothesize that the use of concentrated CaCl₂ (10%) seems to have induced calcium crystallization and thrombus formation at the tip of the dialysis catheter. Next, we diluted the replacement Ca solution, and since then we have not observed any new cases of crystallization and recirculation. We need additional data to define which maximum concentration of Ca solution could be safely used in the regional citrate anticoagulation protocol in critically ill patients undergoing CVVHDF.

Box 1: When to suspect vascular access recirculation during CRRT with RCA

- Decreased ionized Ca within the circuit (post-filter)
 - Increased systemic Ca (total and ionized Ca)
 - Unchanged systemic total Ca/ionized Ca ratio
 - Decreased urea in blood circuit
 - Increased systemic urea
 - Metabolic acidosis

Risk conditions for the development of recirculation during CRRT: line reversal of dialysis circuit, short femoral catheter, vein/catheter thrombosis

CRRT continuous renal replacement therapy, RCA regional citrate anticoagulation

Funding The authors did not receive any funding.

Declarations

Conflict of interest On behalf of all authors, the corresponding author states that there is no conflict of interest.

Ethical statement The case report for this “lessons for the clinical nephrologist” paper was approved by the local Ethics Committee (CAAE 4705152150000071).

References

1. Durão MS, Monte JC, Batista MC, Oliveira M, Iizuka IJ, Santos BF, Pereira VG, Cendoroglo M, Santos OF (2008) The use of regional citrate anticoagulation for continuous venovenous hemodiafiltration in acute kidney injury. *Crit Care Med* 36(11):3024–3029
2. Chenouard A, Liet JM (2017) Regional citrate anticoagulation: beware of recirculation phenomenon. *Ther Apher Dial* 21:206–207
3. Degraeve A, Danse E, Laterre PF, Hantson P, Werion A (2019) Regional citrate anticoagulation and influence of recirculation on ionized calcium levels in the circuit. *J Artif Organs* 22(4):341–344
4. Connors JM, Levy JH (2020) COVID-19 and its implications for thrombosis and anticoagulation. *Blood* 135(23):2033–2040
5. Di Minno A, Ambrosino P, Calcaterra I, Di Minno MND (2020) Covid-19 and venous thromboembolism: a meta-analysis of literature studies. *Semin Thromb Hemost* 46:763–771
6. Gupta A, Madhavan MV, Sehgal K, Nair N, Mahajan S et al (2020) Extrapulmonary manifestations of COVID-19. *Nat Med* 26:1017–1032
7. Helms J et al (2020) High risk of thrombosis in patients with severe SARS-CoV-2 infection: a multicenter prospective cohort study. *Intensive Care Med* 46(6):1089–1098
8. Dohér MP, Torres de Carvalho FR, Scherer PF, Matsui TN, Ammirati AL, Caldin da Silva B, Barbeiro BG, Carneiro FD, Corrêa TD, Ferraz LJR, Dos Santos BFC, Pereira VG, Batista MC, Monte JCM, Santos OFP, Bellomo R, Serpa Neto A, Durão MS (2021) Acute kidney injury and renal replacement therapy in critically ill COVID-19 patients: risk factors and outcomes: a single-center experience in Brazil. *Blood Purif* 50(4–5):520–530
9. KDIGO clinical practice guideline for acute kidney injury (2012) *Kidney Int Suppl* 2:1

Publisher's Note Springer Nature remains neutral with regard to jurisdictional claims in published maps and institutional affiliations.