

Received: 2022.05.11
Accepted: 2022.07.28
Available online: 2022.08.24
Published: 2022.09.25

Use of a Modified ABTHERA ADVANCE™ Open Abdomen Dressing with Intrathoracic Negative-Pressure Therapy for Temporary Chest Closure After Damage Control Thoracotomy

Authors' Contribution:
Study Design A
Data Collection B
Statistical Analysis C
Data Interpretation D
Manuscript Preparation E
Literature Search F
Funds Collection G

ABCDEF 1 **Luis G. Fernandez**
ACDEF 1 **Scott H. Norwood**
ABEF 2 **Carolina Orsi**
ABF 2 **Marvin Heck**
ABEF 3 **Katherine Gonzalez** 
AB 1 **Natalie Williams**
ACDEF 4 **Marc R. Matthews**
ACDE 5 **Thomas M. Scalea**
EF 6 **Rebecca Swindall**

1 Department of Surgery, UT Health East Texas, Tyler, TX, USA
2 Department of Surgery, University of Texas Health Science Center, Tyler, TX, USA
3 School of Medicine, The University of Texas Medical Branch, Galveston, TX, USA
4 Burn Emergency Services, Respiratory Care Services, Arizona Burn Center, Maricopa Medical Center, University of Arizona College of Medicine, Phoenix, AZ, USA
5 University of Maryland School of Medicine, University of Maryland Medical Center, Baltimore, MD, USA
6 Department of Epidemiology and Biostatistics, University of Texas Health Science Center, Tyler, TX, USA

Corresponding Author: Luis Fernandez, e-mail: luis.fernandez@uthct.edu
Financial support: None declared
Conflict of interest: None declared

Case series

Patient: Male, 33-year-old • Male, 51-year-old
Final Diagnosis: Cardio thoracic trauma
Symptoms: Hemorrhagic shock
Medication: —
Clinical Procedure: Intrathoracic negative pressure therapy • thoracotomy
Specialty: Biotechnology • Cardiac Surgery • Critical Care Medicine • Surgery

Objective: Unusual clinical course

Background: Damage control surgery (DCS) is an established emergency operative concept, initially described and most often utilized in abdominal trauma. DCS prioritizes managing acute hemorrhage and contamination, leaving the abdominal wall fascia open and covering the existing wound with a temporary abdominal wall closure, most commonly negative-pressure wound therapy (NPWT). The patient undergoes aggressive resuscitation to optimize physiology. Once achieved, the patient is returned to the operating room for definitive surgical intervention. There is limited evidence suggesting that using damage control thoracotomy within the chest cavity improves mortality and morbidity rates. Our review failed to find a case in which NPWT using ABTHERA ADVANCE™ Open Abdomen Dressing has been successfully used in the setting of thoracic trauma.





Case Reports: This case series describes 2 examples of NPWT as a form of temporary chest closure in penetrating and blunt thoracic injury. The first case was a penetrating self-inflicted stab wound to the chest. The NPWT was applied as a form of temporary thoracotomy, closure at the index surgery. The second case was a blunt injury to the chest of a polytrauma patient following a motor vehicle accident. The patient sustained rib fractures on his left side and had a bilateral pneumothorax. An emergent thoracotomy was performed due to delayed intrathoracic bleeding noted on hospital day 11, and NPWT was applied as described above, in the first case.

Conclusions: These cases suggest that damage control thoracotomy with intrathoracic placement of a modified ABTHERA ADVANCE™ Open Abdomen Dressing negative-pressure system may be an effective and life-saving technique with the potential for positive outcomes in these high-risk patients.

Keywords: Negative-Pressure Wound Therapy • Thoracic Injuries • Trauma Centers

Full-text PDF: <https://www.amjcaserep.com/abstract/index/idArt/937207>



 2241  —  10  16

Background

Damage control surgery (DCS) is a widely established technique in trauma surgery, with the main goals of managing hemorrhagic shock and controlling gross contamination in an abbreviated surgical procedure. [1] After establishing control of the life/limb-threatening issues, the patient undergoes temporary abdominal closure (TAC) and undergoes continued resuscitation to a more optimal physiologic state in the intensive care unit (ICU) setting prior to a definitive procedure and closure [1-4]. Although this technique is thoroughly accepted in traumatic abdominal surgery, however there are limited studies regarding the effectiveness of NPWT in damage control thoracotomy (DCT) [5,6].

A generally accepted indication for DCS in thoracic trauma includes cardiorespiratory arrest following isolated penetrating thoracic trauma with evidence of signs of life [6-9]. Other indications for DCT include post-traumatic persistent hypotension due to intrathoracic hemorrhage and/or evidence of air embolism or pericardial tamponade [5-9]. Signs of life are defined by the American College of Surgeons Committee on Trauma as presence of pupillary response, spontaneous ventilation, presence of carotid pulse, measurable/palpable blood pressure, extremity movement, and/or cardiac electrical activity [10].

In addition to controlling hemorrhage and contamination, DCT can also be used for traumatic thoracic injuries, releasing pericardial tamponade, controlling bronchopulmonary fistula, and gaining access to permit the use of cardiac massage to improve cardiac output and organ perfusion [11]. If the patient survives the DCT, it is vital to quickly correct the lethal triad of hypothermia, acidosis, and coagulopathy to promote better outcome for the patient [12].

We report on 2 examples of the successful use of DCT with application of negative-pressure wound therapy (NPWT) utilizing the ABTHERA ADVANCE™ Open Abdomen Dressing as a form of temporary thoracotomy closure (TTC) in penetrating and blunt thoracic injury (Figure 1). For these patients, laparotomy packing and NPWT was used for temporary damage control, which ultimately led to positive outcomes and survival. Although the best method for utilizing DCT has yet to be established [5-9], these cases describe how vacuum-assisted thoracic closure was used as an effective technique in damage control thoracic surgery. Patient consent was obtained at time of treatment.

Modified ABTHERA ADVANCE Temporary Thoracic Closure Technique (AA-TTC)

In both cases presented, an ABTHERA ADVANCE™ Open Abdomen Dressing was used to achieve TTC. A step-by-step description of the technique is provided below and the correct procedural sequence was found to perform a successful AA-TTC.

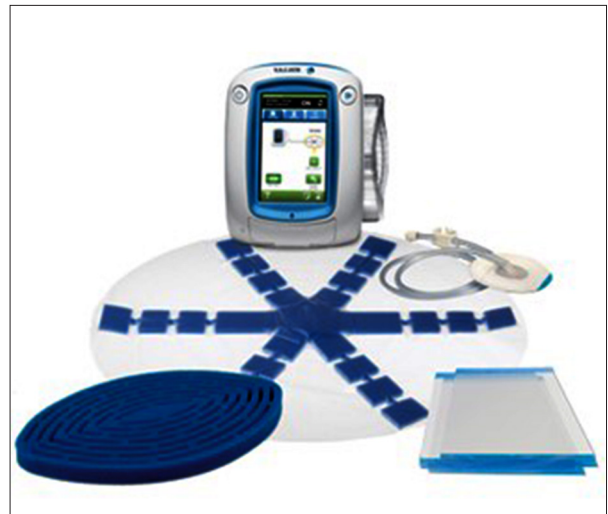

Figure 1. ABTHERA ADVANCE™ Open Abdomen Dressing, negative-pressure wound therapy system.

Technical Steps:

1. All surgical bleeding must be quickly and effectively controlled.
2. Apply large sheets of oxidized cellulose over the controlled bleeding areas or areas of generalized oozing, as needed (eg, SURGICEL® NU-KNIT Absorbable Hemostat or another non-exothermic agent).
3. The ABTHERA ADVANCE™ Fenestrated Visceral Protective Layer (VPL) is cut to fit and applied within the chest cavity, being careful to cover the area of injury and all adjacent organs. This is placed over the oxidized cellulose layer.
4. A 32-French right-angle pericardial tube and 32-French thoracostomy tube is placed within the thoracic cavity as needed.
5. Sterile laparotomy packs are added as needed.
6. ABTHERA ADVANCE™ Perforated Foam is applied over the sterile laparotomy packs.
7. The polyvinyl adhesive sheets, provided in the ABTHERA ADVANCE™ Open Abdomen Dressing kit, are applied to seal the AA-TTC dressing.
8. A 2- to 3-cm perforation is made in the polyvinyl adhesive sheet and the SENSAT.R.A.C.™ pressure delivery system is applied and adhered over the perforation.
9. The SENSAT.R.A.C.™ pressure delivery system is attached to a compatible V.A.C.® Therapy Unit and set to an initial negative pressure (NP) of 35 mmHg. The NP settings may be adjusted as needed based on observed blood/fluid output.

Case Reports

Case 1

The patient was a 33-year-old man who presented to the Emergency Department after multiple self-inflicted stab wounds

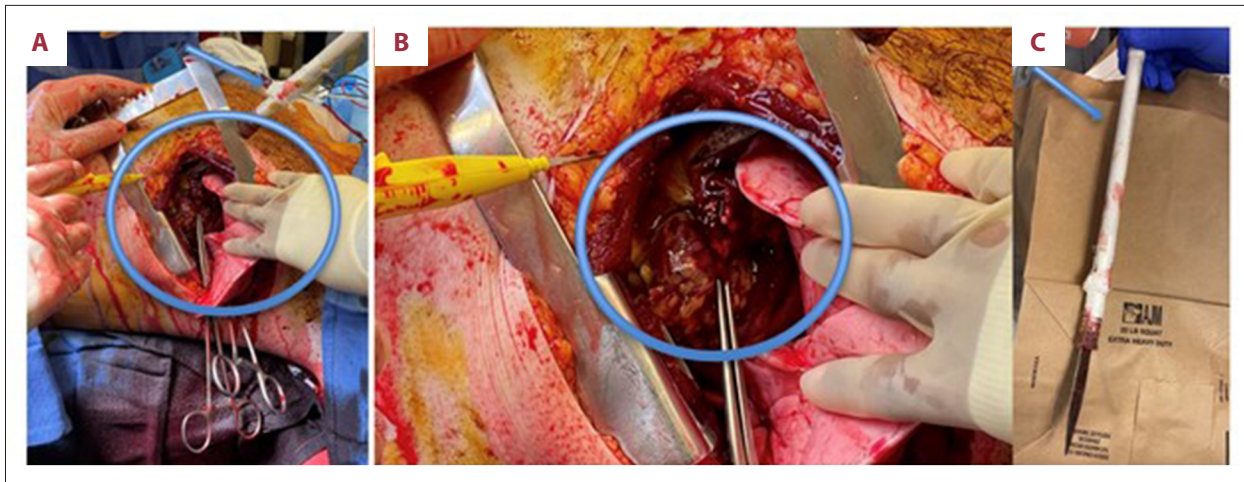


Figure 2. (A, B) Penetrating self-inflicted, stab wound to the chest with cardiac laceration (circle), (A, C) improvised “shank” (arrow).

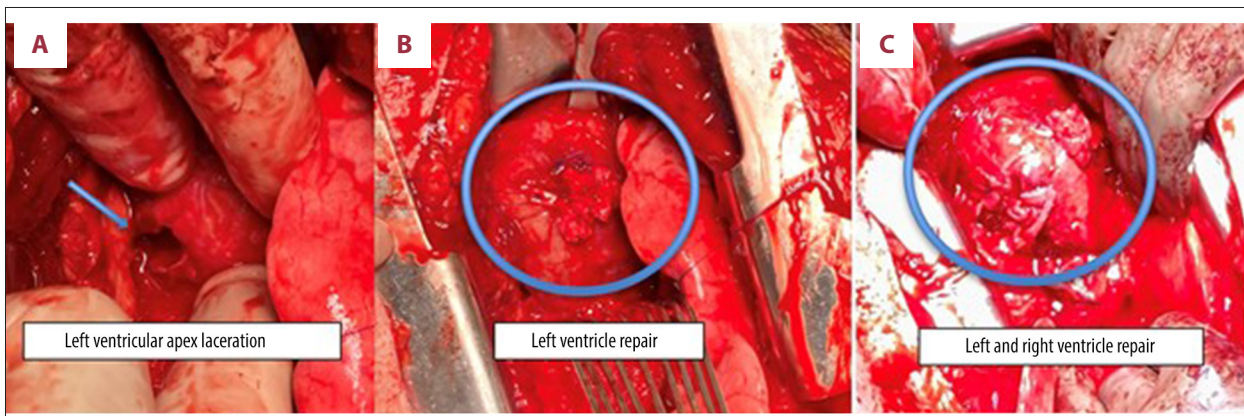


Figure 3. (A) Left ventricular apex laceration (arrow), (B, C) operative repair of left and right ventricle lacerations (circle).

to the chest. The patient was combative and confused at the scene, with a knife through the left side of his chest, just lateral to his sternum (**Figure 2A-2C**). The patient was tachypneic, hypotensive (87/70 mmHg), tachycardiac (126 beats/min), with distended neck veins, muffled heart tones (Becks’ triad), with absent breath sounds to auscultation to the left chest. The patient had an Injury Severity Score and an Abbreviated Injury Score of 25 and 5, respectively. He was intubated upon arrival and taken to the operating room for an emergent thoracotomy.

A left lateral thoracotomy at the fifth intercostal space was performed. Six lacerations to the apex of the right and left ventricle were found. There was also a contusion to the left lower lobe of the lung. A longitudinal pericardiotomy was performed to release the cardiac tamponade. The cardiac lacerations on the right and left ventricular apex were repaired with 3-0 pledged proline sutures (see **Figure 3A-3C**). The left hemithorax and heart were irrigated with 3 liters of hypochlorous acid solution. The heart was wrapped in SURGICEL NU-KNIT® Absorbable Hemostat to mitigate continued oozing from the cardiac repair (**Figure 4**).

The DCT was complete. At this time, we decided to use the modified TTC-NPWT technique to keep the left anterolateral thoracotomy incision open. A 32-French right-angle pericardial tube was placed within the anterior mediastinum and a standard 32-French thoracostomy tube was placed in the left thoracic cavity. The ABTHERA ADVANCE™ Fenestrated VPL was cut to fit and applied to the heart and lungs. Three sterile laparotomy packs were added and ABTHERA ADVANCE™ Perforated Foam was applied to negative 35 mmHg pressure (**Figure 5A, 5B**).

During the operation, 21 units of packed red blood cells (PRBC), 2 units of platelets, 4 units of cryoprecipitate, 16 units of fresh frozen platelets, 1 liter of 0.9 normal saline, and 250 cc of sodium bicarbonate were administered intravenously. The patient received a total of 23 units of PRBC, 2 units of platelets, and 18 units of fresh frozen plasma in the first 24 h.

The patient became febrile (39°C) and hypotensive during the first night after the DCT. He was given an additional 2 units of fresh frozen plasma and a chest X-ray was performed, which showed left lower-lobe consolidation. A computed tomography

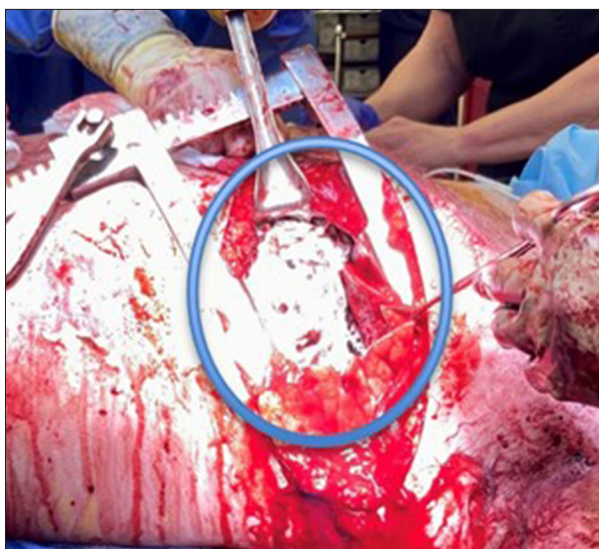


Figure 4. The heart wrapped with SURGICEL NU-KNIT® Absorbable Hemostat dressing (circle).

(CT) scan of the chest with intravenous contrast showed no active cardiac bleeding and transesophageal echo demonstrated no cardiac structural anomalies. The patient had an estimated ejection fraction of 65%. On post-operative day (POD) 2, a second-look thoracotomy was performed. The right and left ventricular apex laceration repairs were intact and the left hemidiaphragm and lung parenchyma had no further injuries noted. Primary closure of left lateral thoracotomy incision was completed along with the placement of a 3M™ Prevena™ Peel

and Place Dressing negative-pressure system over the incision (**Figure 6A-6D**).

Complications after the second-look thoracotomy included thrombocytopenia, anemia due to blood loss, and continued difficulty with moving the right upper extremity. On POD 7 the patient was weaned from the ventilator, extubated, and the pericardial tube was removed. The left thoracostomy tube was left in place on water seal. The patient was transferred in stable condition to the University of Texas Medical Branch in Galveston for his remaining recovery on POD 9. His thoracostomy tube was removed on POD 13 (**Figure 7**) and his neurologic examination continued to improve. The patient had no further complications reported, the thoracotomy incision was healing well, and he was subsequently discharged to a rehabilitation facility.

Case 2

A 51-year-old man with past medical history of substance abuse, yet negative for other comorbidities, was transferred from an outside hospital after suffering polytrauma from a motor vehicle accident. His injuries included left rib fractures and bilateral pneumothorax, which were managed with bilateral tube thoracostomies. On hospital day (HD) 11, the left tube thoracostomy had increased bloody output and the patient clinically decompensated, rapidly becoming tachycardic and severely hypotensive (systolic blood pressure of 40 mmHg). The patient was taken to the operating room for an emergent left thoracotomy.

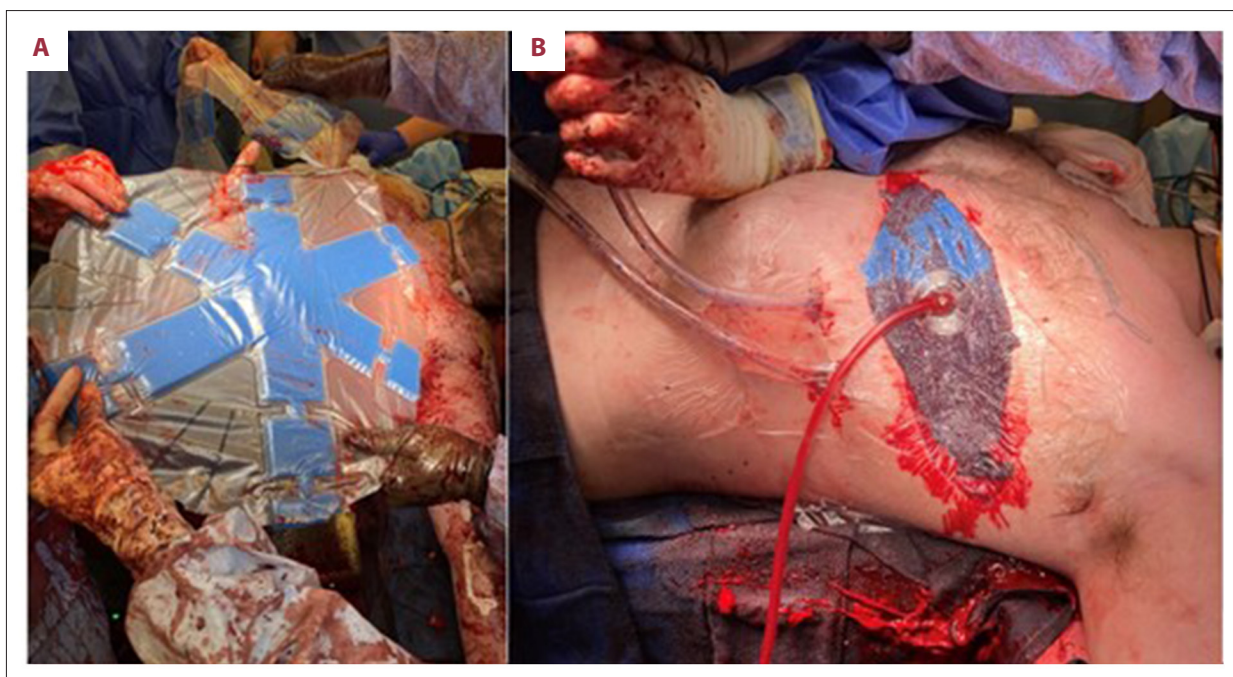


Figure 5. (A) Placement of the modified ABTHERA ADVANCE™ Open Abdomen Dressing, (B) left thoracostomy tubes for temporary chest closure.

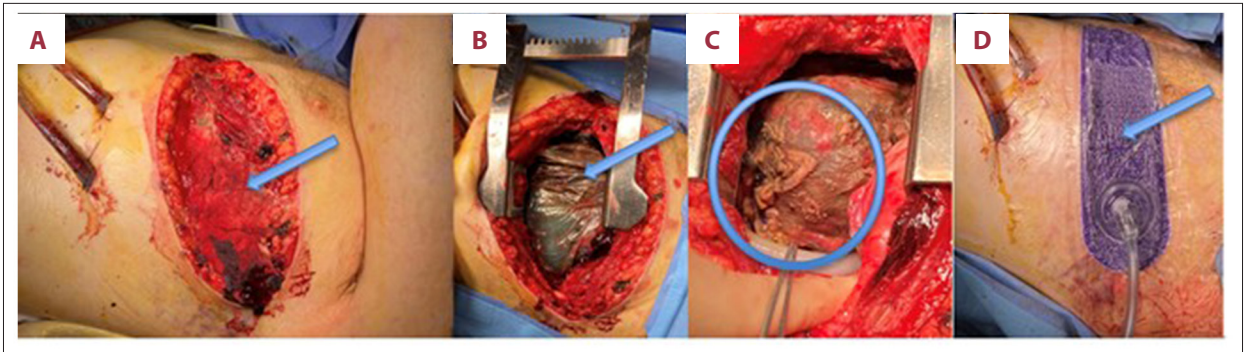


Figure 6. Second-look thoracotomy. (A) Laparotomy packs (arrow), (B) Visceral Protective Layer (arrow), (C) intact cardiac repair (circle), (D) 3M™ Prevena™ Peel and Place Dressing (arrow).

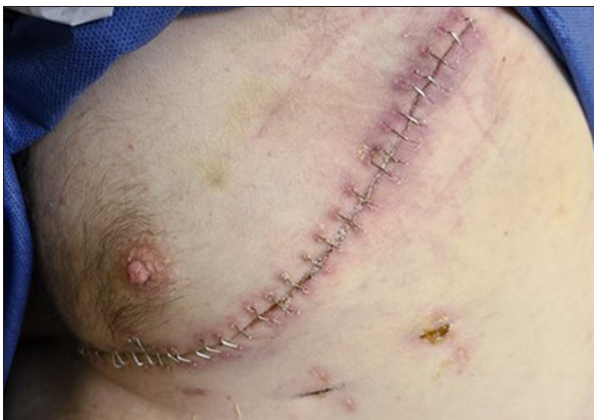

Figure 7. Post-operative left thoracotomy incision.

A left lateral thoracotomy was performed through the fifth intercostal space. Upon entry into the chest, approximately 2 liters of clotted blood was encountered (Figure 8A). The chest was packed starting at the apex. Additional laparotomy packs were then placed laterally, posteriorly, and medially. The rib fracture sites were identified but there was no active bleeding. The chest was irrigated with hypochlorous acid solution and the laparotomy packs were systematically removed starting at the apex, then laterally, medially, and posteriorly. A search was made for a suspected intercostal artery as the source of the hemorrhage and the entire contents of the left hemithorax, heart, and mediastinum were inspected, but no obvious injury or active source of bleeding could be found.

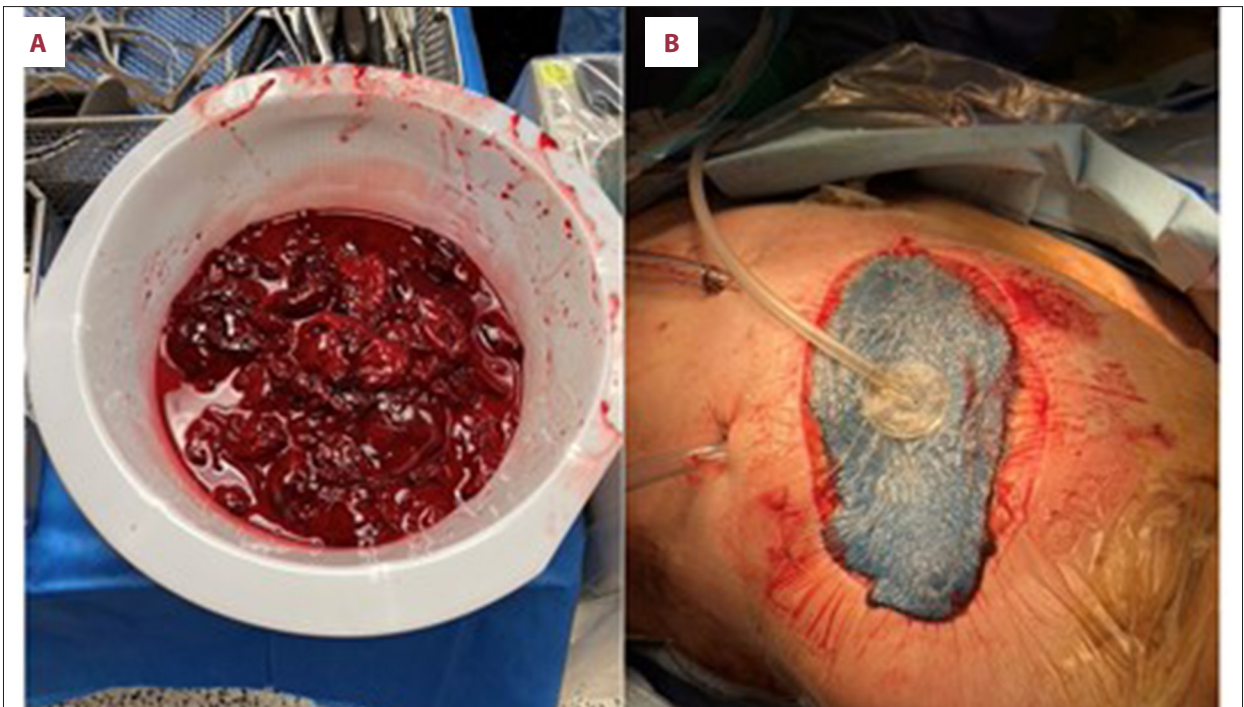


Figure 8. (A) Upon entry into the chest approximately 2 liters of clotted blood was encountered. (B) Modified ABThera Advance™ Open Abdomen Dressing and left thoracotomy tubes placed for temporary chest closure.

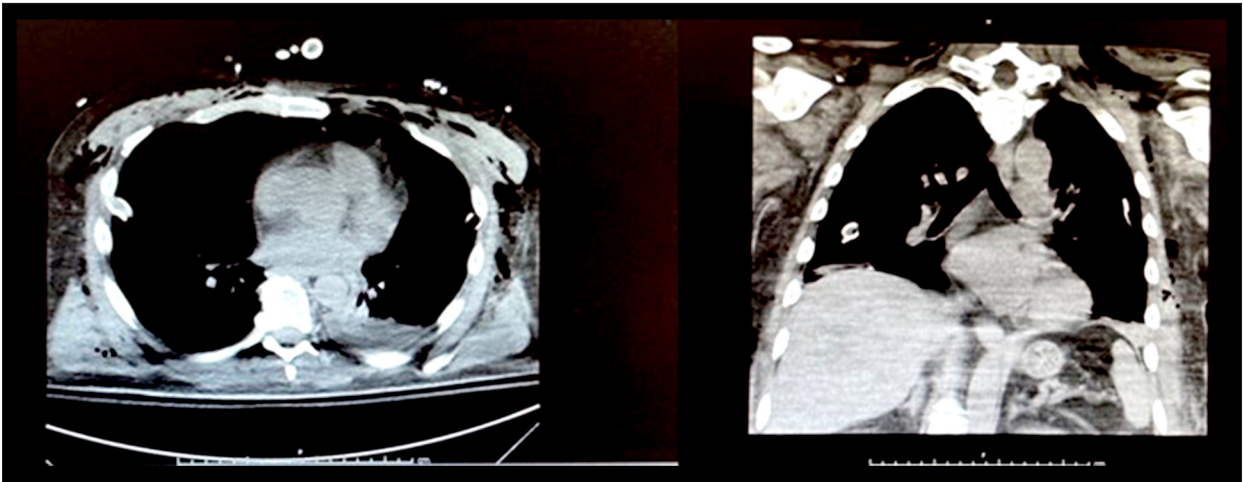


Figure 9. Post-operative CT angiogram of the chest was performed 24 hours after negative-pressure wound therapy and damage control therapy revealed no active arterial extravasation.

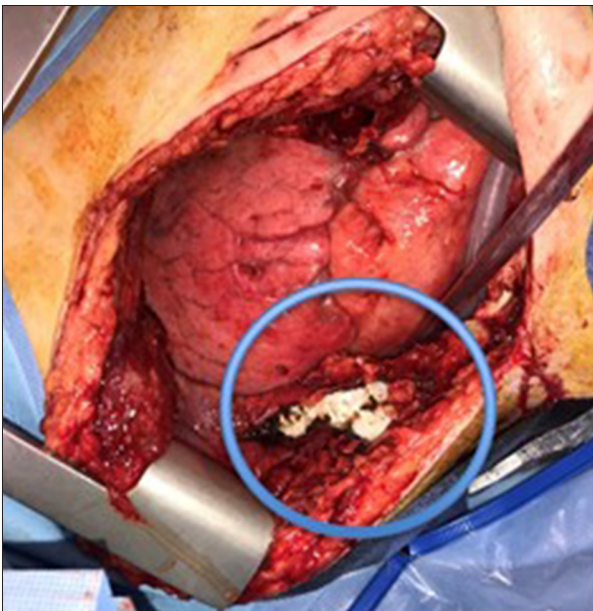


Figure 10. An intercostal artery at the left fourth rib fracture was noted to have active bleeding. This was ligated and packed with oxidized cellulose (circle).

The decision was made to use the modified TTC-NPWT technique to temporarily close the chest to return for re-exploration after further resuscitation. Two 32-French chest tubes were positioned posteriorly and anteriorly. A modified ABTHERA vacuum-assisted wound closure device was positioned over the entire left lung. Four laparotomy packs were placed over the device and ABTHERA ADVANCE™ Perforated Foam was applied to negative 35 mmHg pressure (**Figure 8B**).

The patient was resuscitated in the ICU over 48 h. He received 4 units of PRBC peri-operatively and the chest tube output and output through the TTC-NPWT/DCT was negligible. The patient

remained hemodynamically stable. A post-operative CT angiogram of the chest was performed 24 h after the TTC-NPWT/DCT, which revealed no active arterial extravasation (**Figure 9**). The patient was then taken back to the operating room 48 h after the index thoracotomy. The vacuum-assisted closure device was removed and the left thoracic cavity was irrigated and inspected. An intercostal artery at a left fourth rib fracture was noted to have active bleeding. This was ligated and packed with oxidized cellulose (**Figure 10**), and definitive closure of the left lateral thoracotomy was done. The patient returned to the ICU intubated. He underwent percutaneous tracheostomy placement, was weaned from the ventilator, transferred to the floor, and subsequently discharged to rehabilitation.

Discussion

Case 1 demonstrates a successful use of DCT principles to emergently treat cardiac tamponade, perform cardiac massage, repair complex penetrating cardiac injuries, and use a modified vacuum-assisted temporary thoracic closure to stabilize the patient before definitive surgical closure of the chest. Case 2 illustrates the successful treatment of a massive, delayed hemothorax in a patient with severe polytrauma that was treated with evacuation of the hemothorax, DCT and temporary chest wall closure with NPWT, followed by effective resuscitation, elective definitive washout, control of bleeding, and closure of the thoracic cavity. The temporary chest wall closure with NPWT did not lead to physiologic cardiopulmonary compromise in either of these patients and afforded the opportunity to evaluate the underlying traumatic injuries to provide definitive repair in a more physiologically favorable setting. No patient required re-exploration for bleeding and there was no clinically significant difference in mean airway pressure following the index operation and chest definitive closure.

DCT is a life-saving measure, with infrequent opportunities for its application; therefore, there is limited clinical experience in its use [5,6]. Retrospective reports about the procedure are scarce [5-9]. Therefore, there remains controversy surrounding the procedure as to patient selection, surgical technique, and optimal application. Consequently, no consensus exists regarding the most effective temporary closure technique for the open thoracic cavity. Although a wide variety of packing and closure methods have been used, these 2 cases provide a clear example of how delayed closure with a modified ABTHERA ADVANCE™ Open Abdomen Dressing negative-pressure system can be successfully used as a form of TTC after DCT.

A review of 130 DCT procedures found a survival rate of 67%, ranging from 42% to 77% [5-9]. In these studies, optimal packing technique has not been established. Unlike damage control in abdominal laparotomies, careful consideration is required when deciding on the location and type of packing to ensure normal respiratory and cardiac physiology in the chest during temporary closure. In a review of their surgical experiences, O'Connor, DuBose, and Scalea demonstrated that peak airway pressures were lower in patients undergoing temporary closure with an institutionally developed modified NPWT system compared to those who underwent traditional bony thoracic closure [9].

Negative-pressure therapy has been used for deep sternal wounds [11,13,14]. When negative pressure is used for sternal wounds, it allows arteriolar dilatation to promote granulation tissue formation and decreases edema and bacterial colonization of the wound [11]. NPWT has also been used effectively as a form of TAC in abdominal DCS [1-4,16]. Negative-pressure therapy can provide an optimal physiologic environment for healing [11-16].

References:

1. Molnar TF. Thoracic damage control surgery. *J Thorac Dis.* 2019 Feb;11(Suppl. 2): S158-66
2. Frazee RC, Abernathy SW, Jupiter DC, et al. Are commercial negative pressure systems worth the cost in open abdomen management? *J Am Coll Surg.* 2013;216:730-33
3. Klein Y. Closure of the Open abdomen: A practical approach. *Curr Trauma Rep* 2016;2:196-201
4. Fernández LG. Management of the open abdomen: Clinical recommendations for the trauma/acute care surgeon and general surgeon. *Int Wound J.* 2016;13(Suppl. 3):25-34
5. Douglas A, Puzio T, Murphy P, et al. Damage control thoracotomy: A systematic review of techniques and outcomes. *Injury.* 2021;52(5):1123-27
6. Vargo DJ, Battistella FD. Abbreviated thoracotomy and temporary chest closure: An application of damage control after thoracic trauma. *Arch Surg.* 2001;136(1):21-24
7. Liu A, Nguyen J, Ehrlich H, et al. Emergency resuscitative thoracotomy for civilian thoracic trauma in the field and emergency department settings: A systematic review and meta-analysis. *J Surg Res.* 2022;273:44-55
8. Phelan HA, Patterson SG, Hassan MO, et al. Thoracic damage-control operation: Principles, techniques, and definitive repair. *J Am Coll Surg.* 2006;203(6):933-41
9. O'Connor JV, DuBose JJ, Scalea TM. Damage control thoracic surgery: Management and outcomes. *J Trauma Acute Care Surg.* 2014;77(5):660-65
10. Seamon MJ, Haut ER, Van Arendonk K, et al. An evidence-based approach to patient selection for emergency department thoracotomy A practice management guideline from the Eastern Association for the Surgery of Trauma. *J Trauma Acute Care Surg.* 2015;79(1):159-73
11. Hersh RE, Jack JM, Dahman MI, et al. The vacuum-assisted closure device as a bridge to sternal wound closure. *Ann Plast Surg.* 2001;46(3):250-54
12. O'Connor J, Kells A, Henry S, Scalea T. Vacuum-assisted closure for the treatment of complex chest wounds. *Ann Thorac Surg.* 2005;79:1196-200
13. Chowdhry SA, Wilhelmi BJ. Comparing negative pressure wound therapy with instillation and conventional dressings for sternal wound reconstructions. *Plas Reconstr Surg Glob Open.* 2019;7(1):e2087
14. Barbera F, Lorenzetti F, Marsili R, et al. The impact of preoperative negative pressure wound therapy on pectoralis major muscle flap reconstruction for deep sternal wound infections. *Ann Plast Surg.* 2019;83(2):195-200
15. Elnahas Y, Ammar A. Vacuum assisted closure therapy for post sternotomy mediastinitis: Definitive or bridge to reconstruction. *Journal of the Egyptian Society of Cardio-Thoracic Surgery.* 2018;26(2):136-40
16. Auer T, Sauseng S, Delcev P, Kohek P. Effect of negative pressure therapy on open abdomen treatments. Prospective randomized study with two commercial negative pressure systems. *Front Surg.* 2021;7:596056

Conclusions

Our report supports the use of NPWT temporary closure techniques as a safe and effective TTC after DCT. It is our opinion that the experience gained in the management of the open abdomen with TAC-NPWT may be translational to application in the thoracic cavity in appropriately selected patients. We believe that this report will contribute to the scant existing clinical experience in the use of modified NPWT in the setting of DCT. We have shown that intrathoracic placement of a modified NPWT system for TTC can be successfully applied in penetrating and blunt thoracic injuries and may be a viable alternative for TTC. We hope that this experience will lead to further scientific study of the effects of NPWT in the thoracic setting, developing a fuller understanding of DCT, its indications, techniques, and available options for the treating surgeon.

These cases suggest that DCT with intrathoracic placement of a modified ABTHERA ADVANCE™ Open Abdomen Dressing negative-pressure system may be an effective and life-saving technique with the potential for positive outcomes in these high-risk patients.

Declaration of Figures' Authenticity

All figures submitted have been created by the authors who confirm that the images are original with no duplication and have not been previously published in whole or in part.