

# Complex pulmonary arteriovenous fistula in mother and daughter

## Case report

Xin Zhang, MD<sup>a,b,\*</sup>, Mingxia Zheng, BS<sup>a</sup>, Xingjian Li, MBBS<sup>b</sup>, Yejun Yan, MBBS<sup>b</sup>, Caixia Yang, MBBS<sup>c</sup>, Zhengang Zhao, MD<sup>a</sup>, Yuan Feng, MD<sup>a,\*</sup>, Mao Chen, MD, PhD<sup>a,\*</sup>

### Abstract

**Rationale:** Complex pulmonary arteriovenous fistula (PAVF) is unusual, and even rarer in 2 members of a family. PAVF may not appear on chest X-ray or computed tomography imaging, especially in asymptomatic patients, and therapy is limited. Herein, PAVFs occurring in a mother and daughter are described, with the current standard methods of diagnosis and treatment of PAVF.

**Patient concerns:** A 34-year-old woman and her 13-year-old daughter presented with light cyanosis of the nail beds but were otherwise asymptomatic, and physical examination was unremarkable. Their arterial oxygen saturation levels were low (80–85%).

**Diagnoses:** Angiography led to a diagnosis of PAVF involving the bilateral lung in both women.

**Interventions:** The combined use of coils with occluder (patent ductus arteriosus, or PDA) to obstruct the fistula.

**Outcomes:** After interventional treatment, the patients' arterial oxygen saturation improved rapidly (90–95%). At 6-month follow-up, the patients' symptoms and oxygen saturation were normal.

**Lessons:** PAVF is an autosomal dominant disease. Here, the characteristics of the 2 patients were very similar. Using detachable coils and then a PDA occluder is a highly efficient method for treating complex PAVFs.

**Abbreviations:** HHT = hereditary hemorrhagic telangiectasia, PAVF = pulmonary arteriovenous fistula, PDA = patent ductus arteriosus.

**Keywords:** family, interventional treatment, pulmonary arteriovenous fistulas

## 1. Introduction

Pulmonary arteriovenous fistula (PAVF) is a very rare vascular anomaly, with an estimated prevalence of 2 or 3 per 100,000 people.<sup>[1]</sup> PAVFs may be acquired, but most are congenital and associated with hereditary hemorrhagic telangiectasia (HHT). Sporadic isolated cases are also reported.<sup>[2]</sup>

Most PAVFs (80%) are considered local, with a simple morphology with a single feeding artery and venous sac and a single drainage vein. The remaining PAVFs (~20%) are characterized as complex, that is, vascularized by more than 1

branch of the pulmonary artery or through several segmental pulmonary arteries and (or) drained through multiple segmental pulmonary veins.<sup>[3]</sup> Compared with simple PAVFs, complex PAVFs are rarer and more severe.

Therapy for PAVF is limited, and there is significant morbidity and mortality.<sup>[3]</sup> The presence and significance of symptoms depend on the size of the left-to-right shunt.<sup>[1,4]</sup> Surgery has been the main treatment, but the iatrogenic damage to normal lung tissue can occur, and there are many complications.<sup>[4,5]</sup>

Herein, we describe 2 interesting cases of complex PAVF, not related to HHT, that occurred in a mother and her daughter. Both displayed similar clinical features and pathological involvement, and both recovered after the combined use of coils with a patent ductus arteriosus (PDA) occluder to obstruct the fistula.

## 2. Case report

The 2 patients consented to publish this case report, which was also approved by the Institutional Review Board of West China Hospital of Sichuan University, Chengdu, China.

### 2.1. Case 1

A 34-year-old woman was admitted to the hospital due to low arterial oxygen saturation, which was noted during the preoperative work-up for elective gynecologic surgery of an ectopic pregnancy, 2 months before admission. Arterial blood gas showed a partial pressure of arterial oxygen (PaO<sub>2</sub>) of 49 mm Hg and an arterial oxygen saturation (SaO<sub>2</sub>) of 83% on room air. The patient had no cardiorespiratory symptoms except slight

Editor: N/A.

The authors report no conflicts of interest.

<sup>a</sup> Department of Cardiology, West China Hospital, Sichuan University, Chengdu,

<sup>b</sup> Department of Cardiology, <sup>c</sup> Department of Hematology and Rheumatology, Central Hospital of Baoji City, Weibin District, Baoji, Shaanxi, China.

\* Correspondence: Yuan Feng, Mao Chen, Department of Cardiology, West China Hospital, Sichuan University, Chengdu, Sichuan Province, China (e-mails: fynotebook@hotmail.com, hmaochen@vip.sina.com), Xin Zhang, Sichuan University West China Hospital, Chengdu, Sichuan, China (e-mail: 466184698@qq.com).

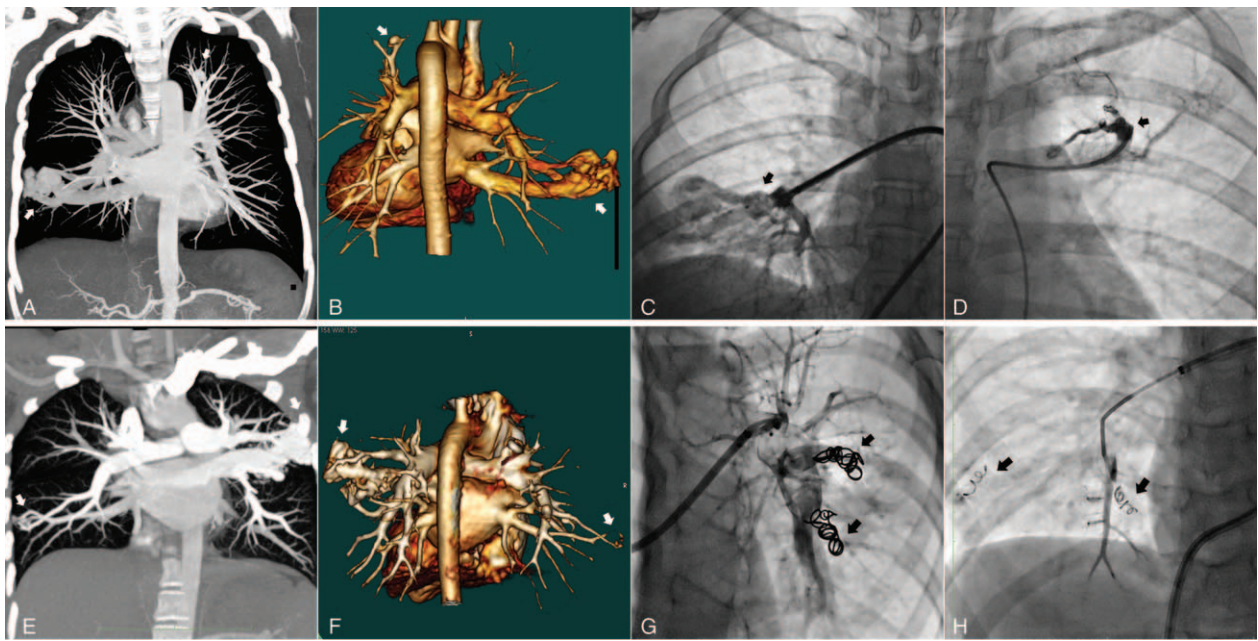
Copyright © 2019 the Author(s). Published by Wolters Kluwer Health, Inc. This is an open access article distributed under the terms of the Creative Commons Attribution-Non Commercial License 4.0 (CCBY-NC), where it is permissible to download, share, remix, transform, and buildup the work provided it is properly cited. The work cannot be used commercially without permission from the journal.

Medicine (2019) 98:2(e13922)

Received: 17 September 2018 / Received in final form: 3 December 2018 /

Accepted: 10 December 2018

<http://dx.doi.org/10.1097/MD.0000000000013922>



**Figure 1.** Pulmonary arteriovenous fistulas and postprocedural images of mother (A–D) and daughter (E–H). (A, B) Multislice computed tomography showing an anomalous communication between the basal segment of the lower lobe of the right lung and the left upper lobe (white arrows). (C, D) Successful closure of the pulmonary arteriovenous fistula using a patent ductus arteriosus closure and platinum detachable coils (black arrows). (E, F) Multislice computed tomography showing an anomalous communication between the lower lobe of the right lung and left lung upper lobe (white arrows). (G, H) Successful closure of the pulmonary arteriovenous fistula using 6 platinum detachable coils (black arrows).

cyanosis of the nail beds. She denied chest pain, hemoptysis, cough, ankle edema, palpitation, or orthopnea. The patients' history, review of systems, and physical examination of the chest and precordium were unremarkable.

Laboratory studies showed normal urinalysis, a hemoglobin of 169 g/L, and red blood cell count of 5.66 million/mL. Echocardiography was unremarkable. Computed tomography angiography showed a large complex lesion composed of serpiginous tubular structures involving the basal segment of the lower lobe of the right lung and bilateral upper lobes, suggestive of a racemose tangle of blood vessels (Fig. 1 A, B). The large PAVF was between the anterior basal segment of the lower lobe of the right pulmonary artery and the upper basal segment of the right vein (37 × 28 mm). These signs indicated a large complex PAVF involving both the upper lobe and basal segment of right lower lobe. The serpiginous angiogram also showed an arteriovenous communication in the anterior segment of the left upper lobe.

After a complete work-up, the PAVF was successfully occluded with platinum detachable coils (Cook Medical, Bloomington, IN) and PDA occluder (P10/12, Starway Medical Technology, Beijing, China; Fig. 1 C, D). They were successfully deployed with proper positioning and there was no residual leak immediately after the procedure.

After intervention, the oxygen saturation (96%) markedly improved on room air and was maintained at the 6-month follow-up. The patient was later administered warfarin (2.5 mg, once daily) for 6 months to prevent embolism.

## 2.2. Case 2

A 13-year-old girl was admitted to the hospital in July 2014. The patient's mother (case 1, above) had received a diagnosis of arteriovenous fistula in the left lung. Because of this, the patient

also had an angiogram, which revealed a small arteriovenous fistula in the right lower lobe. She was asymptomatic, and her history and systems review were unremarkable.

The pertinent physical findings were elevated hemoglobin (202 g/L) and red blood cell count (6.36 million/mL). An electrocardiogram showed slight changes in coronary artery circulation. Computed tomography angiography revealed a large complex lesion in the upper lobe of the right lung, and the lower lobe, outer basal segment, and left upper lobe of the left lung. The large PAVF was between the anterior superior left pulmonary artery and the apical posterior vein of the left vein (Fig. 1E, F).

Six spring coils (Cook Medical) were used to embolize the fistula while avoiding any occlusion of the entire arterial branch (Fig. 1G, H). After embolization, the outflow vessels of the fistula were blocked as well as some healthy lung vessels. However, we could not completely embolize all of the fistulas.

After intervention, the patient's oxygen saturation (96%) markedly improved on room air. At the 6-month follow-up, the patient's symptoms and oxygen saturation were unremarkable. The patient was instructed to take aspirin (100 mg, once daily) for 6 months to prevent embolism.

## 3. Discussion

The PAVF is a rare anomaly, which can be classified as simple or complex. It is even rarer for the complex type to occur in 2 members of the same family. PAVF is an autosomal dominant disease, with about 90% of cases occurring in patients with HHT,<sup>[1,6]</sup> or alternatively, acquiring PAVF because of liver disease or infections such as tuberculosis. However, these possibilities were excluded in our patients, and the diagnoses were idiopathic PAVF.

Both the characteristics and locations of lesions in the 2 patients were very similar. Both were asymptomatic, and the physical examination revealed only slight cyanosis in the nail

beds and an oxygen saturation of 70% to 85% on room air according to pulse oximetry. After medical intervention, the oxygen saturation increased to 95%. The majority of patients with multiple PAVFs have lesions confined to the lower lobes; 8% to 20% of patients have bilateral PAVFs.<sup>[7]</sup> The present cases were rare congenital PAVF that did not involve the upper left lobe. The fistula sites of the 2 cases were similar.

The PAVF may not be observed on a plain chest film or computed tomography image. Angiographic visualization of all portions of both lungs is required to detect the presence of multiple lesions and to delineate the location of the feeding artery and the draining vein.<sup>[8,9]</sup> In patients with multiple lesions, pulmonary arteriography can confirm the presence of fistulas with a pulmonary arterial blood supply.

Diffuse PAVFs result in hypoxemia and severe complications, including cerebrovascular accidents, hemoptysis, brain abscess, and hemothorax secondary to rupture,<sup>[9]</sup> which are challenging to treat. Surgery has long been standard. Percutaneous embolotherapy is now usually preferable, as this avoids major surgery, general anesthesia, and the loss of pulmonary parenchyma function.<sup>[10]</sup> Platinum coil embolization is performed for pulmonary arteriovenous malformations, preserving the perfusion of a healthy lung. However, there is risk of paradoxical embolization with coils, even when using detachable ones, ranges from 0.7% to 4%. Other disadvantages include recanalization and migration through the sac.<sup>[10–12]</sup> A PDA occluder has been successfully used for embolization of pulmonary arteriovenous malformations, as well as rapid occlusion of such malformations with a large feeding artery.

Considering that the complex type is more severe and therapy is limited, for our patients we combined the use of coils with a PDA occluder. The PDA occluders and coils were sized according to the dimension of the feeding artery. This prevented potential migration through the sac into the draining vein, which may result in a nontarget embolization. Embolotherapy was performed at the distal level close to the PAVF to preserve perfusion of the healthy lung.

The cases we describe here highlight a rare and unique presentation of PAVF in 2 members of a family, mother, and daughter. PAVF is an autosomal dominant disease, and both the characteristics and locations were very similar. We combined the use of coils with a PDA occluder to obstruct the fistula. After interventional treatment, the patients' arterial oxygen saturation

improved rapidly, and remained stable when we followed up at 6 months. Despite of these, our case has limitations. For example, there is an absence of other diagnostics, like genetic tests, performance of which could enhance knowledge about this condition.

### Author contributions

**Conceptualization:** Yuan Feng, Mao Chen.

**Methodology:** Yejun Yan, Mao Chen.

**Project administration:** Mingxia Zheng.

**Resources:** Xingjian Li.

**Software:** Caixia Yang.

**Writing – original draft:** Xin Zhang.

**Writing – review & editing:** Zhengang Zhao.

### References

- [1] Shovlin CL, Winstock AR, Peters AM, et al. Medical complications of pregnancy in hereditary haemorrhagic telangiectasia. *QJM* 1995;88:879–87.
- [2] Liu K, Liu S. Pulmonary arteriovenous fistula in an aged patient. *Eur J Cardiothorac Surg* 2011;39:e149.
- [3] White RI Jr, Mitchell SE, Barth KH, et al. Angioarchitecture of pulmonary arteriovenous malformations: an important consideration before embolotherapy. *AJR Am J Roentgenol* 1983;140:681–6.
- [4] Gossage JR, Kani G. Pulmonary arteriovenous malformation: a state of the art review. *Am J Respir Crit Care Med* 1998;158:643–60.
- [5] Liu FY, Wang MQ, Fan QS, et al. Endovascular embolization of pulmonary arteriovenous malformations. *Chin Med J (Engl)* 2010;123:23–8.
- [6] Faughnan ME, Granton JT, Young LH. The pulmonary vascular complications of hereditary haemorrhagic telangiectasia. *Eur Respir J* 2009;33:1186–94.
- [7] Cartin-Ceba R, Swanson KL, Krowka MJ. Pulmonary arteriovenous malformations. *Chest* 2013;144:1033–44.
- [8] Glenn F, Harrison CS, Steinberg I. Pulmonary arteriovenous fistula occurring in siblings: report of two cases. *Ann Surg* 1953;138:886–91.
- [9] Prager RL, Laws KH, Bender HW Jr. Arteriovenous fistula of the lung. *Ann Thorac Surg* 1983;36:231–9.
- [10] Dines DE, Seward JB, Bernatz PE. Pulmonary arteriovenous fistulas. *Mayo Clin Proc* 1983;58:176–81.
- [11] Faughnan ME, Palda VA, Garcia-Tsao G, et al. International guidelines for the diagnosis and management of hereditary haemorrhagic telangiectasia. *J Med Genet* 2011;48:73–87.
- [12] Takahashi K, Tanimura K, Honda M, et al. Venous sac embolization of pulmonary arteriovenous malformation: preliminary experience using interlocking detachable coils. *Cardiovasc Intervent Radiol* 1999;22:210–3.