

# Morphologic Analysis of Nonosseous Talocalcaneal Coalitions Using 3D Reconstruction

Azusa Yoneda, MD<sup>1</sup> , Yasuhito Tanaka, MD<sup>1</sup>, Hiromasa Fujii, MD<sup>1</sup>, Shinji Isomoto, MD<sup>2</sup>, and Kazuya Sugimoto, MD<sup>2</sup>

## Abstract

**Background:** Resection of talocalcaneal coalitions has generally involved osseous coalitions. We attempted to evaluate the morphology of nonosseous talocalcaneal coalitions. This study aimed to investigate if the calcaneal articular surface area of feet with talocalcaneal coalitions is different than that of normal feet.

**Methods:** Twenty nonosseous talocalcaneal coalition cases with analyzable computed tomography (CT) scans were compared to 20 control cases. Three-dimensional models of the talus and calcaneus were constructed, and the surface areas of the posterior facet (SPF), whole talocalcaneal joint of the calcaneus (SWJ), and coalition site (SCS) of each 3D-CT model were measured. “Calibrated” values of the 2 groups were created to adjust for relative size of the tali and then compared. The preoperative and postoperative AOFAS Ankle-Hindfoot scale was calculated for 9 cases that had undergone single coalition resection.

**Results:** The calibrated SPF and SWJ were significantly greater in the coalition group than in the control group (40% and 12%, respectively). No significant difference was detected between the calibrated (SWJ – SCS) value of the coalition group and the calibrated SWJ value of the control group. The AOFAS scale was improved postoperatively in all 9 cases analyzed.

**Conclusion:** The calcaneal articular surface of nonosseous talocalcaneal coalition feet in our series was larger than that of the normal feet. This study indicates that the total calcaneal articular surface after coalition resection may be comparable to the calcaneal articular surface of normal feet. We suggest that the indication for coalition resection be reconsidered for nonosseous coalition.

**Level of Evidence:** Level III, retrospective comparative study.

**Keywords:** talocalcaneal coalition, 3-dimensional computed tomography, calcaneal articular surface

## Introduction

Tarsal coalition is classified histologically into osseous, cartilaginous, or fibrous type. Incomplete coalition is mostly cartilaginous or fibrous histologically. Moreover, incomplete coalition causes abnormal mechanical stress and induces pain.<sup>5</sup> Talocalcaneal coalition is the most common type in tarsal coalition in Japan,<sup>6</sup> whereas the incidence rates of talocalcaneal and calcaneonavicular coalitions are almost equal in Western countries.<sup>10</sup> Coalition resection is the standard treatment for patients with persistent symptoms unrelieved by conservative therapy.<sup>9</sup> Although good outcomes are expected from coalition resection, especially in young athletes,<sup>9,11</sup> some studies report poor results in cases with relatively broad coalitions.

Wilde et al<sup>12</sup> and Luhmann et al<sup>7</sup> reported that poor results were observed in feet with a >50% coalition area of the posterior facet of the calcaneus noted on preoperative computed tomography (CT). Moreover, Comfort et al<sup>1</sup> reported that if the coalition occupied more than one-third

<sup>1</sup> Department of Orthopaedic Surgery, Nara Medical University, Nara, Japan

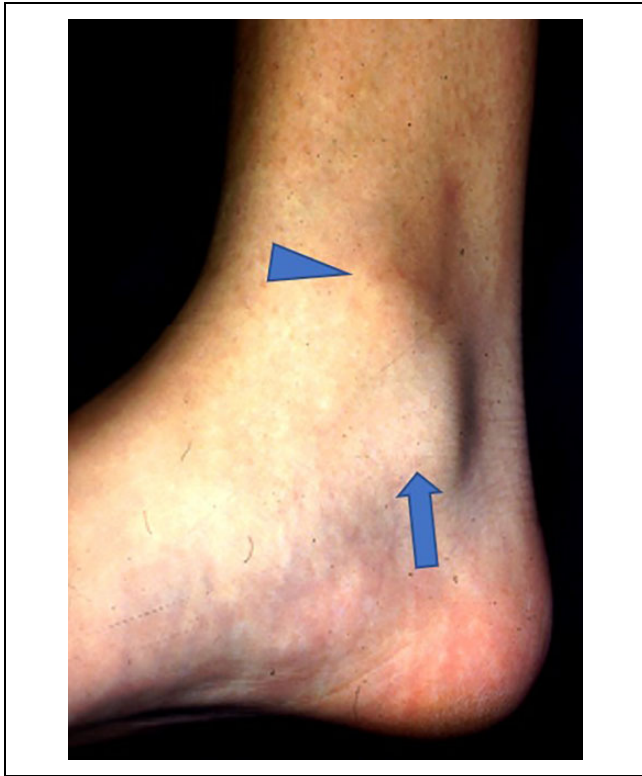<sup>2</sup> Department of Orthopaedic Surgery, Nara Prefecture General Medical Center, Nara, Japan

### Corresponding Author:

Azusa Yoneda, MD, Department of Orthopaedic Surgery, Nara Medical University, 840 Shijo-cho, Kashihara, Nara 634-8522, Japan.

Email: azusa@naramed-u.ac.jp





**Figure 1.** Bony protrusion (arrow) at the site of talocalcaneal coalition, located posteroinferiorly to the medial malleolus (arrowhead).

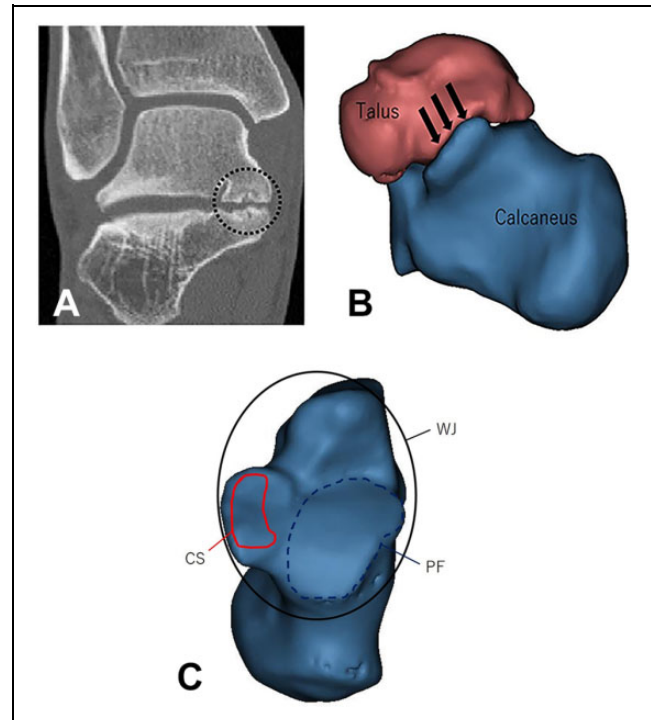
of the total joint surface, 75% of their results were fair or poor. These percentages of the area of coalition, which were obtained from the clinical outcomes, are often considered as an indication for resection of coalition. The majority of the coalitions in these previous studies was osseous. We supposed that the characteristics of talocalcaneal coalitions and the normal feet should be compared to evaluate the appropriateness of coalition resection, and nonosseous coalitions need to be analyzed separately from osseous coalitions because their pathologic conditions are different.

A bony protrusion at the site of coalition is one of the clinical features of talocalcaneal coalitions (Figure 1). Therefore, we hypothesized that the calcaneal articular surface of the feet with talocalcaneal coalition is larger than that of the normal feet and aimed to prove this theory. Moreover, we also intended to evaluate the morphologic validity of coalition resection.

In previous studies, the extent of coalition was calculated by measuring the width of the coalition of each coronal CT slice. We planned to use a software for 3-dimensional (3D) analysis instead because this method is more accurate.

## Materials and Methods

This retrospective study was approved by the institutional review boards of our institutes.

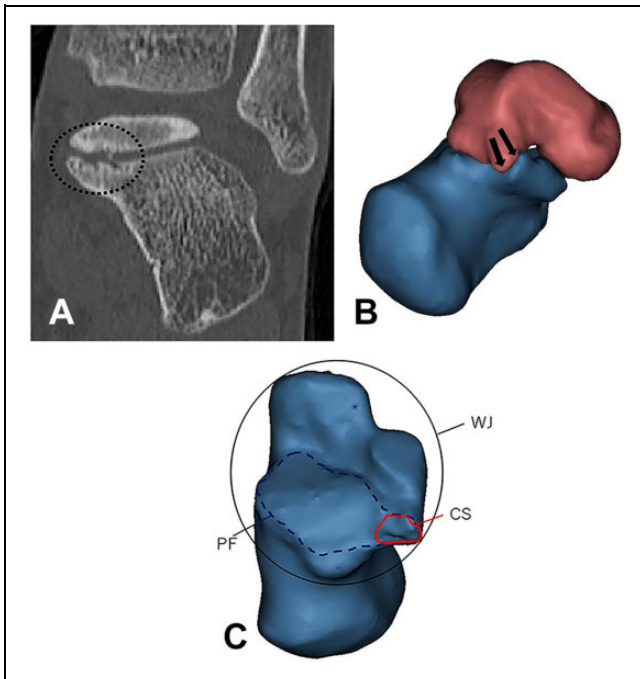


**Figure 2.** Coalition at the middle facet. (A) Coronal computed tomography. (B) Three-dimensional model of the talus and calcaneus. Arrows indicate the coalition. (C) Three-dimensional model of the calcaneus viewed from above. Each circle indicates a whole talocalcaneal joint (WJ), posterior facet (PF), and coalition site (CS).

We reviewed the medical records of patients who visited either of our 2 hospitals between 2012 and 2019 with a diagnosis of talocalcaneal coalition. We included cases that had foot CT scans taken at the age of 13 years or older, with enough slices to adapt to the software and without osteoarthritic change. We excluded 1 osseous coalition case. The control group included accessory navicular and lower leg fractures. The inclusion criteria were the same in the coalition and control groups.

CT data were stored as Digital Imaging and Communications in Medicine (DICOM) files. Three-dimensional models of the talus and calcaneus were obtained from the DICOM using Mimics Research 21.0 (Materialise, Leuven, Belgium) (Figures 2A and B, 3A and B). These 3D models were imported to 3-matic Research 13.0 (Materialise), and the surface area or the length of each site was measured using the software.

The surface areas of the posterior facet (SPF) and the whole talocalcaneal joint of the calcaneus (SWJ) of each foot were obtained (Figures 2C and 3C). We defined the SWJ as the whole superior surface area of the calcaneus under the talus, not the total of the anterior, middle, and posterior facets, because identifying the anterior facet was sometimes difficult and the surface areas of the facets could be inaccurate. The mean value of both feet was acquired for



**Figure 3.** Coalition at the posterior facet. (A) Coronal computed tomography. (B) Three-dimensional model of the talus and calcaneus. (C) Three-dimensional model of the calcaneus viewed from above.

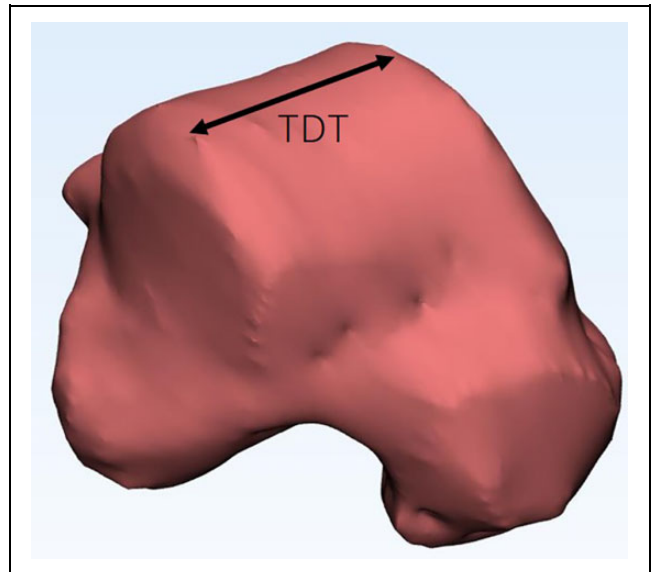
bilateral coalition cases. The values were calibrated to compare the 2 groups. We set the transverse diameter of the trochlea of the talus (TDT) as a standard after checking its appropriateness by proving the correlation between the surface area of the calcaneus facets (SPF and SWJ) and the diameter in the control group (Figure 4). The surface area was divided by the squared TDT value to calibrate the area by the length. The calibrated SPF and SWJ values of the coalition and control groups were compared.

We obtained the surface area of the coalition site (SCS) and compared the calibrated (SWJ – SCS) value of the coalition group with the calibrated SWJ value of the control group (Figures 2C and 3C).

For an additional clinical evaluation, preoperative and postoperative American Orthopaedic Foot & Ankle Society (AOFAS) ankle-hindfoot scale<sup>4</sup> scores were calculated for 9 cases in the coalition group—corresponding to patients who had undergone single coalition resection at our institutions. The foot that had more severe symptoms was analyzed for bilateral coalition cases because the AOFAS scale represented the condition of that foot.

### Statistical Analysis

The Shapiro-Wilk test was used to analyze if the data were normally distributed. Data correlation was defined by the Pearson product-moment correlation coefficient for



**Figure 4.** Three-dimensional model of the talus. Transverse diameter of the trochlea of talus (TDT) is shown.

normally distributed data or the Spearman rank correlation coefficient for nonnormally distributed data. In comparing data of the 2 groups, 2-sample *t* tests or Mann-Whitney tests were used for normally or nonnormally distributed data, respectively. In comparing data of the same group, paired *t* tests or Wilcoxon signed rank tests were used. All computations were completed with IBM SPSS Statistics (version 27; IBM Corp, Armonk, NY, USA), and *P* values <.05 were considered significant. A power analysis was performed with G\*Power (version 3.1.9.7; Dusseldorf University, Dusseldorf, Germany).<sup>2</sup>

### Results

Twenty cases with nonosseous coalition were included in the coalition group: 10 males and 10 females, with a mean age of 28 (range, 13-58) years. In contrast, 20 cases were included in the control group: 11 males and 9 females, with a mean age of 29 (range, 14-53) years. The demographics did not differ significantly between the groups (sex, *P* = .752; age, *P* = .779).

We first evaluated the correlation between the transverse diameter of the TDT and surface area of the calcaneus facets (SPF and SWJ) in the control group. The TDT showed a very strong correlation with the SPF ( $\gamma = 0.790$ ; *P* < .001) and SWJ ( $\gamma = 0.771$ ; *P* < .001). Therefore, we set TDT as the standard for calibrating the value of SPF and SWJ.

The mean SPF was  $7.46 \pm 1.88 \text{ cm}^2$  in the coalition group and  $5.83 \pm 1.07 \text{ cm}^2$  in the control group (*P* = .003), whereas the mean SWJ was  $15.43 \pm 2.94 \text{ cm}^2$  in the coalition group and  $15.01 \pm 2.07 \text{ cm}^2$  in the control group (*P* = .698). The “calibrated” values used to adjust for different-sized tali of the SPF and SWJ were calculated as (SPF/TDT<sup>2</sup>) and (SWJ/TDT<sup>2</sup>), respectively. The mean calibrated SPF was

**Table 1.** Comparison of Surface Area of the Calcaneus Between the Coalition Group and the Control Group.

	Coalition, Mean $\pm$ SD	Control, Mean $\pm$ SD	P value
SPF, cm <sup>2</sup>	7.46 $\pm$ 1.88	5.83 $\pm$ 1.07	.003
SWJ, cm <sup>2</sup>	15.43 $\pm$ 2.94	15.01 $\pm$ 2.07	.698
Calibrated SPF	1.23 $\pm$ 0.21	0.88 $\pm$ 0.09	<.001
Calibrated SWJ	2.56 $\pm$ 0.29	2.28 $\pm$ 0.23	.002

Abbreviations: SPF, surface area of the posterior facet; SWJ, surface area of the whole talocalcaneal joint of the calcaneus.

**Table 2.** Comparison of Surface Area With Coalition Site Removed Between the Coalition Group and the Control Group.

	Coalition, Mean $\pm$ SD	Control, Mean $\pm$ SD	P value
SCS, cm <sup>2</sup>	1.58 $\pm$ 0.90		
SWJ-SCS, cm <sup>2</sup>	13.85 $\pm$ 2.76	15.01 $\pm$ 2.07	.102
Calibrated (SWJ-SCS)	2.30 $\pm$ 0.28	2.28 $\pm$ 0.23	.792

Abbreviations: SCS, surface area of the coalition site; SWJ, surface area of the whole talocalcaneal joint of the calcaneus.

1.23  $\pm$  0.21 in the coalition group and 0.88  $\pm$  0.09 in the control group, and the mean calibrated SWJs were 2.56  $\pm$  0.29 and 2.28  $\pm$  0.23, respectively. Both were significantly greater in the coalition group than in the control group ( $P < .001$ ;  $P = .002$ ) (Table 1). A post hoc power analysis revealed that the power was 0.99 for the calibrated SPF and 0.91 for the calibrated SWJ.

The mean SCS in the coalition group was 1.58  $\pm$  0.90 cm<sup>2</sup>, and the mean SCS-to-SPF ratio was 22.6%  $\pm$  15.7%. The mean (SWJ – SCS) was 13.85  $\pm$  2.76 cm<sup>2</sup>, which was compared with the mean SWJ of the control group ( $P = .102$ ). The mean calibrated (SWJ – SCS) value of the coalition group was 2.30  $\pm$  0.28, and the mean calibrated SWJ value of the control group was 2.28  $\pm$  0.23 ( $P = .792$ ) (Table 2). Power analysis revealed that each group should have had a sample size of 64 to achieve a power level of 0.80.

The mean postoperative follow-up duration of the 9 cases with single coalition resection was 1.9 (range, 0.8–4.0) years, and the AOFAS scale score improved after coalition resection in all cases. The mean preoperative AOFAS scale score was 73.9  $\pm$  15.0, and the mean postoperative score was 89.7  $\pm$  4.7. The scale showed a significant improvement postoperatively ( $P = .008$ ).

## Discussion

This is the first study that evaluated the morphologic feature of talocalcaneal coalitions by measuring the calcaneal surface area. Our findings show that in this small cohort, the calcaneal articular surface of the feet with nonosseous talocalcaneal coalition is relatively larger than that of normal feet. This correlated with the typical clinical feature of

talocalcaneal coalitions—the presence of a bony protrusion at the coalition site.

Previous studies reported poor results in resection of coalitions that occupied more than half of the posterior facet<sup>7,12</sup> or one-third of the total joint surface.<sup>1</sup> Conversely, Khoshbin et al<sup>3</sup> observed favorable long-term results when resections were performed on talocalcaneal coalitions that were larger than 50% of the posterior facet.

If the articular surface area after resection is comparable to that of a normal foot, the authors believe that a coalition resection should not affect the weightbearing of the calcaneus in well aligned feet. Wilde et al<sup>12</sup> reported that unsatisfactory results were found in the feet corresponding to preoperative CT showing heel valgus >16 degrees. Moreover, Luhmann et al<sup>7</sup> showed that heel valgus >21 degrees was associated with poor outcomes.

In this study, the mean SCS-to-SPF ratio in the coalition group (22.6%) was considerably smaller than that in previous studies (53.4%,<sup>7</sup> 46%<sup>12</sup>). One of the reasons for this finding is that all our cases were nonosseous coalition, whereas the majority of coalitions of the previous studies was osseous. Generally, incomplete nonosseous coalition induces pain and is distinguished from osseous coalition. The pathogenesis is different between osseous and nonosseous coalitions; therefore, the resection recommendations of the previous studies may not be appropriate for incomplete coalitions. Although the sample size of the cases that underwent coalition resection was small and the follow-up duration was short, all cases had good outcomes. A further study including the postoperative evaluation with a larger sample size is warranted to discuss the validity and indication of coalition resection for nonosseous coalitions.

In previous studies, the coalition extent was calculated by measuring the width of the coalition of each coronal CT slice. We employed software for 3D analysis instead, which rendered our measurements more accurate and clearer than those of previous studies. Rozansky et al<sup>8</sup> reported the clinical benefits of 3D-CT for talocalcaneal coalitions. Three-dimensional CT displays the precise location, shape, and extent of talocalcaneal coalitions, which are helpful in characterizing the coalition. Moreover, software 3D-CT analysis allows preoperative planning to be more accurate and detailed.

The present study has limitations. The main limitation was that each site of the 3D foot model in the software was identified and calculated manually by the first author. The edges of the posterior facet or coalition site were sometimes unclear on 3D-CT, especially in young patients with incomplete ossification; thus, we excluded patients under 13 years of age. CT slices of each plane were checked to determine the extent of the posterior facet or coalition accurately when their edges were unclear on the 3D model. Another limitation was that we analyzed the talocalcaneal coalition at different sites altogether. The effect of coalition resection on foot alignment and weightbearing depends not only on the size but also on the site of the coalition. Nevertheless, our finding that the calcaneal articular surface in nonosseous talocalcaneal

coalitions is larger than that of the normal feet remains consistent. Further outcomes could have been analyzed if the talocalcaneal coalition at each site had been analyzed separately and if we had worked with a larger sample size.

## Conclusions

The present study found that the calcaneal articular surface of the feet with nonosseous talocalcaneal coalitions was larger than that of normal feet in our 20-patient series. Moreover, this study indicates that the residual calcaneal articular surface area after coalition resection is comparable to the calcaneal articular surface of normal feet. Our small clinical series combined with this imaging study suggests that in well aligned feet, resection of nonosseous talocalcaneal coalitions is a reasonable treatment option.

## Ethical Approval

Ethical approval for this study was obtained from institutional review board of Nara Medical University (Approval number: 2484) and Nara Prefecture General Medical Center (Approval number: 556).


## Declaration of Conflicting Interests

The author(s) declared no potential conflicts of interest with respect to the research, authorship, and/or publication of this article. ICMJE forms for all authors are available online.

## Funding

The author(s) received no financial support for the research, authorship, and/or publication of this article.

## ORCID iD

Azusa Yoneda, MD,  <https://orcid.org/0000-0002-8989-4084>

## References

1. Comfort TK, Johnson LO. Resection for symptomatic talocalcaneal coalition. *J Pediatr Orthop*. 1998;18:283-288.
2. Faul F, Erdfelder E, Lang AG, Buchner A. G\*Power 3: A flexible statistical power analysis program for the social, behavioral, and biomedical sciences. *Behav Res Methods*. 2007;39:175-191.
3. Khoshbin A, Law PW, Caspi L, Wright JG. Long-term functional outcomes of resected tarsal coalitions. *Foot Ankle Int*. 2013;34(10):1370-1375.
4. Kitaoka HB, Alexander IJ, Adelaar RS, Nunley JA, Myerson MS, Sanders M. Clinical rating systems for the ankle-hindfoot, mid-foot, hallux, and lesser toes. *Foot Ankle Int*. 1994;15(7):349-353.
5. Kumai T, Takakura Y, Akiyama K, Higashiyama I, Tamai S. Histopathologic study of nonosseous tarsal coalition. *Foot Ankle Int*. 1998;19(8):525-531.
6. Kumai T, Tanaka Y, Takakura Y, Tamai S. Isolated first naviculocuneiform joint coalition. *Foot Ankle Int*. 1996;17(10):635-640.
7. Luhmann SJ, Schoenecker PL. Symptomatic talocalcaneal coalition resection: indications and results. *J Pediatr Orthop*. 1998;18:748-754.
8. Rozansky A, Varley E, Moor M, Wenger DR, Mubarak SJ. A radiologic classification of talocalcaneal coalitions based on 3D reconstruction. *J Child Orthop*. 2010;4(2):129-135.
9. Scranton PE. Treatment of symptomatic talocalcaneal coalition. *J Bone Joint Surg Am*. 1987;69(4):533-539.
10. Stormont DM, Peterson HA. The relative incidence of tarsal coalition. *Clin Orthop*. 1983;181:23-36.
11. Takakura Y, Sugimoto K, Tanaka Y, Tamai S. Symptomatic talocalcaneal coalition, its clinical significance and treatment. *Clin Orthop Relat Res*. 1991;269:249-256.
12. Wilde PH, Torode IP, Dickens DR, Cole WG. Resection for symptomatic talocalcaneal coalition. *J Bone Joint Surg Br*. 1994;76(5):797-801.