

# Endovascular aortic repair in an asymptomatic COVID-19-positive patient with a symptomatic inflammatory abdominal aortic aneurysm

Halim Yammine, MD, Jocelyn K. Ballast, BA, Neil Poulsen, MD, and Frank R. Arko III, MD, *Charlotte, NC*

## ABSTRACT

In this report, we present the case of a COVID-19-positive patient whose symptomatic inflammatory abdominal aortic aneurysm was successfully treated with endovascular aortic repair at our institution. We discuss the reasoning behind the type of therapy used and the various lessons learned. Based on our experience with this patient, we recommend an endovascular approach for similar COVID-19 patients and suggest a prophylactic dose of enoxaparin (Lovenox; 40 mg daily) postoperatively for 14 days. (*J Vasc Surg Cases and Innovative Techniques* 2020;6:531-3.)

**Keywords:** EVAR; AAA; COVID-19; Symptomatic; Endovascular

The COVID-19 pandemic has swept the nation and the whole planet in the past few months. Despite its being predominantly a respiratory illness, the vascular system is also affected by the disease, with reports of spontaneous arterial and venous thrombosis.<sup>1-4</sup> Here we describe the case of an asymptomatic COVID-19 patient who was treated at our institution for a symptomatic inflammatory abdominal aortic aneurysm (AAA). The patient consented to the publication of these case details.

## CASE REPORT

A 65-year-old white man presented to an outside institution with symptoms of lower abdominal pain radiating to his back. He had known chronic back pain, but the pain had worsened in the past 4 days, prompting him to go to the emergency department. There, computed tomography angiography of the abdomen and pelvis (Fig 1) showed a 5.3-cm inflammatory AAA. Transfer of the patient to our facility was accepted. Per our hospital's protocol, he was tested for COVID-19 as soon as he arrived at the ward, and his operation was delayed by 24 hours until we obtained the results. The patient tested

positive for COVID-19, although he did not have any respiratory symptoms or any other of the typical symptoms usually associated with the disease.

He underwent a successful percutaneous endovascular aortic repair (Fig 2) on hospital day 2 in less than 30 hours from admission. To reduce the thrombotic complications associated with COVID-19, he received a larger than usual dose of heparin intraoperatively and was discharged home on postoperative day 1 on subcutaneous enoxaparin (Lovenox). His symptoms resolved after the procedure.

## DISCUSSION

COVID-19 has changed the way we approach all aspects of medicine, including vascular surgery. Despite the complete cessation of all elective cases from mid-March to mid-May because of COVID-19, vascular surgeons continued to provide care for patients with a plethora of urgent and emergent vascular conditions. Our patient presented with abdominal pain radiating to the back in the presence of a 5.3-cm AAA, requiring prompt evaluation and treatment.

At the beginning of the outbreak of COVID-19, we were still learning about the virus and its modes of transmission, so we wanted to limit staff exposure to body fluids and pulverized tissue from electrocautery. At our institution, we transitioned early in the pandemic to performing mostly endovascular procedures. Endovascular aortic repair is usually a much faster procedure than open repair in addition to being less risky and our procedure of choice in the setting of an inflammatory AAA. It also results in a much shorter length of stay compared with open repair. Our reasoning was to reduce overall time in the operating room and in the hospital, thus limiting staff exposure. For these reasons, we elected to proceed with an endovascular repair. The procedure was carried out with the least number of people in the room possible. The duration of the procedure was 40 minutes, and it was done totally

---

From the Carolinas Medical Center, Sanger Heart and Vascular Institute, Atrium Health.

Author conflict of interest: F.R.A. is a consultant for Medtronic and is on the speakers bureau.

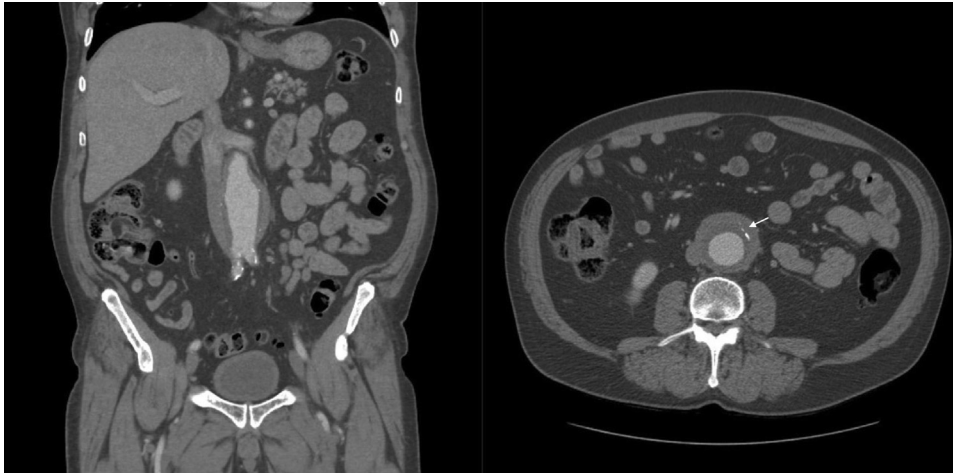
Correspondence: Halim Yammine, MD, Carolinas Medical Center, Sanger Heart and Vascular Institute, 1001 Blythe Blvd, Ste 300, Charlotte, NC 28203 (e-mail: [hyammine@gmail.com](mailto:hyammine@gmail.com)).

The editors and reviewers of this article have no relevant financial relationships to disclose per the Journal policy that requires reviewers to decline review of any manuscript for which they may have a conflict of interest.

2468-4287

© 2020 The Authors. Published by Elsevier Inc. on behalf of Society for Vascular Surgery. This is an open access article under the CC BY-NC-ND license (<http://creativecommons.org/licenses/by-nc-nd/4.0/>).

<https://doi.org/10.1016/j.jvscit.2020.08.016>



**Fig 1.** Coronal and axial computed tomography angiography views showing 5.3-cm inflammatory abdominal aortic aneurysm (AAA). The arrow points to the halo around the aneurysm wall.

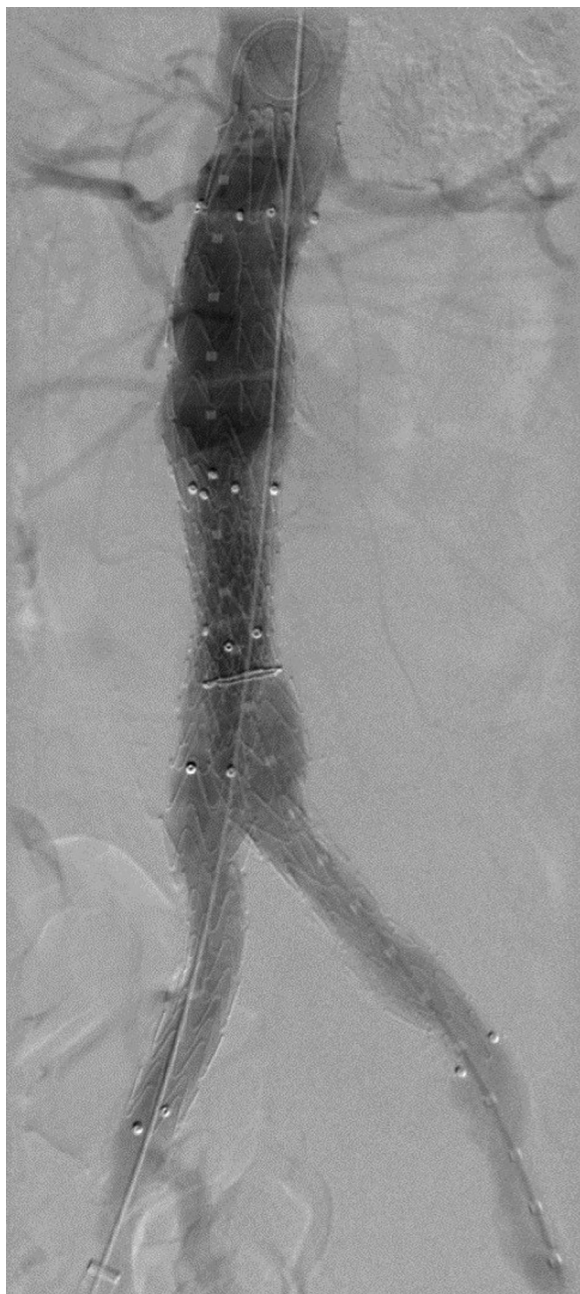percutaneously and under general anesthesia, decreasing the time of exposure to the virus for the entire operating room team. He was also discharged home on postoperative day 1, further limiting his exposure to the team caring for him.

There are two reports in the literature about endovascular aortic repair in ruptured AAA in COVID-19-positive patients, but neither involved inflammatory AAA.<sup>5,6</sup> Our patient's D-dimer level was elevated (2.23  $\mu\text{g}$  FEU/mL), and the C-reactive protein level was mildly elevated (0.9 mg/dL). Although it has not previously been described, we wonder whether the inflammation associated with this patient's AAA was due to the virus as COVID-19 has been shown to cause inflammation in various other parts of the human body.<sup>7,8</sup> We encourage people to report on any inflammatory AAAs they have treated in COVID-19 patients to see whether a relationship can be established.

There have been reports linking COVID-19 to arterial and venous thrombosis, some suggesting that the virus may cause excessive inflammation, platelet activation, endothelial dysfunction, or stasis.<sup>3</sup> Others have reported on complement-associated microvascular injuries leading to the thrombosis.<sup>4</sup> In addition, Giacomelli et al<sup>9</sup> reported a case of acute thrombosis of a Dacron aortic prosthetic graft in a patient with severe COVID-19-related pneumonia. Iba et al<sup>1</sup> even suggested thromboembolic prophylaxis in all hospitalized patients with COVID-19. Because of these reports, we elected to give the patient higher than usual doses of heparin intraoperatively and kept the activated clotting time >300 seconds during the case. In addition, we prescribed subcutaneous enoxaparin (40 mg daily) that evening to continue for 14 days after surgery.

Whereas more data are necessary to support the correlation between COVID-19 and arterial and venous thrombosis and the value of prophylactic anticoagulation, we thought that in the presence of multiple reports of increased clotting, it was prudent in this case to take steps to decrease the risk of limb thrombosis. Given the fact that the patient did not have a thrombotic event and the higher risk for bleeding complications with the full dose, we decided on the prophylactic dose. There are no data to support either choice or to help determine the duration of treatment.

Finally, another aspect to consider in dealing with symptomatic or ruptured AAA is the health care worker's safety. These cases are typically emergently transferred to tertiary or quaternary referral centers such as ours, sometimes in the middle of the night. In the case of a ruptured aneurysm, the patient would typically be transferred directly to the operating room, and everyone in the room would be required to wear the appropriate protective equipment including an N95 mask covered by a regular surgical mask, a face shield, and gown and gloves. However, symptomatic aneurysm patients are transferred to the surgical ward if they are stable. Asymptomatic patients are not routinely tested in most emergency departments, possibly increasing the risk of exposure to the virus during such transfers. Our patient was not tested for COVID-19 at the institution where he presented because of lack of typical symptoms, but he tested positive once he arrived at our facility, where we routinely test patients undergoing procedures. Despite wearing of a regular surgical mask and gloves in examining the patient before the test results came back, no face



**Fig 2.** Intraoperative angiogram showing successful endovascular aortic repair and exclusion of aneurysm.

shields or N95 masks were worn, allowing health care workers to potentially have been exposed. The lack of uniform testing across institutions suggests that special

care needs to be taken with emergently transferred patients, including, perhaps, new institutional policies to protect health care workers.

## CONCLUSIONS

Vascular surgeons continue to take care of urgent and emergent conditions during the COVID-19 pandemic, including symptomatic AAA patients. In COVID-19-positive patients, we recommend a total percutaneous endovascular approach when possible and suggest low-dose anticoagulation postoperatively to decrease the risk of limb thrombosis. We also urge health care workers to treat urgent and emergent transfers as though positive and to take all precautions necessary until a test result is available.

## REFERENCES

1. Iba T, Levy JH, Levi M, Connors JM, Thachil J. Coagulopathy of coronavirus disease 2019. *Crit Care Med* 2020;48:1358-64.
2. Connors JM, Levy JH. COVID-19 and its implications for thrombosis and anticoagulation. *Blood* 2020;135:2033-40.
3. Bikdeli B, Madhavan MV, Jimenez D, Chuich T, Dreyfus I, Driggin E, et al. COVID-19 and thrombotic or thromboembolic disease: implications for prevention, antithrombotic therapy, and follow-up. *J Am Coll Cardiol* 2020;75:2950-73.
4. Magro C, Mulvey JJ, Berlin D, Nuovo G, Salvatore S, Harp J, et al. Complement associated microvascular injury and thrombosis in the pathogenesis of severe COVID-19 infection: a report of five cases. *Transl Res* 2020;220:1-13.
5. Shih M, Swearingen B, Rhee R. Ruptured abdominal aortic aneurysm treated with endovascular repair in a patient with active COVID-19 infection during the pandemic. *Ann Vasc Surg* 2020;66:14-7.
6. Rinaldi LF, Marazzi G, Marone EM. Endovascular treatment of a ruptured pararenal abdominal aortic aneurysm in a patient with coronavirus disease-2019: suggestions and case report. *Ann Vasc Surg* 2020;66:18-23.
7. Merad M, Martin JC. Pathological inflammation in patients with COVID-19: a key role for monocytes and macrophages [author correction: *Nat Rev Immunol* 2020;20:448]. *Nat Rev Immunol* 2020;20:355-62.
8. Tay MZ, Poh CM, Rénia L, MacAry PA, Ng LF. The trinity of COVID-19: immunity, inflammation and intervention. *Nat Rev Immunol* 2020;20:363-74.
9. Giacomelli E, Dorigo W, Fargion A, Calugi G, Cianchi G, Pratesi C. Acute thrombosis of an aortic prosthetic graft in a patient with severe COVID-19-related pneumonia. *Ann Vasc Surg* 2020;66:8-10.

Submitted Jun 9, 2020; accepted Aug 12, 2020.