

# Recurrent small bowel obstruction in a 60-year-old celiac patient: a rare entity of a common disease

Ofir Har-Noy<sup>a</sup>, Michal Amitai<sup>b</sup>, Dan Carter<sup>a</sup>

Chaim Sheba Medical Center, Ramat Gan, Israel

## Abstract

A 60-year-old woman with a medical history of celiac disease was evaluated due to recurrent episodes of small bowel obstruction. Upper and lower endoscopies were normal. The small bowel pathology consisted of celiac disease, and the anti-endomysial antibody was positive. Dilatation of small bowel loops was demonstrated on abdominal computed tomography. Further evaluation was conducted using video capsule endoscopy that demonstrated regional narrowing and severe ulceration in the middle of the small bowel. Upper and lower double balloon endoscopies failed to demonstrate the lesion. On explorative laparotomy a small bowel mass in the proximal ileum was excised. Pathology revealed ulcerated, well to moderately differentiated adenocarcinoma without regional nodal involvement. We discuss the etiology and treatment of small bowel carcinoma. This case emphasizes that a high level of suspicion is required in order to diagnose early stage small bowel adenocarcinoma in celiac patients.

**Keywords** Celiac disease, small-bowel adenocarcinoma, small bowel capsule endoscopy

*Ann Gastroenterol 2014; 27 (2): 170-172*

## Introduction

Celiac disease is a common entity in the western world, with reported incidence of close to 1:100. The risk for development of small bowel malignancy is increased in celiac patients, ranging from 1.3 to 3.2 in various studies. Precancerous possible finding is ulcerative jejuno-ileitis, characterized by ulceration and strictures of the small intestine. Adenocarcinoma and enteropathy associated T-cell lymphoma (EATL) are the most common tumors, and the risk for small intestinal adenocarcinoma is 10 fold higher than in the general population. Hereby we report a case of small bowel recurrent partial obstruction in a celiac patient.

## Case report

A 60-year-old woman was referred to our gastroenterology clinic for evaluation of two episodes of abdominal pain and

distention that started 3 months prior to her first presentation. Her abdominal pain was colicky, originated in the left lower quadrant and was followed by vomiting and abdominal distention. Each episode lasted for approximately 2 weeks and resolved spontaneously.

Her past medical history consisted of celiac disease, diagnosed at the age of 10 years, and anxiety. Her medical treatment contained citalopram and tibolone. The patient did not follow a strict gluten-free diet. Her father died at the age of 60 due to colon cancer.

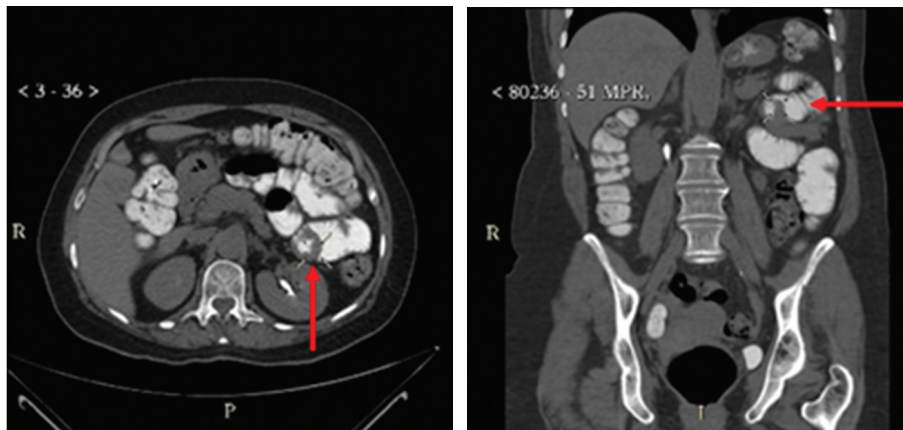
The patient was examined in the emergency department during the second episode. Her physical examination demonstrated left abdominal tenderness without peritoneal signs. Her white blood count was 12.05 K/mcL (4-10.8), with a left shift (absolute neutrophils count of 8.72 K/mcL, normal: 1.8-7.7) and her hemoglobin level was 14.5 g/dL (11.7-15.7). Blood chemistry results were unremarkable, and C-reactive protein level was 8.9 mg/L (normal range 0-5). A computed tomography scan of the abdomen demonstrated dilatation of several small bowel loops, up to 41 mm (Fig. 1). The patient was treated conservatively with gradual resolution of her complaints. After she was referred for our consultation, the patient underwent upper and lower endoscopies, which were normal. Biopsies from the proximal small bowel, taken to diagnose the activity of celiac disease, demonstrated partial shortening of the villi with increased number of intraepithelial lymphocytes, compatible with grade 3 Marsh classification. Anti-endomysial antibody was positive. We decided to further evaluate the small bowel by a video capsule. A single large ulceration, with partial occlusion of the lumen in the middle of the small bowel was demonstrated. Antegrade and retrograde double-balloon enteroscopies failed to reach

Departments of <sup>a</sup>Gastroenterology (Ofir Har-Noy, Dan Carter), Chaim Sheba Medical Center, Ramat Gan; <sup>b</sup>Diagnostic Imaging, Chaim Sheba Medical Center, 52621 Tel Hashomer, affiliated to the Sackler Faculty of Medicine, Tel Aviv University, Tel Aviv (Michal Amitai), Israel

Conflict of Interest: None

Correspondence to: Dan Carter, MD, Department of Gastroenterology, Chaim Sheba Medical Center, Ramat Gan, Israel, Tel.: +972 3 5302197, e-mail: carterd@zahav.net.il

Received 4 September 2013; accepted 29 October 2013



**Figure 1** Abdominal computed tomography. Red arrows: Dilated small bowel loops with thickened wall and post-stenosis collapsed small-bowel loops (left- axial, right-coronal)

the desired region, and the patient was sent for laparotomy. A firm lesion was palpated in the proximal ileum. The lesion was excised, and pathology revealed ulcerated, well to moderately differentiated adenocarcinoma invading the entire thickness of the small bowel wall into the mesentery. Surgical margins were free of tumor cells, and regional nodes were not involved. The tumor was classified as pT3, N0, Mx. The patient was prescribed capecitabine for 6 months. After one year the patient is free of any symptoms or evidence of recurrence.

## Discussion

Small bowel adenocarcinomas (SBAs) constitute only around 2% of all gastrointestinal tumors, despite small bowel rapid mucosal turnover and high carcinogen exposure. However, their poor prognosis warrants early diagnosis and treatment. SBAs constitute 25% of all small bowel tumors and are the most common type of tumor in the small bowel [1]. SBAs usually present with non-specific signs and symptoms such as anemia, abdominal pain, weight loss, gastrointestinal bleeding, nausea and vomiting, bowel obstruction and even perforation [2,3]. The diagnosis of SBA requires a high index of suspicion, since none of the symptoms is specific enough to merit a diagnosis on a clinical basis alone. Genetic risk factors for the development of SBA are familial adenomatous polyposis, hereditary non-polyposis colorectal cancer and Peutz-Jegher's syndrome. The environment also plays a role with increased risk after prolonged consumption of alcohol, tobacco and diet rich in cured and smoked food or red meat. Celiac and Crohn's disease also predispose for SBA development [1,4]. The mechanism of carcinogenesis in patients with celiac disease is unknown [5]. Several possible mechanisms have been considered, such as environmental carcinogens, chronic inflammation, chronic antigenic stimulation, release of pro-inflammatory cytokines, immune surveillance problems and nutritional deficiencies. Multiple mutations were found to be involved in the process

of carcinogenesis in celiac patients. Studies have revealed a link between the aberrant CpG island methylation/ microsatellite instability pathway and celiac disease [6]. A different study [7] linked mismatch repair pathways and adenomatous polyposis coli promoter methylation to celiac disease. As mentioned before, our patient was diagnosed with celiac disease, and did not follow a gluten-free diet. Strict adherence to gluten-free diet was found to be a possible preventing measure against the development of small bowel cancers in a few studies [5]. The time course of SBA development in association with celiac disease is not well defined [8,9]. Therefore, a high index of suspicion is recommended in celiac patients, particularly in subjects with poor compliance to gluten-free diet or poor mucosal response [3].

Celiac disease was found to be present in up to 13% of SBA cases. Moreover, in celiac patients, SBA tends to occur more commonly in the proximal small bowel [3]. No single test has been proven to be the best test of choice for diagnosis of SBA, and usually multiple tests and modalities are needed. The choice of different methods depends on the availability in each institution. Small bowel computed tomography and magnetic resonance studies can be used for imaging of the small bowel. These modalities are non-invasive and can visualize extra luminal findings. However, ionizing radiation and false negative results due to overlapping and under distention of bowel loops are important limitations for their use [1]. Video capsule endoscopy (VCE) can also be used for the diagnosis of SBA, by direct visualization of the small bowel lumen, in a minimally invasive way. Several studies demonstrated that VCE has a better sensitivity than radiological studies [1]. However, VCE is unable to definitively localize the tumor, take biopsies or resect it. Another possible limitation is the risk for capsule retention due to narrowing of the small bowel lumen. However, the removal of the capsule can help identify and treat the causative lesion. Endoscopic techniques used to visualize the small bowel include double or single balloon enteroscopy or intra-operative enteroscopy.

Treatment of SBA is primarily surgical, whether be it exten-

sive or segmental resection of small bowel depends on the location of the tumor [2,10]. Regional lymph-node involvement or existence of metastasis merits the use of adjuvant chemotherapy [1]. Most chemotherapy regimens use different combinations of drugs used for colorectal cancers. The prognosis in SBA cases is usually poor, usually due to late diagnosis. Five-year survival ranges from 15% to 42% [1,2,4]. Patients diagnosed at an earlier stage tend to have a better prognosis.

In conclusion, this case emphasizes that a high level of suspicion is required in order to diagnose early stage SBA in celiac patients. Moreover, the clinician has to strive for the right diagnosis, using various modalities, in light of the influence of early diagnosis on patient's morbidity and mortality.

## References

1. Zouhairi ME, Venner A, Charabaty A, Pishvaian MJ. Small bowel adenocarcinoma. *Curr Treat Options Oncol* 2008;**9**:388-399.
2. Talamonti MS, Goetz LH, Rao S, Joehl RJ. Primary cancers of the small bowel: analysis of prognostic factors and results of surgical management. *Arch Surg* 2002;**137**:564-750; discussion 570-571.
3. Howdle PD, Jalal PK, Holmes GK, Houlston RS. Primary small-bowel malignancy in the UK and its association with coeliac disease. *QJM* 2003;**96**:345-353.
4. Verma D, Stroehlein JR. Adenocarcinoma of the small bowel: a 60-yr perspective derived from M. D. Anderson Cancer Center Tumor Registry. *Am J Gastroenterol* 2006;**101**:1647-1654.
5. Catassi C, Bearzi I, Holmes GK. Association of celiac disease and intestinal lymphomas and other cancers. *Gastroenterology* 2005;**128**(4 Suppl 1):S79-S86.
6. Bergmann F, Singh S, Michel S, et al. Small bowel adenocarcinomas in celiac disease follow the CIM-MSI pathway. *Oncol Rep* 2010;**24**:1535-1539.
7. Diosdado B, Buffart TE, Watkins R, et al. High-resolution array comparative genomic hybridization in sporadic and celiac disease-related small bowel adenocarcinomas. *Clin Cancer Res* 2010;**16**:1391-1401.
8. Elfström P, Granath F, Ye W, Ludvigsson JF. Low risk of gastrointestinal cancer among patients with celiac disease, inflammation, or latent celiac disease. *Clin Gastroenterol Hepatol* 2012;**10**:30-36.
9. Mukherjee R, Kelly CP, Leffler DA. Gastrointestinal cancer in celiac disease: "the first days are the hardest days, don't you worry anymore?". *Clin Gastroenterol Hepatol* 2012;**10**:4-6.
10. Coco C, Rizzo G, Manno A, Mattana C, Verbo A. Surgical treatment of small bowel neoplasms. *Eur Rev Med Pharmacol Sci* 2010;**14**:327-333.