

# Catastrophic bilateral sudden sensorineural hearing loss following COVID-19

Michael Edwards, Jameel Muzaffar , Paresh Naik, Christopher Coulson

Department of Otolaryngology,  
University Hospitals Birmingham  
NHS Foundation Trust,  
Birmingham, UK

## Correspondence to

Dr Michael Edwards;  
michael.edwards19@nhs.net

Accepted 25 May 2021

## SUMMARY

Since December 2019, when it was first detected in Wuhan, the SARS-CoV-2 (COVID-19) has spread across the globe. The pandemic has had an unprecedented impact on the global population with >110 million confirmed cases and 2.5 million deaths. The most common initial symptoms of COVID-19 infection are cough, dyspnoea, fever, malaise and anosmia. Severe clinical manifestations include respiratory compromise, pneumonia, organ failure and death. There have been many other less common symptoms as a result of COVID-19 described in the literature, including significant rates of olfactory dysfunction. However, we believe there has been only one other previously documented cases of bilateral hearing loss.

Sudden sensorineural hearing loss is a relatively common presentation seen by otolaryngologists. It is defined as rapid hearing loss,  $\geq 30$  dB occurring over 3 consecutive days in three contiguous sound frequencies. The exact pathological process is yet to be fully characterised, though it is most commonly unilateral and commonly develops shortly following viral infection. Treatment typically consists of glucocorticoid steroids administered orally, via intratympanic injection or a combination of both routes though there are currently no standardised management of these patients.

Bilateral sudden sensorineural hearing loss (SSNHL) is rare, accounting for <2% of all cases. We describe a case of bilateral SSNHL in a 68-year-old patient who presented with profound hearing loss shortly after symptomatic infection with COVID-19, which at the time of publication is the first such case reported in the literature.

## CASE PRESENTATION

A 68-year-old woman presented to her general practitioner with a 3-day history of sudden onset of profound bilateral hearing loss following a high fever and intense bilateral tinnitus the day before. This occurred on a background of recent COVID-19 infection. The patient initially developed high-grade fever and cough 10 days prior to onset of otologic symptoms. This prompted a COVID-19 PCR test on the same day which returned positive. For the period of time between COVID-19 diagnosis and the onset of otologic symptoms, the patient remained clinically healthy.

The patient had a medical history of non-alcoholic fatty liver disease, hypertension, insulin-dependent diabetes mellitus and dyslipidaemia. Their regular medications included aspirin 75 mg once daily, atorvastatin 20 mg once daily, atenolol 50 mg once daily, bendroflumethiazide 2.5 mg

once daily, candesartan 4 mg once daily, humalog insulin 34 units at morning and 24 units at night and metformin 1 g two times a day. They had a pre-COVID-19 audiogram carried out in 2009, which was normal ([figure 1](#)).

On examination, both external auditory canals were healthy and the tympanic membranes were normal. A pure tone audiometry (PTA) found severe-profound sensorineural hearing loss in both ears ([figure 2](#)). An MRI of the internal auditory meati was not offered to this patient in keeping with guidelines published by the National Institute for Health and Care Excellence.<sup>1</sup>

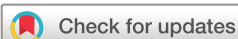They were initially treated with a 7-day course of prednisolone 60 mg once daily and a left-sided intratympanic methylprednisolone (125 mg) injection. PTA was repeated 3 days later which revealed improvement of the left ear ([figure 3](#)). The decision was made to continue treatment with bilateral intratympanic methylprednisolone injections. Four days following this, further PTA was performed ([figure 4](#)). A third left-sided and second right-sided intratympanic methylprednisolone injection was administered which concluded medical management. The patient returned 1 week later for final audiogram testing ([figure 5](#)). The PTA values are summarised in [table 1](#). This confers a diagnosis of profound bilateral SSNHL.

## TREATMENT

Treatment comprised of both oral and intratympanic steroid administration. At presentation, the patient commenced a 7-day course of 60 mg prednisolone once daily and received a 1 mL left-sided intratympanic methylprednisolone injection (125 mg/mL) which lead to an initial mild improvement in left-sided hearing. Following a total of two right-sided and three left-sided intratympanic steroid injections, serial PTA demonstrated a persistent and profound bilateral SSNHL.

## DISCUSSION

The role of COVID-19 in hearing loss is scarcely documented and poorly understood. There is a considerable amount of on-going research to better characterise SSNHL, which aims to develop both diagnostic and management strategies. A systematic literature review was carried out using the PubMed database. The key words used were ‘coronavirus’, ‘COVID-19’, ‘hearing loss’, ‘sensorineural hearing loss’ and ‘SSNHL’. After the literature was screened, the following resulting publications were fully reviewed: a systematic review, one comparative study and nine case studies.



© BMJ Publishing Group Limited 2021. No commercial re-use. See rights and permissions. Published by BMJ.

**To cite:** Edwards M, Muzaffar J, Naik P, et al. *BMJ Case Rep* 2021;**14**:e243157. doi:10.1136/bcr-2021-243157

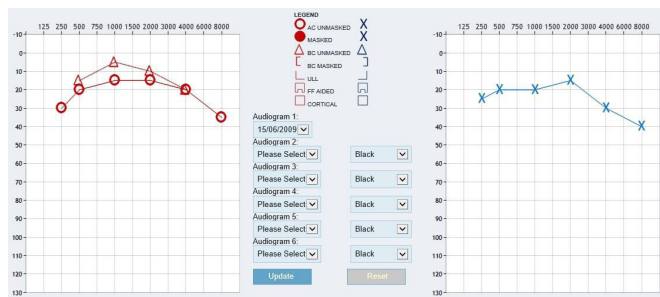


Figure 1 Pre-COVID-19 audiogram.

In November 2020, Maharaj and colleagues<sup>2</sup> published a systematic review of otologic dysfunction in patients with COVID-19, the first and only of its kind to date. They found just four documented cases of SSNHL related to COVID-19, none of which were bilateral in nature. Furthermore, they found two cases of unilateral sensorineural hearing loss and a single case of unilateral conductive hearing loss, the latter of which was presumed to be due to a middle ear effusion secondary to nasopharyngeal infection.

Although we describe the first recorded bilateral case, Koumpa and colleagues<sup>3</sup> reported the first British case of unilateral SSNHL following COVID-19 in September 2020. The 45-year-old man suffered a severe infective course, requiring intubation and ICU support for 30 days. This was complicated further by bilateral pulmonary emboli, ventilator-associated pneumonia, pulmonary hypertension and anaemia. Although they did not receive any ototoxic medications, the patient then reported tinnitus and hearing loss 1 week after discharge from ICU. Following a 1-week course of oral prednisolone, this patient reported subjective improvement, and after three rounds of rescue intratympanic injections of 0.5 mL methylprednisolone (125 mg/mL) they showed no improvement on PTA.

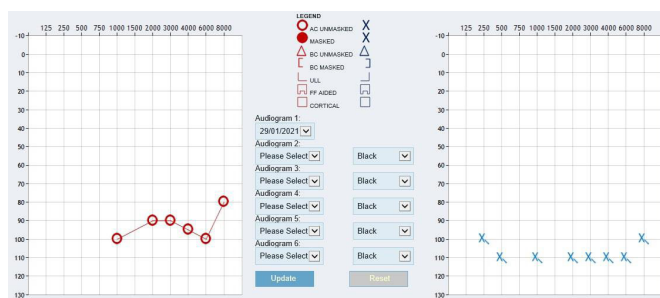


Figure 2 Pretreatment audiogram.

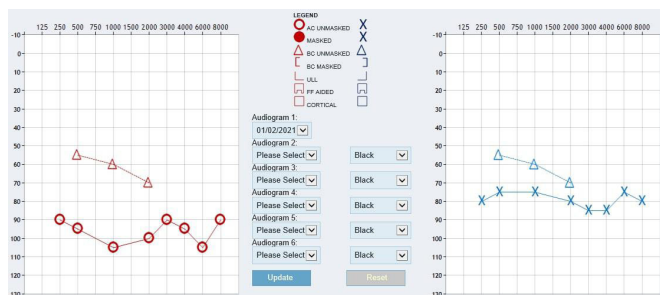


Figure 3 Following oral steroids and left-sided intratympanic steroid injection.

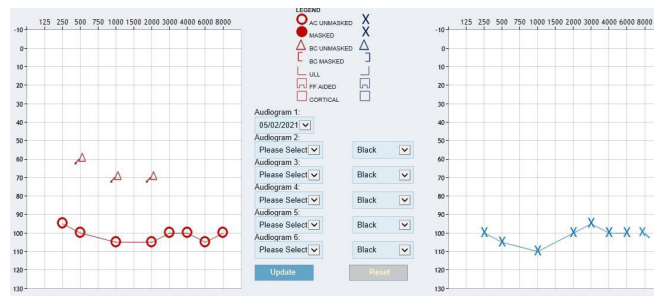


Figure 4 Following second left-sided and initial right-sided intratympanic steroid injection.

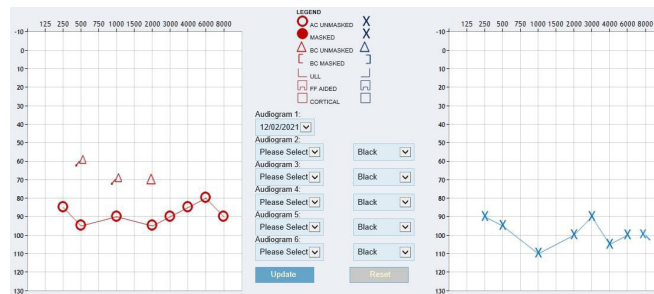


Figure 5 Final audiogram after receiving three left-sided and two right-sided intratympanic steroid injections and 7 days of prednisolone 60 mg once daily.

In January 2021, Chern *et al*<sup>4</sup> described an 18-year-old girl with bilateral SSNHL and associated COVID-19 infection. They were found to have bilateral intralabyrinthine haemorrhage (left more pronounced than right on MRI) 8 weeks after loss of hearing, and tested positive for COVID-19 IgG antibodies 10 weeks after the onset of symptoms. The authors attributed the otologic symptoms to COVID-19-associated coagulopathy and/or direct viral invasion of the labyrinth of cochlear nerve, though the case they report does not feature prodromal fever or tinnitus, and details positive IgG COVID-19 antibodies tested for 10 weeks after initial presentation with new onset loss of taste and olfaction. Both patients received steroids by both oral and intratympanic route, though unlike the case we describe, this patient saw gradual improvement in the right ear. This association between severity on MRI of the left ear versus the right ear, and the clinical course of worsening of the former and improvement of the latter seem to support a coagulopathic rather than direct invasion theory of pathogenesis.

There is new evidence that COVID-19 causes significant decline cochlear hair cell function, as documented by Mustafa.<sup>5</sup> The comparative study of asymptomatic individuals with positive COVID-19 PCR found reduction in sensitivity to higher frequency PTA when compared with healthy controls. Perhaps, more importantly, the amplitude of transient-evoked otoacoustic emissions were significantly reduced in the test group, which possibly represents COVID-19 having a direct and deleterious effect on cochlear hair cells.

Owing to the fact that the disease process of SSNHL remains poorly understood it remains a topic undergoing extensive collaborative research within the otolaryngology community. The SeaSheL National Prospective Cohort Study,<sup>6</sup> supported by INTEGRATE, the UK ENT Trainee Research Network and the National Institute for Health Research Clinical Research Network, is an on-going collaborative project which aims to establish a standardised patient pathway for those presented

**Table 1** Air conduction pure tone audiometry values summarised

	1 kHz (right, left)	2 kHz (right, left)	3 kHz (right, left)	4 kHz (right, left)	6 kHz (right, left)
1. Baseline	15, 20	15, 15	Not recorded	20, 30	Not recorded
2. Pretreatment	100, 110	90, 110	90, 110	95, 110	100, 110
3. Following oral and IT steroid treatment	105, 75	100, 80	90, 85	90, 85	105, 75
4. Following second IT treatment	105, 110	105, 100	100, 95	100, 100	105, 100
5. Following third IT treatment	90, 110	95, 100	90, 90	85, 105	80, 100

IT, intratympanic.

with SSNHL, develop methods to prognosticate those with the disease and to accurately elucidate the morbidity that it confers. Recently, a national prospective randomised controlled trial for treatment options for SSNHL was announced by INTERGRATE,<sup>7</sup> the largest of its kind thus far, which aims to determine the efficacy of steroid treatments given via different routes.

As the evidence of an association between COVID-19 and SSNHL increases, clinicians should consider the presence of hearing changes as part of their clinical assessment of these patients to ensure timely identification and treatment.

### Learning points

- ▶ Profound and permanent bilateral sudden sensorineural hearing loss may occur as a result of COVID-19.
- ▶ There is evidence that COVID-19 may cause cochlear damage.
- ▶ Administration of intratympanic and oral steroids remains the mainstay of treatment, though outcomes are variable.
- ▶ Despite multimodal steroid treatment, this patient with bilateral COVID-19-related hearing loss has had very poor outcomes.
- ▶ The association between COVID-19 and hearing loss is yet to be clearly described, and work is needed to tackle this emerging phenomenon.

**Contributors** ME: contributed as the main author. JM and PN: offered advice and guidance to the transcript. CC: supervised the case.

**Funding** The authors have not declared a specific grant for this research from any funding agency in the public, commercial or not-for-profit sectors.

**Competing interests** None declared.

**Patient consent for publication** Obtained.

**Provenance and peer review** Not commissioned; externally peer reviewed.

This article is made freely available for use in accordance with BMJ's website terms and conditions for the duration of the covid-19 pandemic or until otherwise determined by BMJ. You may use, download and print the article for any lawful, non-commercial purpose (including text and data mining) provided that all copyright notices and trade marks are retained.

### ORCID iD

Jameel Muzaffar <http://orcid.org/0000-0003-3065-0269>

### REFERENCES

- 1 National Institute for Health and Care Excellence. Hearing loss in adults: assessment and management [Internet]. Available: <https://www.nice.org.uk/guidance/ng98> [Accessed 5 Apr 2021].
- 2 Maharaj S, Bello Alvarez M, Mungul S, *et al.* Otologic dysfunction in patients with COVID-19: a systematic review. *Laryngoscope Investig Otolaryngol* 2020;5:1192–6.
- 3 Koumpa FS, Forde CT, Manjaly JG. Sudden irreversible hearing loss post COVID-19. *BMJ Case Rep* 2020;13. doi:10.1136/bcr-2020-238419. [Epub ahead of print: 13 Oct 2020].
- 4 Chern A, Famuyide AO, Moonis G, *et al.* Bilateral sudden sensorineural hearing loss and Intralabyrinthine hemorrhage in a patient with COVID-19. *Otol Neurotol* 2021;42:e10–14.
- 5 Mustafa MWM. Audiological profile of asymptomatic Covid-19 PCR-positive cases. *Am J Otolaryngol* 2020;41:102483.
- 6 Mandavia R, Hannink G, Ahmed MN, *et al.* Prognostic factors for outcomes of idiopathic sudden sensorineural hearing loss: protocol for the SeaSHel national prospective cohort study. *BMJ Open* 2020;10:e038552.
- 7 Sudden Hearing Loss RCT – INTEGRATE [Internet]. Available: <https://entintegrate.co.uk/issnhl-rct> [Accessed 3 Mar 2021].

Copyright 2021 BMJ Publishing Group. All rights reserved. For permission to reuse any of this content visit <https://www.bmj.com/company/products-services/rights-and-licensing/permissions/>  
BMJ Case Report Fellows may re-use this article for personal use and teaching without any further permission.

Become a Fellow of BMJ Case Reports today and you can:

- ▶ Submit as many cases as you like
- ▶ Enjoy fast sympathetic peer review and rapid publication of accepted articles
- ▶ Access all the published articles
- ▶ Re-use any of the published material for personal use and teaching without further permission

### Customer Service

If you have any further queries about your subscription, please contact our customer services team on +44 (0) 207111 1105 or via email at [support@bmj.com](mailto:support@bmj.com).

Visit [casereports.bmj.com](http://casereports.bmj.com) for more articles like this and to become a Fellow