Received: 13 July 2020 | Revised: 16 November 2020 | Accepted: 25 November 2020

DOI: 10.1111/nmo.14062

ORIGINAL ARTICLE

Neurogastroenterology & Motility NGM WILEY

Fasted and fed small bowel motility patterns at cine-MRI in chronic intestinal pseudo-obstruction

Kyra L. van Rijn[1] | Albert J. Bredenoord[2] | André J. P. M. Smout[2] | Gerd Bouma[3] | Jeroen A. W. Tielbeek[1,5] | Karin Horsthuis[4] | Jaap Stoker[1] | Catharina S. de Jonge[1]

[1]Department of Radiology and Nuclear Medicine, Amsterdam Gastroenterology, Endocrinology and Metabolism, Amsterdam UMC, University of Amsterdam, Amsterdam, The Netherlands

[2]Department of Gastroenterology and Hepatology, Amsterdam Gastroenterology, Endocrinology and Metabolism, Amsterdam UMC, University of Amsterdam, Amsterdam, The Netherlands

[3]Department of Gastroenterology and Hepatology, Amsterdam Gastroenterology, Endocrinology and Metabolism, Amsterdam UMC, Vrije Universiteit Amsterdam, Amsterdam, The Netherlands

[4]Department of Radiology and Nuclear Medicine, Amsterdam Gastroenterology, Endocrinology and Metabolism, Amsterdam UMC, Vrije Universiteit Amsterdam, Amsterdam, The Netherlands

[5]Department of Radiology, Spaarne Gasthuis, Haarlem, The Netherlands

Correspondence
Catharina S. de Jonge, Amsterdam UMC, University of Amsterdam, Department of Radiology and Nuclear Medicine, Amsterdam Gastroenterology, Endocrinology and Metabolism, Meibergdreef 9, Amsterdam, The Netherlands.
Email: c.s.dejonge@amsterdamumc.nl

Funding information
Amsterdam Gastroenterology, Endocrinology and Metabolism

Abstract

Background: Chronic intestinal pseudo-obstruction (CIPO) is a severe intestinal motility disorder of which the pathophysiology is largely unknown. This study aimed at gaining insight in fasted and fed small bowel motility in CIPO patients using cine-MRI with caloric stimulation.

Methods: Eight adult patients with manometrically confirmed CIPO were prospectively included. Patients underwent a cine-MRI protocol after an overnight fast, comprising fasting-state scans and scans after ingestion of a meal (Nutridrink, 300 kcal). Small bowel motility was quantified resulting in a motility score in arbitrary units (AU) and visually assessed by three radiologists. Findings were compared with those in 16 healthy volunteers.

Key Results: Motility scores (median, IQR) in CIPO patients were 0.21 (0.15–0.30) in the fasting state and 0.23 (0.15–0.27) directly postprandially. In healthy volunteers, corresponding motility scores were 0.15 (0.13–0.18) and 0.22 (0.19–0.25), respectively. The postprandial change in motility score was +1% (–19 to +21%) in CIPO and +39% (+23 to +50%) in healthy volunteers (p = 0.001*). Visual analysis revealed increased small bowel contractility in four, normal in two, and decreased in two CIPO patients.

Conclusions & Inferences: Surprisingly, we found hyperactive small bowel motility in half of the CIPO patients, suggestive of uncoordinated motility. A wide variation in motility patterns was observed, both higher, lower, and comparable contractility compared with healthy subjects. No clear postprandial activation was seen in patients. Cine-MRI helps to gain insight in this complex disease and can potentially impact treatment decisions in the future.

KEYWORDS
cine magnetic resonance imaging, food challenge, gastrointestinal motility, intestinal pseudo-obstruction, magnetic resonance imaging, small intestine

1 | INTRODUCTION

Chronic intestinal pseudo-obstruction (CIPO) is a severe and rare digestive disease with neurogenic and/or myogenic failure of intestinal motility, characterized by bowel dilatation and abnormal intestinal contractility. Clinical features include abdominal pain and distention, vomiting, and difficulty with oral or enteral nutrient intake, which seriously impairs patients' quality of life and eventually may require chronic total parenteral nutrition.[1–4]

Chronic intestinal pseudo-obstruction is a heterogeneous disease and its pathophysiology is largely unclear, resulting in difficulty with diagnosis, often requiring invasive measurements. Diagnosis is mostly based on clinical symptoms of obstruction, ruling out a mechanical obstruction and trying to understand pathophysiological features by performing antroduodenal manometry.[2,5–8] Manometry is an invasive, burdensome, cumbersome and expensive test that is not widely available.[6–9] For these reasons, there is a demand for a noninvasive, more acceptable, and widely available technique to gain insight in pathophysiology and diagnosis of CIPO.

Cine-MRI has emerged as a noninvasive method for evaluating small bowel motility and previous studies show a decreased contractility and lower global small bowel motility in CIPO patients compared with healthy volunteers.[10–13] However, none of the previous studies focused on gaining insight in pathophysiology by measuring motility patterns in the fasted and fed state, whereas both feeding states can demonstrate disturbances in CIPO patients.[9,14] By evaluating the transition of fasted to fed small bowel motility, insights into the response of the entire small bowel to food can be obtained.

Using cine-MRI, we recently developed a clinically practical caloric stimulation test (food challenge) for small bowel motility using a small-volume test meal with high-caloric density.[15] We hypothesized that in CIPO patients motility in the fasted and fed state is lower compared with healthy volunteers and postprandial activation is decreased. Measurement with cine-MRI has the potential to gain insight in pathophysiology of this complex disease and to play a role in diagnosis in the future. Hence, the aim of this study was to use cine-MRI and caloric stimulation to gain insight in fasted and fed small bowel motility patterns of CIPO patients.

Keypoints

- Small intestinal motor activity in CIPO patients is variable in the fasted and fed state, ranging from decreased to increased compared with healthy volunteers.
- No clear postprandial activation is observed in CIPO patients.
- Cine-MRI helps to gain insight in this complex disease and can potentially impact treatment decisions in the future.

2 | MATERIALS AND METHODS

2.1 | Ethical

Ethical approval was obtained at the Institutional Review Board at Amsterdam UMC, location Meibergdreef (2018_059 and 2015_259). All included subjects gave written informed consent prior to inclusion.

2.2 | Population

Nine patients, previously diagnosed with CIPO based on clinical symptoms of intestinal obstruction, radiologically dilated bowel loops and typical findings at antroduodenal manometry were included prospectively. Manometry was deemed compatible with a neuropathic CIPO if there was an abnormal propagation of phase 3 of the migrating motor complex (MMC) and a myopathic CIPO in case of an abnormally low contraction amplitude or a combination of these two.[5] Data gathered from 16 healthy volunteers included in a previous study[15] were used to compare the CIPO patients' data with normal findings. Exclusion criteria for both groups were unable to give informed consent and contra-indications for MRI. For healthy volunteers, a history of abdominal surgery, gastrointestinal diseases, or current gastrointestinal symptoms were also exclusion criteria.

2.3 | Study design

All CIPO patients underwent a cine-MRI scanning protocol after an overnight fast and received a stimulus in the form of a 300-kcal, 200-ml liquid test meal (Nutridrink juice style, apple flavor, Nutricia, Zoetermeer, The Netherlands). The meal contained per 100 ml: energy 150 kcal, protein 3.9 g, carbohydrate 33.5 g, and fat 0 g. This meal was also given to the included healthy volunteers, in whom it was well tolerated and stimulated motility.[15] Because one CIPO patient had an aversion to the taste of this test meal, in this patient it was substituted by a 278-kcal, 230-ml drink (Milkshake, vanilla flavor, Desira, Molkerei Gropper GmbH & Co. KG, Bissingen, Germany). This meal contained per 100 ml: energy 120 kcal, protein 3.6 g, carbohydrate 14 g, and fat 5.5 g. Motility-influencing medications (including prokinetics, antibiotics, and analgesics) were stopped 48 h before the scan.

2.4 | MRI protocol

In CIPO patients, two MRI scans in the fasted state were performed, with an interval of 10 min between scans. This time period was chosen to possibly take into account the phases of the migrating motor complex[16] while maintaining a scanning protocol with reasonable length. Subsequently patients ingested the test meal via a straw while lying supine in the MRI scanner. After ingestion of the meal, patients underwent three postprandial scans: one directly after

finishing, one approximately 10 minutes and one 20 minutes after the test meal. The healthy volunteers underwent a similar scanning protocol (one fasted scan, one scan directly postprandial and one 20 minutes postprandial). In CIPO patients, scans were made at two additional time points to obtain extra information but these were not used in further comparisons with healthy volunteers.

All scans were performed on a 3 T MRI scanner (Ingenia, Philips, Best, the Netherlands) in supine position. No bowel preparation was used. An anterior coil covering the abdomen was used and a posterior coil in the table. After anatomical planning sequences, a coronal dynamic single slice 2D balanced fast-field echo (bFFE) sequence captured small bowel motility during a 20-second breath-hold. Scan parameters in CIPO patients were TE/TR: 1.13/2.27 ms, flip angle: 20°, FOV: 400 × 400 mm (FH ×LR), slice thickness 10 mm, spatial resolution: 1.8. × 1.8 x 10 mm, and temporal resolution: 2 frames per second (fps). Scans parameters in healthy volunteers were TE/TR: 0.89/1.90 ms, flip angle: 20°, FOV: 400 × 400 mm (FH × LR), spatial resolution: 2.5 × 2.5 × 10 mm, and temporal resolution: 10 fps. The scans of healthy volunteers were undersampled to a temporal resolution of 2 fps to ensure comparability with patient scans. A 3D coronal bFFE scan was used to plan the dynamic 2D slice in a plane containing the greater part of the small bowel.

2.5 | Quantified motility analysis

Small bowel motility was quantified using a validated post-processing algorithm, GIQuant (Motilent, London, UK). This method is based on measuring displacement using the standard deviation of the Jacobian and results in a single numerical motility score in Arbitrary Units (AU).[17,18] To account for dilated bowel loops, an edge detection algorithm was used on the motility registration reference image (Figure 1). A region of interest (ROI) was drawn around the small bowel on the reference image, and then instead of averaging all pixels within the ROI (as usual), an edge detection algorithm was used to provide a binary mask. This mask was applied to the GIQuant motility map, thereby excluding the binary masks' "zero" values from the analysis, resulting in a final motility map including mainly bowel wall and excluding areas not detected as an edge, which mostly corresponds with (air-filled) bowel lumen. Only the pixels within the final motility map were averaged to calculate the motility score, which provides a specific motility score for the bowel wall rather than the lumen to reduce the average effect of grossly abnormal small bowel diameter. Scans of CIPO patients were analyzed and scans of healthy volunteers were re-analyzed with the described technique. The small bowel was delineated by the study coordinator with >3 years of experience using MATLAB R2019a (The MathWorks, Natick, MA, USA), and delineations were checked by an abdominal radiologist with 25 years' experience.

2.6 | Visual analysis

Visual assessment of cine-MRI scans of CIPO patients at both fasted time points, immediately and 20 minutes after the test meal, was carried out independently and blinded by three abdominal radiologists (1, 6 and 25 years' experience, respectively). Scoring items were drawn up by an experienced abdominal radiologist, a neurogastroenterologist, and the study coordinators based on previous literature[10–12] and global visual assessment. Each cine-MRI of a CIPO patient was assessed in random order, against three random healthy volunteers' scans (as a reference) at the corresponding time point. Visual assessment was comprised out three items: "small bowel motility," scored on a 5-point scale (markedly decreased to markedly increased contractility), "small bowel content," scored on 4-point scale (normal, increased gas, increased fluid, or increased gas and fluid), and maximal luminal diameter measured in cm, with diameters >3 cm interpreted as distension.[19] The 5-point scale for small bowel

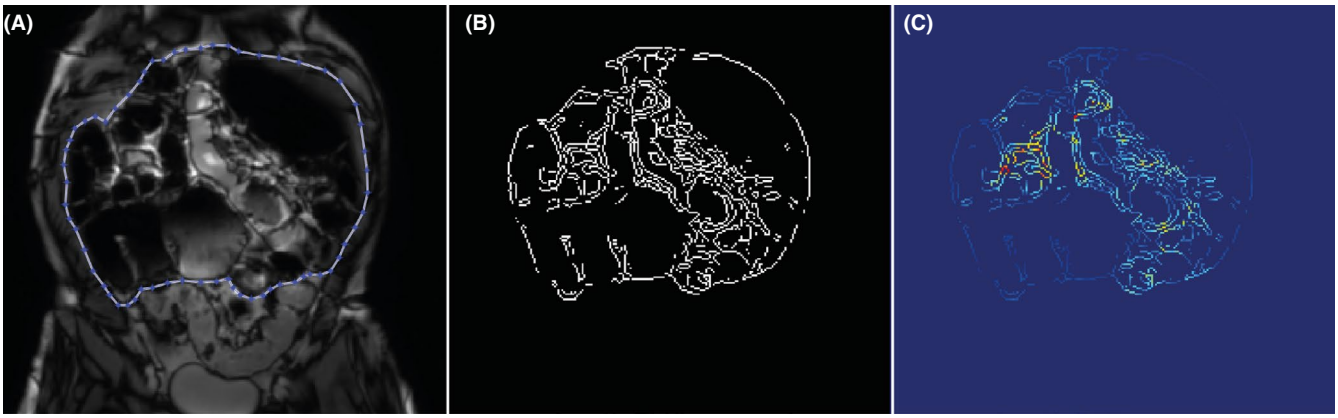

FIGURE 1 Edge detection method. A, shows a reference image of a cine-MRI scan on which the region of interest, the small bowel, is delineated. Within this region of interest edge detection is applied, resulting in the edge detection map (B), all black areas in this map are excluded from the calculation of the motility score. The motility score is calculated from the final motility map (C), with areas of high motility in red and low motility in blue.

TABLE 1 Patient characteristics

Patient	Gender	Age (years)	Manometry pattern	Time since manometry (months)	Underlying cause of CIPO	Treatment[a]
A	Male	73	Myopathic	43	Idiopathic	Pyridostigmine
B	Female	72	Myopathic	24	Scleroderma	Magnesium oxide and TPN
C	Male	68	Neuropathic	69	Idiopathic	None
D	Female	34	Neuropathic	89	MEN IIB	Pyridostigmine, erythromycin, metronidazole/ciprofloxacin, magnesium oxide
E	Male	67	Neuropathic	23	Idiopathic	Erythromycin, amoxicillin/clavulanate
F	Male	66	Myopathic	56	Scleroderma	None
G	Female	25	Neuropathic	65	Idiopathic	None
H	Female	75	Myopathic	9	Idiopathic	TPN, PEG-J

Abbreviations: MEN, Multiple endocrine neoplasia; PEG-J, Percutaneous endoscopic gastrostomy-jejunal tube; TPN, Total parenteral nutrition.
[a]at time of the MRI (motility-influencing medications were temporally stopped 48 h prior to the MRI).

motility was afterward merged to a 3-point scale: "decreased," "normal," and "increased" contractility.

The final score for the categorical variables was determined by the agreement of at least two out of three radiologists. In case, the three observers disagreed a consensus meeting, which was held to determine the final score. For the luminal diameter, the average of three observers was calculated.

2.7 | Cine-MRI and manometry motility patterns

We described the predominant motility pattern at cine-MRI as a hyperactive, a normoactive, or a hypoactive motility pattern. The hyperactive motility pattern was defined quantitatively as a motility score above the healthy interquartile range (IQR) in at least three out of four time points and visually as an increased motility in at least three out of four time points. The normoactive and hypoactive pattern were defined similarly as the hyperactive pattern, but with a motility score within the IQR and visually normal motility for a normoactive pattern and a motility score below the healthy IQR and visually decreased motility for a hypoactive pattern. The motility patterns on cine-MRI were described in relation to the motility patterns from previously obtained manometry measurements.

2.8 | Statistical analysis

Quantified motility was presented as medians with IQRs. Visual scores were presented as frequencies and percentages. To assess the response to the test meal, a percentual effect size was calculated ((postprandial score-baseline score)/baseline score*100) directly postprandially and 20 min postprandially because these time points could be matched with the healthy volunteers. The two fasted measurements in CIPO patients were averaged to establish the baseline. Differences in response to the test meal between CIPO patients and healthy volunteers were compared with the Mann-Whitney *U* test. A *p*-value of < 0.05 was considered significant.

3 | RESULTS

Nine patients with CIPO were included (4 females, median age 68, range 25–75 years) and findings compared with 16 healthy volunteers (6 females, median age 25, range 19–37 years). One patient could not sustain the protocol due to severe back complaints and problems with ingesting the test meal and was excluded. Patient characteristics of the eight included patients are shown in Table 1. In CIPO patients, manometry had been performed median 50 months (range 9–89 months) before inclusion. Patients fasted median 13 h (range 6–19 h) before undergoing the scanning protocol. In all patients, ingestion of the test meal was well tolerated. One patient was unable to drink through a straw because of previous lip surgery and sat up on the scanning table for ingestion of the test meal.

3.1 | Quantified motility

Figure 2 shows the quantified motility scores over time. Fasted small bowel motility in CIPO patients was 0.21 (0.14–0.26) at time point one and 0.18 (0.13–0.21) at time point two. Fed motility in CIPO patients directly, 10 minutes, and 20 minutes after the meal was 0.23 (0.13–0.26), 0.20 (0.13–0.25), and 0.20 (0.15–0.24), respectively.

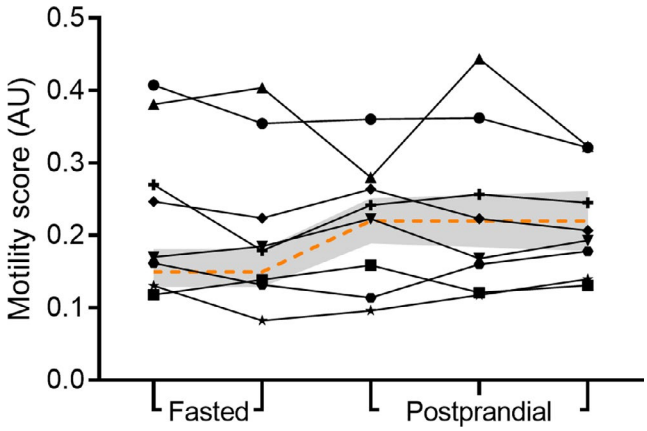

FIGURE 2 Quantified global small bowel motility. Every line represents the motility scores of an individual CIPO patient at two fasted time points and three postprandial time points. The orange dashed line represents the median motility score in healthy volunteers (interquartile range in gray)

In healthy volunteers, the fasted motility score was 0.15 (0.13–0.18) and motility scores directly after the test meal and 20 minutes thereafter were 0.22 (0.19–0.25) and 0.22 (0.18–0.26), respectively.

3.2 | Postprandial activation

In Figure 3, the effect of the test meal on small bowel motility is visualized. The effect size (median [IQR]) in CIPO patients was +1% (−19 to +21%) directly postprandial and +5% (−15 to +18%) 20 min postprandial, being significantly lower than in healthy volunteers (p = 0.001* and p = 0.004*). In healthy volunteers, motility increased +39% (+23 to +50%) directly postprandial and +57% (+29 to +74%) 20 min postprandial.

3.3 | Visual assessment

In total, 32 cine-MRI scans of eight CIPO patients were assessed visually. In 25% (8/32), decreased contractility was observed, in 25% (8/32) normal contractility and in the other 50% (16/32) increased contractility. Small bowel content was normal in 31% (10/32), the remaining scans showed increased gas, increased fluid or both increased gas and fluid in 25% (8/32), 28% (9/32), and 16% (5/32), respectively. In 72% (23/32), the measured diameter was larger than the upper limit for healthy small bowel (3 cm) (Figure 4).

3.4 | Cine-MRI quantified and visual assessment

Figure 5 shows the quantified small bowel motility and visually assessed contractility per patient. In seven patients, the quantitative assessment matched the visual assessment in at least three out of four time points. Three of these seven patients showed a hyperactive pattern (A, C, and D), two a normoactive pattern (E and F) and two a hypoactive pattern (B and H).

The remaining patient (G) showed a hyperactive pattern on visual assessment but a normoactive pattern on quantitative assessment.

A cine-MRI scan of a CIPO patient with hyperactive motility (patient A) and hypoactive motility (patient H) can be found in the supplementary material online Video S1 and Video S2.

3.5 | Manometry vs. cine-MRI assessment

Four patients showed a myopathic motility pattern at the previous antroduodenal manometry measurement, at cine-MRI one of these four patients (A) showed a hyperactive pattern, one (F) a

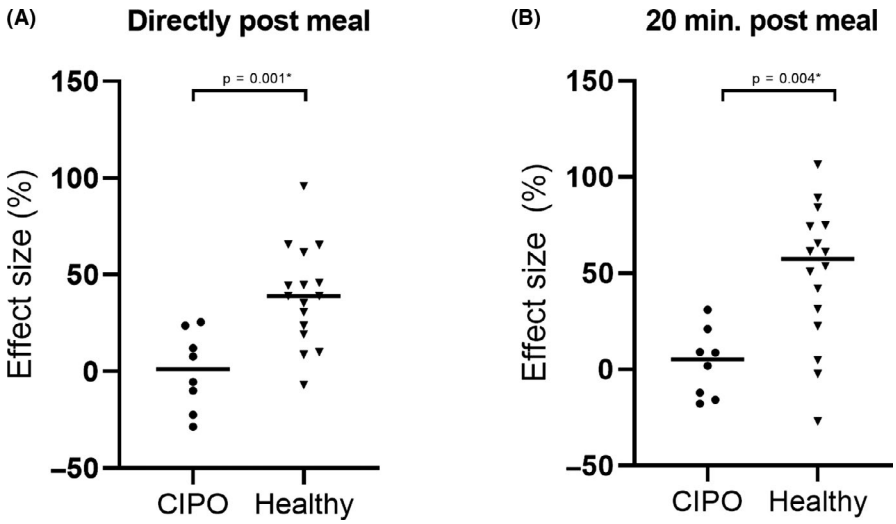

FIGURE 3 Effect of the test meal on small bowel motility. Dot plot (A) representing change between baseline motility and direct postprandial motility, p = 0.001* and (B) representing change between baseline motility and 20 minutes postprandial motility, p = 0.004*. The horizontal lines represent the median.

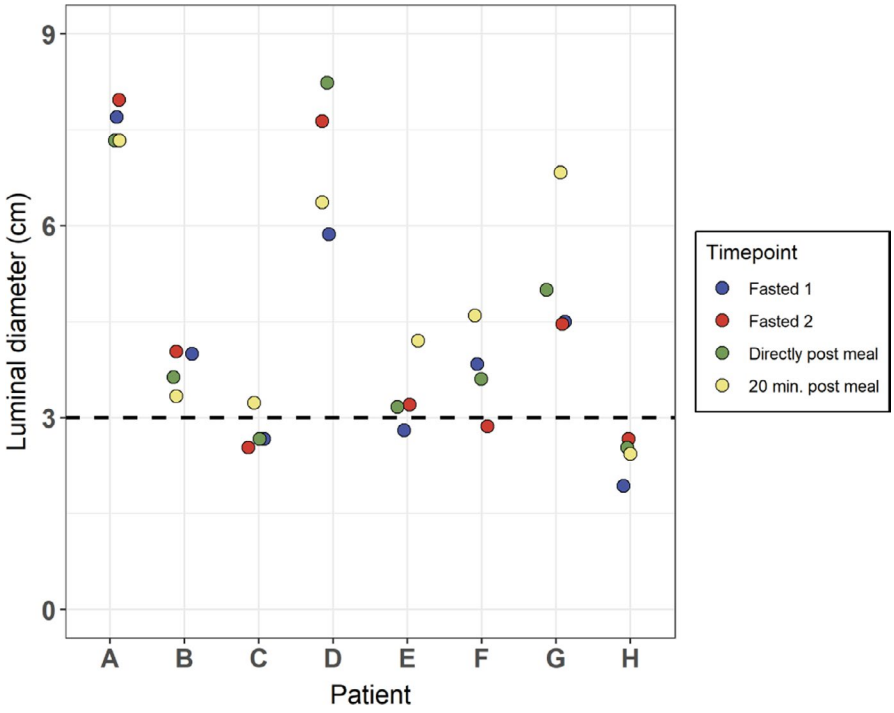

FIGURE 4 Maximal luminal diameter per patient. Small bowel luminal diameter at four time points per patient (A–H) is shown. The dashed line at 3 cm represents the upper limit of normal small bowel luminal diameter; above this line is interpreted as distension.

normoactive pattern and two (B and H) a hypoactive pattern, both quantitatively and visually.

The remaining four patients showed a neuropathic motility pattern at the previous antroduodenal manometry measurement. At cine-MRI, two of these four patients (C and D) showed a hyperactive pattern and one of these four patients (E) showed a normoactive pattern both quantitatively and visually. The remaining patient (G) showed a normoactive pattern at the quantitative measurement but had a hyperactive pattern visually.

4 | DISCUSSION

In this study, using cine-MRI and caloric stimulation, we recorded real-time images of fasting and postprandial bowel motility in CIPO patients with the aim to increase insight into the pathophysiology. A wide variation in intestinal motor activity was observed, ranging from increased, to similar and decreased motility, as compared to healthy subjects. Surprisingly, we found hyperactive small bowel motility in half of the CIPO patients. Since transit is delayed rather than accelerated in CIPO, this is suggestive of uncoordinated motility. Also, a decreased postprandial activation of small bowel motility was observed in CIPO patients after a caloric stimulus compared with healthy volunteers.

Cine-MRI in different physiological states provides novel insight in bowel motility of CIPO patients. Our finding of hyperactive small bowel motility is not in agreement with previous studies using cine-MRI in CIPO.[10–12] Ohkubo et al. observed less segmental peristalsis and measured decreased segmental contractility in CIPO patients compared with healthy volunteers and irritable bowel syndrome (IBS) patients.[10] In addition, Menys et al. found lower global small bowel motility in CIPO patients compared with healthy volunteers.[11]

One of the explanations for these contradicting results could be the difference in use of oral preparation. Recently, it has been shown that oral mannitol preparation has a prokinetic effect in healthy volunteers.[15] Ohkubo et al[10] used bowel preparation only in control groups and not in CIPO patients. Therefore, in that study nonactivated bowels of CIPO patients were compared with activated bowels of the control groups. This might explain the relatively decreased motility in CIPO patients.

In the study by Menys et al[11] bowel preparation was ingested by both CIPO patients and healthy volunteers. Thus, the measured decreased motility in CIPO patients indicates a reduced capability to activate motility. Successful ingestion of the total volume of the mannitol solution was not reported, however, and results may have been influenced by incomplete bowel preparation, and hence less stimulation, in a subgroup of patients. Furthermore, the quantification technique used in that study was partly the same as used in our study, but edge detection was not yet available, which might have resulted in an erroneously low motility score in patients with severely distended bowels. The differences between the results of our study and previously reported findings highlight the complexity of the disease and reflect the influence of (patho) physiology on measurement and interpretation of intestinal motility patterns. To move forward with this technique in diseased populations, it is of great importance that we use standardized techniques across the field. The use of feeding instead of oral bowel preparation has the

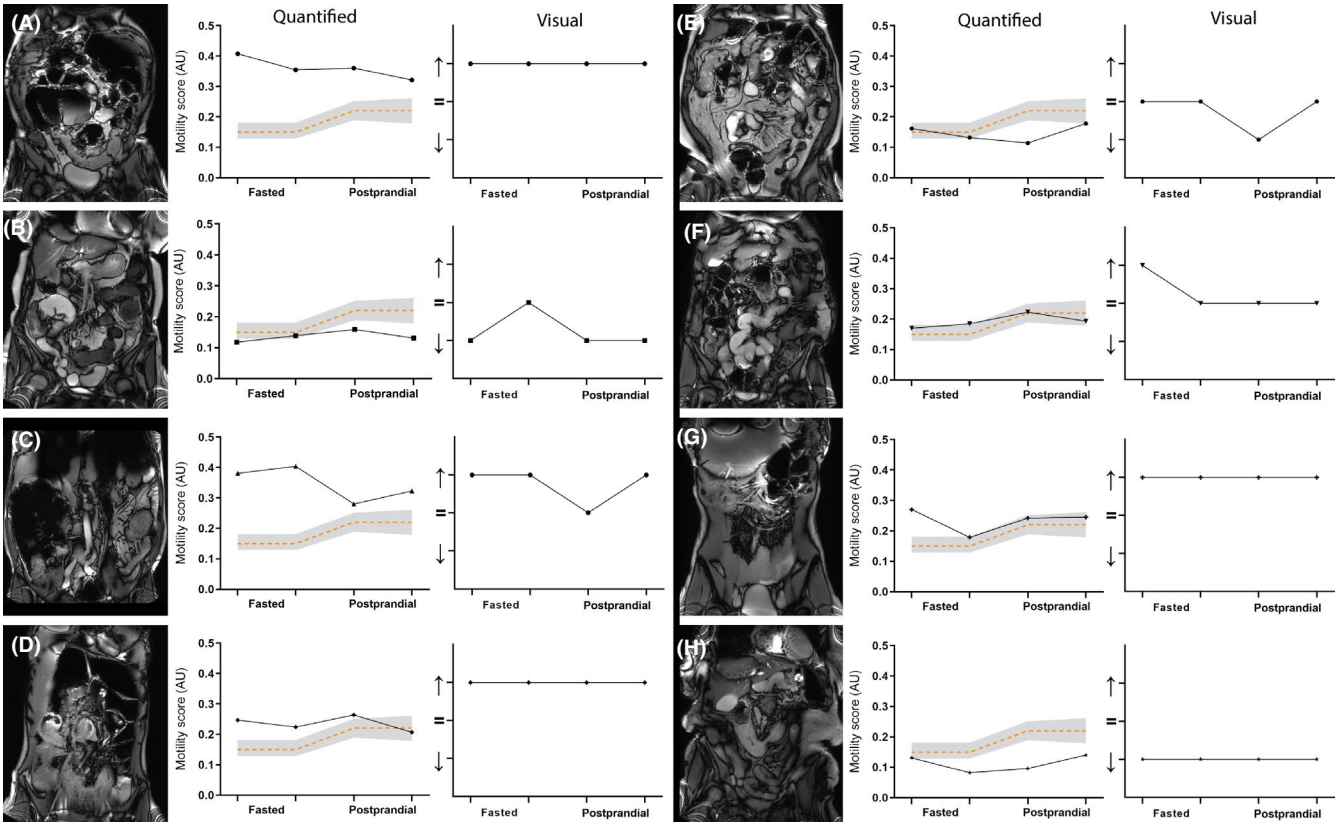

FIGURE 5 Quantified and visually assessed small bowel motility per CIPO patient. For patients A–H, a MRI slice is shown and graphs with quantified and visual motility assessment at four time points. The left graph shows the quantified motility scores and the orange dashed line represents the median motility in healthy volunteers with the interquartile range in gray. The right graph shows the visually assessed small bowel motility, with the upwards arrow on the y-axis representing increased motility and vice versa.

benefit of being more tolerable to participants and is therefore more likely to be used successfully.

In our study, the caloric stimulus induced a significantly lower effect on motility in CIPO patients than in healthy volunteers, indicating an impaired response to food. Thus far, the absence of a normal transition from fasted to postprandial motility in CIPO patients was assessed with manometry,[9,14] and this study is the first in which this abnormality was demonstrated with MRI. The use of a small-volume, liquid meal as a clinical diagnostic test is appealing since it is easy to use and well tolerated.[15] MRI assessment of the motility pattern at baseline in combination with an impaired response to food could be valuable for diagnosis of CIPO.

Furthermore, the clearly distinguishable intestinal motor patterns detectable with cine-MRI, both visually and quantitatively, can potentially play a role in the management of CIPO. The observed visual patterns might be relevant for decision-making in treatment, for example, in the selection of drug treatment. Treatment with prokinetics in hyperactive bowel motility seems paradoxical, whereas logical in patients with a hypoactive motility pattern. Interestingly, of the four patients with visually increased motility, three showed the most dilated bowels of all eight CIPO patients, suggesting that there might be a relation between increased air content and increased motility. Moreover, an added value of the quantification technique is that it allows detection of more subtle changes in motility, which can support treatment monitoring. The simple way of visualizing motility patterns show that this tool is clinically useful in assessment of motility patterns and support clinical implementation.

Cine-MRI has clear advantages toward antroduodenal manometry, which is the current reference standard for small bowel motility measurements. Cine-MRI is noninvasive and widely available and has the ability to visualize the entire small bowel. We used antroduodenal manometry as an inclusion criterion to ascertain the presence of enteric dysmotility; in addition, it provided us with knowledge on the motility patterns. We would expect a hypo- or normoactive motility pattern at cine-MRI to match myopathic CIPO and a hyperactive pattern to match neuropathic CIPO. This assumption is valid in six out of eight patients if we compare manometry with the visual assessment on cine-MRI. If we look at the other two patients, one showed a myopathic pattern at manometry but a hyperactive pattern at MRI, possibly a result of severe bowel dilatation resulting in incomplete contractions and low amplitudes at manometry. The other patient had a neuropathic pattern at manometry but no clear abnormalities at MRI and symptoms had dissolved with treatment.

The time frame during which intestinal motility is recorded with cine-MRI is much shorter than what is customary in antroduodenal manometry; nevertheless, our results show that cine-MRI captures clear visual motility patterns. Therefore, it is likely that

this MRI technique can be used as a tool that provides useful information on motility patterns that may help in the management of CIPO patients.

The acquisition and post-processing techniques used in our study affected the resulting measurements. For example, since motility was assessed on 2D cine-MRI slices, global small bowel motility at that slice location is captured and not motility in the entire bowel volume. In addition, in one patient the quantification technique resulted in a normal motility score while visually motility was increased. Looking at the scan of this patient half of the delineated area (small bowel) consisted of hyperactive bowels while the other half contained bowel loops with less movement. Using the quantification technique, this averages to a global motility score within the healthy range, while visually the pattern is interpreted by the radiologists as predominant hyperactivity. Notable is that the motility scores of the healthy volunteers differed some from the previously published scores,[15] this can be explained by the lowered temporal resolution of the MRI scans (undersampled from 10 to 2 fps) and by the analysis of the motility scans with the newest, CE-marked algorithm of Motilent. In contrast to the research version of the algorithm that was used in the previous study,[15] the CE-marked algorithm includes breathing correction.[17,18,20]

Because CIPO is a rare disease and strict inclusion criteria were applied, including abnormal findings at antroduodenal manometry, the sample size in this study is small. Another limitation is that the median age of the CIPO patients was higher than of the healthy volunteers. It has been reported that there is no effect of age on small bowel motility measured with antroduodenal manometry,[21] but the effect of age on cine-MRI motility measurements remains unclear. However, the extremely abnormal motility observed in CIPO patients and the absence of postprandial response is unlikely to be explained only by an age difference. It would be valuable to evaluate the effect of age on small bowel motility measurements with cine-MRI in the future. Furthermore, in most patients there is a large time difference between the manometry measurement and the cine-MRI measurements which complicates comparison of the two techniques. To our knowledge, no studies on changes over time in manometry motility patterns in CIPO exist, which complicates a statement on if the motility pattern at diagnosis remained present at time of the MRI measurement.

In this study, we found various motility patterns in CIPO patients in the fasted and fed state with an unexpected hyperactive pattern in half of the patients. The clearly distinguishable patterns assessed on cine-MRI increase understanding of physiology in this complex, heterogeneous disease and can potentially play a pivotal role in diagnosis and treatment strategies in the future.

ACKNOWLEDGMENTS

We thank Paul Groot, Sandra van de Berg-Faay, Raschel Snoeks, and the 3T MRI group from the Amsterdam UMC, location Academic Medical Center, for technical support. We thank Alex Menys from Motilent for post-processing analysis of the cine-MRI scans.

DISCLOSURE

This work was presented at NeuroGASTRO 2019 and Digestive Disease Week 2020.[22,23] KLR, AJPMS, GB, JAWT, KH, and CSJ have nothing to declare. JS has a research agreement with Takeda. AJB received research funding from Nutricia, Norgine, and Bayer and received speaker and/or consulting fees from Laborie, Arena, EsoCap, Diversatek, Medtronic, Dr. Falk Pharma, Calypso Biotech, Thelial, Robarts, Reckitt Benckiser, Regeneron, Celgene, Bayer, Norgine, AstraZeneca, Almirall, Arena, and Allergan and holds stocks in Side Sleep Technologies.

AUTHOR CONTRIBUTION

KLR and CSJ conducted the research. KLR, AJB, AJPMS, GB, KH, JS, and CSJ designed the study. JAWT, KH, and JS visually assessed the MRI scans. KLR and CSJ analyzed the data. AJB, AJPMS, and JS contributed insights on the interpretation of the results. KLR and CSJ wrote the manuscript. AJB, AJPMS, GB, JAWT, KH, and JS revised the manuscript. KLR, AJB, AJPMS, GB, JAWT, KH, JS, and CSJ approved the final draft before submission.

FUNDING INFORMATION

This research was partly funded by the Amsterdam Gastroenterology, Endocrinology and Metabolism institute of Amsterdam UMC. The sponsors had no role in the study design, collection, analysis and interpretation of the data, and writing of the report.

ORCID

Kyra L. van Rijn https://orcid.org/0000-0001-7937-5849
Albert J. Bredenoord https://orcid.org/0000-0001-5918-2062
André J. P. M. Smout https://orcid.org/0000-0001-7796-6282
Jaap Stoker https://orcid.org/0000-0002-9822-3784
Catharina S. de Jonge https://orcid.org/0000-0002-3921-0895

REFERENCES

1. Mann SD, Debisnki HS, Kamm MA. Clinical characteristics of chronic idiopathic intestinal pseudo- obstruction in adults. *Gut*. 1997;41(5):675-681.
2. Stanghellini V, Cogliandro RF, De Giorgio R, et al. Natural history of chronic idiopathic intestinal pseudo-obstruction in adults: a single center study. *Clin Gastroenterol Hepatol*. 2005;3(5):449-458. https://doi.org/10.1016/S1542-3565(04)00675-5
3. Amiot A, Joly F, Alves A, Panis Y, Bouhnik Y, Messing B. Long-term outcome of chronic intestinal pseudo-obstruction adult patients requiring home parenteral nutrition. *Am J Gastroenterol*. 2009;104(5):1262-1270. https://doi.org/10.1038/ajg.2009.58
4. Pironi L, Konrad D, Brandt C, et al. Clinical classification of adult patients with chronic intestinal failure due to benign disease: an international multicenter cross-sectional survey. *Clin Nutr*. 2018;37(2):728-738. https://doi.org/10.1016/j.clnu.2017.04.013
5. Stanghellini V, Camilleri M, Malagelada JR. Chronic idiopathic intestinal pseudo-obstruction: clinical and intestinal manometric findings. *Gut*. 1987;28(1):5-12. https://doi.org/10.1136/GUT.28.1.5
6. Knowles CH, Lindberg G, Panza E, De Giorgio R. New perspectives in the diagnosis and management of enteric neuropathies. *Nat Rev Gastroenterol Hepatol*. 2013;10(4):206-218. https://doi.org/10.1038/nrgastro.2013.18

7. Di Nardo G, Di Lorenzo C, Lauro A, et al. Chronic intestinal pseudo-obstruction in children and adults: diagnosis and therapeutic options. *Neurogastroenterol Motil*. 2017;29(1):e12945.
8. Di Nardo G, Karunaratne TB, Frediani S, De Giorgio R. Chronic intestinal pseudo-obstruction: progress in management? *Neurogastroenterol Motil*. 2017;29(12):e13231. https://doi.org/10.1111/nmo.13231
9. Stanghellini V, Cogliandro R, Cogliandro L, et al. Clinical use of manometry for the diagnosis of intestinal motor abnormalities. *Dig Liver Dis*. 2000;32(6):532-541. https://doi.org/10.1016/S1590-8658(00)80011-0
10. Ohkubo H, Kessoku T, Fuyuki A, et al. Assessment of small bowel motility in patients with chronic intestinal pseudo-obstruction using cine-MRI. *Am J Gastroenterol*. 2013;108(7):1130-1139. https://doi.org/10.1038/ajg.2013.57
11. Menys A, Butt S, Emmanuel A, et al. Comparative quantitative assessment of global small bowel motility using magnetic resonance imaging in chronic intestinal pseudo-obstruction and healthy controls Neurogastroenterology & Motility. *Neurogastroenterol Motil*. 2016;28:376-383. https://doi.org/10.1111/nmo.12735
12. Fuyuki A, Ohkubo H, Higurashi T, et al. Clinical importance of cine-MRI assessment of small bowel motility in patients with chronic intestinal pseudo-obstruction: a retrospective study of 33 patients. *J Gastroenterol*. 2016;52(5):577-584. https://doi.org/10.1007/s00535-016-1251-8
13. de Jonge CS, Smout AJPM, Nederveen AJ, Stoker J. Evaluation of gastrointestinal motility with MRI: advances, challenges and opportunities. *Neurogastroenterol Motil*. 2017;2018(30):1-7. https://doi.org/10.1111/nmo.13257
14. Connor FL, Di Lorenzo C. Chronic intestinal pseudo-obstruction: assessment and management. *Gastroenterology*. 2006;130(2):S29-S36. https://doi.org/10.1053/j.gastro.2005.06.081
15. de Jonge CS, Menys A, van Rijn KL, Bredenoord AJ, Nederveen AJ, Stoker J. Detecting the effects of a standardized meal challenge on small bowel motility with MRI in prepared and unprepared bowel. *Neurogastroenterol Motil*. 2019;31(2):e13506. https://doi.org/10.1111/nmo.13506
16. Husebye E. The patterns of small bowel motility: physiology and implications in organic disease and functional disorders. *Neurogastroenterol Motil*. 1999;11(3):141-161. https://doi.org/10.1046/j.1365-2982.1999.00147.x
17. Odille F, Menys A, Ahmed A, Punwani S, Taylor SA, Atkinson D. Quantitative assessment of small bowel motility by nonrigid registration of dynamic MR images. *Magn Reson Med*. 2012;68(3):783-793. https://doi.org/10.1002/mrm.23298
18. Menys A, Taylor SA, Emmanuel A, et al. Global small bowel motility: assessment with dynamic MR imaging. *Radiology*. 2013;269(2):443-450. https://doi.org/10.1148/radiol.13130151
19. Cronin CG, Delappe E, Lohan DG, Roche C, Murphy JM. Normal small bowel wall characteristics on MR enterography. *Eur J Radiol*. 2010;75(2):207-211. https://doi.org/10.1016/j.ejrad.2009.04.066
20. Menys A, Hamy V, Makanyanga J, et al. Dual registration of abdominal motion for motility assessment in free-breathing data sets acquired using dynamic MRI. *Phys Med Biol*. 2014;59(16):4603-4619. https://doi.org/10.1088/0031-9155/59/16/4603
21. Fich A, Camilleri M, Phillips SF. Effect of age on human gastric and small bowel motility. *J Clin Gastroenterol*. 1989;11(4):416-420.
22. van Rijn KL, de Jonge CS, Bouma G, Horsthuis K, Bredenoord AJ, Stoker J. Abstracts NeuroGASTRO 2019–202 assessment of small bowel motility in chronic intestinal pseudo-obstruction using caloric stimulation and dynamic MRI. *Neurogastroenterol Motil*. 2019;31(S4):e13671. https://doi.org/10.1111/nmo.13671
23. van Rijn KL, Bredenoord A, Bouma G, et al. 943 assessment of small bowel motility in chronic intestinal pseudo-obstruction using caloric stimulation and cine-Mri. *Gastroenterology*. 2020;158(6):S-191. https://doi.org/10.1016/s0016-5085(20)31160-4

SUPPORTING INFORMATION

Additional supporting information may be found online in the Supporting Information section.

How to cite this article: Rijn KL, Bredenoord AJ, Smout AJ, et al. Fasted and fed small bowel motility patterns at cine-MRI in chronic intestinal pseudo-obstruction. *Neurogastroenterology & Motility*. 2021;33:e14062. https://doi.org/10.1111/nmo.14062