



## Original Research

# Assessing Parathyroid Gland Viability and Predicting Postoperative Hypoparathyroidism in Thyroid Surgery: The Utility of Indocyanine Green Angiography

Erman Sobutay, Hakan Cakit, Tarik Terzioglu

Department of General Surgery, Koc Foundation American Hospital, Istanbul, Türkiye

### Abstract

**Objectives:** Postoperative hypoparathyroidism is a common complication following thyroidectomy, with the potential for significant morbidity and cost. While various techniques have been proposed for intraoperative parathyroid gland (PG) identification and preservation, indocyanine green (ICG) angiography has emerged as a promising method. In this retrospective study, patients who underwent total thyroidectomy with or without central neck dissection were evaluated for the utility of ICG angiography in identifying PGs and the correlation of ICG scores with postoperative parathyroid function.

**Methods:** ICG angiography was performed using a standardized protocol, and the degree of PG vascularization was assessed visually. A scoring system was employed based on ICG uptake intensity in PGs, as described in the literature. Pearson's correlation test examined the relationship between the total ICG score and percentage parathyroid hormone (PTH) gradient, postoperative calcium, and PTH levels. In addition, patients with at least one well-vascularized PG were also evaluated.

**Results:** Twenty-two patients were included in the study. Significant positive correlations were found between the total ICG score and postoperative PTH levels ( $r=0.549$ ,  $p=0.008$ ), and a negative correlation with the percentage of PTH gradient ( $r=-0.504$ ,  $p=0.01$ ). However, six patients with well-vascularized PGs on ICG angiography still developed postoperative hypoparathyroidism.

**Conclusion:** ICG angiography offers a potential tool for evaluating PG vascularization during thyroidectomy and predicting the risk of postoperative hypoparathyroidism. However, its application should be used judiciously, and the technique should be improved for PG preservation. Further studies are warranted to better understand its benefits and limitations in thyroid surgery.

**Keywords:** Fluorescence, hypoparathyroidism, ICG, indocyanine green, parathyroid glands, thyroidectomy

Please cite this article as "Sobutay E, Cakit H, Terzioglu T. Assessing Parathyroid Gland Viability and Predicting Postoperative Hypoparathyroidism in Thyroid Surgery: The Utility of Indocyanine Green Angiography. Med Bull Sisli Etfal Hosp 2023;57(4):466–472".

The most frequent complication following thyroidectomy is hypoparathyroidism.<sup>[1]</sup> The likelihood of developing hypoparathyroidism increases in cases involving extensive thyroid resection, central neck dissection, and procedures undertaken for recurrence.<sup>[2,3]</sup> Decreased plasma concentrations of parathyroid hormone (PTH) may lead to the development of hypocalcemia.<sup>[4]</sup> The incidence

of transient hypoparathyroidism has been reported as 6-49%.<sup>[1,5]</sup> However, in some patients, permanent hypoparathyroidism may develop. The literature presents varying percentages, contingent upon the specific study and patient cohort, with recorded rates reaching up to 12.5%.<sup>[1,6,7]</sup> Transient hypoparathyroidism can increase the length of hospital stay and hospitalization costs.<sup>[8]</sup> Moreover, per-

**Address for correspondence:** Erman Sobutay, MD. Department of General Surgery, Koc Foundation American Hospital, Istanbul, Türkiye

**Phone:** +90 535 655 23 55 **E-mail:** drsobutay@gmail.com

**Submitted Date:** September 21, 2023 **Revised Date:** November 20, 2023 **Accepted Date:** December 01, 2023 **Available Online Date:** December 29, 2023

©Copyright 2023 by The Medical Bulletin of Sisli Etfal Hospital - Available online at [www.sislietfaltip.org](http://www.sislietfaltip.org)

**OPEN ACCESS** This is an open access article under the CC BY-NC license (<http://creativecommons.org/licenses/by-nc/4.0/>).



manent hypoparathyroidism can lead to lifelong medication use, with an increased risk of cerebral, vascular, ocular, and renal damage, and other adverse outcomes that may severely impair patients' quality of life.<sup>[2,5,9]</sup>

Despite meticulous surgical techniques and surgeon experience, the parathyroid glands (PG) or their blood supply may be damaged, or glands can be inadvertently resected during procedures.<sup>[10]</sup> Currently, intraoperative detection of PGs is mainly based on visual inspection, depending on surgical experience.<sup>[11]</sup> However, various intraoperative localization techniques have been proposed over the last decades to facilitate PG identification. New fluorescence techniques have been implemented to enable the detection and conservation of PGs during surgery.<sup>[11]</sup> Two potential approaches that can be used include near-infrared autofluorescence imaging and indocyanine green (ICG) fluorescence imaging.<sup>[12-14]</sup>

ICG is a fluorescent contrast agent approved by the Food and Drug Administration and has been utilized since 1956.<sup>[12]</sup> It is widely used in fluorescence imaging to assess tissue perfusion and vascularization in real-time. After ICG is administered by intravenous injection, it circulates in the bloodstream by binding to plasma proteins and is then eliminated from the body by the hepatobiliary system.<sup>[13]</sup> Its half-life is 3-5 minutes, and its elimination is completed within 15-20 minutes.<sup>[15]</sup> ICG emits fluorescence in the near-infrared spectrum when excited with light in the 750-800 nm range.<sup>[16]</sup> This characteristic has facilitated its application in various medical fields, including ophthalmology, colorectal surgery, reconstructive surgery, cholangiography, and lymph node mapping.<sup>[16]</sup>

More recently, ICG has been used to evaluate parathyroid vascularization after thyroid resection.<sup>[17-19]</sup> In a study published in 2016, Vidal Fortuny et al.<sup>[18]</sup> demonstrated the usefulness of ICG angiography in evaluating parathyroid vascularization in patients undergoing total thyroidectomy. In the same year, Zaidi et al.<sup>[17]</sup> and Lavazza et al.<sup>[19]</sup> also published their retrospective studies reporting similar results.

Upon a comprehensive review of the literature, it was predominantly found that a correlation exists between the uptake of ICG and parathyroid function after surgery.<sup>[15]</sup> In a randomized prospective study, it was reported that postoperative hypocalcemia did not develop in any of the 146 patients in whom at least one PG was found to have been well-perfused using ICG angiography.<sup>[20]</sup> On the other hand, Rudin et al.<sup>[21]</sup> found that it took at least two, rather than a single well-perfused PG, to predict postoperative parathyroid function better. In another study, Galvez-Pastor et al.<sup>[22]</sup> showed that a total ICG score of 4 PGs above 3 was a negative predictor for postoperative hypocalcemia.

This study retrospectively reviewed patients who underwent ICG angiography to evaluate PGs during total thyroidectomy at our institution. The study aimed to assess the ability to use ICG angiography to aid in identifying the PGs and investigate whether there was a correlation between ICG angiography patterns and postoperative parathyroid functions.

## Methods

### Study Population

This study was conducted in accordance with the principles of the Declaration of Helsinki. Approval was granted by the local Institutional Review Board (IRB1.088, 2023.274). The medical records of all patients who underwent total thyroidectomy at our institution between July 2022 and July 2023 were retrospectively reviewed. Among patients who underwent intraoperative ICG angiography to evaluate the parathyroid glands (PGs), those in whom all four PGs were identified (taking into account accidentally removed glands) were included in this study. There were no selection criteria for the use of ICG angiography; it was applied during surgery if the technical equipment was available in the operating room.

Patients with concurrent parathyroid disease, a history of previous neck surgery, or those using calcium supplements were excluded from the study. Patients who also underwent central neck dissection during thyroidectomy were not excluded from the study. No patient had a history of allergies or intolerance to ICG, iodine dyes, or renal or hepatic insufficiency.

Patient demographics, surgical indications, preoperative laboratory results, intraoperative findings, surgical video recordings, pathology reports, and postoperative calcium and PTH levels were retrospectively collected.

### Surgical Procedure and ICG Angiography

All surgical procedures were performed by the same senior surgeon with over thirty years of experience in endocrine surgery. Thyroidectomy was performed using a Focus Harmonic scalpel (Ethicon, Cincinnati, OH) to avoid devascularization or inadvertent removal of PGs by standard capsular dissection technique. The energy device was not used when dissecting close to the PGs and the recurrent laryngeal nerves. Routine intra-operative nerve monitoring was used in all operations. Attempts were made to identify four parathyroid glands in orthotopic locations during thyroidectomy. Once the thyroid specimen had been removed, PGs were identified through visual inspection followed by ICG angiography. The thyroidectomy specimen was examined on the operating table for any inadvertently removed

PG before being sent for histopathological examination. PGs that were found to be inadvertently removed were autotransplanted. Nonvascularized glands in ICG angiography were left in place. For patients diagnosed with papillary thyroid carcinoma or suspected thyroid carcinoma on frozen section, central neck dissection was performed after parathyroid assessment to avoid inadvertent PG removal along with the lymph nodes.

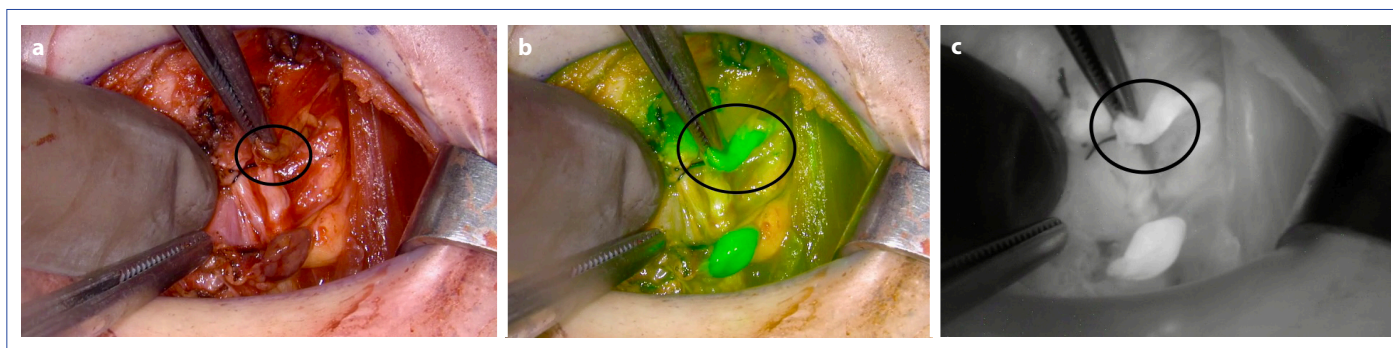
ICG angiography was performed following the same protocol as applied in previous studies.<sup>[23,24]</sup> The optimal total dosage for ICG administration has not been definitively established, and in most studies, the dosage and frequency of injections are determined by the surgeon's preference. Twenty-five milligrams of ICG (Verdye®, Diagnostic Green GmbH, Aschheim-Dornach, Germany) was prepared in 10 ml sterile water, and 3 ml was given to the patient via the peripheral venous route. Afterward, the venous catheter was flushed with a saline solution to obtain rapid images. The maximum daily injection dose is 5 mg per kg; however, even if multiple applications are made during a typical procedure, the ICG used is well below established safety limits.<sup>[18,24]</sup>

Approximately two minutes after injection, ICG-enhanced fluorescence imaging of PGs was obtained using the PIN-POINT fluorescence imaging system and a portable hand-

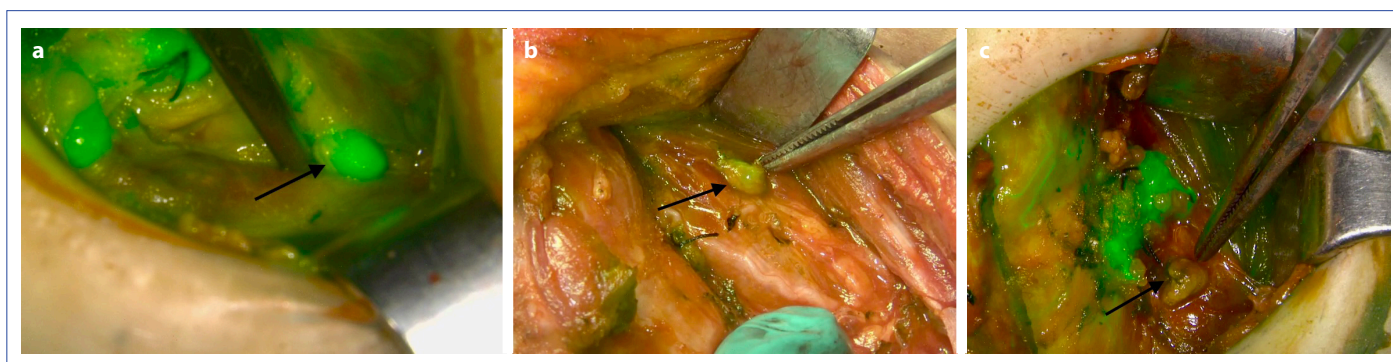
held near-infrared camera (SPY-PHI, Stryker Endoscopy, CA, USA). Normal light images were recorded, and the operating theatre lights were dimmed. Then, normal colorized images with overlay green fluorescence near-infrared view mode of imaging were obtained and recorded (Fig. 1). In patients undergoing central neck dissection, angiography was repeated after lymphadenectomy. All images were recorded in the hospital database.

### Parathyroid Glands Viability and ICG Scoring

Due to the abundant blood supply of the PGs, they are seen more clearly in ICG angiography than in the surrounding tissues. The PGs with good blood supply after thyroidectomy have higher fluorescence levels.<sup>[25]</sup> The authors retrospectively evaluated video footage recorded during surgery. Visual assessment of the PGs was performed using a two-point grading system described by Vidal Fortuny et al.<sup>[18]</sup> Accordingly, the PGs were graded into three categories: 0, nonvascularized (no green color); 1, partially vascularized (pale green color); and 2, well-vascularized (bright green color) (Fig. 2). PGs detected in pathological examination or autotransplanted were scored as 0. Vascularization scores of all PGs were determined, and total scores were calculated for each patient.



**Figure 1.** Representative ICG angiography images: (a) Normal white light view (b) Superposed green fluorescence near-infrared view (c) Black and white near-infrared view. Circles indicate the parathyroid gland.



**Figure 2.** Various degrees of ICG fluorescence of parathyroid glands after completion of thyroidectomy (a) Well-vascularized (bright green, viability score 2) (b) Partially vascularized (pale green, viability score 1) (c) Devascularized (no green color, viability score 0).

## Postoperative Follow-up

All patients' serum calcium and PTH levels were routinely checked on the first day after surgery. Normal reference levels for calcium and PTH in the authors' institution are between 8.6–10.5 mg/dl and 15–65 pg/ml, respectively. A serum calcium level below 8.0 mg/dl was defined as hypocalcemia, and a PTH level below 15 pg/ml was defined as hypoparathyroidism. The percentage of the PTH gradient was calculated as (preoperative PTH – postoperative PTH) / preoperative PTH × 100.

Calcium and vitamin D supplements were started in patients with hypocalcemia or hypoparathyroidism. Biochemical blood parameters were checked regularly until the patients became normocalcemic or until permanent hypoparathyroidism was diagnosed.

## Statistical Analysis

SPSS® software v26.0 (SPSS Inc., Chicago, IL, USA) was used for statistical analysis. Data are presented as mean ± standard deviation (SD) or median and interquartile range (IQR) depending on the distribution. The normality of data distribution was tested with the Shapiro-Wilk test for quantitative variables. Categorical variables are displayed as numbers and percentages (%). Spearman correlation coefficient was used to evaluate the correlation between the total ICG score and percentage PTH gradient, postoperative calcium, and PTH levels. All analyses were two-tailed; a significance level of  $p \leq 0.05$  was determined as statistically significant.

## Results

A total of twenty-two patients who met the criteria were included in the study. The mean age was  $53.5 \pm 11.3$  years, and the majority of patients were female (77%). The mean body mass index was  $26 \pm 4.9$  kg/m<sup>2</sup>. The most common indication for thyroid surgery was thyroid cancer (73%). Preoperative levels of PTH, calcium, and vitamin D were within normal limits for all patients. Clinical data and preoperative biochemical results are presented in Table 1.

The mean operative time was  $94 \pm 22.8$  minutes, with central neck dissection performed in 50% of the patients. On the first day after surgery, the mean PTH value was  $21.3 \pm 13.3$  pg/ml, the mean calcium value was  $8.6 \pm 0.5$  mg/dl, and the mean percentage of PTH gradient was  $55.8 \pm 27.8\%$ . No statistically significant difference was observed between patients who underwent central neck dissection and those who did not in terms of postoperative calcium, PTH values, and total ICG scores. Postoperatively, two patients (9%) had a serum calcium value of  $< 8$  mg/dl, eight patients (36%) had a serum PTH level of  $< 15$  pg/ml, and none exhibited symptoms. Details of perioperative characteristics and

**Table 1.** Baseline characteristics of study population.

Age, years	53.5±11.3
Gender, female (%)	17 (77)
BMI (kg/m <sup>2</sup> )	26±4.9
Indications for surgery	
Thyroid cancer	16 (73)
Multinodular goitre	5 (23)
Graves' disease	1 (4)
Preoperative laboratory	
PTH (pg/ml)*	53.4±19.5
Calcium (mg/dl)*	9.3±0.4
Phosphorus (mg/dl)*	3.5±0.5
Magnesium (mg/dl)†	2 (1.9–2.1)
Vitamin D (ng/ml)*	55.2±18.9

Values in parentheses are percentages, \* values are mean (SD), and † values are median (interquartile range). Abbreviations: BMI: Body mass index; PTH: Parathyroid hormone.

postoperative biochemical results are displayed in Table 2.

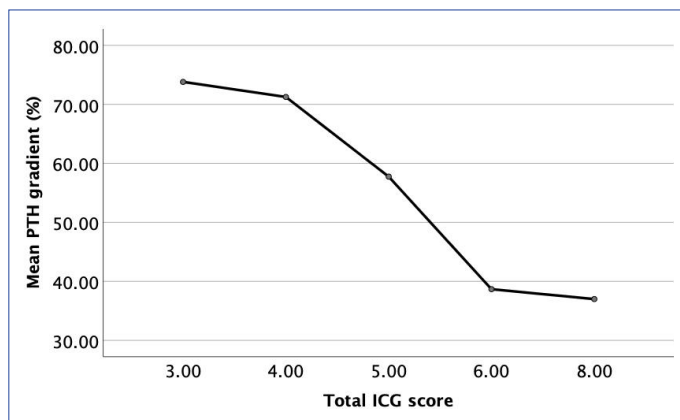
The median total ICG score for the patients was 5.5 (IQR, 3.75–6). In two patients (9%), ICG angiography did not demonstrate at least one well-vascularized PG. Transient hypoparathyroidism was observed in these patients without any symptoms (PTH levels were 5.7 pg/ml and 6.5 pg/ml, and calcium levels were 8.1 mg/dl and 8.4 mg/dl on the first postoperative day). Subsequently, at follow-ups, PTH levels were measured as 20 and 15 pg/ml after seven days, and 24 and 60 pg/ml after one month, respectively. However, among the remaining 20 patients with an ICG score of 2 in at least one PG, calcium levels were below 8 mg/dl in two patients, and PTH levels were below 15 pg/ml in six.

There were significant positive correlations between the total ICG score and postoperative PTH levels ( $r=0.549$ ;  $p=0.008$ ) (Fig. 3) and a negative correlation between the percentage of PTH gradient ( $r=-0.504$ ;  $p=0.01$ ) (Fig. 4). However, no correlation was found between the total ICG

**Table 2.** Perioperative characteristics and postoperative biochemical results

Operative time, minutes	94±22.8
Central lymph node dissection (%)	11 (50)
Postoperative 24th-hour laboratory	
PTH (pg/ml)*	21.3±13.3
Mean PTH gradient (%)*	55.8±27.8
Calcium (mg/dl)*	8.6±0.5
Total ICG score, median (IQR)†	5.5 (3.75–6)
ICG score 2 (at least one well-vascularized gland)	20 (91)

Values in parentheses are percentages, \* values are mean (SD), and † values are median (interquartile range). Abbreviations: PTH: Parathyroid hormone; ICG: Indocyanine green.



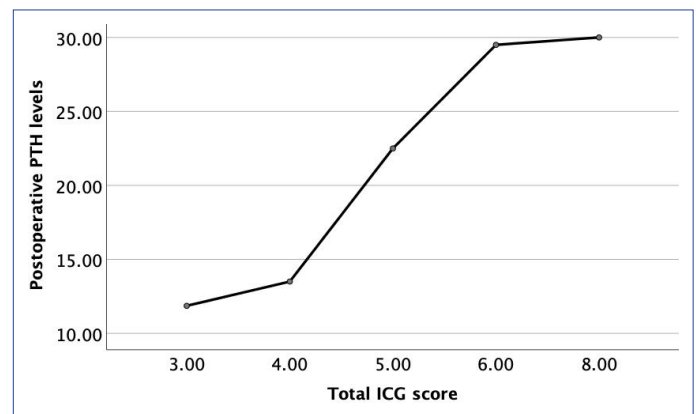
**Figure 3.** The relationship between the mean percentage of the PTH gradient and the total ICG score.

score and postoperative calcium levels ( $r=0.420$ ;  $p=0.052$ ). No perioperative or postoperative complications related to the use of ICG were observed. None of the 22 patients experienced symptomatic hypocalcemia or permanent hypoparathyroidism.

## Discussion

The present study aimed to evaluate the utility of ICG angiography in identifying parathyroid glands (PGs) during total thyroidectomy and investigate whether there was a correlation between ICG angiography patterns and postoperative parathyroid functions. To the best of our knowledge, this study is one of the few conducted in our country that focuses on using ICG angiography for PG detection in thyroid surgery. The ICG scores, both total and individual gland scores, were determined based on ICG uptake intensity of the PGs as previously defined in the literature. Statistical analysis revealed a significant positive correlation between the total ICG score and postoperative PTH levels ( $r=0.549$ ;  $p=0.008$ ) and a negative correlation between the percentage of PTH gradient ( $r=-0.504$ ;  $p=0.01$ ). However, upon individual patient examination, hypoparathyroidism was observed in six patients who had at least one well-vascularized PG, contrary to findings reported in some previous studies.<sup>[20,26]</sup>

Postoperative hypoparathyroidism stands as the most common complication following thyroid surgery and may occur due to inadvertent removal or devascularization of PGs.<sup>[1]</sup> Current methods for evaluating parathyroid function involve measuring calcium and PTH levels after surgery. Many studies have demonstrated that intraoperative ICG angiography can provide immediate assessment of parathyroid function following resection, offering an advantage over these conventional methods.<sup>[27]</sup> Consequently, there has been growing interest in the application of ICG angiog-



**Figure 4.** The relationship between the postoperative PTH levels and the total ICG score.

raphy in thyroid surgery.

Vidal Fortuny et al.<sup>[18]</sup> introduced a scoring system based on the degree of ICG fluorescence in the PGs, grading glands as 0, 1, or 2 according to their vascularization degree. In their system, nonvascularized glands received a score of 0, while well-vascularized glands received 2 points. This scoring system has been utilized in various forms across many studies. In Vidal Fortuny et al.'s<sup>[18]</sup> original publication, they examined 36 patients, and postoperative PTH levels were found to be within the normal range for 30 patients with an ICG score of 2 in at least one PG. Transient hypoparathyroidism developed in two out of six patients with well-vascularized PGs not detected on ICG angiography. Rudin et al.<sup>[21]</sup> studied 86 patients who underwent total thyroidectomy with ICG angiography. In contrast to Vidal Fortuny et al., they found that having at least two glands with an ICG score of 2 correlated with normal PTH levels, predicting parathyroid function with 57% accuracy and 58% sensitivity. However, they noted that this method was not 100% predictive and should not be the sole method for predicting postoperative hypoparathyroidism. Galvez-Pastor et al.<sup>[22]</sup> calculated total scores for the four PGs (4-ICG score) and demonstrated that this score effectively discriminated in predicting postoperative hypocalcemia. In a study by Moreno Llorente et al.,<sup>[26]</sup> which compared the diagnostic accuracy of the one-gland ICG score with the four-gland sum ICG score in 50 patients undergoing thyroidectomy, it was found that the one-gland ICG score had higher diagnostic accuracy in predicting hypocalcemia. Although the majority of literature supports the idea that ICG scores of PGs predict PTH and calcium levels after thyroid surgery, some studies do not align with these findings. Razavi et al.<sup>[28]</sup> found that postoperative calcium levels were normal in 20 patients with a vascularization score of 0, while transient hypocalcemia occurred in 5 patients with high ICG scores in their study involving 43 patients. They concluded

that ICG angiography could not predict postoperative hypocalcemia. In a prospective evaluation of 60 patients, Papavramidis et al.<sup>[29]</sup> reported that ICG scores could not predict PTH and calcium levels after thyroidectomy. However, they noted that ICG angiography was useful in detecting PGs in 98% of cases. The discrepancies in study outcomes may be attributed to the lack of standardized numerical criteria for interpreting ICG angiography images, as the scoring process remains subjective.

In a prospective randomized study, Vidal Fortuny et al.<sup>[20]</sup> concluded that when ICG angiography shows at least one well-vascularized PG, systematic calcium/PTH measurement after total thyroidectomy and systematic calcium supplementation is unnecessary. However, in our study, the postoperative PTH levels of 6 patients with at least one well-vascularized PG detected on ICG angiography were below the normal range. Therefore, although well-vascularized PGs are shown in ICG angiography when low PTH/calcium levels are detected postoperatively, oral calcium replacement is continued in our center even if the patients do not have signs of hypocalcemia.

Most retrospective studies in the literature demonstrate the benefits of ICG angiography. It should not be forgotten that the subjective observation of the surgeon is an important factor in these studies. Contrary to the qualitative scoring systems in the literature, Lang et al.<sup>[30]</sup> quantitatively calculated the light intensity of each PG according to the trachea in patients who underwent thyroidectomy. Accordingly, fluorescent light intensity correlated with postoperative parathyroid function. In addition to the primary benefit of using ICG angiography in thyroidectomy, surgeons' awareness of PG preservation may increase, leading to a more meticulous dissection of the vascular pedicle.

In this study, only PGs that were found to be inadvertently removed were autotransplanted. Nonvascularized glands in ICG angiography were left in place. Rudin et al.<sup>[21]</sup> analyzed the usefulness of ICG angiography in guiding autotransplantation in patients undergoing thyroidectomy. Although more autotransplantation was performed in the group that underwent ICG angiography than in the group that did not (36% vs. 12%,  $p=0.0001$ ), there was no significant difference in postoperative PTH levels.

ICG angiography should increase the number of PGs visualized and preserved during surgery, thereby helping to reduce postoperative hypocalcemia rates. For this reason, applying ICG at the beginning of the surgery may allow visualization of PGs and their vascular pedicles. However, ICG angiography has some limitations in this respect. ICG does not specifically settle in the parathyroid tissue and is also taken up by the thyroid. Therefore, it has been reported

that the thyroid emits fluorescent signals similar to those of PGs, which may interfere with PG visual detection.<sup>[31]</sup> In addition, after dissection, ICG can be used to identify devascularized glands and assist in the decision of autotransplantation.

Our study has several limitations. First, it was retrospective, but since all surgical videos and patient data were properly stored in the hospital database, evaluation could be made without data loss. Second, the number of patients is relatively small. The most significant limitation was the surgeon's subjective interpretations due to the nature of the evaluation of ICG angiography.

## Conclusion

This study investigated the use of ICG angiography in evaluating PG functions during thyroid surgery by examining the relationship between the ICG scores of the PGs and postoperative hypoparathyroidism. Although correlations were found between the total ICG score and postoperative PTH levels and the percentage of PTH gradient, having a single well-vascularized PG did not prevent the development of postoperative hypoparathyroidism. The use of ICG angiography may help the surgeon understand the status of the PGs before dissection and control the vascularization of the PGs during the continuation of the surgery. Combining ICG angiography findings with early postoperative PTH measurement may have an important place in the early prediction of hypocalcemia. However, the limitations of ICG angiography applications in thyroid surgery should be recognized, and this technique should be developed to help protect PGs.

## Disclosures

**Ethics Committee Approval:** The study was approved by the Koc University Institutional Review Board (No: 2023.274.IRB1.088, dated 09.08.2023).

**Peer-review:** Externally peer-reviewed.

**Conflict of Interest:** None declared.

**Authorship Contributions:** Concept – E.S., H.Ç., T.T.; Design – E.S., H.Ç., T.T.; Supervision – E.S., H.Ç., T.T.; Materials – E.S., T.T.; Data collection &/or processing – E.S., H.Ç.; Analysis and/ or interpretation – E.S., H.Ç.; Literature search – E.S., H.Ç.; Writing – E.S.; Critical review – E.S., H.Ç., T.T.

## References

1. Edafe O, Antakia R, Laskar N, Uttley L, Balasubramanian SP. Systematic review and meta-analysis of predictors of post-thyroidectomy hypocalcaemia. *Br J Surg* 2014;101:307–20. [CrossRef]
2. Kakava K, Tournis S, Papadakis G, Karelis I, Stampouloglou P, Kassi E, et al. Postsurgical hypoparathyroidism: a systematic review. *In Vivo* 2016;30:171–9.

3. Unlu MT, Aygun N, Demircioglu ZG, Isgor A, Uludag M. Effects of central neck dissection on complications in differentiated thyroid cancer. *Sisli Etfal Hastan Tip Bul* 2021;55:310–7. [\[CrossRef\]](#)
4. Akgun IE, Unlu MT, Aygun N, Kostek M, Tufan AE, Yanar C, et al. The reality of hypoparathyroidism after thyroidectomy: which risk factors are effective? Single-center study. *Sisli Etfal Hastan Tip Bul* 2022;56:262–9. [\[CrossRef\]](#)
5. Bilezikian JP, Khan A, Potts JT Jr, Brandi ML, Clarke BL, Shoback D, et al. Hypoparathyroidism in the adult: epidemiology, diagnosis, pathophysiology, target-organ involvement, treatment, and challenges for future research. *J Bone Miner Res* 2011;26:2317–37.
6. Lorente-Poch L, Sancho JJ, Muñoz-Nova JL, Sánchez-Velázquez P, Sitges-Serra A. Defining the syndromes of parathyroid failure after total thyroidectomy. *Gland Surg* 2015;4:82–90.
7. Annebäck M, Hedberg J, Almquist M, Stålberg P, Norlén O. Risk of permanent hypoparathyroidism after total thyroidectomy for benign disease: a nationwide population-based cohort study from Sweden. *Ann Surg* 2021;274:e1202–8. [\[CrossRef\]](#)
8. Yazicioğlu MÖ, Yılmaz A, Kocaöz S, Özçağlayan R, Parlak Ö. Risks and prediction of postoperative hypoparathyroidism due to thyroid surgery. *Sci Rep* 2021;11:11876. [\[CrossRef\]](#)
9. Shoback D. Clinical practice. Hypoparathyroidism. *N Engl J Med* Jul 2008;359:391–403. [\[CrossRef\]](#)
10. Sitges-Serra A. Etiology and diagnosis of permanent hypoparathyroidism after total thyroidectomy. *J Clin Med* 2021;10:543.
11. Tjahjono R, Nguyen K, Phung D, Riffat F, Palme CE. Methods of identification of parathyroid glands in thyroid surgery: a literature review. *ANZ J Surg* 2021;91:1711–6. [\[CrossRef\]](#)
12. Demarchi MS, Karenovics W, Bédar B, Triponez F. Near-infrared fluorescent imaging techniques for the detection and preservation of parathyroid glands during endocrine surgery. *Innov Surg Sci* 2021;7:87–98. [\[CrossRef\]](#)
13. Demarchi MS, Karenovics W, Bédar B, Triponez F. Intraoperative autofluorescence and indocyanine green angiography for the detection and preservation of parathyroid glands. *J Clin Med* 2020;9:830. [\[CrossRef\]](#)
14. Barbieri D, Indelicato P, Vinciguerra A, Di Marco F, Formenti AM, Trimarchi M, et al. Autofluorescence and indocyanine green in thyroid surgery: a systematic review and meta-analysis. *Laryngoscope* 2021;131:1683–92. [\[CrossRef\]](#)
15. Jitpratoom P, Anuwong A. The use of ICG enhanced fluorescence for the evaluation of parathyroid gland preservation. *Gland Surg* 2017;6:579–86. [\[CrossRef\]](#)
16. Alander JT, Kaartinen I, Laakso A, Pätilä T, Spillmann T, Tuchin VV, et al. A review of indocyanine green fluorescent imaging in surgery. *Int J Biomed Imaging* 2012;2012:940585. [\[CrossRef\]](#)
17. Zaidi N, Bucak E, Yazici P, Soundararajan S, Okoh A, Yigitbas H, et al. The feasibility of indocyanine green fluorescence imaging for identifying and assessing the perfusion of parathyroid glands during total thyroidectomy. *J Surg Oncol* 2016;113:775–8.
18. Vidal Fortuny J, Belfontali V, Sadowski SM, Karenovics W, Guigard S, Triponez F. Parathyroid gland angiography with indocyanine green fluorescence to predict parathyroid function after thyroid surgery. *Br J Surg* 2016;103:537–43. [\[CrossRef\]](#)
19. Lavazza M, Liu X, Wu C, Anuwong A, Kim HY, Liu R, et al. Indocyanine green-enhanced fluorescence for assessing parathyroid perfusion during thyroidectomy. *Gland Surg* 2016;5:512–21.
20. Vidal Fortuny J, Sadowski SM, Belfontali V, Guigard S, Poncet A, Ris F, et al. Randomized clinical trial of intraoperative parathyroid gland angiography with indocyanine green fluorescence predicting parathyroid function after thyroid surgery. *Br J Surg* 2018;105:350–7. [\[CrossRef\]](#)
21. Rudin AV, McKenzie TJ, Thompson GB, Farley DR, Lyden ML. Evaluation of parathyroid glands with indocyanine green fluorescence angiography after thyroidectomy. *World J Surg* 2019;43:1538–43.
22. Gálvez-Pastor S, Torregrosa NM, Ríos A, Febrero B, González-Costea R, García-López MA, et al. Prediction of hypocalcemia after total thyroidectomy using indocyanine green angiography of parathyroid glands: a simple quantitative scoring system. *Am J Surg* 2019;218:993–9. [\[CrossRef\]](#)
23. Vidal Fortuny J, Karenovics W, Triponez F, Sadowski SM. Intraoperative indocyanine green angiography of the parathyroid gland. *World J Surg* 2016;40:2378–81. [\[CrossRef\]](#)
24. Fanaropoulou NM, Chorti A, Markakis M, Papaioannou M, Michalopoulos A, Papavramidis T. The use of Indocyanine green in endocrine surgery of the neck: a systematic review. *Medicine (Baltimore)* 2019;98:e14765. [\[CrossRef\]](#)
25. Jin H, Dong Q, He Z, Fan J, Liao K, Cui M. Application of a fluorescence imaging system with indocyanine green to protect the parathyroid gland intraoperatively and to predict postoperative parathyroidism. *Adv Ther* 2018;35:2167–75. [\[CrossRef\]](#)
26. Moreno Llorente P, García Barrasa A, Francos Martínez JM, Alberich Prats M, Pascua Solé M. Intraoperative indocyanine green (ICG) angiography of the parathyroids glands in prediction of post-thyroidectomy hypocalcemia: diagnostic accuracy of the ICG score 2 versus the 4-ICG score. *Cir Esp (Engl Ed)* 2022;100:274–80. [\[CrossRef\]](#)
27. Hauck A, Pons A, Abdel-Aziz T. On indocyanine green fluorescence and autofluorescence in thyroid and parathyroid surgery: a scoping systematic review. *Health Sci Rev* 2022;5:100064. [\[CrossRef\]](#)
28. Razavi AC, Ibraheem K, Haddad A, Saparova L, Shalaby H, Abdelgawad M, et al. Efficacy of indocyanine green fluorescence in predicting parathyroid vascularization during thyroid surgery. *Head Neck* 2019;41:3276–81. [\[CrossRef\]](#)
29. Papavramidis TS, Anagnostis P, Chorti A, Pliakos I, Panidis S, Koutsoumparis D, et al. Do near-infrared intra-operative findings obtained using indocyanine green correlate with post-thyroidectomy parathyroid function? The icgpredict study. *Endocr Pract* 2020;26:967–73. [\[CrossRef\]](#)
30. Lang BH, Wong CK, Hung HT, Wong KP, Mak KL, Au KB. Indocyanine green fluorescence angiography for quantitative evaluation of in situ parathyroid gland perfusion and function after total thyroidectomy. *Surgery* 2017;161:87–95. [\[CrossRef\]](#)
31. Kim SW, Lee HS, Lee KD. Intraoperative real-time localization of parathyroid gland with near infrared fluorescence imaging. *Gland Surg* 2017;6:516–24. [\[CrossRef\]](#)