

Primary yolk sac tumor originating from the endometrium

A case report and literature review

Liang Song, MD^{a,b}, Xiaoxia Wei, MD^c, Danqing Wang, MD^{a,b}, Kaixuan Yang, MD^c, Mingrong Qie, MD^{a,b,*}, Rutie Yin, MD^{a,b,*}, Qingli Li, MD^{a,b,*}

Abstract

Rationale: Yolk sac tumors (YSTs) are malignant germ cell tumors that secrete alpha-fetoprotein (AFP). These tumors commonly develop in infants, young children, and young women and often originate in the gonads. Primary endometrial YST is a very rare malignancy, and a primary endometrial YST in the absence of abnormal AFP levels is even rarer.

Patient concerns: A 38-year-old woman presented with the chief complaint of prolonged menstruation and increased menstrual bleeding with a duration of more than 2 months.

Diagnoses: Postoperative pathology confirmed a diagnosis of endometrial YST with metastasis to the greater omentum (stage IVB).

Interventions: The patient underwent a laparoscopic extrafascial hysterectomy, bilateral adnexectomy, pelvic lymphadenectomy, abdominal para-aortic lymphadenectomy, omentectomy, and appendectomy. Additionally, she received 6 courses of multidrug chemotherapy (bleomycin, etoposide, and cisplatin; BEP).

Outcomes: After completing chemotherapy, the patient underwent regular follow-up examinations. No recurrence was noted during a 24-month follow-up period.

Lessons: YST is mainly treated using surgery and chemotherapy, which may spare endocrine functions in young patients. The BEP regimen appears to be an effective postoperative chemotherapy regimen for patients with endometrial YST.

Abbreviations: 5-FU = 5-fluorouracil, Act-D = actinomycin-D, ADM = adriamycin, AFP = alpha-fetoprotein, AWD = alive with disease, BEP = bleomycin–etoposide–cisplatin regimen, BLM = bleomycin, BSO = bilateral salpingo-oophorectomy, CA = carbohydrate antigen, CBDCA = carboplatin, CK = cytokeratin, CEA = carcinoembryonic antigen, CPA = cyclophosphamide, DDP = cisplatin, DOD = dead from the disease, FUDR = 5-fluoro-2-deoxy-β-uridine, HCG = human chorionic gonadotropin, HYS = hysterectomy, LD = lymphadenectomy, LN = lymph node, MTX = methotrexate, ND = not described, NED = no evidence of the disease, OMT = omentectomy, PTX = paclitaxel, TAH = total abdominal hysterectomy, VCR = vincristine, VP16 = etoposide, YST = yolk sac tumor.

Keywords: endodermal sinus tumor, endometrial tumor, endometrium, yolk sac tumor

Editor: N/A.

RY and MQ are co-corresponding authors.

Funding: Health and Family Planning Commission of Sichuan Province (17PJ245).

We obtained written consent from the patient for the publication of this case report.

The authors have no conflicts of interest to disclose.

^a The Department of Obstetrics and Gynecology, West China Second University Hospital of Sichuan University, Chengdu, Sichuan, ^b Key Laboratory of Birth Defects and Related Diseases of Women and Children, Sichuan University, Ministry of Education, ^c Department of Pathology, West China Second University Hospital of Sichuan University, Chengdu, Sichuan, China.

* Correspondence: Qingli Li, The Department of Obstetrics and Gynecology, West China Second University Hospital of Sichuan University, No. 20 The Third Section of South Renmin Road, Chengdu 610041, China (e-mail: liqingli73@163.com).

Copyright © 2019 the Author(s). Published by Wolters Kluwer Health, Inc. This is an open access article distributed under the terms of the Creative Commons Attribution-Non Commercial License 4.0 (CCBY-NC), where it is permissible to download, share, remix, transform, and buildup the work provided it is properly cited. The work cannot be used commercially without permission from the journal.

Medicine (2019) 98:15(e15144)

Received: 2 November 2018 / Received in final form: 22 February 2019 /

Accepted: 14 March 2019

<http://dx.doi.org/10.1097/MD.00000000000015144>

1. Introduction

Yolk sac tumors (YSTs), also known as endodermal sinus tumors, are malignant germ cell tumors that secrete alpha-fetoprotein (AFP). These tumors, which commonly develop in infants, young children, and young women, often originate in the gonads and are distributed along the central axis of the body.^[1] Approximately 20% of female patients develop extra-ovarian YSTs,^[2] and the vagina is the most common site of YST growth in infants and young children.^[3] Primary endometrial YST is a very rare phenomenon, and primary endometrial YST with normal levels of AFP is even rarer. To date, only 1 case of primary endometrial YST has been reported in the literature.^[2] Here, we report the case of a patient with a primary endometrial YST and normal AFP levels and review the related literature.

2. Case report

The patient was a 38-year-old woman of childbearing age with a history of regular menstruation, gravidity 3, and parity 1. She underwent a B-mode ultrasound examination at a local hospital to evaluate the complaint of prolonged menstruation and increased menstrual bleeding of a duration exceeding 2 months. The results of the examination indicated the presence of a lesion

in the intrauterine space. The patient underwent diagnostic curettage, and a pathological examination of the tissue specimen indicated the possibility of sarcoma. Accordingly, the pathological specimen was sent to the Department of Pathology of our hospital, and the pathological report indicated the presence of a mixed-type endometrial adenocarcinoma (approximately 80% clear cell carcinoma and 20% poorly differentiated endometrioid adenocarcinoma) accompanied by mucinous adenocarcinoma.

A pelvic examination revealed uterine enlargement at approximately 50 days after conception. The uterine surface was soft and smooth without tenderness, and no other abnormalities were observed. Tumor marker evaluations revealed a high level of carbohydrate antigen (CA) 125 (58.5 U/mL), and normal levels of AFP, carcinoembryonic antigen (CEA), CA199, and human chorionic gonadotropin (HCG). A magnetic resonance imaging examination indicated a slight expansion of the uterine cavity and a patchy area of abnormal signal intensity suggestive of uterine bleeding. The left obturator lymph node, which was approximately 0.8 cm × 0.5 cm in size, was relatively larger than the right node, and no other abnormalities were found. The patient was diagnosed with mixed-type endometrial adenocarcinoma.

On December 9, 2016, the patient underwent a laparoscopic extrafascial hysterectomy, bilateral adnexectomy, pelvic lymphadenectomy, abdominal para-aortic lymphadenectomy, omentectomy, and appendectomy. Intraoperatively, the uterus remained enlarged at approximately 50 days after pregnancy, and a 0.3-cm nodule was observed on the left side of the peritoneal reflection of the bladder. No abnormalities were observed in the bilateral ovaries or oviducts, and no enlargement or hardening of the pelvic and abdominal para-aortic lymph nodes was observed. However, scattered hard nodules (size: 0.5–0.8 cm) were observed in the greater omentum. Furthermore, a

postoperative uterus evaluation observed hard nodules (size 2.5 cm × 1.2 cm) in the left posterior wall of the uterine cavity. Postoperative pathology revealed a stage IVB endometrial YST with tumor metastasis to the greater omentum.

Postoperatively, the patient was administered 6 courses of chemotherapy with the bleomycin–etoposide–cisplatin (BEP) regimen. Although she developed adverse reactions, such as grade IV neutropenia and vomiting, during chemotherapy, these symptoms improved after treatment. She was followed up regularly for 24 months after completing chemotherapy, and no tumor recurrence occurred during this period.

3. Pathological findings

The endometrial YST (Fig. 1) invaded to a depth corresponding to less than half of the full muscularis layer; specifically, only a thin layer of tissue had been infiltrated. In the muscle wall, tumor thrombosis was observed in a vessel adjacent to the tumor, and the tumor itself had metastasized to the greater omentum (Fig. 2). No metastasis was found elsewhere. Immunohistochemistry yielded the following positive results: cytokeratin (CK)18+++ , SALL-4+++ (Fig. 3), multifocal AFP+, multifocal CD56+, unifocal CD15+, unifocal P16+, P-CK+++ , glypican 3+++ (Fig. 4), unifocal CEA+, β-catenin (membrane)++ , P53++ , Ki67 positivity rate of approximately 90%, Mutl homolog (MLH)1+++ , MutS protein homolog (MSH)2++ , PMS2++ (PMS2 Postmeiotic Segregation), and MSH6+++ . Additionally, the tumor yielded negative results for estrogen receptor (Fig. 5), progesterone receptor (Fig. 6), OCT3/4 (octamer-binding transcription factor), CK7X3, EMAX3 (Mepithelial Membrane Antigen), CD30, CD117, CRX2, WT-1X2 (Wilm's tumor), VIMX2 (Vimentin), CD146, Melan-A, HMB45 (Human Melanoma Black), human placental lactogen, HCG, synaptophysin, cyclin D1, napsin-AX2, CD10, and CK5/6.

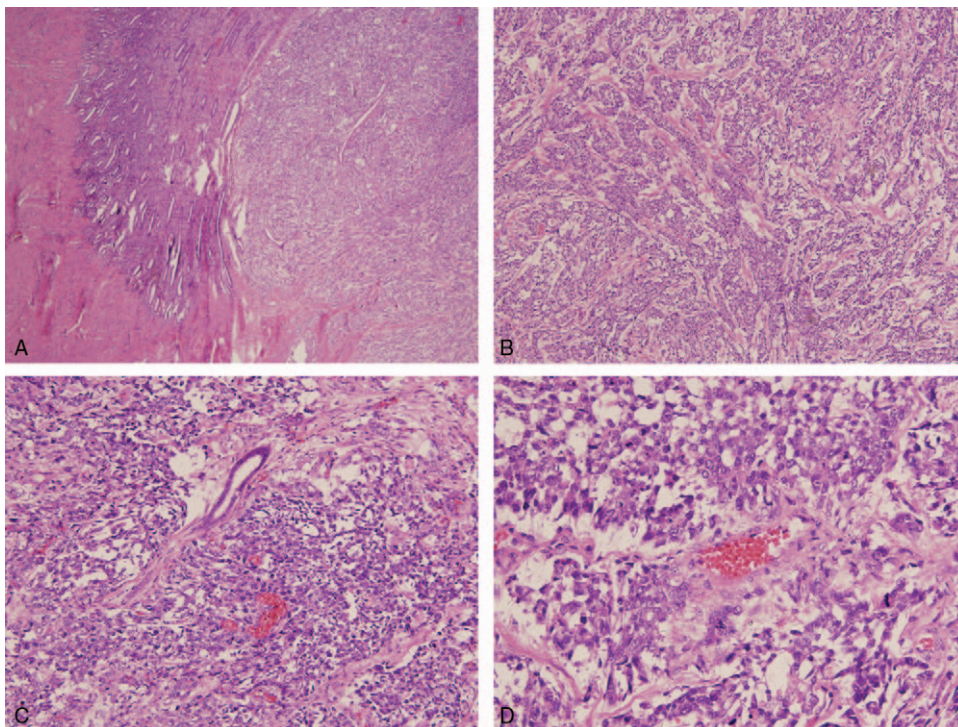


Figure 1. Images of an endometrial yolk sac tumor. A, 40×; B, 100×; C, 200×; and D, 400× magnification.

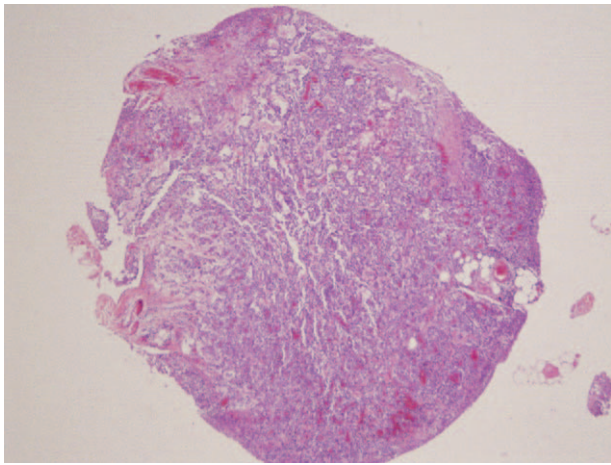


Figure 2. Infiltration by the yolk sac tumor into the greater omentum.

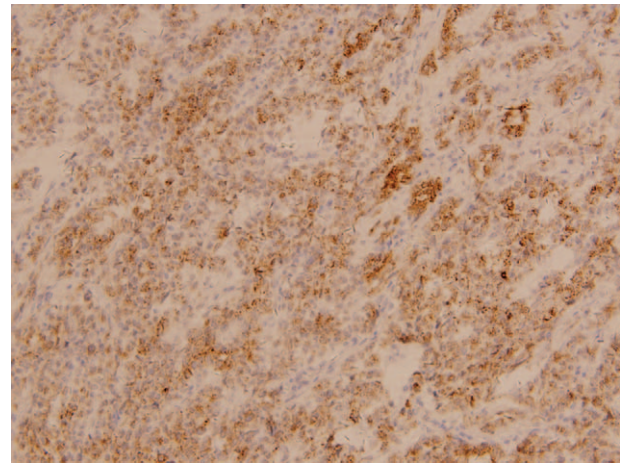


Figure 4. Immunohistochemical staining for glypican 3 (positive result).

4. Discussion and literature review

Primary endometrial YST is very rare, with only 11 cases reported in the literature to date (Table 1). Of these, 8 cases involved simple endometrial YST, 2 involved endometrial YST accompanied by endometrial adenocarcinoma, and 1 involved a combination of adenocarcinoma, high-grade stromal sarcoma, and YST. Increased AFP levels have been observed in 10 cases, whereas normal AFP levels were reported in only 1 case.^[2-12] Therefore, the patient in this article is only the second reported case of a primary endometrial YST with normal AFP.

Four theoretical hypotheses have been suggested to explain the development of endometrial YST tissue: the abnormal migration of primordial germ cells, which are hidden in the endometrial basal layer, during embryogenesis; an undiscovered YST metastasis; residual tissue after an incomplete abortion; and the abnormal differentiation of somatic cells.^[3-5,7] However, approximately 20% of female patients develop extra-ovarian YSTs. In most such patients, the tumor is distributed along the central axis of the body,^[1,2] which includes the mediastinum, pineal area, sacrococcygeal area, and female reproductive

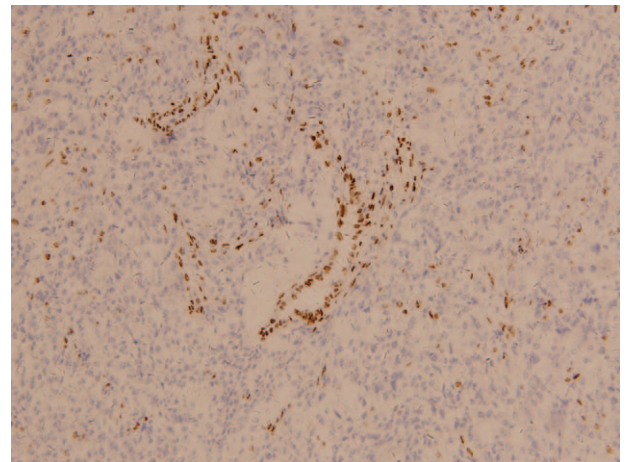


Figure 5. Immunohistochemical staining for estrogen receptor (negative result).

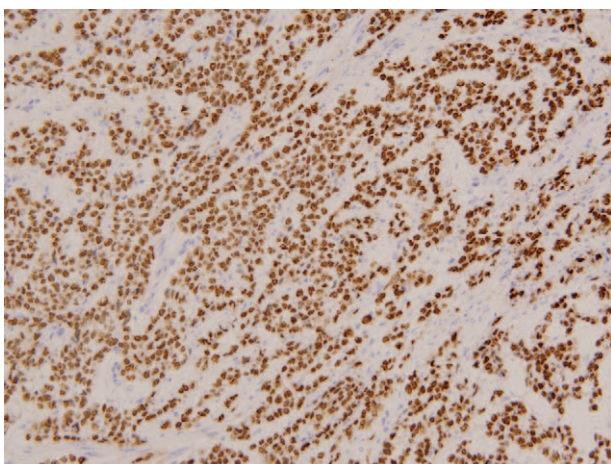


Figure 3. Immunohistochemical staining for SALL-4 (positive result).

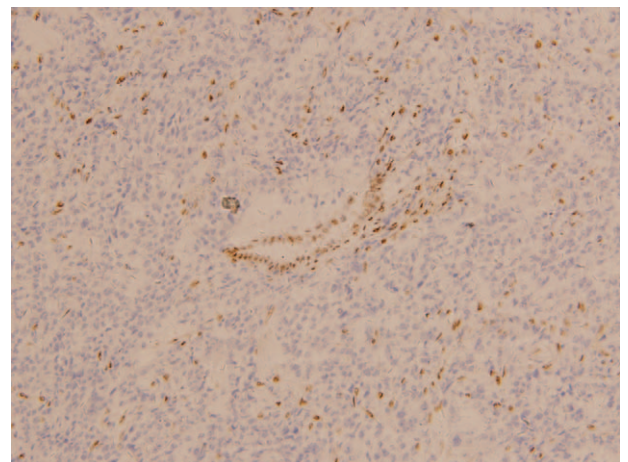


Figure 6. Immunohistochemical staining for progesterone receptor (negative result).

Table 1

Cases of primary endometrial yolk sac tumor.

Reference	Age (years)	AFP level	Surgery	Histopathology	Metastasis site	Chemotherapy	Radiotherapy	Follow up duration (months)	Status at last follow-up
[2]	49	Normal (3 weeks after surgery)	TAH, BSO, LD	YST	None	None	45 Gy on the pelvis	28	NED
[3]	28	380 ng/mL postoperation	TAH, BSO	YST	Liver, pelvic LNs	VCR, CTX, ADM, MTX, 5-FU	-	8	DOD
[4]	24	3600 ng/mL postoperation	Supracervical HYS, BSO	YST	Umbilicus	VCR, Act-D, CPA	+	24	DOD
[5]	27	1580 ng/mL preoperation	TAH, BSO, OMT	YST	None	VCR, Act-D, CPA	-	14	NED
[6]	42	18,530 ng/mL preoperation	TAH, BSO	YST	None	Vinblastine, BLM, DDP	-	24	NED
[7]	30	1762 ng/mL preoperation	TAH	YST	None	BLM, VP16, DDP	-	72	NED
[8]	29	3593.4 ng/mL preoperation	Modified HYS with left adnexa resection, LD	YST	None	VP16, CBDCA, BLM	-	39	NED
[9]	31	242.3 IU/mL preoperation	TAH, BSO, LD, OMT	YST	None	BLM, VP16, DDP	-	24	NED
[10]	59	27,670 U/mL postoperation	TAH, BSO, LD, OMT	Adenocarcinoma, YST	Liver, diaphragm	BLM, VP16, DDP	21 Gy by vaginal brachytherapy	19	AWD
[11]	65	2306 ng/mL preoperation	Modified radical HYS, BSO, LD	Adenocarcinoma, stromal sarcoma, YST	LN	PTX, CBDCA	-	ND	Survived surgeries
[12]	28	1522 ng/mL postchemotherapy	TAH, BSO, OMT, LD, appendectomy, partial resection of the sigmoid colon with anastomosis	Adenocarcinoma, YST	Peritoneum	PTX, ADM, DDP, CBDCA, MTX, Act-D, VP16, BLM, pingyangmycin, VCR, FUDR, oxaliplatin, CPA	-	10	AWD
Present case	38	Normal	TAH, BSO, LD, OMT, appendectomy	YST	Omentum	BLM, VP16, DDP	-	24	NED

5-FU=5-fluorouracil, Act-D=actinomycin-D, ADM=adriamycin, AFP=α-fetoprotein, AWD=alive with disease, BLM=bleomycin, BSO=bilateral salpingo-oophorectomy, CBDCA=carboplatin, CPA=cyclophosphamide, DDP=cisplatin, DOD=dead from the disease, FUDR=5-fluoro-2-deoxy-β-uridine, HYS=hysterectomy, LD=lymph node, MTX=methotrexate, ND=no evidence of the disease, OMT=omentectomy, PTX=paclitaxel, TAH=total abdominal hysterectomy, VCR=vincristine, VP16=etoposide, YST=yolk sac tumor.

tract.^[13] In infants and young children, the vagina is most common site of YST growth.^[3]

YSTs are prone to early metastasis and infiltration into surrounding tissue structures and can metastasize through the bloodstream and lymphatic system. In the current case, although no metastasis was observed in the lymphatic system, implantation metastasis was detected in the greater omentum. Therefore, this extremely rare condition supports the tendency of YST to metastasize early.

Given the rarity of primary endometrial YST, little systematic research has addressed the relevant surgical procedures, postoperative adjuvant therapies, and/or standard treatment regimens. In 1993, Fujita et al^[14] reported that in a cohort of 41 patients with ovarian YST, conservative surgery and postoperative adjuvant chemotherapy yielded 5 and 10-year survival rates of approximately 80%. Furthermore, Nawa et al^[15] reported that tumor staging and cytoreductive surgery are 2 important factors that influence the prognosis of patients with ovarian YST and observed that cisplatin-based chemotherapy was superior to cisplatin-free chemotherapy after cytoreductive surgery.

Among the 11 patients reported on in the literature,^[2–12] 9 underwent uterine bilateral adnexectomy, 1 retained the normal right ovary, and 1 retained both ovaries. Although 1 patient refused postoperative chemotherapy in favor of radiotherapy, the other 10 patients underwent postoperative adjuvant chemotherapy. The longest post-treatment follow-up duration was 6 years, during which no tumor recurrence was observed, and the shortest follow-up duration was 8 months after treatment due to patient death. The 2 patients who retained endocrine function were followed for 39 and 72 months, respectively, with no tumor recurrence.

Although it remains unclear whether the prognosis of endometrial YST is similar to that of ovarian YST, the above studies could serve as references. Notably, the BEP chemotherapy regimen can be administered postoperatively to patients with endometrial YST. Furthermore, AFP is an important and sensitive tumor marker for YST and can often be used to monitor post-treatment metastasis and recurrence. However, despite the crucial role of AFP in the diagnosis, treatment, and follow-up management of YST, we note that a few patients, including the patient in our case, have normal levels of this marker.

5. Conclusion

Primary endometrial YST is extremely rare, and even rarer in the context of a normal AFP level. Most cases are treated with surgery and chemotherapy, which can enable a young patient to

retain their endocrine function. Furthermore, the BEP chemotherapy regimen appears to be an effective postoperative chemotherapy regimen for patients with endometrial YST.

Author contributions

Resources: Xiaoxia Wei, Liang Song.

Supervision: Danqing Wang, Kaixuan Yang, Mingrong Qie, Rutie Yin, Qingli Li.

Validation: Xiaoxia Wei.

Writing – original draft: Liang Song.

Writing – review & editing: Liang Song, Qingli Li.

References

- [1] Talerma A. Primary endodermal sinus tumor of the endometrium presenting as “recurrent” endometrial adenocarcinoma. *Gynecol Oncol* 2002;84:184.
- [2] Spatz A, Bouron D, Pautier P, et al. Primary yolk sac tumor of the endometrium: a case report and review of the literature. *Gynecol Oncol* 1998;70:285–8.
- [3] Pileri S, Martinelli G, Serra L, Bazzocchi F. Endodermal sinus tumor arising in the endometrium. *Obstet Gynecol* 1980;56:391–6.
- [4] Clement PB, Young RH, Scully RE. Extraovarian pelvic yolk sac tumors. *Cancer* 1988;62:620–6.
- [5] Ohta M, Sakakibara K, Mizuno K, et al. Successful treatment of primary endodermal sinus tumor of the endometrium. *Gynecol Oncol* 1988;31:357–64.
- [6] Joseph MG, Fellows FG, Hearn SA. Primary endodermal sinus tumor of the endometrium. A clinicopathologic, immunocytochemical, and ultrastructural study. *Cancer* 1990;65:297–302.
- [7] Rossi R, Stacchiotti D, Bernardini MG, et al. Primary yolk sac tumor of the endometrium: a case report and review of the literature. *Am J Obstet Gynecol* 2011;204:e3–4.
- [8] Wang C, Li G, Xi L, et al. Primary yolk sac tumor of the endometrium. *Int J Gynaecol Obstet* 2011;114:291–3.
- [9] Abhilasha N, Bafna UD, Pallavi VR, et al. Primary yolk sac tumor of the endometrium: a rare entity. *Indian J Cancer* 2014;51:446.
- [10] Patsner B. Primary endodermal sinus tumor of the endometrium presenting as “recurrent” endometrial adenocarcinoma. *Gynecol Oncol* 2001;80:93–5.
- [11] Oguri H, Sumitomo R, Maeda N, et al. Primary yolk sac tumor concomitant with carcinosarcoma originating from the endometrium: case report. *Gynecol Oncol* 2006;103:368–71.
- [12] Ji ML, Lu Y, Guo LN, et al. Endometrial carcinoma with yolk sac tumor-like differentiation and elevated serum β -hCG: a case report and literature review. *Onco Targets Ther* 2013;6:1515–22.
- [13] Zhang B, Gao S, Chen Y, Wu Y. Primary yolk sac tumor arising in the pancreas with hepatic metastasis: a case report. *Korean J Radiol* 2010;11:472–5.
- [14] Fujita M, Inoue M, Tanizawa O, et al. Retrospective review of 41 patients with endodermal sinus tumor of the ovary. *Int J Gynecol Cancer* 1993;3:329–35.
- [15] Nawa A, Obata N, Kikkawa F, et al. Prognostic factors of patients with yolk sac tumors of the ovary. *Am J Obstet Gynecol* 2001;184:1182–8.