

# Delayed Complications Due to Polymer Coating Embolism after Endovascular Treatment

Takayuki Kitamura,<sup>1,2</sup> Hidenori Oishi,<sup>1,2</sup> Takashi Fujii,<sup>3</sup> Kohsuke Teranishi,<sup>2</sup> Kenji Yatomi,<sup>2</sup> Munetaka Yamamoto,<sup>2</sup> and Hajime Arai<sup>2</sup>

There have recently been reports of patients who developed postprocedural symptoms or alterations due to delayed foreign body embolisms observed in imaging findings. Polymer coating of devices have been described as a possible cause of foreign body embolisms, manifesting in delayed granulomatous responses and exhibiting characteristic imaging findings. In four of 4,025 patients who underwent coil embolization in our hospital or its affiliated facilities, similar findings were observed. Delayed lesions appeared between 1 month and 1 year after the procedures. There was extensive edema in the perfusion area of the treated vessels. In two cases examined by contrast-enhanced magnetic resonance imaging, multiple solid enhancing lesions within vasogenic edema were observed. Biopsy revealed a membranous foreign body in a blood vessel with surrounding foreign body granuloma formation in 1 case. Because these findings are similar to those of cases reported previously, they were considered as a foreign body embolism due to coating separations from the devices. Polymer coating separation occurs most frequently from guidewires. Especially if a metal introducer is used, the risk of separation increases. Surgeons should carefully follow the manufacturers' instructions when they use these devices and should acknowledge and report any events that may occur. Although these complications are extremely rare, further studies are warranted of similar cases; and we should prepare and share information on these intravascular devices for wide-scale dissemination in the industry.

**Keywords:** delayed complications, polymer coating embolism, endovascular treatment, foreign body

## Introduction

Intravascular treatment is an established therapeutic procedure in the treatment of intracranial aneurysms. Balloons, stents, and pipeline embolization devices (PEDs) have been

introduced to endovascular treatment with the ever-increasing advancement in the technology for manufacturing these devices. However, embolisms have garnered considerable attention as complications in endovascular treatment. Asymptomatic embolisms occurred in approximately 24–71% of patients who underwent cerebral angiography or endovascular treatment.<sup>1,2</sup> Recently there have been reports of patients who developed delayed symptoms and/or alterations in imaging findings due to a foreign body embolism following endovascular treatment. Delayed multiple enhancing lesions with edema were detected following coil embolization.<sup>3–5</sup> Biopsy revealed granulomatous angiitis encasing foreign material that is similar to hydrophilic coating.<sup>6</sup> We report four cases of patients who developed delayed extensive edema in the perfusion area of the treated vessels, among 4025 patients who underwent coil embolization treatment (including that with PEDs) in our hospital or its affiliated facilities between October 1998 and May 2018, with a review of the literature.

## Case Series

The characteristics of this case series are shown in Table 1. In cases 1 and 2, the patients underwent coil embolization for a ruptured and an unruptured aneurysm, respectively. The patient in case 1 developed postprocedural symptoms of numbness and partial seizures 2 months later, and the patient in case 2 developed postprocedural numbness 1 month later. Magnetic resonance imaging (MRI) revealed edematous lesions in the perfusion area. The symptoms improved with steroids in case 1 and without treatment in case 2. Definitive diagnoses for these two patients were not obtained because other than plain MRIs, contrast-enhanced MRIs or other examinations were not performed, except for a cerebrospinal fluid test in case 1. The details for the patients in cases 3 and 4, who underwent further examinations for scrutiny, were described as being those of representative cases.

## Case 3

A woman in her early 60s (Fig. 1) underwent stent-assisted coil embolization for an unruptured aneurysm in the left internal carotid artery (supraclinoid portion). She complained of motor aphasia, dysarthria, and hyposthenia of the right upper limb from 50 days after the procedure. An MRI, 60 days after the procedure, revealed extensive edema in the region of the left anterior parietal lobe. That was well after she had undergone surgery for bladder cancer. Extensive testing was performed because metastatic brain

<sup>1</sup>Department of Neuroendovascular Therapy, Juntendo University Faculty of Medicine, Tokyo, Japan

<sup>2</sup>Department of Neurosurgery, Juntendo University Faculty of Medicine, Tokyo, Japan

<sup>3</sup>Department of Neurosurgery, National Defense Medical College, Tokorozawa, Saitama, Japan

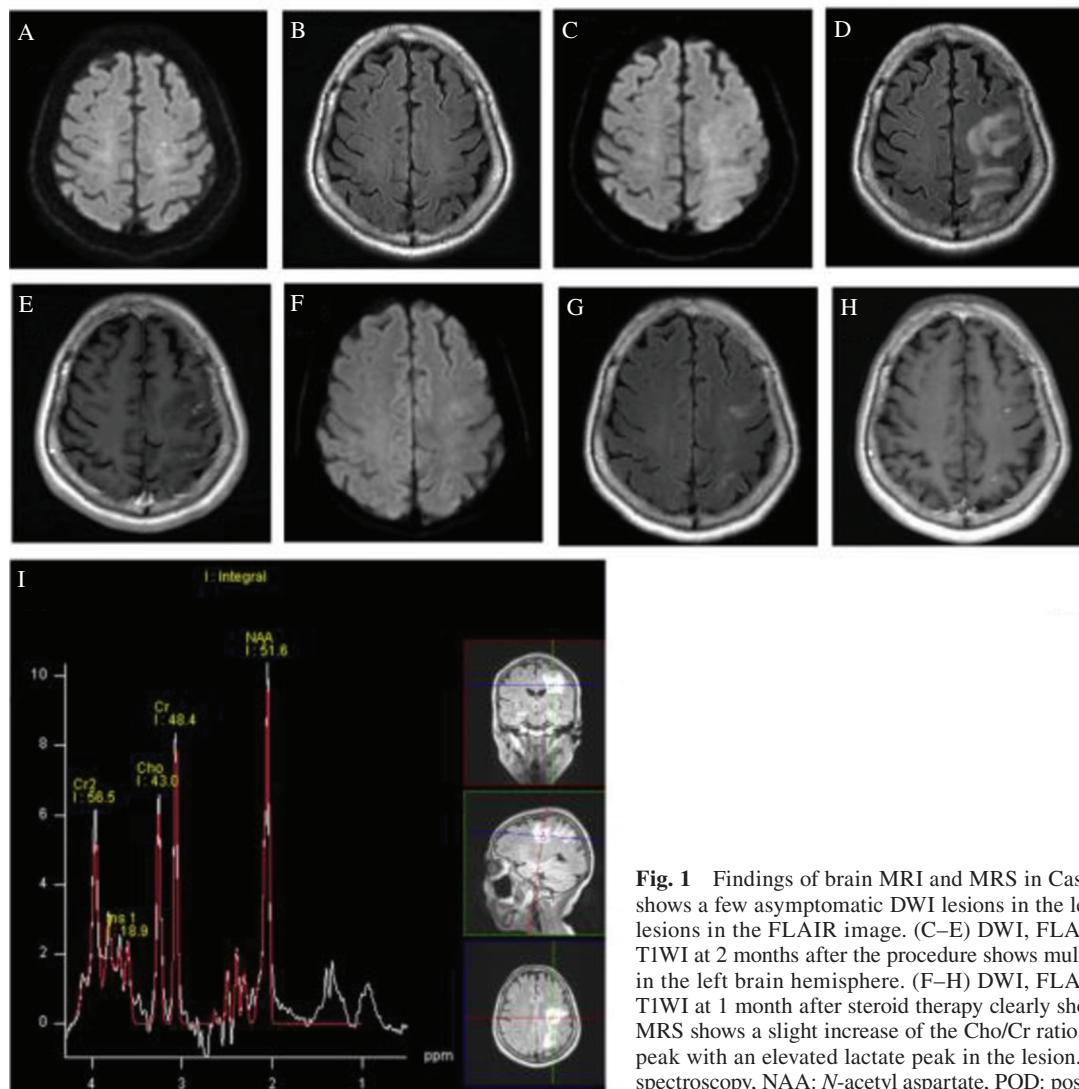
Received: December 26, 2018; Accepted: June 3, 2019  
Online December 18, 2019

Copyright© 2020 by The Japan Neurosurgical Society  
This work is licensed under a Creative Commons Attribution-NonCommercial-NoDerivatives International License.

**Table 1** Case series demographics and clinical characteristics

Patient no.	Age/Sex	SAH/WFNS grade	Aneurysm	Method	Clinically silent emboli	Edema in the white matter	Enhanced lesion (CE T <sub>1</sub> )	Symptom onset/ Lesions detect	Symptom	Treatment	Biopsy	Allergy	f/u MRI edema and enhanced lesion
1	40s/M	(+)/ II	A com A (Lt A1/A2)	Simple	ND	Lt ICA/Blt ACA area	Not done	2 months/ 2 months	Lt numbness, partial seizure	Steroid, AED	None	None	Improve 2 months
2	40s/F	(-)	Lt ICA OphA	Balloon	ND	Lt ICA area	Not done	1 month/ 3 months	Rt numbness	None	None	Pediatric asthma	Improve 9 months
3	60s/F	(-)	Lt ICA (C2 portion)	Stent	Lt ICA area	Lt ICA area	Same area/ Multiple solid	50 days/ 60 days	Aphasia, Rt hemiparesis	Steroid	None	None	Improve 1 month
4	50s/F	(+)/ IV	Rt MCA	Balloon	ND	Rt MCA area	Same area/ Multiple solid	1 year/ 1 year	Epileptic seizure	AED	Done	Metal allergy suspected	Improve 6 months

ACA: anterior cerebral artery, A com A: anterior communicating artery, AED: antiepileptic drug, CE T<sub>1</sub>: contrast-enhanced T<sub>1</sub>-weighted, f/u: follow up, ICA: internal carotid artery, MCA: middle cerebral artery, ND: not described, OphA: ophthalmic artery, SAH: subarachnoid hemorrhage, WFNS: World Federation of Neurosurgical Societies.



**Fig. 1** Findings of brain MRI and MRS in Case 3. (A and B) POD 1 MRI shows a few asymptomatic DWI lesions in the left brain hemisphere but no lesions in the FLAIR image. (C–E) DWI, FLAIR, and contrast-enhanced T1WI at 2 months after the procedure shows multiple solid enhancing lesions in the left brain hemisphere. (F–H) DWI, FLAIR, and contrast-enhanced T1WI at 1 month after steroid therapy clearly shows diminishing lesions. (I) MRS shows a slight increase of the Cho/Cr ratio and a decrease of the NAA peak with an elevated lactate peak in the lesion. MRS: magnetic resonance spectroscopy, NAA: N-acetyl aspartate, POD: postoperative day.

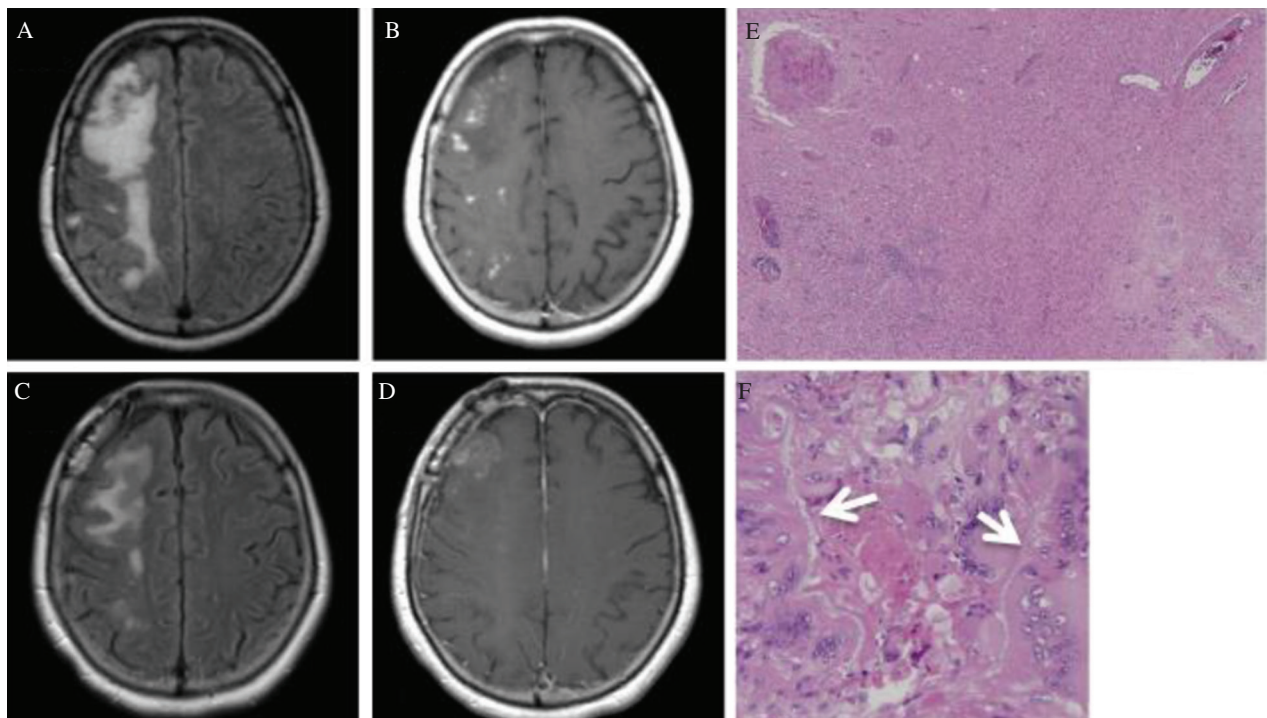
tumors, lymphoma, infarction, demyelinating disorders and abscesses were suspected based on the past history and imaging findings.

There was no rise of tumor marker level in the blood test, and soluble interleukin-2 receptor (sIL-2R) at 218 U/mL was also within the normal range. No inflammatory reactions, the elevation of eosinophils or immunologically abnormal findings, were observed. The cerebrospinal fluid test results showed: slightly elevated values of total protein (TP) concentration 51 mg/dL and cellular count 7/ $\mu$ L, normal glucose at 61 mg/dL, normal myelin basic protein at 31.3 pg/mL, and negative oligoclonal immunoglobulin G bands. From those results, demyelinating disorders such as multiple sclerosis (MS) were ruled out. In the MRI with contrast-enhanced T1-weighted images (T1WIs), multiple nodular enhancing lesions were observed within the edematous lesions. The magnetic resonance spectroscopy (MRS) results of the edematous lesions were as follows. *N*-acetyl aspartate (NAA) was lowered, and the relative order of signal intensity in the spectrum pattern was: choline (Cho) < creatine (Cr) < NAA. From the results of various tests, tumors, infarction, and abscesses were ruled out. Furthermore, there was no history of allergies or any findings of associations with allergic diseases. Eventually, other diseases were ruled out as well. Because of the similarity of these findings to those in previous reports, we came to the conclusion that the clinical diagnosis was delayed granulomatous alteration due to a foreign body embolism.

The patient's symptoms quickly improved with the administration of 4 mg of betamethasone and 200 mL of concentrated glycerin solution twice a day. The steroid was gradually reduced. An MRI 1 month after beginning the treatment showed the edematous lesions had improved considerably and the enhancing lesions had begun to disappear. Thereafter, follow-up has been conducted by imaging without revealing any signs of exacerbation.

#### Case 4

A woman in her mid-50s (Fig. 2) underwent coil embolization with the balloon-neck remodeling technique for a ruptured aneurysm [the World Federation of Neurosurgical Societies (WFNS) grading system classification grade IV] at the right middle cerebral artery bifurcation. Generalized convulsions occurred 1 year after the treatment. MRI exhibited an extensive edematous lesion in the region of the right middle cerebral artery, and contrast-enhanced T1WI revealed multiple nodular enhancing lesions within the edematous lesions. In a cerebrospinal fluid test, except for a slight increase of TP (47 mg/dL), there were no findings suggestive of MS. Despite various tests, the cause of the symptoms was unidentifiable. An anticonvulsant was effective to temporarily alleviate the symptoms. Even after 6 months after beginning the medication, the edematous lesions had not improved, and convulsions occurred repeatedly. Therefore, we biopsied the lesions including the enhancing lesions in the right frontal lobe. Considering the possibility of a



**Fig. 2** Findings of brain MRI and histologic appearances in Case 4. (A and B) Before biopsy MRI shows multiple enhancing lesions in the right MCA territory surrounded by vasogenic edema. (C and D) FLAIR, and contrast-enhanced T1WI at 2 months after biopsy clearly shows diminishing lesions. (E and F) Right frontal lobe biopsy. Hematoxylin–Eosin stain at 40 $\times$  (E) and 200 $\times$  (F) magnification demonstrate irregular gliosis, and a collection of lymphocytes accompanied by chronic inflammation around the blood vessels. Membrane-like foreign bodies (arrows) accompany the formation of granulomatous inflammation with many multinucleated giant cells. MRI: magnetic resonance imaging, MCA: middle cerebral artery.

malignant lymphoma, steroids were not used. MRS findings of the lesion before the procedure were as follows. NAA was lower. Cho and Cr were higher. And lactate (Lac) was slightly higher than that in the unaffected side.

In the histological examination, findings associated with the chronic inflammation, such as extensive loss of nerve tissues, emergence of irregular gliosis, and the accumulation of lymphocytes around the vessels were detected. Immunostaining revealed that CD20, CD79  $\alpha$ -positive B-lymphocytes, and CD3-positive T-lymphocytes were present in the mixture, and the MIB-1 cell proliferation index was extremely low. Thus, malignant lymphoma was ruled out. A membranous foreign body and foreign body granuloma formation with surrounding multinucleated giant cells were observed in a space that seemed to be in the lumen of the vessels. From these findings, we arrived at a diagnosis of a delayed granulomatous lesion due to foreign body emboli after coil embolization.

As evidenced in the postprocedural MRI, the edematous lesions and enhancing lesions seemed to have improved. Seizures became controllable with anticonvulsants. A metallic patch test was performed because metallic allergies were suspected, but the results were all negative. There was no apparent association with any allergic diseases.

## Discussion

Foreign body emboli following cerebral angiography has been described by Silberman et al.<sup>7)</sup> Mehta et al.<sup>8)</sup> pointed out that the hydrophilic polymer used for devices might be the cause of foreign body embolisms. In 2010 they found a similarity between pathological samples in the hearts and lungs of patients who underwent angiography examinations or therapy with devices, and the hydrophilic polymer of devices examined *ex vivo*.<sup>9)</sup> Furthermore, in pathological findings of three patients that were treated with the pipeline embolization device (PED), foreign body emboli in small vessels were found to be associated with the polyvinylpyrrolidone (PVP) used for the hydrophilic coating of the devices.<sup>10)</sup> In addition to those reports, there are several recent reports in which delayed multiple enhancing lesions with perilesional edema were observed after a coiling procedure.<sup>3-5,11)</sup>

In 2008, Fealey et al.<sup>12)</sup> reported the results of a biopsy of a patient who developed delayed multiple ring enhancing lesions after coil embolization. The biopsy revealed granulomas and microabscesses, in which polymer filaments were identified. They also reported hydrophilic coating separation might have induced a foreign body granulomatous response or microabscesses.<sup>12)</sup> Shapiro et al.<sup>6)</sup> also reported granulomatous angiitis encasing foreign material similar to PVP. Collectively, hydrophilic coating could be a cause of foreign body embolisms, and foreign bodies induce delayed granulomatous responses, as shown in characteristic imaging findings.

In an article by Mehta et al.,<sup>13)</sup> they reviewed 32 cases of patients who exhibited an intracranial polymer reaction after vascular intervention. Among them, delayed symptoms were observed in 12 cases (38%). Most of them developed enhancing parenchymal lesions that were associated with

granulomas and/or abscesses on the same side as the procedure.<sup>13)</sup> In 2017, Chopra et al.<sup>14)</sup> presented a review article on polymer coating embolism. Although concerns are rising year-by-year, case reports that include delayed symptoms are still sparse. Evidentially, their characteristics and clinical manifestations for diagnostics and therapeutic strategies remain to be established.

Delayed complications occurred in about 0.6% of patients that had undergone embolization treatment of aneurysms. In the present study, the incidence rate was 0.1%, observed in four of 4025 patients in our hospital or its affiliated facilities. It is a rare complication, while the actual number of patients with complications could be slightly larger because there might have been some asymptomatic patients.

According to previous reports, lesions have been found several weeks or months after the coiling procedure, in the perfusion area of treated arteries in multiple forms with accompanying vasogenic edema. It is also well known that in contrast-enhanced images, many of the lesions appear solid, but sometimes they exhibit ring enhancement. In the present study, delayed symptoms appeared between 1 month and 1 year after the coiling procedure, and lesions were located in the perfusion area of the treated arteries in all four cases. In two cases, a contrast agent was used and multiple solid enhancing lesions within the edema were observed in both cases, but no images of ring-enhancing lesions were observed.

In case 3, diffusion weighted imaging taken the day after the coiling procedure revealed asymptomatic high intensity lesions scattered in the area proximal to the site where enhancing lesions were detected later in contrast-enhanced imaging. Hydrophilic coating that separate and spread during coil treatment may become a source of a foreign body embolism and cause delayed granulomatous lesions. MRS findings, e.g., a lowered NAA/Cr ratio, a slightly increased Cho/Cr ratio, and a Lac peak, seem to indicate an ischemic state, MS, or acute disseminated encephalomyelitis, reflecting demyelinating lesions and/or an inflammatory response.<sup>11)</sup> The patients in cases 3 and 4 were examined with MRS. In these cases, similar findings were obtained, indicating the presence of an inflammatory lesion due to granuloma.

Regarding clinical signs and symptoms, investigators reported that patients commonly developed nonspecific symptoms, such as headache and sense of fatigue, and focal symptoms at the site of edematous lesions.<sup>11,12)</sup> Although asymptomatic cases have been reported previously,<sup>4,11)</sup> all the cases in the present study were symptomatic. There are no standard therapies currently available. There are reports that asymptomatic cases recovered without therapy. For symptomatic cases, convulsive seizures were treated with anticonvulsants. Antibiotics are often administered because the possibility of infectious diseases cannot be ruled out. However, it is considered ineffective.

In all the reports in which steroids were used, a quick recovery of symptoms and efficacy revealed in imaging findings were frequently attained. Steroids are considered as one of the most effective therapeutic options, although an optimal standard regimen including the dosage has not been

established. In cases 1 and 3 in the present study, steroids were administered, and the imaging findings improved compared with those of cases 2 and 4, in which steroids were not administered. These results suggest the likelihood that steroids are effective.

Shapiro et al.<sup>6)</sup> reported that four of five patients had type-I allergies. Descriptions of allergic responses to PVP are also found in other articles,<sup>15,16)</sup> (i.e., pathological conditions of a delayed response might be associated with type-IV rather than type-I allergies). In case 4 in the present study, a metallic patch test was conducted for 17 kinds of metals, for which the results were all negative. Evidentially none of these four cases were associated with allergies.

Polyvinylpyrrolidone, used for many devices as hydrophilic coating material, is likely the most suspected embolic material. A PVP-like foreign body was detected in the pathological findings in a case of a patient who developed a fatal hemorrhage following PED therapy,<sup>10)</sup> as well as in another patient, reported by Shapiro et al.,<sup>6)</sup> who developed enhancing lesions following endovascular treatment.

It has been suggested that one of the factors that cause coating separation, is a tight-fitting catheter system. Especially, when there is a difficult access route to the lesion, intracatheter friction is increased and coating separation tends to occur easily. The devices used in the present study are listed in Table 2. A coaxial system was used for all the treatments. In case 3, there was a slight difficulty accessing the aneurysm, while it was not especially difficult compared with the other cases.

The amount of separated PVP may be one of the factors for the occurrence rate of embolism including asymptomatic cases. The immune function of each individual patient would significantly be associated to the rate. In 2015, it was reported that the U.S. Food and Drug Administration (FDA) received 500 medical device reports and recall requests from 1 January 2014, claiming hydrophilic and hydrophobic coating separation.<sup>17)</sup> The majority of recalls were associated with guidewires.<sup>17)</sup> The instruction manual includes a description that the usage of metallic needles and metallic introducer sheaths against guidewires should be avoided, because they are a possible cause of breakdown and cutting. Operating precautions also included remarks about the possible events, e.g., when these devices are used concurrently with metallic devices, the polyurethane resin coating covering the surface of the wire (Ni-Ti alloy) could separate. Furthermore, regardless of the surgeons' knowledge about the possibility that hydrophilic coating of devices separate, metallic introducer sheaths are sometimes used for their convenience during the actual procedure. When a guidewire is inserted, sometimes a visible amount of coating material is separated, which could cause an embolism. Proper usage of each device is recommended and the recognition and reporting of events that occur is necessary.

Histologically, Barnwell et al.<sup>18)</sup> first reported a foreign body that looked strikingly similar to the hydrophilic coating on a catheter. Later, Mehta et al.<sup>8,9)</sup> and Hu et al.<sup>10)</sup> indicated that hydrophilic coating materials are foreign body embolic sources. Shapiro et al.<sup>6)</sup> and Fealey et al.<sup>12)</sup> reported that

**Table 2** Equipment for coil embolization

Tools	Case 1	Case 2	Case 3	Case 4
Sheath introducer	7F Medikit long sheath <sup>a</sup>	6F Medikit long sheath <sup>a</sup> 7F Medikit long sheath <sup>a</sup>	4F Medikit long sheath <sup>a</sup>	7F Medikit long sheath <sup>a</sup>
Diagnostic catheter	4F Medikit JNS <sup>a</sup>	4F Medikit JNS <sup>a</sup>	4F Medikit JNS <sup>a</sup>	
Guiding catheter	Medikit 7F VT(C) <sup>a</sup>	Envoy 6F <sup>b</sup> Britetip 7F <sup>c</sup>	Axcelguide 6F <sup>a</sup> Medikit Cerulean G 6F <sup>a</sup>	Britetip 7F <sup>c</sup>
Support catheter		Medikit 4F JB-3 <sup>a</sup>	Medikit Cerulean G 4F <sup>a</sup>	
Microcatheter	Excelsior SL-10 <sup>d</sup>	Excelsior 1018 <sup>d</sup> Excelsior SL-10 <sup>d</sup>	Excelsior SL-10 <sup>d</sup> Prowler select plus <sup>b</sup>	Excelsior SL-10 <sup>d</sup>
Guidewire	Radifocus 035 <sup>e</sup>	Radifocus 035 <sup>e</sup> X-pedion 10 <sup>f</sup>	Radifocus 035 <sup>e</sup> Amplatz extra stiff wire 035 <sup>e</sup> GT wire 012 <sup>e</sup>	Radifocus 035 <sup>e</sup> X-pedion 10 <sup>f</sup> GT wire 012 <sup>e</sup>
Balloon/stent	GT wire 012 <sup>e</sup>	GT wire 012 <sup>e</sup> HyperGlide <sup>f</sup>	ASAHI/CHIKAI 014 <sup>h</sup> Enterprise 2 <sup>b</sup>	HyperForm <sup>f</sup>
Coil	GDC-10 <sup>d</sup>	GDC-10 <sup>d</sup> GDC-18 <sup>d</sup> Trufill DCS <sup>b</sup>	Target <sup>d</sup>	GDC-10 <sup>d</sup> Trufill Orbit <sup>b</sup>

<sup>a</sup>Medikit, Tokyo, Japan. <sup>b</sup>CERENOVUS, Irvine, California, USA. <sup>c</sup>Cordis Corporation, Miami Lakes, FL, USA. <sup>d</sup>Stryker, Fremont, CA, USA. <sup>e</sup>Terumo, Tokyo, Japan. <sup>f</sup>Medtronic Japan Co., Ltd. <sup>g</sup>Cook Medical, Bloomington, Indiana, USA. <sup>h</sup>ASAHI INTECC, Aichi, Japan.

similar pathological findings were obtained in delayed multiple enhancing lesions, indicating that foreign bodies induced granulomatous responses. In case 4 in the present study, biopsy revealed the presence of intravenous membranous material and formation of foreign body granulomas surrounded by many multinucleated giant cells. While it is difficult to prove that the foreign body causing an embolism is actually a piece or pieces of the polymer coating, our findings are similar to and consistent with those in many previous reports.<sup>6–10,13,14)</sup>

## Conclusion

Polymer coating embolism from intravascular medical devices has recently begun to attract much attention. Coating materials are used for almost all of the devices used in endovascular procedures. These coating materials could become the cause of foreign body embolisms. Proper usage according to the manufacturers' instructions is important because there is a possibility that improper handling and storage of these devices might increase the risk of polymer coating separation.

Although there were pathological findings in one case in the present study, it was conjectured that all four cases exhibited delayed granulomatous responses due to polymer coating embolisms, determined from clinical symptoms and imaging findings. Even though complications are rare, further more in-depth studies are warranted. Moreover, it is essential that, for large-scale dissemination, we provide and share information with the manufacturers of these intravascular devices.

## Acknowledgment

We thank Robert E. Brandt, Founder, CEO, and CME, of MedEd Japan, for editing and formatting the manuscript.

## Conflicts of Interest Disclosure

The authors declare no conflicts of interest associated with this manuscript.

## References

- 1) Bendszus M, Koltzenburg M, Burger R, Warmuth-Metz M, Hofmann E, Solymosi L: Silent embolism in diagnostic cerebral angiography and neurointerventional procedures: a prospective study. *Lancet* 354: 1594–1597, 1999

- 2) Cronqvist M, Wirestam R, Ramgren B, et al.: Diffusion and perfusion MRI in patients with ruptured and unruptured intracranial aneurysms treated by endovascular coiling: complications, procedural results, MR findings and clinical outcome. *Neuroradiology* 47: 855–873, 2005
- 3) Okawara M, Son J, Yamaguchi H, Yamada S, Ueda M, Maeda T: A case of multiple enhancing lesions after coil embolization: the association with hydrophilic polymer emboli. *No Kekkannai Chiryō* 1: 37–43, 2016 (Japanese)
- 4) Shoda K, Kimura K, Yonezawa S, Takenaka S, Hara S, Fukazawa S: A case of delayed symptomatic multiple white matter lesions after cerebral aneurysm coil embolization. *Jpn J Neurosurg* 27: 38–44, 2018
- 5) Cruz JP, Marotta T, O'Kelly C, et al.: Enhancing brain lesions after endovascular treatment of aneurysms. *AJNR Am J Neuroradiol* 35: 1954–1958, 2014
- 6) Shapiro M, Ollenschlegler MD, Baccin C, et al.: Foreign body emboli following cerebrovascular interventions: clinical, radiographic, and histopathologic features. *AJNR Am J Neuroradiol* 36: 2121–2126, 2015
- 7) Silberman J, Cravioto H, Feigin I: Foreign body emboli following cerebral angiography. *Trans Am Neurol Assoc* 85: 123–125, 1960
- 8) Mehta RI, Mehta RI, Fishbein MC, et al.: Intravascular polymer material after coil embolization of a giant cerebral aneurysm. *Hum Pathol* 40: 1803–1807, 2009
- 9) Mehta RI, Mehta RI, Solis OE, et al.: Hydrophilic polymer emboli: an under-recognized iatrogenic cause of ischemia and infarct. *Mod Pathol* 23: 921–930, 2010
- 10) Hu YC, Deshmukh VR, Albuquerque FC, et al.: Histopathological assessment of fatal ipsilateral intraparenchymal hemorrhages after the treatment of supraclinoid aneurysms with the Pipeline Embolization Device. *J Neurosurg* 120: 365–374, 2014
- 11) Deguchi K, Kawahara Y, Deguchi S, et al.: A patient develops transient unique cerebral and cerebellar lesions after unruptured aneurysm coiling. *BMC Neurol* 15: 49, 2015
- 12) Fealey ME, Edwards WD, Giannini C, Piepgras DG, Cloft H, Rihal CS: Complications of endovascular polymers associated with vascular introducer sheaths and metallic coils in 3 patients, with literature review. *Am J Surg Pathol* 32: 1310–1316, 2008
- 13) Mehta RI, Mehta RI: Polymer-induced central nervous system complications following vascular procedures: spectrum of iatrogenic injuries and review of outcomes. *Hum Pathol* 53: 178–190, 2016
- 14) Chopra AM, Mehta M, Bismuth J, et al.: Polymer coating embolism from intravascular medical devices - a clinical literature review. *Cardiovasc Pathol* 30: 45–54, 2017
- 15) Yoshida K, Sakurai Y, Kawahara S, et al.: Anaphylaxis to polyvinylpyrrolidone in povidone-iodine for impetigo contagiosum in a boy with atopic dermatitis. *Int Arch Allergy Immunol* 146: 169–173, 2008
- 16) Adachi A, Fukunaga A, Hayashi K, Kunisada M, Horikawa T: Anaphylaxis to polyvinylpyrrolidone after vaginal application of povidone-iodine. *Contact Derm* 48: 133–136, 2003
- 17) U.S. Food and Drug Administration: Lubricious coating separation from intravascular medical devices. FDA Safety Communication. FDA: Silver Spring, MD, 2015
- 18) Barnwell SL, D'Agostino AN, Shapiro SL, Nesbit GM, Kellogg JX: Foreign bodies in small arteries after use of an infusion microcatheter. *AJNR Am J Neuroradiol* 18: 1886–1889, 1997

Corresponding author:

Takayuki Kitamura, Department of Neurosurgery and Neuroendovascular Therapy, Juntendo University Faculty of Medicine, 2-1-1 Hongo, Bunkyo-ku, Tokyo 113-8421, Japan.

✉ tkitamu@juntendo.ac.jp