



Case Report

# Malignant middle cerebral artery infarction following subacute subdural hematoma: A case report and literature review

Saad Moughal<sup>1</sup>, Micaela Uberti<sup>2</sup>, Alaa Al-Mousa<sup>3</sup>, Salem Al-Dwairy<sup>3</sup>, Anan Shtaya<sup>2</sup>, Erlick Pereira<sup>2</sup>

<sup>1</sup>Neurosciences Research Centre, Molecular and Clinical Sciences Research Institute, <sup>2</sup>Neurosciences Research Centre, Molecular and Clinical Sciences Research Institute, Atkinson Morley Neurosurgery Centre, St George's, University of London, Tooting, London, United Kingdom, <sup>3</sup>Department of General and Special Surgery, Faculty of Medicine, The Hashemite University, Zarqa, Jordan.

E-mail: Saad Moughal - saad.m@hotmail.co.uk; Micaela Uberti - micaela.uberti@nhs.net; Alaa Al-Mousa - amousa80@yahoo.com;

\*Salem Al-Dwairy - salemyd@hotmail.com; Anan Shtaya - ashtaya@sgul.ac.uk; Erlick Pereira - epereira@sgul.ac.uk



**\*Corresponding author:**

Salem Al-Dwairy,  
Department of General and  
Special Surgery, Faculty of  
Medicine, The Hashemite  
University, Zarqa, Jordan.

salemyd@hotmail.com

Received : 21 November 2020

Accepted : 18 February 2021

Published : 17 March 2021

**DOI**

10.25259/SNI\_838\_2020

**Quick Response Code:**



## ABSTRACT

**Background:** Subacute subdural hematomas (ASDH) are only treated surgically when they cause mass effect significant enough to give symptoms. Rarely, sub-ASDH may cause enough pressure to result in a malignant middle cerebral artery (MCA) territory infarction. Decompressive craniectomy (DC) is the last resort to reduce intracranial pressure following malignant MCA infarction. Herein, we review the literature and describe a case of MCA/posterior cerebral artery (PCA) territories infarction following drainage of a sub-ASDH that was treated with DC with good outcome.

**Case Description:** We report a case of malignant right-sided MCA/PCA infarction in a 62-year-old man who presented with progressive headache following a cycling incident leading to a head injury. Initial CT head demonstrated a small right ASDH. He had no neurological deficit, headache settled on analgesia, and there was no expansion of the SDH on the repeat CT; therefore, he was managed conservatively. He was admitted 6-days later with worsening headaches and hyponatremia. Repeat CT revealed an increase in size of the hematoma and mass effect leading to a mini-craniotomy and evacuation of hematoma. He developed left-sided hemiplegia, slurred speech and hyponatremia, and CT head demonstrated a right-sided MCA/PCA infarction with significant mass effect. He underwent emergent DC and subsequent cranioplasty and ultimately recovered to mRS of 2.

**Conclusion:** SDH are frequent neurosurgical entities. Malignant MCA/PCA strokes following mini-craniotomies are rare but need to be considered especially during the consent process.

**Keywords:** Subdural hematoma, Malignant middle cerebral artery infarction, Decompressive craniectomy

## INTRODUCTION

Subdural hematomas (SDH) are a well-known entity that can result from a head injury. The natural history of subdural bleeds has been described elsewhere.<sup>[18]</sup> These include acute, subacute and chronic hematomas, and follow different clinical trajectories hence require specified management.<sup>[3]</sup> Small asymptomatic SDH are normally managed conservatively. However, larger collections that result in clinical deterioration can signify potential expanding cerebral edema which requires emergent treatment.<sup>[14]</sup> Acute SDH are associated with refractory elevated

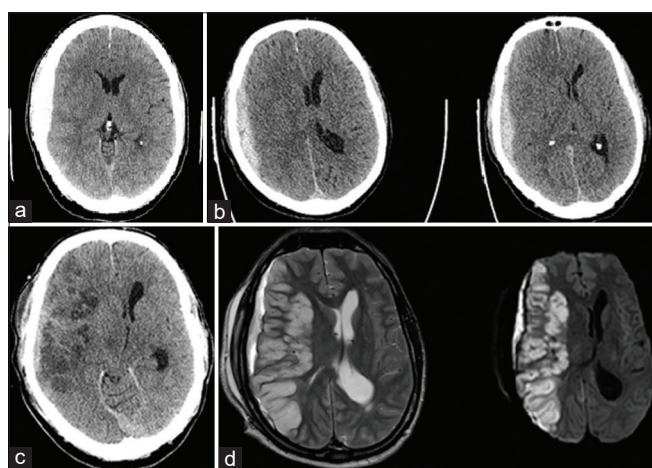
This is an open-access article distributed under the terms of the Creative Commons Attribution-Non Commercial-Share Alike 4.0 License, which allows others to remix, tweak, and build upon the work non-commercially, as long as the author is credited and the new creations are licensed under the identical terms.

©2021 Published by Scientific Scholar on behalf of Surgical Neurology International

intracranial pressure (ICP) and carry the greatest mortality and morbidity.<sup>[19]</sup> The deleterious effects of a head injury are compounded by aberrant cerebrovascular autoregulation and consequential vasospasm.<sup>[13]</sup> Malignant middle cerebral artery (MCA) infarction is normally a consequence of thromboembolic stroke;<sup>[11]</sup> however, it has been reported to result from head injury<sup>[5]</sup> but not following subacute SDH. Decompressive craniectomy (DC) are a life-saving and last line of treatment for these types of strokes.<sup>[17]</sup> In this report, we present a case of a patient who developed malignant MCA infarction after a subacute SDH and review the literature for potential mechanisms.

## CASE REPORT

A 62-year-old male previously fit and well presented with a 1-day history of severe headache following a cycling accident that caused a head injury. There was no altered consciousness and he was neurologically intact on arrival to ED. Computer tomography (CT) of the head showed a right hemispheric acute subdural hematoma (ASDH) with no significant mass effect [Figure 1a]. Initial blood results were normal. The patient was admitted for observation and remained well, so was discharged after 5 days. Six days later he attended hospital with a progressive headache. A CT head showed expansion of now sub-acute SDH with 9 mm of midline shift [Figure 1b]. Although he was clinically stable, he was booked for urgent surgery. He had transient hyponatremia of 129 mmol/L which was successfully corrected. Two-hours after admission his conscious level deteriorated (GCS 15–9; M5V2E2) and he subsequently had a seizure. A mini-craniotomy was done to evacuate the hematoma, and the procedure was uncomplicated. His neurological status



**Figure 1:** Initial computed tomography (CT) demonstrated a small right acute subdural hematoma with minimal shift (a). CT performed at re-presentation demonstrated enlarged ASDH with mass effect (b). Right malignant middle cerebral artery/posterior cerebral artery territory infarction on CT (c) and MRI (T2, d).

remained at GCS 8 (M4V2E2) and he developed dense left-sided hemiplegia. CT and MRI showed a right-MCA infarction with midline shift [Figures 1c and d, respectively]. The patient underwent a DC. Two days postoperative the patient recovered to GCS 15 but had persistent left-sided weakness. He was discharged to a neurorehabilitation center and commenced on clopidogrel 75 mg and atorvastatin 40 mg. One-month later he underwent a cranioplasty. Four months postoperatively, the patient recovered with a Modified Rankin Score of 2. Unfortunately, 2 years later he developed a wound infection after another minor head injury involving the surgical site. This was treated with several courses of antibiotics as the patient refused to have further surgery, but eventually the bone flap had to be removed. He then developed trephined syndrome and his left sided weakness got slightly worse. After a new long course of antibiotics, he had a new titanium cranioplasty inserted and has recovered well. He is now fully independent, and only has minimal left arm and leg weakness.

## DISCUSSION

Raised ICP can occur after an acute SDH; hence, maintenance of cerebral perfusion pressure is central to the treatment paradigm.<sup>[18]</sup> Cytotoxic edema causing raised ICP leads to a marked reduction in cerebral blood flow, hence increasing the risk of ischemia. In this context of space-occupying edema malignant MCA infarction could develop, which was confirmed by MRI imaging in our patient. Furthermore, additional implicating factors include direct pressure from the SDH and mechanical attenuation of the MCA.<sup>[15]</sup> Occlusion of small vessels resulting in cerebral infarction and brain swelling following ASDH has been reported in laboratory studies.<sup>[10]</sup> Indeed, this theory strongly supports the pathophysiological changes in our patient, as he developed MCA and posterior cerebral artery territory infarctions likely due to small vessel occlusion.

In severe head injuries, vasospasm may be aggravated by hemoglobin blood products, due to SDH or subarachnoid hemorrhage, or mechanical force through endothelin-mediated hypercontractility.<sup>[2]</sup> A cascade of events ensues involving excitotoxic mediators resulting in secondary brain injury. Sustained electrochemical instability following traumatic brain injury (TBI) is predominately mediated by glutamate excitotoxicity. This phenomenon is central to the development of seizures<sup>[16]</sup> and is common in SDH and can further increase the ICP. Untreated cerebral edema carries risks of irreversible neurological damage<sup>[1]</sup> and has been implicated in vasospasm. However, we did not perform angiography in our case and the role of vasospasm in such scenarios is to be addressed.

Hyponatremia is associated with an increased risk of mortality in hospitalized patients,<sup>[19]</sup> and untreated can cause seizures, coma, or death. The intermediary mechanism

involves expanding cerebral edema. Hyponatremia can occur secondary to SIADH or cerebral salt wasting<sup>[8]</sup> and management strategies are directed at the differences in volume status with each condition. The mechanisms that interplay hyponatremia and vasospasm in are poorly understood, although in our case it may have been consequential of the expanding hematoma. Seizures can be a direct result of the head injury the patient sustained causing a rise in ICP and potentially resulting in ischemic changes. Altogether, cytotoxic edema compounded by hyponatremia and seizures may have led to ischemia, thereby creating a vicious cycle of expanding cerebral edema.

DC a life-saving procedure for treatment of refractory raised ICP, in cases of large hemispheric infarction or significant head injury.<sup>[4,6]</sup> The benefits of aggressive decompression in the context of TBI and malignant supratentorial infarction have been demonstrated,<sup>[7]</sup> where the timing to surgical decompression is debated.<sup>[9]</sup> Delayed subdural hematoma and intraoperative brain swelling are recognized complications of decompressive surgery;<sup>[12]</sup> however, malignant MCA infarction following craniotomy for subacute SDH has not been reported. In our case, the patient's neurological status deteriorated immediately before evacuation of the expanded SDH. DC was performed within 6 h of radiological evidence of malignant MCA infarction with good outcome.

## CONCLUSION

Malignant supratentorial infarction following SDH is rarely reported. Expanding cerebral edema, hyponatremia, and reduced cerebral blood flow contribute to malignant infarction. Postoperative brain imaging in the context of progressive neurological deficit for subacute SDH is prudent to identify this rare complication. Surgical decompression was performed quickly to prevent tentorial herniation and death and produced a good functional outcome.

## Declaration of patient consent

The authors certify that they have obtained all appropriate patient consent.

## Financial support and sponsorship

Nil.

## Conflicts of interest

There are no conflicts of interest.

## REFERENCES

1. Adrogue HJ. Consequences of inadequate management of hyponatremia. *Am J Nephrol* 2005;25:240-9.

2. Alford PW, Dabiri BE, Goss JA, Hemphill MA, Brigham MD, Parker KK. Blast-induced phenotypic switching in cerebral vasospasm. *Proc Natl Acad Sci USA* 2011;108:12705-10.
3. Alves JL, Santiago JG, Costa G, Pinto AM. A standardized classification for subdural hematomas-I. *Am J Forensic Med Pathol* 2016;37:174-8.
4. Back L, Nagaraja V, Kapur A, Eslick GD. Role of decompressive hemicraniectomy in extensive middle cerebral artery strokes: A meta-analysis of randomised trials. *Intern Med J* 2015;45:711-7.
5. Bae DH, Choi KS, Yi HJ, Chun HJ, Ko Y, Bak KH. Cerebral infarction after traumatic brain injury: Incidence and risk factors. *Korean J Neurotrauma* 2014;10:35-40.
6. Bor-Seng-Shu E, Figueiredo EG, Amorim RL, Teixeira MJ, Valbuza JS, de Oliveira MM, *et al.* Decompressive craniectomy: A meta-analysis of influences on intracranial pressure and cerebral perfusion pressure in the treatment of traumatic brain injury. *J Neurosurg* 2012;117:589-96.
7. Chen J, Li M, Chen L, Chen W, Zhang C, Feng Y, *et al.* The effect of controlled decompression for severe traumatic brain injury: A randomized, controlled trial. *Front Neurol* 2020;11:107.
8. Cole CD, Gottfried ON, Liu JK, Couldwell WT. Hyponatremia in the neurosurgical patient: Diagnosis and management. *Neurosurg Focus* 2004;16:E9.
9. Eberle BM, Schnüriger B, Inaba K, Gruen JP, Demetriades D, Belzberg H. Decompressive craniectomy: Surgical control of traumatic intracranial hypertension may improve outcome. *Injury* 2010;41:894-8.
10. Fujisawa H, Maxwell WL, Graham DI, Reasdale GM, Bullock R. Focal microvascular occlusion after acute subdural haematoma in the rat: A mechanism for ischaemic damage and brain swelling? *Acta Neurochir Suppl (Wien)* 1994;60:193-6.
11. Heiss WD. Malignant MCA infarction: Pathophysiology and imaging for early diagnosis and management decisions. *Cerebrovasc Dis* 2016;41:1-7.
12. Huang YH, Lee TC, Lee TH, Yang KY, Liao CC. Remote epidural hemorrhage after unilateral decompressive hemicraniectomy in brain-injured patients. *J Neurotrauma* 2012;30:96-101.
13. Kalita J, Singh RK, Misra UK. Cerebral salt wasting is the most common cause of hyponatremia in stroke. *J Stroke Cerebrovasc Dis* 2017;26:1026-32.
14. Karibe H, Hayashi T, Hirano T, Kameyama M, Nakagawa A, Tominaga T. Surgical management of traumatic acute subdural hematoma in adults: A review. *Neurol Med Chir (Tokyo)* 2014;54:887-94.
15. Mirvis SE, Wolf AL, Numaguchi Y, Corradino G, Joslyn JN. Posttraumatic cerebral infarction diagnosed by CT: Prevalence, origin, and outcome. *AJR Am J Roentgenol* 1990;154:1293-8.
16. Rabinstein AA, Chung SY, Rudzinski LA, Lanzino G. Seizures after evacuation of subdural hematomas: Incidence, risk factors, and functional impact. *J Neurosurg* 2010;112:455-60.
17. Vahedi K, Hofmeijer J, Juettler E, Vicaut E, George B, Algra A, *et al.* Early decompressive surgery in malignant infarction of the middle cerebral artery: A pooled analysis of three randomised controlled trials. *Lancet Neurol* 2007;6:215-22.
18. Vega RA, Valadka AB. Natural history of acute subdural

hematoma. *Neurosurg Clin N Am* 2017;28:247-55.

19. Waikar SS, Mount DB, Curhan GC. Mortality after hospitalization with mild, moderate, and severe hyponatremia. *Am J Med* 2009;122:857-65.

**How to cite this article:** Moughal S, Uberti M, Al-Mousa A, Al-Dwairy S, Shtaya A, Pereira E. Malignant middle cerebral artery infarction following subacute subdural hematoma: A case report and literature review. *Surg Neurol Int* 2021;12:105.