

Fascicular parasystole and recurrent syncope – a case report

Johannes Steinfurt^{1,2*}, Stefan Asbach^{1,2}, Katja E. Odening^{1,2}, Thomas S. Faber^{1,2}, Brigitte Stiller^{2,3}, Christoph Bode^{1,2}, and Jürgen Biermann^{1,2}

¹Department of Cardiology and Angiology I, Heart Center Freiburg University, Hugstetter Str. 55, 79106 Freiburg, Germany; ²Faculty of Medicine, University of Freiburg, 79085 Freiburg, Germany; and ³Department of Congenital Heart Defects and Pediatric Cardiology, Heart Center, Freiburg University, Mathildenstr. 1, 79106 Freiburg, Germany

Received 22 September 2017; accepted 6 February 2018; online publish-ahead-of-print 5 March 2018

Introduction

Parasystole refers to an ectopic pacemaker that discharges with a constant rate competing with the primary pacemaker of the heart the sinus node. Parasystolic pacemakers have been described in the atrium, atrioventricular node, His bundle, and in the ventricle. Ventricular parasystole usually carries a benign prognosis, but there are a few reports of ventricular tachyarrhythmia initiated by parasystolic beats.

Case presentation

We present a case of a 15-year-old otherwise healthy teenager with recurrent most likely arrhythmic syncope who was diagnosed with ventricular parasystole from the left posterior fascicle. After exclusion of structural and primary electrical heart disease, the patient was deemed at increased risk of parasystole-induced tachyarrhythmia, and thus catheter ablation of the ectopic focus was performed. Since catheter ablation the patient continues to be free of any symptoms.

Discussion

This report highlights the potential risks of parasystole in context of recurrent syncope and reviews the available literature on parasystole and ventricular tachyarrhythmia.

Keywords

Fascicular parasystole • Syncope • Ventricular tachycardia • Ventricular fibrillation • Case report

Learning points

- Fascicular parasystole is a rare cardiac arrhythmia caused by an autonomous ventricular focus that can capture the non-refractory ventricle but is protected from the surrounding myocardium due to entrance block.
- Typical electrocardiogram features of parasystole are variable 'coupling' intervals between sinus rhythm beats and ectopic ventricular rhythm, interectopic intervals that are almost exact multiples of the basal ectopic rate, and the presence of fusion beats.
- Although parasystole generally carries a benign prognosis, parasystolic beats may be capable of inducing ventricular tachycardia and ventricular fibrillation on rare occasions.
- Catheter ablation is a curative treatment option for symptomatic patients.

Introduction

Ventricular parasystole is a rare cardiac arrhythmia with an estimated prevalence of 0.1–0.3%¹ that is usually associated with structural heart disease.^{2,3} It is caused by an autonomous ventricular focus that fires at a constant rate and is capable to capture the non-refractory ventricle but is protected from the surrounding myocardium due to some degree of entrance block. This parasystolic activity leads to a unique electrocardiogram (ECG) consisting of monomorphic premature ventricular contractions (PVCs) with variable 'coupling' intervals, intervals between ectopic beats that are almost exact multiples of the basal ectopic rate, and fusion beats.^{4,5} The parasystolic rate is often not completely constant (pure parasystole) because electrotonic influences of sinus rhythm beats can advance or delay the ectopic discharge (modulated parasystole).⁶

* Corresponding author. Tel: +49 761 270 34010, Fax: +49 761 270 73090, Email: johannes.steinfurt@universitaets-herzzentrum.de. This case report was reviewed by Borislav Dinov and Justin Luermans.

© The Author(s) 2018. Published by Oxford University Press on behalf of the European Society of Cardiology.

This is an Open Access article distributed under the terms of the Creative Commons Attribution Non-Commercial License (<http://creativecommons.org/licenses/by-nc/4.0/>), which permits non-commercial re-use, distribution, and reproduction in any medium, provided the original work is properly cited. For commercial re-use, please contact journals.permissions@oup.com

This case report discusses the potential risks of parasystole in the context of recurrent syncope and reviews the existing literature on parasystole and ventricular arrhythmias.

Timeline

Year	Event
2012	1st syncope (during dish washing)
2013	2nd syncope with concussion (during cycling)
2014	Diagnosis of fascicular parasystole and recurrent, most likely arrhythmic syncope. Catheter ablation of ectopic focus and implantation of internal loop-recorder (ILR)
2016	Recurrence of parasystole. Successful catheter ablation of ectopic focus
Since ablation	Normal 12-lead electrocardiogram, Holter, and ILR interrogation without parasystolic activity

Case presentation

A 15-year-old otherwise healthy teenager was admitted for recurrent syncope, a recent exercise-associated episode and another

syncope at relative rest. The two episodes were characterized by sudden onset without any prodromes and absence of specific triggers. On admission, her heart rate (65 b.p.m.), blood pressure (116/69 mmHg), and physical examination were unremarkable. There was no family history of unexplained syncope or sudden cardiac death. The 12-lead ECG, Holter, and exercise stress test revealed no abnormality except for frequent monofocal PVCs, fusion beats, and rare couplets. The total PVC burden ranged from 19% to 23%. The PVCs showed a fascicular morphology, varying coupling intervals, and a constant intrinsic rate consistent with fascicular parasystole from the left posterior fascicle (LPF) (*Figures 1 and 2*). Structural heart disease was ruled out by normal echocardiography and unremarkable contrast-enhanced magnetic resonance imaging. Ajmaline challenge was not performed due to a low pre-test probability for Brugada syndrome⁷ and potential adverse events during ajmaline challenge in this age group.⁸

Catheter ablation was proposed to the patient and her family, and they consented to an interventional strategy. Using a transseptal access guided by intracardiac echocardiography and a 3D mapping system (CARTO 3 with PaSo module, Biosense Webster, Diamond Bar, CA, USA), we performed activation- and pacemapping of the ectopic focus. The earliest activation (-50 ms pre-QRS) with a unipolar qs signal was located in the LPF area at the posterior septum and was effectively targeted by ablation (*Figure 3A*). An internal loop-recorder (ILR) was implanted in order to monitor ablation success and to rule out other causes of syncope. After an uneventful course of more than 2 years and absence of parasystole on Holter and ILR

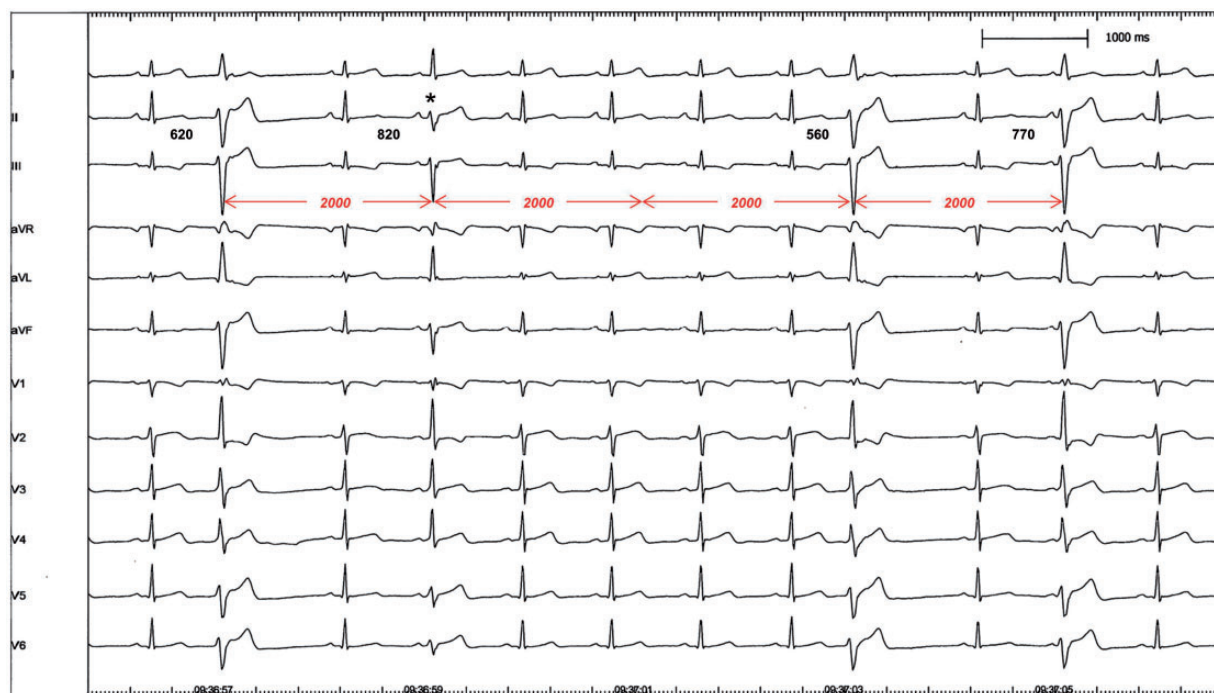

Figure 1 12-lead electrocardiogram with monofocal premature ventricular contractions showing a small R-wave in V₁ and left anterior hemiblock pattern (left axis deviation, rS in inferior leads, qR in aVL). The premature ventricular contractions have completely different ‘coupling’ intervals but identical interectopic intervals (2000 ms) revealing the basal rate of a parasystolic focus (the third parasystolic beat being concealed). Simultaneous activation by parasystole and sinus rhythm (note preceding p-wave) results in a fusion beat (*).

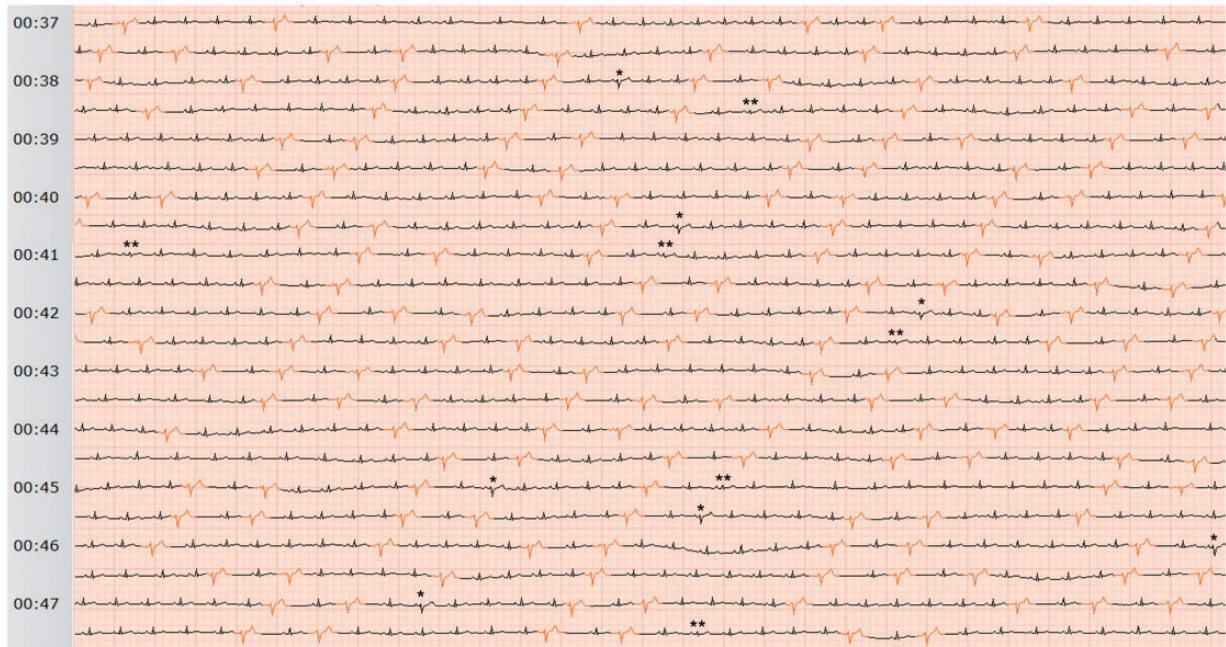


Figure 2 Holter electrocardiogram with parasystole and occasional fusion beats resulting from fusion of parasystole occurring shortly before sinus rhythm (*) and fusion of sinus rhythm occurring shortly before parasystole (**). The parasystolic rate is not completely constant.

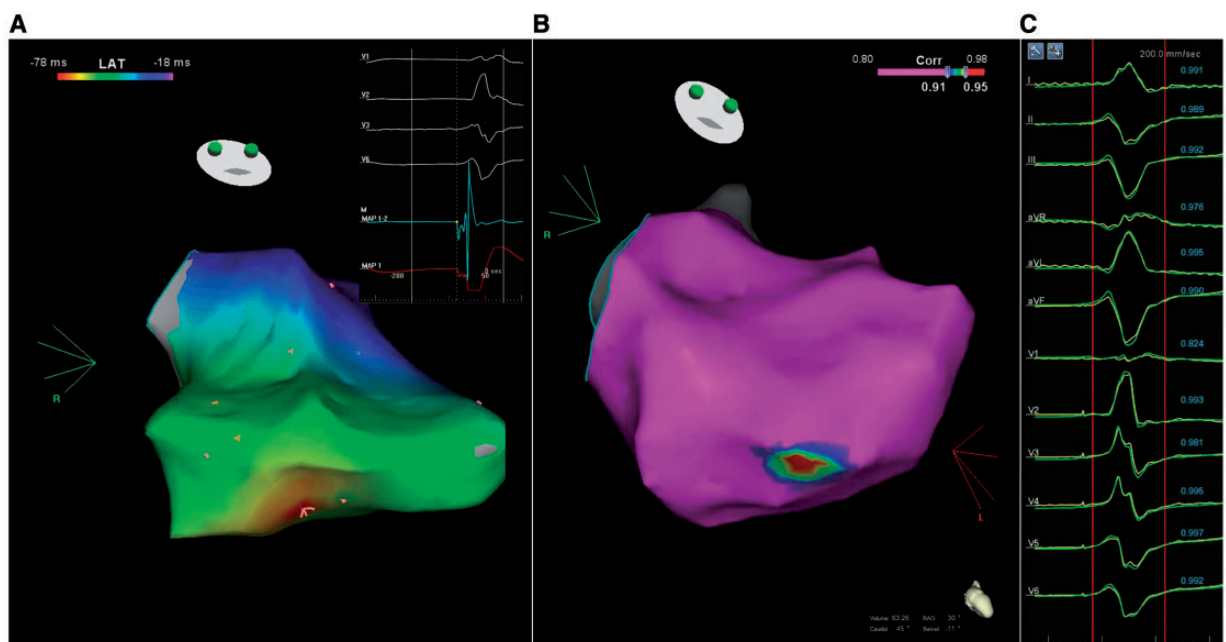


Figure 3 (A) Left ventricle in right anterior oblique view demonstrating a postero-septal origin of parasystole in the area of the posterior fascicle. (B) Left ventricle in right anterior oblique view with PaSo pace map indicating the highest pace map correlation again postero-septal. (C) Perfect match (12/12) of paced QRS morphology (yellow) with parasystole (green) at the site of highest correlation. Note the small low-output pacing spikes to ensure local capture. Corr, correlation; LAT, local activation time.

interrogations, the patient presented again with palpitations and dizziness related to a late recurrence of parasystole. A detailed activation map with a multipolar mapping catheter—to enhance the detection of Purkinje potentials—was attempted but limited by early mechanical termination of parasystole which was unresponsive to isoproterenol. However, a perfect pace map reconfirmed precisely the LPF region again as origin of the parasystolic focus and enabled targeted ablation of the culprit area (Figure 3B and C). Since then, repeated Holter recordings and ILR interrogation confirmed absence of parasystole and the patient continues to be free of any symptoms.

Discussion

Parasystole is an extremely rare cardiac arrhythmia, especially in a young teenager without structural heart disease. Although ventricular parasystole is generally considered a benign condition,⁴ even after myocardial infarction,^{2,3} a closely coupled parasystolic PVC falling on the descending T wave could potentially be proarrhythmic.^{4,9} Indeed, there are scarce reports of ventricular tachycardia (VT) and also ventricular fibrillation (VF) initiated by parasystolic beats in patients with structural heart disease or hypokalaemia.^{10–14} In addition, the Purkinje network—the likely origin of fascicular parasystole in this case—is a well-known source for VT and VF in patients with and without structural heart disease.¹⁵ The parasystolic rate in our patient was not completely constant on Holter (Figure 2), and particularly modulated parasystole seems to be associated with malignant ventricular tachyarrhythmia according to one study.¹² We did not document any tachyarrhythmia in this case, but our patient experienced recurrent, most likely arrhythmic syncope. After exclusion of structural and primary electrical heart diseases like long QT syndrome and catecholaminergic polymorphic VT, our patient was deemed at increased risk of ventricular tachyarrhythmia caused by a parasystolic PVC. Thus, catheter ablation of the ectopic focus was performed.

Conclusion

Patients with fascicular parasystole and recurrent arrhythmic syncope may be at increased risk of malignant ventricular tachyarrhythmia.

Catheter ablation is a curative treatment option for symptomatic patients.

Consent: The author/s confirm that written consent for submission and publication of this case report including image(s) and associated text has been obtained from the patient in line with COPE guidance.

Conflict of interest: none declared.

References

1. Glancy DL. Group beating resulting from ventricular parasystole. *Proc (Bayl Univ Med Cent)* 2003;**16**:352–353.
2. Salazar J, McKendrick CS. Ventricular parasystole in acute myocardial infarction. *Br Heart J* 1970;**32**:377–385.
3. Kotler MN, Tabatznik B, Mower MM, Tominaga S. Prognostic significance of ventricular ectopic beats with respect to sudden death in the late postinfarction period. *Circulation* 1973;**47**:959–966.
4. Antzelevitch C, Burashnikov A. Overview of basic mechanisms of cardiac arrhythmia. *Card Electrophysiol Clin* 2011;**3**:23–45.
5. Issa ZF, Miller JM, Zipes DP, eds. Chapter 3—Electrophysiological mechanisms of cardiac arrhythmias. In: *Clinical Arrhythmology and Electrophysiology: A Companion to Braunwald's Heart Disease*. 2nd ed. Philadelphia: W.B. Saunders; 2012. p36–61.
6. Jalife J. Modulated parasystole: still relevant after all these years! *Heart Rhythm* 2013;**10**:1441–1443.
7. Steinfurt J, Biermann J, Bode C, Odening KE. The diagnosis, risk stratification, and treatment of Brugada syndrome. *Dtsch Arztebl Int* 2015;**112**:394–401.
8. Conte G, Sieira J, Sarkozy A, de Asmundis C, Di Giovanni G, Chierchia G-B, Ciconte G, Levinstein M, Casado-Arroyo R, Baltogiannis G, Saenen J, Saitoh Y, Pappaert G, Brugada P. Life-threatening ventricular arrhythmias during ajmaline challenge in patients with Brugada syndrome: incidence, clinical features, and prognosis. *Heart Rhythm* 2013;**10**:1869–1874.
9. Lerma C, Glass L. Predicting the risk of sudden cardiac death. *J Physiol (Lond)* 2016;**594**:2445–2458.
10. Jacobson LB. Spontaneous ventricular parasystole initiating ventricular tachycardia. *J Electrocardiol* 1973;**6**:63–70.
11. Doshchitsin VL, Gendlin GE. Parasystolic arrhythmias. *Kardiologija* 1977;**17**:54–60.
12. Robles de Medina EO, Delmar M, Sicouri S, Jalife J. Modulated parasystole as a mechanism of ventricular ectopic activity leading to ventricular fibrillation. *Am J Cardiol* 1989;**63**:1326–1332.
13. Szpot M. Case of ventricular fibrillation recorded during Holter monitoring and initiated by ventricular parasystole. *Prz Lek* 1994;**51**:319–321.
14. Itoh E, Aizawa Y, Washizuka T, Uchiyama H, Kitazawa H, Kusano Y, Naitoh N, Shibata A. Two cases of ventricular parasystole associated with ventricular tachycardia. *Pacing Clin Electro* 1996;**19**:370–373.
15. Haissaguerre M, Vigmond E, Stuyvers B, Hocini M, Bernus O. Ventricular arrhythmias and the His-Purkinje system. *Nat Rev Cardiol* 2016;**13**:155–166.