



Contents lists available at ScienceDirect

International Journal of Surgery Case Reports

journal homepage: www.casereports.com

Acute perforating appendicitis caused by metastatic squamous cell carcinoma from the lung: A case report

Toshio Shiraishi^{a,b,*}, Masato Araki^a, Yorihisa Sumida^a, Tomohiro Fujita^a, Shintaro Hashimoto^a, Masato Nishimuta^a, Takamune Matsumoto^a, Kiyoaki Hamada^a, Masayuki Baba^a, Goushi Murakami^a, Kouki Wakata^a, Yukio Inamura^a, Shigeyuki Morino^a, Akihiro Nakamura^a, Daisuke Niino^c, Tetsuro Tominaga^b, Takashi Nonaka^b, Terumitsu Sawai^b, Takeshi Nagayasu^b

^a Department of Surgery, Sasebo City General Hospital, 9-3 Hirase-machi, Sasebo, Nagasaki, 857-8511, Japan

^b Department of Surgical Oncology, Nagasaki University Graduate School of Biomedical Science, 1-7-1 Sakamoto, Nagasaki, 852-8501, Japan

^c Department of Pathology, Sasebo City General Hospital, 9-3 Hirase-machi, Sasebo, Nagasaki, 857-8511, Japan

ARTICLE INFO

Article history:

Received 13 September 2020

Received in revised form 24 October 2020

Accepted 24 October 2020

Available online 29 October 2020

Keywords:

Appendicitis

Lung cancer

Squamous cell carcinoma

Metastasis

Case report

ABSTRACT

INTRODUCTION: Lung cancer is one of the most common cancers. On the other hand, lung cancer metastasis to the appendix is extremely rare, and in many cases it has been diagnosed with the onset of acute perforating appendicitis.

PRESENTATION OF CASE: An 85-year-old man with fever and abdominal pain visited our hospital. He had a history of squamous cell carcinoma of the left upper and lower lobes, metastasis to the ipsilateral lung and femur. CT showed that a finding of acute perforating appendicitis, emergency cecal resection was performed. Examination of the resected specimen showed that the appendix was thickened overall, with a white nodular structure at the root and a perforation in the middle. The final diagnosis was acute perforating appendicitis caused by metastatic squamous cell carcinoma from the lung. The patient had no particular problems during the postoperative course.

DISCUSSION: A PubMed search was performed, this appears to be the first reported case of appendiceal metastasis of squamous cell carcinoma of the lung. Since squamous cell carcinoma of the lung has a stronger tendency for local extension than other histological types, perforating appendicitis due to distant metastasis to the abdominal organs and metastasis to the appendix was reported as a very valuable case.

CONCLUSION: Because the progression of concomitant or secondary appendicitis is rapid, we recommend frequent imaging modalities, prophylactic appendectomy be considered for patients who also have lung cancer and imaging findings show suspected metastasis to the appendix.

© 2020 The Author(s). Published by Elsevier Ltd on behalf of IJS Publishing Group Ltd. This is an open access article under the CC BY-NC-ND license (<http://creativecommons.org/licenses/by-nc-nd/4.0/>).

1. Introduction

Lung cancer is one of the most common cancers, and the more the disease progresses, the more frequently it will metastasize to the ipsilateral lymph nodes, bones, and brain. However, lung cancer metastasis to the appendix is extremely rare, and in many cases it has been diagnosed with the onset of acute perforating appendicitis [1–3]. In addition, small cell carcinoma and adenocarcinoma are often reported as the histological types of lung cancer that cause metastatic appendiceal tumor [4,5]. An extremely rare case of surgery for acute perforated appendicitis

due to appendiceal metastasis of squamous cell carcinoma of the lung is reported.

2. Presentation of case

An 85-year-old man visited our hospital because of persistent fever and pain. He had a history of squamous cell carcinoma of the left upper and lower lobes, metastasis to the ipsilateral lung and femur, home oxygen therapy, etc. He was followed-up for the lung cancer at another hospital. At the time of admission, there was right lower abdominal pain. Blood test findings showed high inflammation, normal range of tumor marker levels obtained CEA, ProGRP, and CYFRA. Chest-abdominal contrast-enhanced computed tomography (CT) showed an existing squamous cell carcinoma in the left upper and lower lobes (Fig. 1). The appendix was swollen, with a maximum diameter of about 20 mm, with an increased concen-

* Corresponding author at: Toshio Shiraishi Department of Surgical Oncology, Nagasaki University Graduate School of Biomedical Science, 1-7-1 Sakamoto, Nagasaki, 852-8501, Japan.

E-mail address: toshio.shiraishi1022@gmail.com (T. Shiraishi).

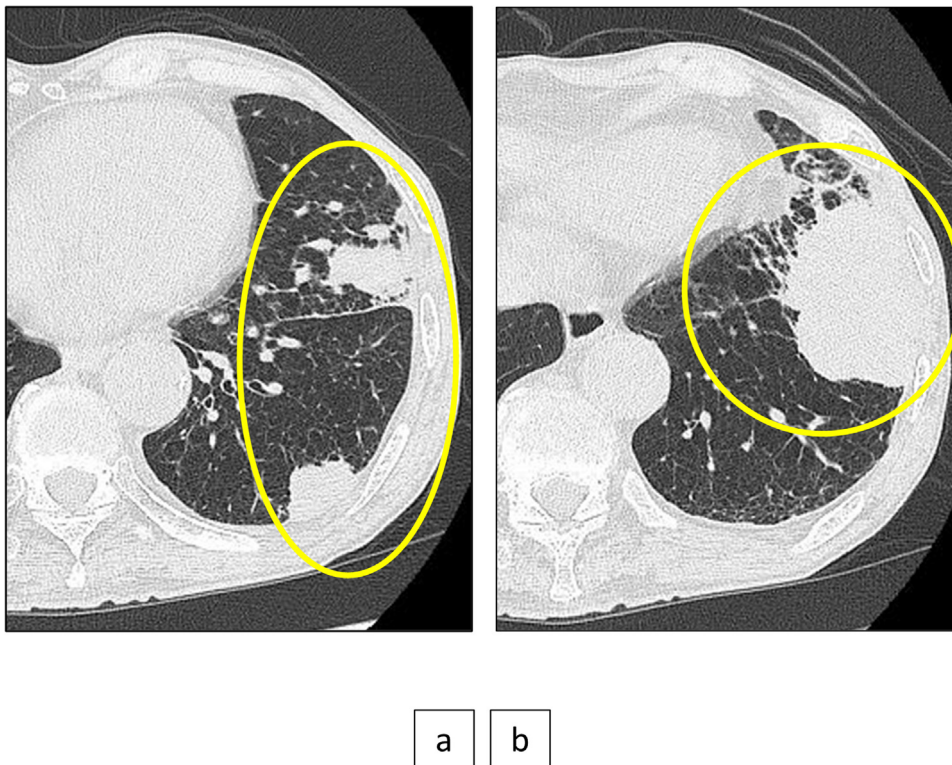


Fig. 1. CT shows an existing squamous cell carcinoma.

tration of surrounding fat tissue, a finding of acute appendicitis. Nodules were found near the cecum, mesentery, peripancreatic area, dorsal side of the left kidney, etc., and were considered to be metastases or dissemination (Fig. 2). Because of his advanced age, history of many previous illnesses, and the fact that he did not want emergency surgery, he was followed-up with conservative treatment. He was admitted to the hospital, and treatment with antibiotics was started. Two days later, he vomited and the blood test showed relapse of inflammation. It was getting worse even in CT, emergency surgery was performed with the consent of the patient.

A midline incision was placed about 10 cm above and below the navel. A perforation was confirmed in the middle of the appendix, and an abscess had formed around the appendix. A white nodular structure near the cecum was considered to be the cause of the perforated appendicitis. The abscess wall and the small intestine were adhered to each other. No nodules were found on the abdominal wall or pelvic floor, but white nodules were also scattered in the mesentery. Cecal resection was performed, the operation time was 83 min, and the blood loss was 98 g.

Examination of the resected specimen showed that the appendix was thickened overall, with a white nodular structure at the root and a perforation in the middle (Fig. 3). Histopathologically (Fig. 4), atypical cells formed large and small tumor vesicles in the thickened appendix wall, and the tumor cells proliferated invasively, centering on the proper muscle layer. On immunostaining, the results were p40(+), CK (cytokeratin)5/6(+). The final diagnosis was acute perforating appendicitis caused by metastatic squamous cell carcinoma from the lung.

The patient had no particular problems during the postoperative course, and he was transferred to the hospital on the 20th day after the operation.

3. Discussion

Acute appendicitis is a common disease, whereas primary and metastatic appendiceal tumors are rare [6]. Breast, lung, stomach, large intestine, pancreas, and others have been reported as the primary organs for metastatic appendiceal tumors [7]. The frequency of metastatic appendiceal tumors due to primary lung cancer is extremely low, with Taira et al. reporting 1/2066 for lung cancer and Dieter et al. reporting 2/4500 [1,2]. Small cell carcinoma and adenocarcinoma are often reported as the histological types of lung cancer causing metastatic appendiceal tumors [4,5,8]. A PubMed search, using keywords such as “lung cancer”, “metastasis”, “appendix”, and “acute appendicitis”, was performed, and this appears to be the first reported case of appendiceal metastasis of squamous cell carcinoma of the lung. Since squamous cell carcinoma of the lung has a stronger tendency for local extension than other histological types, perforating appendicitis due to distant metastasis to the abdominal organs and metastasis to the appendix was reported as a very valuable case.

Metastatic pathways of lung cancer to the appendix include lymphatic or hematogenous metastasis, and metastatic foci are formed in the submucosa or muscular layer. A metastatic appendiceal tumor may be diagnosed before the onset of appendicitis, but the increase in size of metastatic lesions may cause stenosis or obstruction of the lumen of the appendix, and an increase in internal appendiceal pressure often leads to a diagnosis of appendicitis [3]. In addition, appendicitis due to a metastatic appendiceal tumor results in severe inflammation caused by obstruction and is likely to cause perforation [9]. On the other hand, there has also been a report of intestinal stricture caused by peritoneal dissemination of lung cancer [10]. Intestinal invasion by peritoneal dissemination invades from the serosal surface of the intestine toward the lumen, so that it is difficult to close the lumen. Therefore, it is considered

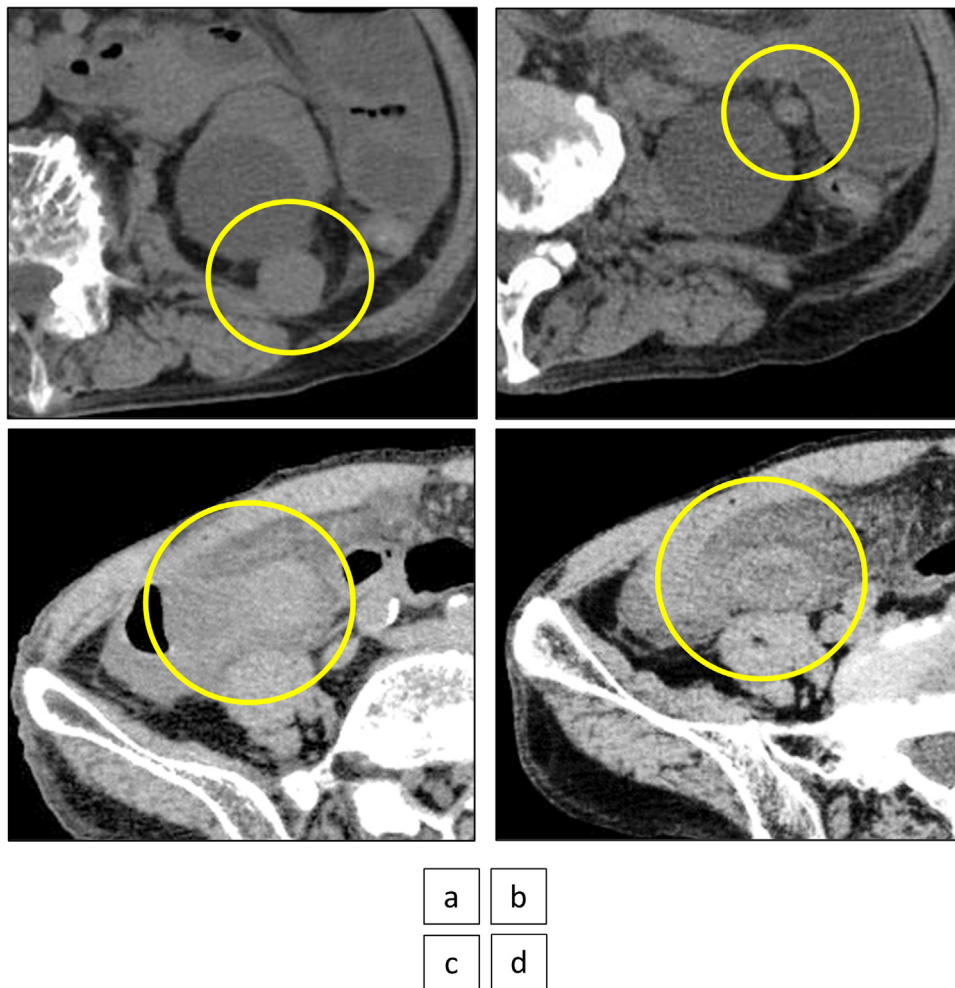


Fig. 2. Nodules are considered to be metastases or dissemination, and the appendix shows findings of acute appendicitis.

- a) Nodule on the dorsal side of the left kidney.
- b) Nodule of the peripancreatic area.
- c) Nodule near the cecum.
- d) The appendix was swollen with an increased concentration of surrounding fat tissue.

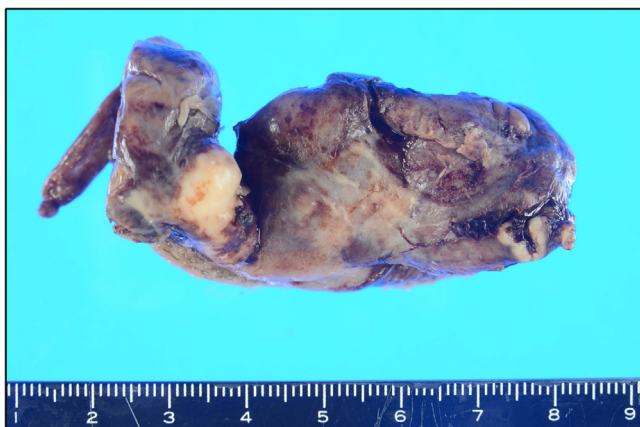

Fig. 3. The appendix is thickened overall, with a white nodular structure at the root and a perforation in the middle.

that it takes a relatively long time to develop acute appendicitis even if peritoneal dissemination is present in the vicinity.

In the present case, pathologically, the tumor cells proliferated, infiltrating mainly in the proper muscle layer, and immunostaining resulted in a diagnosis of metastatic appendiceal tumor of

squamous cell carcinoma of the lung. The appendix was found to be highly inflamed and perforated, with abscess formation around it. In addition, it was considered that the nodules were all disseminated squamous cell carcinoma of the lung, and the appendicitis developed due to infiltration of the appendix, but a metastatic appendiceal tumor was eventually diagnosed on pathological examination. It was difficult to determine whether metastasis or dissemination on preoperative imaging examination or intraoperative macroscopic evaluation.

CT is one of the useful imaging modalities, but it is difficult to diagnose metastatic appendiceal tumor at an early stage, and most of the cases reported were diagnosed as metastatic appendiceal tumor after the onset of abdominal symptoms or after surgery [3,11]. In addition, there are also case reports of a metastatic appendiceal tumor diagnosed by positron emission tomography (PET) examination, which is considered to be a useful examination [12]. In this case, CT showed nodules in the abdominal cavity and retroperitoneum, which may have been diagnosed as appendiceal metastasis had PET been performed before the time of acute appendicitis. In patients with lung cancer who have metastasized to intra-abdominal organs, especially suspected appendiceal metastasis, CT follow-up within a short period of time or PET are necessary because early diagnosis lead to avoidance of emergency surgery.

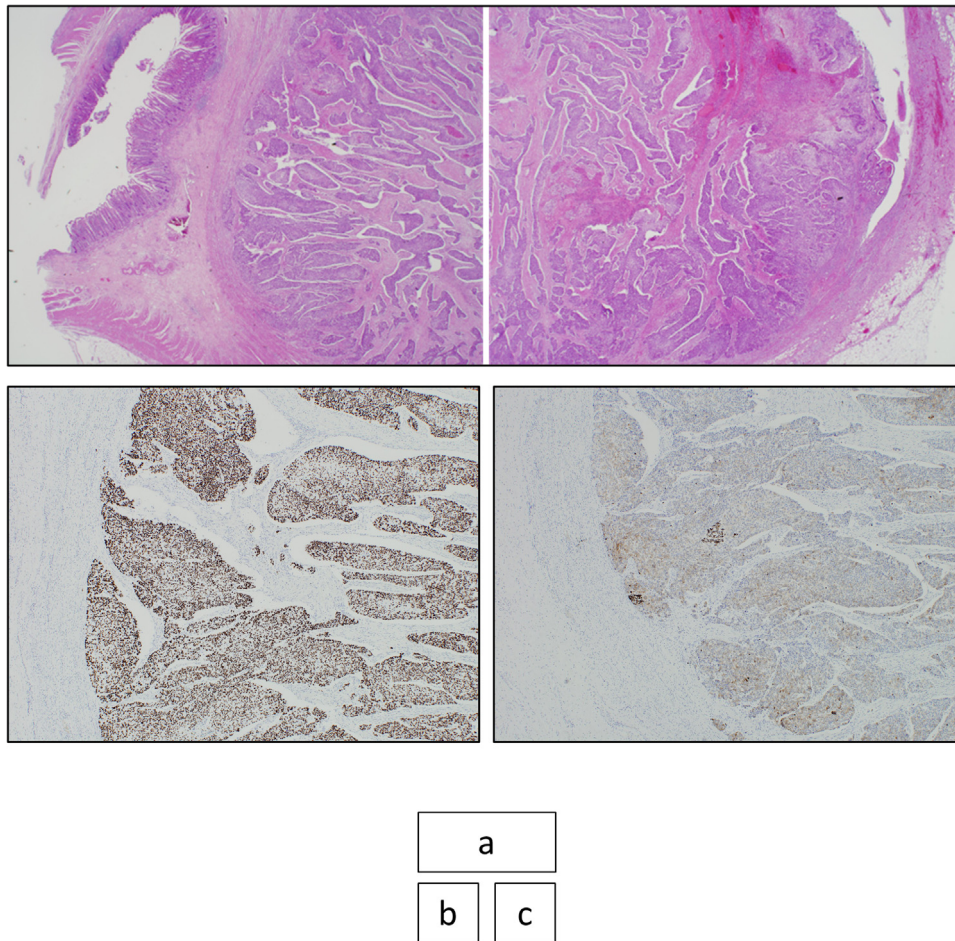


Fig. 4. Histopathological findings.

- a) Atypical cells form large and small tumor vesicles in the thickened appendix wall, and the tumor cells proliferate invasively, centering on the proper muscle layer (HE).
- b) Immunostaining shows p40(+).
- c) Immunostaining shows CK5/6(+).

This work has been reported in line with the SCARE 2018 criteria [13].

4. Conclusion

Acute appendicitis in patients with lung cancer may be due to a rare metastatic appendiceal tumor. We recommend frequent imaging modalities, prophylactic appendectomy be considered for patients who also have lung cancer and imaging findings show suspected metastasis to the appendix because the progression of concomitant or secondary appendicitis is rapid.

This case report is compliant with the SCARE Guidelines 2018.

Declaration of Competing Interest

The authors report no declarations of interest.

Sources of funding

This study was not supported by any grant.

Ethical approval

Not applicable.

Consent

Written informed consent was obtained from the patient for publication of this case report and accompanying images. A copy of the written consent is available for review by the Editor-in-Chief of this journal on request.

Author contribution

Toshio Shiraishi was responsible for the study concept. All authors have read and approved the final version of the manuscript.

Registration of research studies

1. Name of the registry: Acute perforating appendicitis caused by metastatic squamous cell carcinoma from the lung: report of a case and review of the literature.
2. Unique identifying number or registration ID: researchregistry6115.
3. Hyperlink to your specific registration (must be publicly accessible and will be checked): <https://www.researchregistry.com/register-now#home/>.

Guarantor

Toshio Shiraishi.

Provenance and peer review

Not commissioned, externally peer-reviewed.

References

- [1] N. Taira, T. Kawabata, A. Gabe, et al., Analysis of gastrointestinal metastasis of primary lung cancer: clinical characteristics and prognosis, *Oncol. Lett.* 14 (2017) 2399–2404.
- [2] R.A. Dieter Jr, Carcinoma metastatic to the vermiform appendix. Report of three cases, *Dis. Colon Rectum* 13 (1970) 59–60.
- [3] Y. Kimura, T. Machimoto, D. Yasukawa, et al., Acute appendicitis caused by metastatic adenocarcinoma from the lung: a case report, *Surg. Case Rep. Rev.* 4 (59) (2018).
- [4] D. Keramidaris, C. Oikonomou, K. Theodorolea, et al., Acute perforated appendicitis due to metastatic small-cell lung cancer, *Turk. J. Gastroenterol.* 30 (2019) 993–994.
- [5] K. Miyazaki, H. Satoh, K. Sekizawa, et al., Metastasis to appendix from lung adenocarcinoma, *Int. J. Gastrointest. Cancer* 36 (2005) 59–60.
- [6] C. Wolf, P. Friedl, P. Obrist, et al., Acute appendix; sonographic appearance and review of the literature, *J. Ultrasound Med.* 18 (1999) 23–25.
- [7] R.E. Burney, N. Koss, I.S. Goldberg, Acute appendicitis secondary to metastatic carcinoma of the breast, *Arch. Surg.* 108 (1974) 872–875.
- [8] S. Kiriyaama, N. Yamamoto, M. Nakamura, et al., A case of appendiceal metastasis from combined small cell lung carcinoma, *J. Jpn. Surg. Assoc.* 76 (2018) 1257–1263.
- [9] E.B. Goldstein, R.H. Savel, K.L. Walter, et al., Extensive stage small cell lung cancer presenting as an acute perforated appendix: case report and review of the literature, *Ann. Surg.* 70 (2004) 706–709.
- [10] K. Uchiyama, M. Nakamura, S. Tsukinaga, et al., A case of widespread ileal stenosis by metastatic disseminated peritoneal carcinomatosis from lung cancer resected 8 years previously, *J. Jpn. Soc. Gastroenterol.* 104 (2007) 381–387.
- [11] R. Sundararajan, A.B. Landman, Acute appendicitis from metastatic small cell lung cancer, *West. J. Emerg. Med.* 13 (2012) 94–95.
- [12] H.L. Park, R. Yoo Je, E.K. Choi, et al., Acute appendicitis secondary to metastatic small cell lung cancer incidentally found on F-18 FDG PET/CT, *Clin. Nucl. Med.* 37 (2012) e19–21.
- [13] R.A. Agha, M.R. Borrelli, R. Farwana, K. Koshy, A. Fowler, D.P. Orgill, For the SCARE Group, The SCARE 2018 statement: updating consensus Surgical Case REport (SCARE) guidelines, *Int. J. Surg.* 60 (2018) 132–136.

Open Access

This article is published Open Access at [sciencedirect.com](https://www.sciencedirect.com). It is distributed under the [IJSCR Supplemental terms and conditions](#), which permits unrestricted non commercial use, distribution, and reproduction in any medium, provided the original authors and source are credited.