

Received: 2017.09.26
Accepted: 2017.10.12
Published: 2018.01.12

e-ISSN 1941-5923
© Am J Case Rep, 2018; 19: 47-51
DOI: 10.12659/AJCR.907291

A Case of Right-Sided Direct Carotid Cavernous Fistula: A Diagnostic Challenge

Authors' Contribution:
Study Design A
Data Collection B
Statistical Analysis C
Data Interpretation D
Manuscript Preparation E
Literature Search F
Funds Collection G

ABCDEF 1 **Htun Latt**
CDEF 2 **Kyaw Kyaw**
CDEF 1 **Htwe Htwe Yin**
EFG 1 **Deepak Kapoor**
EFG 2 **Sammy San Myint Aung**
EFG 1 **Raheel Islam**

1 Department of Internal Medicine, University of Nevada-Reno, School of Medicine, Reno, NV, U.S.A.
2 Institute for Heart and Vascular Health, Renown Regional Medical Center, Reno, NV, U.S.A.

Corresponding Author: Htun Latt, e-mail: htunlatt888@gmail.com
Conflict of interest: None declared

Patient: Female, 83
Final Diagnosis: Right-sided direct carotid cavernous fistula
Symptoms: Chemosis • proptosis and eye pain
Medication: Topical α -2-adrenergic agonist
Clinical Procedure: Endovascular embolization
Specialty: Internal Medicine • Interventional Radiology • Ophthalmology

Objective: Rare disease/diagnostic challenge





Background: Carotid cavernous fistulas (CCFs) are rare potentially sight-threatening abnormal connections between carotid artery and cavernous sinus.

Case Report: We report a case of CCF in an 83-year-old female, who presented with swollen and painful right eye. The patient was initially treated with empiric antibiotics for suspected peri-orbital cellulitis, as noted clinically and in computed tomography (CT) orbits. However, lack of clinical improvement, physical finding of orbital bruit/thrill, and enlarged superior ophthalmic vein in magnetic resonance (MR) orbits suggest alternate diagnoses. Eventually, CT angiogram (CTA) and carotid-arteriography confirmed the diagnosis of right-sided direct CCF, which was subsequently treated with endovascular embolization. Not only does this case highlight the importance of CCF, which could be a differential diagnosis of swollen red eye, it also addresses the vital importance of physical examination in modern medicine despite the seemingly promising technologies.

Conclusions: Internists should have a low threshold of clinical suspicion for CCF in a patient with swollen red eyes in order to provide timely and proper management.

MeSH Keywords: Carotid-Cavernous Sinus Fistula • Endovascular Procedures • Exophthalmos • Orbital Cellulitis

Full-text PDF: <https://www.amjcaserep.com/abstract/index/idArt/907291>

 1257   4  15



Background

Carotid cavernous fistulas (CCF) are abnormal connections between the carotid artery and cavernous sinus, which can be either direct (high flow) or indirect (low flow) communication. It may occur spontaneously or due to secondary causes. We report a case of right-sided direct CCF that could be a diagnostic challenge for internists.

Case Report

An 83-year-old female with hypertension and dyslipidemia presented to emergency department (ED) with worsening pain and swelling over the right eye. A week ago, the patient visited the ED for the similar complaint without vision changes and she was discharged with a short course of oral prednisone for “allergic conjunctivitis”. Back then, she recalled having right eye itching shortly after eating shrimp. Then the next morning, she woke with a swollen right eye and inability to open it. She denied any known history of food or drug

allergy. At the present visit, the patient complained of right-sided blurred vision. Her vital signs were stable and physical examination showed chemosis and tenderness over the right orbit (Figure 1). Both pupils were equal and reactive. Visual acuity was 20/30 for both eyes with corrective lens. Because of severe chemosis, ophthalmoplegia was difficult to assess for the right eye. Otherwise, the examination was normal. Workup showed normal white count without left shift, erythrocyte sedimentation rate, C reactive protein, ferritin and thyroid function test (TFT). Computed tomography (CT)-orbits-sella showed pre-septal cellulitis without evidence of abscess. She was empirically treated with antibiotics (vancomycin and piperacillin-tazobactam) and topical α 2-adrenergic agonist (brimonidine). Ophthalmology was consulted.

Despite empiric antibiotics, the patient did not show improvement on the following day. There continued to be no evidence of infection (no fever, leukocytosis). So, further imaging was pursued. Magnetic resonance imaging (MRI) of the brain was unremarkable. Additionally, MR-orbits, face and neck, showed right pre- and post-septal orbital cellulitis and enlarged right superior ophthalmic vein with concern for non-occlusive venous thrombosis (Figure 2). However, MR venogram (MRV) of the head showed no evidence of intracranial venous sinus thrombosis. Additionally, MR angiogram (MRA) of the head showed normal circle of Willis. Further blood work including quantiferon test, treponemal antibody test, thyrotropin receptor antibody, thyroid stimulating immunoglobulin (TSI), rheumatoid factor (RF), anti-neutrophil cytoplasmic antibody (ANCA), and anti-nuclear antibody (ANA) were negative.

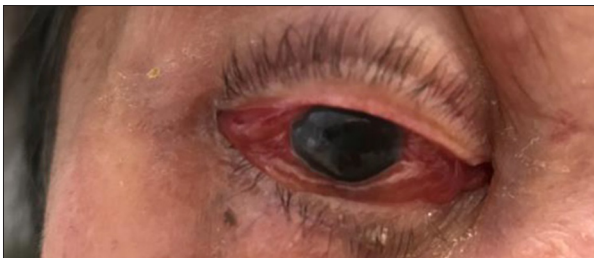

Figure 1. Right eye showing severe chemosis and proptosis.

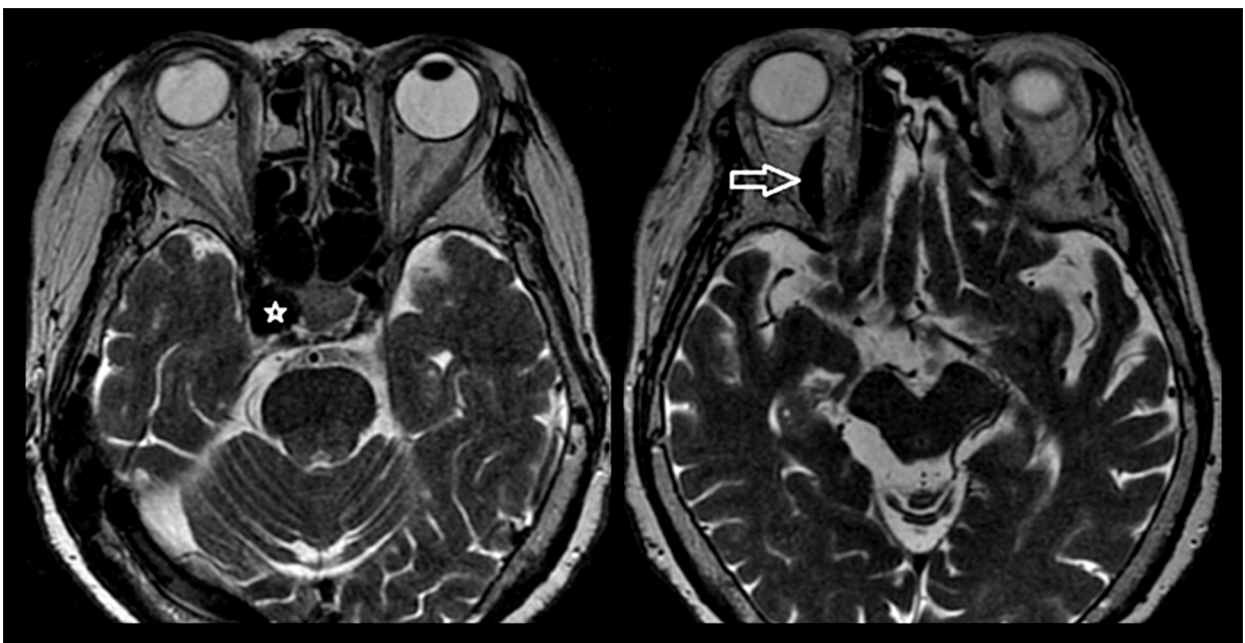


Figure 2. MR-orbits showing enlarged right cavernous sinus (white star) and enlarged right superior ophthalmic vein (white arrow).

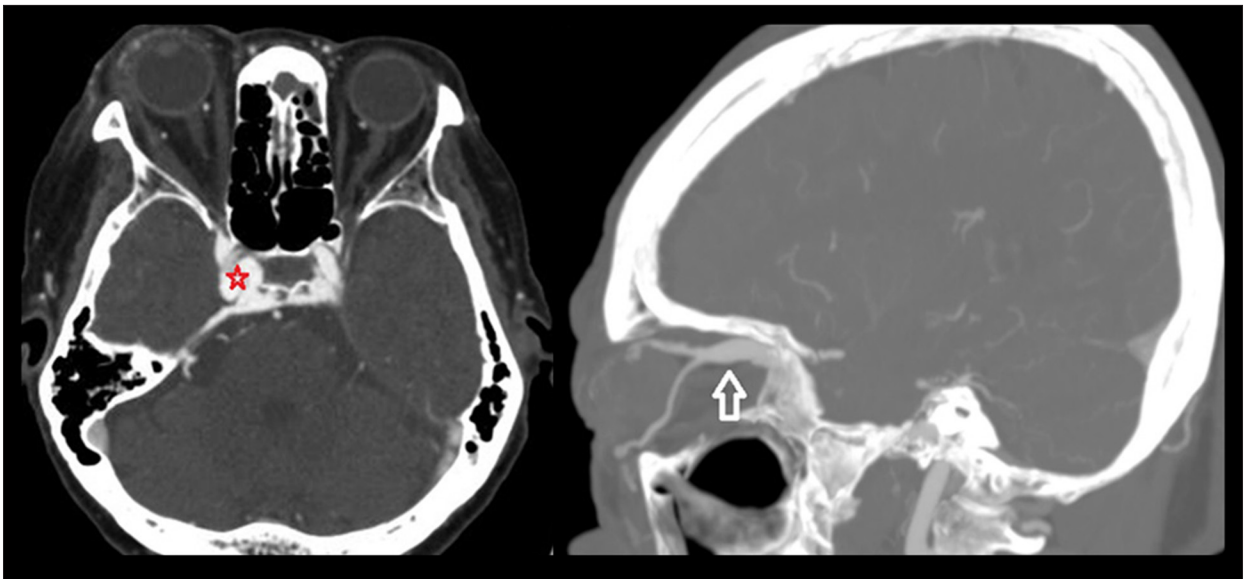


Figure 3. CTA of the head showing extensive arterial filling of the right cavernous sinus (red star) and enlarged right superior ophthalmic vein (white arrow).

On repeat examination of the eye, a bruit with palpable thrill was noted over the right eyeball. Tonometry readings were 38 mm Hg and 22 mm Hg on right and left eyes respectively and visual acuity remained unchanged. Brominidine was stopped and topical brimonidine/timolol (combigan) was initiated. Given the orbital bruit/thrill and enlarged superior ophthalmic vein, CCF was suspected. Eventually, CTA of the head showed extensive arterial filling of the cavernous sinus and arterial opacification with bilateral superior ophthalmic veins, right greater than the left (Figure 3). Subsequently, carotid angiogram revealed early filling of the cavernous sinus and bilateral superior ophthalmic veins with more enlargement on the right than the left upon injection of the right internal carotid artery (ICA), confirming the diagnosis of right-sided direct CCF (Figure 4). No filling of the cavernous sinus was seen on the injection of the left ICA. So, antibiotics were discontinued and endovascular obliteration was planned. However, because of the temporary unavailability of neuro-interventionist at our facility, the patient was transferred to a tertiary facility for endovascular embolization of the right CCF. The patient tolerated the procedure and follow-up at our facility within four weeks showed normal eye examination with stable vision.

Discussion

Carotid cavernous fistulas (CCFs) are rare, abnormal connections between the carotid artery and cavernous sinus, which can be either direct (high flow) or indirect (low flow) communication. Barrow et al. reported a classification of CCFs as follows: direct (high-flow) communication of the carotid artery and cavernous sinus (Type A), indirect communications

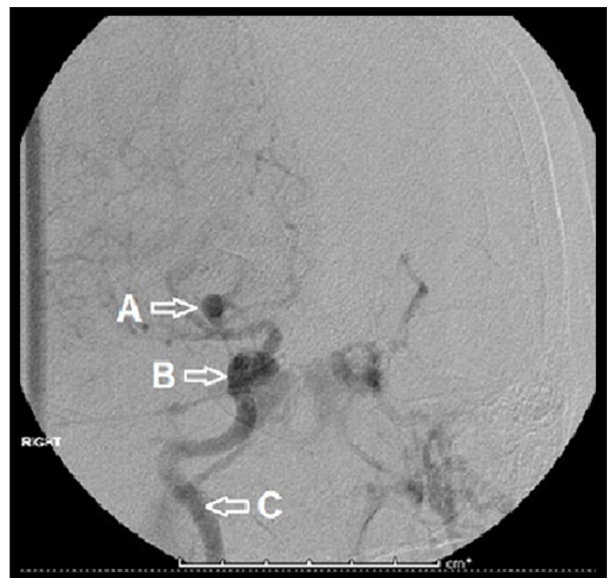

Figure 4. Carotid angiogram showing enlarged right superior ophthalmic vein (A) and early filling of the right cavernous sinus (B) upon injection of the right internal carotid artery (C).

of the cavernous sinus with branches of the cavernous carotid artery (Type B), or dural branches of external carotid artery (Type C), or both the branches of external and internal carotid arteries (Type D) [1].

The CCFs may occur spontaneously or following secondary causes (trauma, vascular aneurysm or malformations and venous thrombosis). Direct CCFs are often caused by head trauma or rupture of intra-cavernous aneurysm or head surgery [2–5].

There is limited data regarding the incidence of CCFs, either primary or secondary types. However, through retrospective analysis, Liang et al. reported that the overall incidence of traumatic CCF was 3.8% among patients with basilar skull fractures [4]. Sudden increase in pressure within the internal carotid artery (ICA) may be the mechanism for the development of direct CCF [6]. Based on the different types, the presentation of CCFs is highly variable. Direct CCFs mostly present with orbital bruit (80%), proptosis (72%), chemosis (55%), abducens nerve palsy (49%), and conjunctival injection (44%) [7]. Vision loss is one of the most fearful complications of CCFs. Sight threatening complications may occur in direct CCF due to severe exposure keratopathy, corneal ulcerations, and possibly central retinal artery occlusion [8]. Currently, no data is available for incidence of vision loss if the direct CCF is not properly and timely treated.

Indirect CCFs often occur spontaneously and are more common in older women [1,9]. The cause of indirect CCFs is unknown and their presentations can vary widely by the patterns of venous drainage and the speed of blood flow. Indirect CCF especially of anterior drainage pattern may threaten the vision through increased intraocular pressure (due to venous congestion) [10].

The differential diagnoses of CCFs are cerebral aneurysms, vascular malformations of eyes, inflammation of orbits, retro-orbital cellulitis, thyroid exophthalmos, retrobulbar hemorrhage, tumor of lacrimal gland, cavernous sinus thrombosis, and vasculitis [11]. CCFs may be suggested by clinical evaluation and imaging studies, especially MR-orbits and CTA or MRA of the head. However, the gold standard test for CCFs remains carotid digital arteriography [5]. Treatment decision depends on the severity of clinical presentations [12]. Generally, treatment of CCFs is suggested if there are worsening visual function, severe proptosis, cranial nerve palsies, intractable bruit, intraocular pressure of more than 25 mm Hg, and increased filling of cortical veins on angiography [11,13]. The prognosis of CCFs is excellent after endovascular treatment [14,15].

References:

1. Barrow DL, Spector RH, Braun IF et al: Classification and treatment of spontaneous carotid-cavernous sinus fistulas. *J Neurosurg*, 1985; 62(2): 248–56
2. Ringer AJ, Salud L, Tomsick TA: Carotid cavernous fistulas: Anatomy, classification, and treatment. *Neurosurg Clin N Am*, 2005; 16(2): 279–95, viii
3. Marín-Fernández AB, Cariati P, Román-Ramos M et al: Posttraumatic carotid-cavernous fistula: Pathogenetic mechanisms, diagnostic management and proper treatment. A case report. *J Clin Exp Dent*, 2016; 8(2): e226–29
4. Liang W, Xiaofeng Y, Weiguo L et al: Traumatic carotid cavernous fistula accompanying basilar skull fracture: A study on the incidence of traumatic carotid cavernous fistula in the patients with basilar skull fracture and the prognostic analysis about traumatic carotid cavernous fistula. *J Trauma*, 2007; 63(5): 1014–20; discussion 1020
5. Guimarães AC, De Carvalho GM, Chone CT, Pfeilsticker LN: Carotid cavernous fistula: A rare complication of maxillofacial trauma. *Head and Neck Oncology*, 2014; 6(3), Article number 23
6. Helmke K, Krüger O, Laas R: The direct carotid cavernous fistula: A clinical, pathoanatomical, and physical study. *Acta Neurochir (Wien)*, 1994; 127(1–2): 1–5
7. Lewis AI, Tomsick TA, Tew JM Jr.: Management of 100 consecutive direct carotid-cavernous fistulas: Results of treatment with detachable balloons. *Neurosurgery*, 1995; 36(2): 239–44; discussion 244–45
8. de Keizer R: Carotid-cavernous and orbital arteriovenous fistulas: Ocular features, diagnostic and hemodynamic considerations in relation to visual impairment and morbidity. *Orbit*, 2003; 22(2): 121–42
9. Çelik GK, Yildirim E: Epileptic seizures induced by a spontaneous carotid cavernous fistula. *Case Rep Med*, 2016; 2016: 9396014

Our patient was initially treated with empiric antibiotics for suspected peri-orbital cellulitis, as noted clinically and in CT orbits. However, lack of clinical improvement, physical finding of orbital bruit/thrill, normal leukocytes and inflammatory markers, and enlarged superior ophthalmic vein in MR-orbits suggest alternate diagnoses. Vascular malformations and venous thrombosis were unlikely given normal MRA and MRV respectively. Normal ANCA, ANA, RF, TFT, and TSI make vasculitis and thyroid ophthalmopathy unlikely. Eventually, CTA and carotid-arteriography confirmed the diagnosis of right-sided direct CCF, which was subsequently treated with endovascular embolization. It is likely that her direct CCF was related to a head trauma two years ago. The patient had no recurrent symptoms at regular follow-up at one and three months. Not only does this case highlight the importance of CCF, which could be a differential diagnosis of swollen red eye, it also addresses the vital importance of physical examination in modern medicine despite the seemingly promising technologies. We were able to provide the correct diagnosis and treatment for a potentially sight-threatening disease.

Conclusions

CCFs are rare potentially sight-threatening abnormal connections between carotid artery and cavernous sinus. Clinicians should have a low threshold for investigation of CCF in a patient with red swollen eyes in order to provide timely and proper management.

Conflict of Interests

None.

Acknowledgement

We thank Dr. Rajesh Rangaswamy from the department of Radiology and Dr. Mark L Hill from the department of Ophthalmology for their expertise in taking care of the patient.

10. Stiebel-Kalish H, Setton A, Nimii Y et al: Cavernous sinus dural arteriovenous malformations: Patterns of venous drainage are related to clinical signs and symptoms. *Ophthalmology*, 2002; 109(9): 1685–91
11. Pülhorn H, Chandran A, Nahser H, McMahon C: Case report: Traumatic carotid-cavernous fistula. *J Trauma Nurs*, 2016; 23(1): 42–44
12. Gemmete JJ, Chaudhary N, Pandey A, Ansari S: Treatment of carotid cavernous fistulas. *Curr Treat Options Neurol*, 2010; 12(1): 43–53
13. Greenberg MS, Arredondo N: *Handbook of neurosurgery*. Thieme Medical Publishers; 2006
14. Gupta AK, Purkayastha S, Krishnamoorthy T et al: Endovascular treatment of direct carotid cavernous fistulae: a pictorial review. *Neuroradiology*, 2006; 48(11): 831–39
15. Kirsch M, Henkes H, Liebig T et al: Endovascular management of dural carotid-cavernous sinus fistulas in 141 patients. *Neuroradiology*, 2006; 48(7): 486–90