

## Juvenile idiopathic arthritis—recent advances

Karen Rosendahl

© The Author(s) 2011. This article is published with open access at Springerlink.com

Juvenile idiopathic arthritis (JIA) is a heterogeneous condition encompassing all forms of chronic arthritis of unknown origin with onset before 16 years of age. It is characterised by chronic synovial inflammation, with potential risk of developing progressive joint destruction and serious functional disability. The reported incidence varies between 0.6 and 1 in 1,000 children. JIA thus represents an important cause of acquired disability in the paediatric age group. During the last decade, new, potent therapeutic agents have become available to children with JIA, underscoring the need for accurate monitoring of therapeutic response both in disease activity and structural damage to the joint, the latter being considered the gold standard in treatment efficacy studies.

Current classifications, based on clinical criteria, are unsatisfactory since clinical parameters are poor markers for disease activity/progress and joint destruction (Table 1). As for imaging, there has been a shift from traditional radiography towards newer techniques such as ultrasound (US) and magnetic resonance imaging (MRI), but without proper evaluation of their accuracy and validity. Joint damage evaluation in JIA is traditionally performed by radiographic scoring methods, assessing joint space narrowing and erosions, but these are rather insensitive, in part due to the growing skeleton. Wrist disease has been associated with a more severe course of arthritis and a poorer functional outcome, and the wrist is the only joint in which suitable radiographic measures of disease progression have been reported. Much effort has recently been spent on validating

existing scoring systems and devising new ones, of which the adapted version of the Sharp/van der Heijde score has gained the most acceptance (Table 1).

US has been shown to be superior to clinical examination in the diagnosis and localisation of joint effusion, bursal fluid collection and synovitis. A structured assessment of synovitis and tenosynovitis, and classification of the findings have been devised; however, the technique needs validation (Table 1). A few small, uncontrolled studies have described improved sensitivity for detecting bone erosions in joints with the use of ultrasound as compared with conventional plain radiography; however, firm conclusions cannot be drawn from these. US may also demonstrate abnormal changes in cartilage (Fig. 1).

The value of MRI as an advanced method to evaluate disease activity and secondary damage in adults with rheumatoid arthritis is under active investigation by a research consortium called Outcome Measures in Rheumatology Clinical Trials (OMERACT). However, the results drawn from OMERACT studies are not directly applicable to children because adult rheumatoid arthritis is different from JIA and because the growing skeleton of children needs a different approach. Indeed, in children, ossification is incomplete and joint space widths vary with age. Thus, despite technical progress in the imaging of cartilage (e.g., development of ultra-short TE sequences, driven equilibrium Fourier transform [DEFT] imaging, and steady-state free precession [SSFP] sequences for the detection of subtle surface irregularities and tiny focal defects of the articular cartilage, diffusion-weighted techniques to assess degradation of collagen fibres, delayed gadolinium-enhanced MRI of cartilage [dGEMRIC] to detect changes in cartilage proteoglycan content, and T2 relaxation time mapping to detect integrity of collagen in the extracellular matrix), the potential helpfulness of these techniques is yet to be seen. The same goes for sophisticated analysis of three-dimensional

---

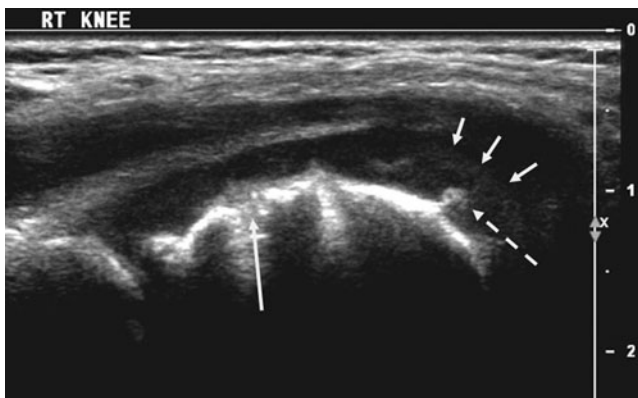
**Disclaimer** Dr. Rosendahl has no financial interests, investigational or off-label uses to disclose.

---

K. Rosendahl (✉)  
Institute of Surgical Sciences/Department of Paediatric Radiology,  
Haukeland University Hospital,  
5021 Bergen, Norway  
e-mail: karen.rosendahl@helse-bergen.no

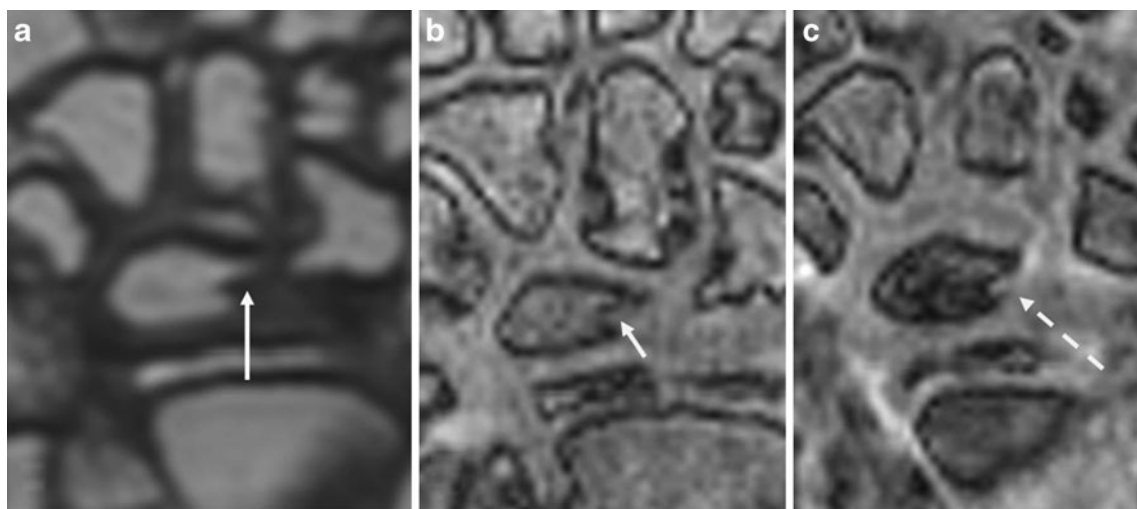
**Table 1** Classification systems for active inflammatory change and chronic structural change in juvenile idiopathic arthritis

| Evaluation                 | Active inflammatory change   |                                      | Chronic, structural change        |  |
|----------------------------|--|--------------------------------------|-----------------------------------|--|
|                            | Detection of abnormality   | Scoring system                       | Detection of abnormality          | Scoring system   |
| Clinical parameters        | Joint swelling (relatively low sensitivity)  | Inaccurate                           | Joint malalignment (late finding) | Inaccurate   |
| Radiography                | Not feasible   |                                      | Feasible                          | Lack of accurate scoring systems. Adapted version of the Sharp/van der Heijde wrist score? |
| Ultrasound                 | Effusions, synovial hypertrophy, tenosynovitis                                     | Needs validation                     | Relatively unfeasible             | Inaccurate   |
| Magnetic resonance imaging | Effusions, bone marrow oedema, synovial hypertrophy with hyperaemia, tenosynovitis | To be published, relatively accurate | Relatively unfeasible             | To be published, relatively inaccurate   |



**Fig. 1** Sagittal ultrasound scan through the distal femoral epiphysis in a 5-year-old boy, showing a focal, echogenic lesion within deep cartilage (*stippled arrow*), as well as bony irregularities/erosion (*long arrow*). The cartilaginous cap of the epiphysis is clearly outlined (*short arrows*)

image data to provide articular surface contour mapping and three-dimensional rendering, as well as volumetric quantification of articular cartilage to evaluate the progression and response to treatment in patients with chronic arthritis. Progress in the assessment of synovitis, including dynamic contrast-enhanced MRI (DCE-MRI) to assess the degree of inflammation is also flawed with methodological difficulties, although voxel-by-voxel analysis of signal intensity versus time curves has proven more accurate than the region-of-interest (ROI) approach in adults with rheumatoid arthritis. Another technique for assessing inflammation using a semiautomated segmentation technique of DCE-MRI has also been described. Thus, although MRI is a potentially powerful imaging tool to assess joint inflammation and the progression of joint damage, standardised, validated and feasible assessment systems are lacking.



**Fig. 2** Coronal T1-weighted volumetric fast spin-echo image of the wrist (a) shows a tubular depression within the lunate (*long arrow*). Based on coronal, fat-saturated pre- (b) and post- (c) contrast images,

a tortuous vessel could be traced (*short and stippled arrows*), entering the lunate via this tubular depression, suggesting a normal vascular channel rather than an erosion

During 2006–2009, we have, as part of a large, European Union-funded multicentre study, devised a new scoring system for wrist and hip involvement in JIA, assessing both active and chronic change, based on MRI and radiography combined. In a large cohort of around 350 patients from 5 to 15 years of age, we have examined the feasibility and accuracy for all the different components within a scoring system, namely, bone erosions, bone marrow oedema, synovitis (effusion, synovial hypertrophy, increased enhancement) and tenosynovitis. In general, the reliability, i.e. inter- and intraobserver agreement, seems to be better for active than for chronic change (Table 1), and thorough standardisation of the scoring method prior to assessment appears to be crucial. One major problem in assessing bone erosions and bone marrow change on MRI in particular is the lack of normal references (Fig. 2). Thus, during the project, such stand-

ards were created based on a population of 89 healthy children aged 5–15 years old. Informed by these findings, we had to adjust some of the definitions used for pathological change.

In conclusion, most of the recent research on JIA has centred on advanced MRI techniques for detecting and assessing injury to cartilage and for assessing synovitis as defined by synovial hypertrophy and hyperaemia, with a much smaller amount of work devoted to assessment systems for clinical use. Thus, the role of MRI (as well as of US) in imaging of JIA is still unclear.

**Open Access** This article is distributed under the terms of the Creative Commons Attribution Noncommercial License, which permits any noncommercial use, distribution, and reproduction in any medium, provided the original author(s) and source are credited.