

IMAGES AND VIDEOS

# Pericardial tumour infiltration of LV cavity in recurrence of previously treated lung adenocarcinoma

Sarosh Khan MBBS MRCP, Maria Ribeiro BSc, Diogo Fernandes BSc and Colin Reid MBBS LRCP MRCS FRCP

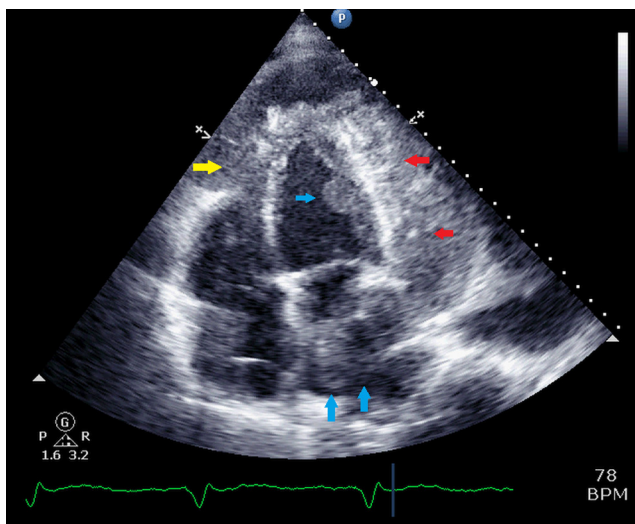
Cardiology, St Richards Hospital, Chichester, UK

Correspondence should be addressed to S Khan: [sarosh.khan@doctors.org.uk](mailto:sarosh.khan@doctors.org.uk)

## Summary

A 72-year-old male with known systolic and diastolic heart failure presented with congestive cardiac failure symptoms over a period of 6 weeks. Successful resection of left upper lobe lung adenocarcinoma 4 years prior. Poor response to optimal medical therapy and IV diuresis. Repeat echocardiogram elicited rare images (Videos 1, 2 and 3) of a significant invasive pericardial tumour involving myocardium and endocardium (Fig. 1). Comparative CT thorax images are also provided (Fig. 2A and B). The importance of cardiac silhouette evaluation on CXR's for

interval change is highlighted with 6-month retrospective review in this case (Fig. 3). A radiographic diagnosis of metastatic adenocarcinoma was made. Given co-morbidities the patient was palliated, after MDT discussion and died soon after in hospice. Primary pericardial tumours are rare. Most common primary sites for metastatic pericardial tumours are lung, breast and the bone marrow (1). Involvement of pericardium and epicardium occurs in up to 70% of patients, usually by direct invasion, with involvement of myocardium in approximately 30%. Extension to endocardium is rare (2). Significant learning from this case with multi-modality imaging evidence of rare pathology.



**Figure 1**  
Transthoracic echocardiogram showing large pericardial mass (red arrow). Mural mass affecting the RV (yellow arrow). Intraluminal mass affecting the LV and LA (blue arrow).

### Video 1

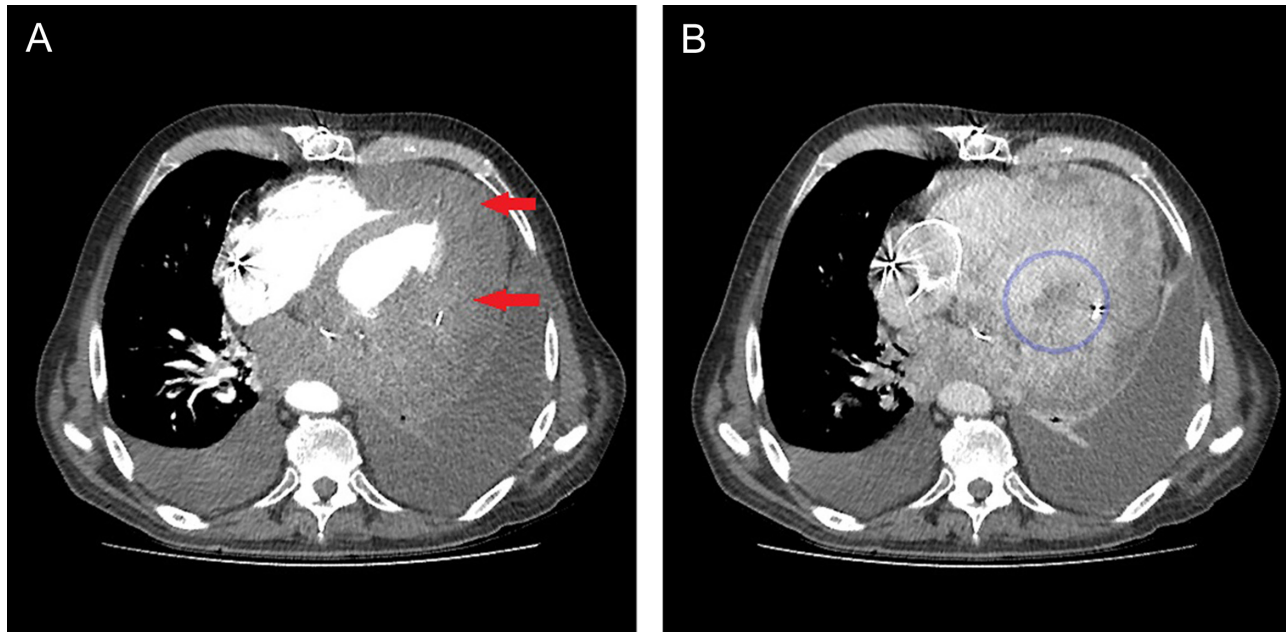
Echocardiographic loop showing a large mass invading the pericardium (A4C view). View Video 1 at <http://movie-usa.glencoesoftware.com/video/10.1530/ERP-17-0074/video-1>.

### Video 2

Echocardiographic loop showing a large mass invading the pericardium (SAX view). View Video 2 at <http://movie-usa.glencoesoftware.com/video/10.1530/ERP-17-0074/video-2>.

### Video 3

Echocardiographic colour Doppler loop showing a non-obstructing mass invading the LA (A4C view). View Video 3 at <http://movie-usa.glencoesoftware.com/video/10.1530/ERP-17-0074/video-3>.



**Figure 2**

(A) CT demonstrating pericardial mass enveloping left ventricle (red arrow) in arterial phase. (B) CT demonstrating pericardial mass invading myocardium seen in portal venous phase (blue circle).

**Declaration of interest**

The authors declare that there is no conflict of interest that could be perceived as prejudicing the impartiality of this article.

**Funding**

This work did not receive any specific grant from any funding agency in the public, commercial, or not-for-profit sector.

**Patient consent**

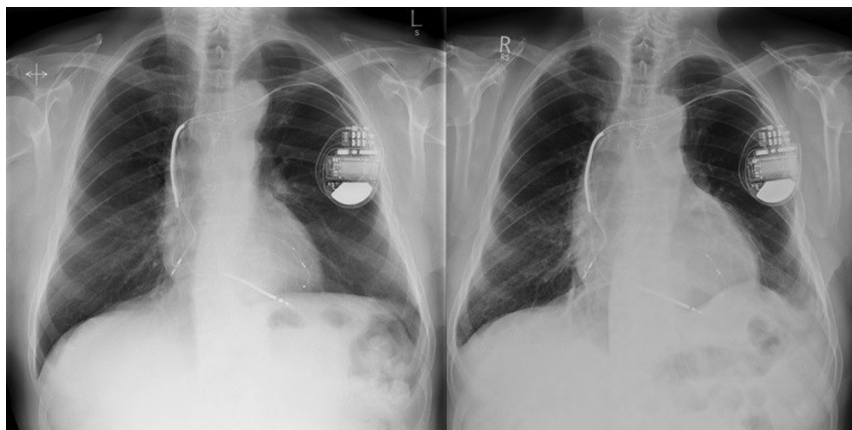
Patient deceased and next-of-kin gave written consent to perform and publish this study case.

**Author contribution statement**

S K and C R – Physicians in charge of patient care. Provided all the clinical information. S K – main author of the study case, research and description. C R – Consultant in charge and reviewed manuscript and case images. D F and M R – Physiologists responsible for collecting and analysing the images. Working alongside S K and C R.

**References**

- 1 Imazio M, Demichelis B, Parrini I, Favro E, Beqaraj F, Cecchi E, Pomari F, Demarie D, Ghisio A, Belli R, *et al.* Relation of acute pericardial disease to malignancy. *American Journal of Cardiology* 2005 **95** 1393–1394. (<https://doi.org/10.1016/j.amjcard.2005.01.094>)



**Figure 3**

CXR's demonstrating distortion of cardiac silhouette with significant enlargement in a 6-month period.

2 Wu P, Chen S, Lin W, Chang C, Chuang W, Hsu M, Liu Y, Chu J,  
Lin P, Wen M, *et al.* Imaging of cardiac and pericardial masses.

*Cardiovascular Imaging Asia* 2017 **1** 23–37. (<https://doi.org/10.22468/cvia.2016.00059>)

---

Received in final form 1 March 2018

Accepted 12 March 2018

Accepted Preprint published online 14 March 2018