

## Clinical comparison of intraoral CMOS and PSP detectors in terms of time efficiency, patient comfort, and subjective image quality

Kıvanç Kamburoğlu<sup>1,\*</sup>, Erçin Samunahmetoğlu<sup>1</sup>, Nejlan Eratam<sup>1</sup>, Gül Sönmez<sup>2</sup>, Sevilay Karahan<sup>3</sup>

<sup>1</sup>Department of Dentomaxillofacial Radiology, Faculty of Dentistry, Ankara University, Ankara, Turkey

<sup>2</sup>Department of Dentomaxillofacial Radiology, Faculty of Dentistry, Adakent University, Mersin, Turkey

<sup>3</sup>Department of Biostatistics, Faculty of Medicine, Hacettepe University, Ankara, Turkey

### ABSTRACT

**Purpose:** This study compared the effectiveness of complementary metal-oxide semiconductors (CMOS) and photostimulable phosphor (PSP) plates as intraoral imaging systems in terms of time efficacy, patient comfort, and subjective image quality assessment in real clinical settings.

**Materials and Methods:** Fifty-eight patients (25 women and 33 men) were included. Patients were referred for a full-mouth radiological examination including 1 bitewing radiograph (left and right) and 8 periapical radiographs for each side (left maxilla/mandible and right maxilla/mandible). For each patient, 1 side of the dental arch was radiographed using a CMOS detector, whereas the other side was radiographed using a PSP detector, ensuring an equal number of left and right arches imaged by each detector. Clinical application time, comfort/pain, and subjective image quality were assessed for each detector. Continuous variables were summarized as mean  $\pm$  standard deviation. Differences between detectors were evaluated using repeated-measures analysis of variance.  $P < 0.05$  was accepted as significant.

**Results:** The mean total time required for all imaging procedures with the CMOS detector was significantly lower than the mean total time required for imaging procedures with PSP ( $P < 0.05$ ). The overall mean patient comfort scores for the CMOS and PSP detectors were 4.57 and 4.48, respectively, without a statistically significant difference ( $P > 0.05$ ). The performance of both observers in subjectively assessing structures was significantly higher when using CMOS images than when using PSP images for all regions ( $P < 0.05$ ).

**Conclusion:** The CMOS detector was found to be superior to the PSP detector in terms of clinical time efficacy and subjective image quality. (*Imaging Sci Dent* 2022; 52: 93-101)

**KEY WORDS:** Radiography, Dental, Digital; Time and Motion Studies; Patient Comfort; Quality Control

### Introduction

Ionizing radiation is frequently used in order to visualize anatomical and pathological structures in conjunction with clinical examinations of patients for routine dental applications.<sup>1,2</sup> For decades, intraoral periapical radiographs were the main dental imaging technique; however, the rapid technological innovations in X-ray systems combined with significant advances in computer systems

enabled the adoption of digital imaging by the dental profession. The first direct digital imaging system, RadioVisioGraphy, was invented by Dr. Frances Mouyen and manufactured by Trophy Radiologie (Vincennes, France) in 1984. Since then, a spate of revolutionary digital receptors for intraoral dental radiography from different brands and companies has reached the dental market.<sup>3</sup> Although periapical radiography involves a relatively low level of exposure to individual patients, its contribution to the population dose is not negligible and the patient dose should be limited to the lowest amount of radiation needed to achieve a diagnostically acceptable image.<sup>4</sup> The doses associated with digital intraoral receptors were reported to be 50% and 80% lower than those associated

Received September 23, 2021; Revised December 13, 2021; Accepted December 29, 2021  
Published online February 11, 2022

\*Correspondence to : Prof. Kıvanç Kamburoğlu

Department of Dentomaxillofacial Radiology, Faculty of Dentistry, Ankara University, Ankara, 06500, Beşevler, Yenimahalle, Ankara, Turkey  
Tel) 90-312-2965632, E-mail) dtkivo@yahoo.com

Copyright © 2022 by Korean Academy of Oral and Maxillofacial Radiology

This is an Open Access article distributed under the terms of the Creative Commons Attribution Non-Commercial License (<http://creativecommons.org/licenses/by-nc/3.0>) which permits unrestricted non-commercial use, distribution, and reproduction in any medium, provided the original work is properly cited.

Imaging Science in Dentistry · pISSN 2233-7822 eISSN 2233-7830

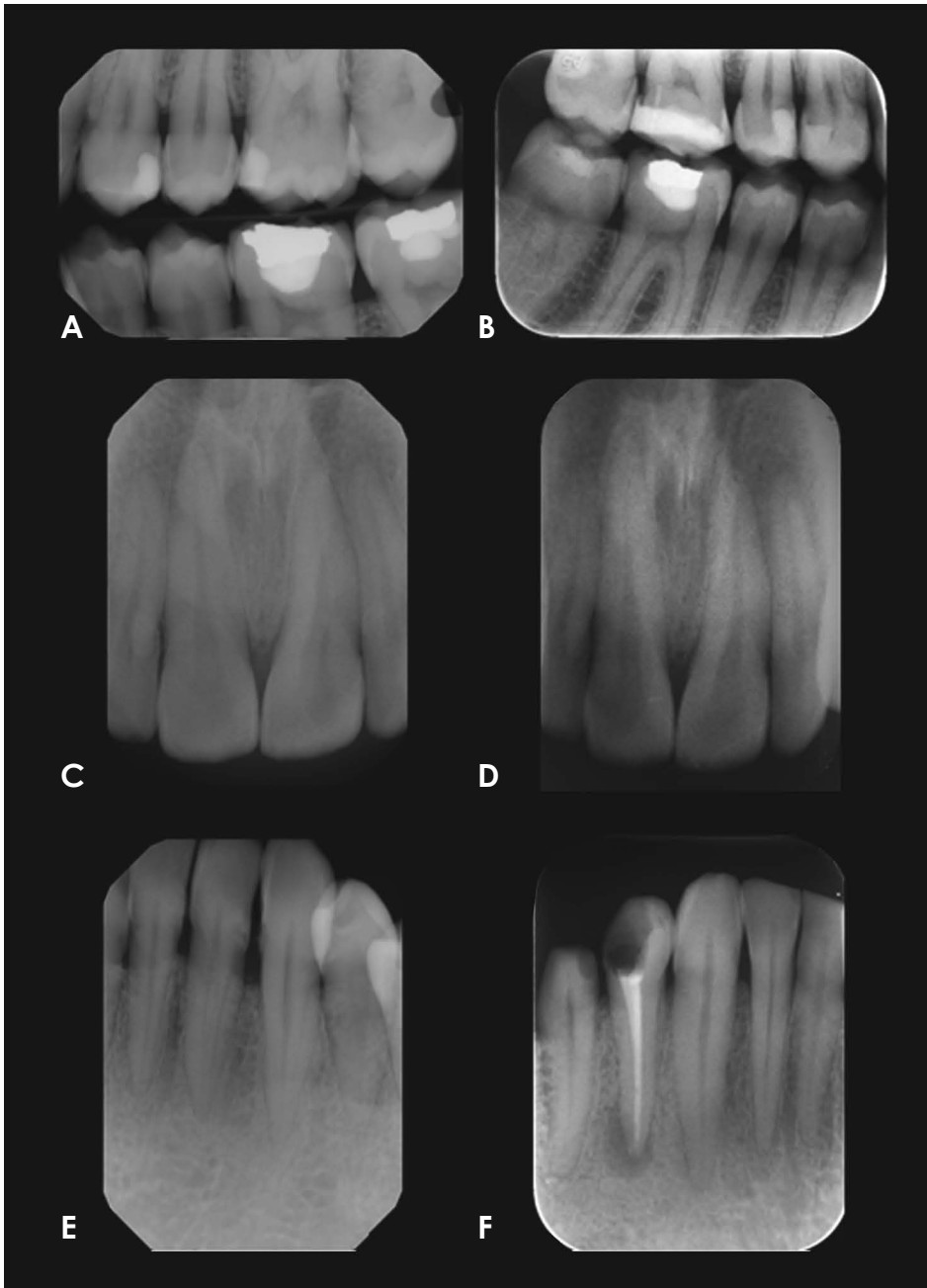
with analog techniques.<sup>5</sup> In addition to dose minimization for both patients and health care providers, digital radiography offers the possibility for computer-aided image interpretation and image enhancement, which result in a more favorable dose-information ratio while eliminating the disadvantages of chemical processing.<sup>6</sup> Recent surveys conducted regarding attitudes towards digital imaging among dentists demonstrated an increased usage of digital radiography in several countries.<sup>7-10</sup> Today, there are 2 modes of digital intraoral imaging: computed radiography (CR), which uses photostimulable phosphor (PSP) plates, and direct digital radiography (DR), which uses solid-state detectors, including charge-coupled devices (CCDs) or complementary metal-oxide semiconductors (CMOS) systems.<sup>11</sup> CR systems use storage phosphor image plates by using a separate image readout process, whereas DR is a way of converting X-rays into electrical charges by means of a direct readout process.<sup>12</sup> PSP detectors have a detection layer of photostimulable crystals that contain europium doped barium fluorohalides.<sup>13</sup> During exposure, X-ray energy is absorbed and temporarily stored by these crystals. When the detection layer is scanned by a high-energy laser beam, the stored energy is then set free as emitted light with a wavelength different from that of the laser beam. Finally, the image is converted into a digital format.<sup>12,13</sup> CCD and CMOS detectors exploit the conversion of X-ray photon energy into light photons as an intermediary stage in the capture of an image.<sup>14</sup> A CMOS typically consist of chips in an integrated circuit and is built of silicon plates that undergo a scintillation process when exposed to X-ray radiation. In this process, light emission causes the breakdown of covalent bonds in silicon, resulting in the release of electrons, which create an electric charge. This charge is transferred to the transistor as a small voltage. The voltage in each transistor can be read separately and consequently appears as a gray value.<sup>15-17</sup> CMOS technology is capable of on-chip integration of analog-to-digital conversion circuitry and produces digital signals without external converters; thus, the radiographic images are available to view in a matter of seconds after the exposure. A disadvantage of CMOS detectors is their thickness, since they are bulky and rigid, which may cause discomfort and application issues.<sup>15</sup> PSP detectors consist of imaging plates that have the same shape and dimensions of conventional films, but the imaging plates in these systems are more rigid than film. Furthermore, some phosphor plates are placed in a plastic envelope with sharp edges to prevent contamination and the operator is unable to bend their corners.<sup>15-18</sup>

The digital receptors may therefore cause problems for the patient and the examiner during radiographic imaging. In clinical settings, patient discomfort and difficulties in tolerating the detector in the mouth may lead to positioning errors, which also influence the diagnostic quality of images and diagnostic accuracy.<sup>15</sup> Several *in vitro* studies have been conducted regarding patient discomfort using bitewing and periapical radiographic examinations of specific locations.<sup>19-22</sup> Earlier *ex vivo* studies compared the image quality<sup>23</sup> and diagnostic quality of images among CCD and PSP systems for the detection of proximal caries, location of the tip of a fine endodontic file, and artificially formed pathologies.<sup>24-26</sup> The authors suggested that both CCD and PSP systems performed similarly in detecting caries;<sup>24</sup> however, CCD systems produced the most reliable images in identifying root canal working length<sup>25</sup> and detecting external root resorption.<sup>26</sup>

Hitherto, most studies conducted to compare different intraoral periapical detectors were designed and conducted *in vitro*. However, in the real clinical environment there are many variables that may influence the clinical applicability, versatility, and diagnostic performance of digital intraoral systems, including patient-related factors. The aim of this clinical study was therefore to compare the effectiveness of CMOS and PSP intraoral detectors in terms of time efficacy, patient comfort, and subjective image quality assessment in real clinical settings.

## Materials and Methods

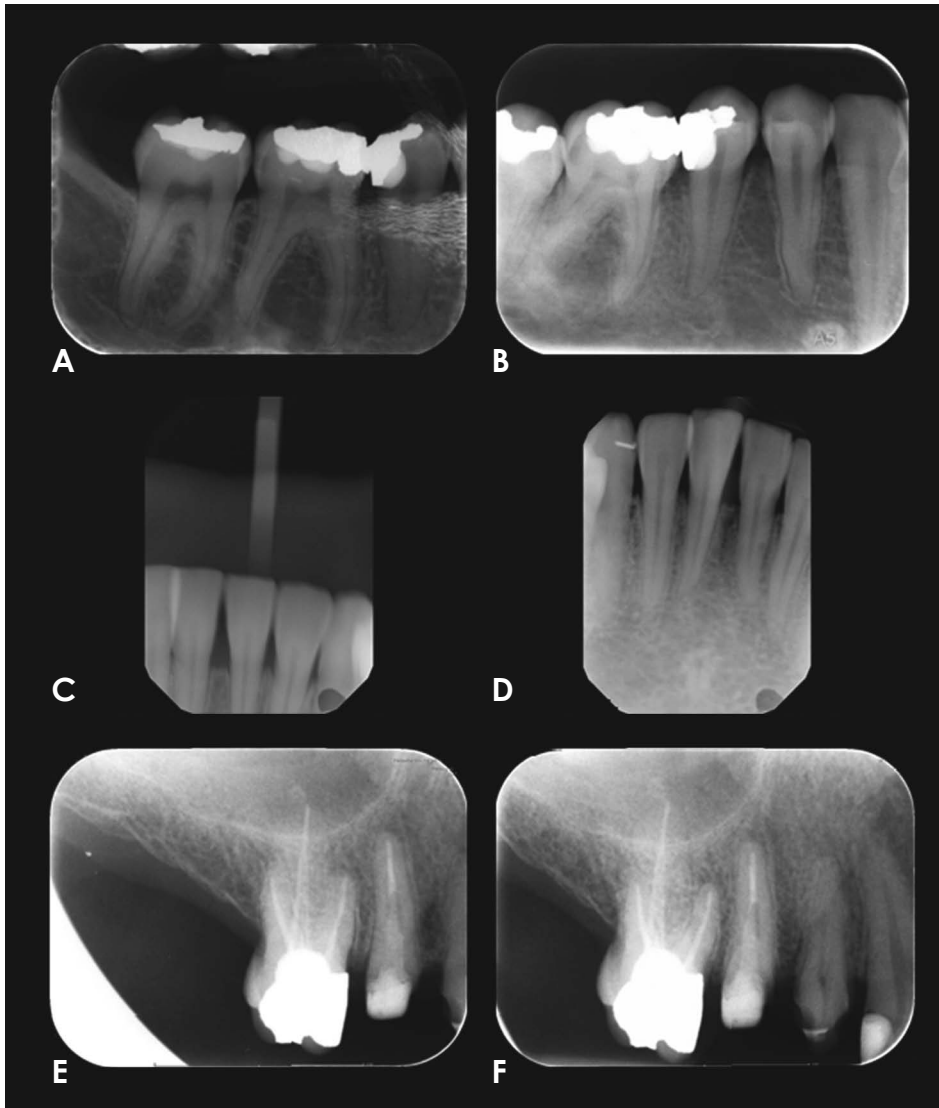Ethical approval was obtained from the Ethics Committee of the Faculty of Dentistry, Ankara University (36290600/02). Potential patients were consecutively recruited from January 2017 to January 2018, and they all provided informed consent for participation. The participants comprised 58 patients (25 women and 33 men) who were admitted to Department of Dentomaxillofacial Radiology with various dental complaints, including periodontitis and active caries and with no more than 4 missing teeth requiring a full-mouth periapical radiographic examination. The mean age of the patients was 40.94 years (standard deviation [SD]: 8.91; age range: 20-74 years). All 58 patients were referred for full-mouth radiological examinations, including 1 bitewing radiograph (left and right) and 8 periapical radiographs for each side (left maxilla/mandible and right maxilla/mandible). One dental X-ray imaging technician with more than 20 years of experience in periapical radiographic imaging performed imaging of 9 different regions (1: maxillary anterior; 2: maxillary canine;



**Fig. 1.** A. A bitewing image obtained with CMOS (the patient's left side). B. A bitewing image obtained with a PSP plate (the patient's right side). C. A periapical image of maxillary incisors obtained with CMOS. D. A periapical image of maxillary incisors obtained with PSP. E. A periapical image of a mandibular canine obtained with CMOS. F. A periapical image of mandibular canine obtained with PSP. Due to the high noise ratio observed in images taken with PSP, trabeculations are observed more clearly in images taken with the CMOS sensor. CMOS: complementary metal-oxide semiconductor, PSP: photostimulable phosphor.

3: maxillary premolars; 4: maxillary molars; 5: mandibular anterior; 6: mandibular canine; 7: mandibular premolar; 8: mandibular molar; 9: bitewing) using the 2 different detector types. A full mouth series, including 16 intra-oral periapical and 2 bitewing images, was obtained from each patient. For each patient, 1 side of the dental arch was radiographed using a CMOS detector, whereas the other side was radiographed using a PSP detector, ensuring an equal number of left and right arches imaged using each detector. The incisors were radiographed twice using the PSP and CMOS detectors, respectively (Fig. 1). Digital intraoral

periapical and bitewing radiographs were exposed using an X-ray machine (Gendex Digital Systems, Hatfield, PA, USA) operated at 65 kVp and 7 mA. Size 2 PSP detectors (GXPS-500 PSP, Gendex Digital Systems, Bensheim, Germany) were utilized. The PSP plates were scanned with Gendex GXPS-500™ Digital X-ray Image Plate Scanner immediately after the exposure, using a standard scanning mode that allowed for a 64 µm (high resolution), 35 µm (super resolution) pixel size, and a 14.3-lp/mm theoretical spatial resolution. A size 2 direct digital intraoral CMOS sensor (Gendex Gxs-700 LP, PA, USA) was utilized for



**Fig. 2.** A. A periapical image of the mandibular premolar-molar area obtained with a damaged (partial stripping and peeled surface) PSP. B. Final periapical image obtained with an undamaged PSP after retake. C. Motion artifact observed in an image obtained with CMOS. D. Mandibular incisor periapical radiography after a retake using CMOS. E. Cone-cut error that occurred due to misalignment of the position-indicating device with the PSP plate. F. Final periapical image obtained by accurate alignment of the position-indicating device with the PSP plate without a cone-cut after retake. CMOS: complementary metal-oxide semiconductor, PSP: photostimulable phosphor.

real-time imaging. The GXS-700 CMOS sensor offers 2.4 million pixels, a pixel size of  $19.5 \mu\text{m} \times 19.5 \mu\text{m}$  and a theoretical resolution of 25.6 lp/mm. *In vivo* imaging was performed using standardized paralleling technique equipment with round collimation (Rinn Manufacturing Company, Elgin, IL, USA) with a focus-receptor distance of 20 cm and an image-exposure time ranging between 0.01 s and 0.08 s, for both detectors depending on tooth-, bone-, and patient-related factors. The periapical and bitewing radiographs were analyzed using SiSoft Medical software (Park Ridge, New Jersey, USA) on a 21.3-inch flat-panel monitor (NEC MultiSync, Munchen, Germany) with  $2,048 \times 2,560$  pixel resolution, in a dimly lit room. Pulpal root canal, dentin, and enamel visibility were used as indicators of optimal image quality, as determined by the consensus of researchers involved in the study.

Clinical application time, comfort/pain analysis, and subjective image quality were assessed for each detector. The clinical application times from the beginning of the procedure to the end of the procedure for each method were measured using a stopwatch. The total time for imaging procedures was determined for all stages (1: detector positioning, 2: tube head and patient positioning, 3: exposure and image acquisition, and 4: total time for all procedures) and recorded by 1 researcher. The patients were also asked to rate their feelings (based on comfort and pain) from extreme discomfort and pain to absence of discomfort (between 1 and 5), gag reflex (score 0: none, 1: very slight, 2: slight) for each detector, and their responses were recorded by the same researcher who also recorded the clinical application times.

The visibility of the periodontal ligament, lamina dura,

bone trabeculation, and anatomical landmarks was used as an indication of subjective image quality for all images. All images were evaluated at random in a dimly lit room. The monitor was adjusted for optimal settings of brightness and contrast, and the settings were not adjusted during viewing. No enhancing functions were used. Images were evaluated separately by 2 dentomaxillofacial radiologists twice at a 2-week interval. The subjective image quality was recorded by using the following 5-point scale. The scoring criteria were as follows: 1: non-diagnostic; 2: poor diagnostic quality; 3: average diagnostic quality, acceptable with minor errors; 4: good diagnostic quality; and 5: very good diagnostic quality. No time restriction was placed on the observers. In addition, retakes due to inadequate image quality that made it impossible to assess the images caused by severe cone-cut (including more than 1 tooth), motion and other artifacts that occurred during image acquisition were also recorded. Only the final accurate image obtained after retakes was included in the statistical analysis (Fig. 2).

Statistical analysis was performed on SPSS for Windows version 23.0 (IBM Corp., Armonk, NY, USA). The normality of continuous variables was determined by the Shapiro-Wilk test. Continuous variables were summarized as mean  $\pm$  SD. Categorical variables were presented as frequencies and percentages. The differences between detectors were evaluated by repeated-measures analysis of variance. Age, sex, and region were controlled in these analyses. The Wilcoxon test was used to compare detectors in terms of patient comfort, nausea reflex, and subjective image quality. The presence of artifacts was compared between sensors using the McNemar test. A *P* value less than 0.05 was accepted as significant. Weighted kappa coefficients were calculated to assess the intra- and inter-observer agreement in subjective image quality assessment for each detector. Kappa values were interpreted according to the following criteria: 0.00-0.20: no agreement, 0.21-0.40: poor agreement, 0.41-0.60: moderate agreement, 0.61-0.80: strong agreement, and 0.81-1.00: excellent agreement.<sup>27</sup>

## Results

A total of 1,044 digital intraoral periapical and bite-wing radiographs were evaluated. Table 1 shows a comparison of the mean ( $\pm$ SD) duration of each procedure and the mean ( $\pm$ SD) of total time required for all procedures using CMOS and PSP in seconds. The overall (all regions taken into consideration) mean time taken to generate 1 series of images including 9 intraoral radio-

**Table 1.** Time for each step and total procedure (unit: seconds)

Procedures	CMOS	PSP
Detector positioning	73.50 $\pm$ 13.14	76.55 $\pm$ 11.66
Tube head and patient positioning	30.06 $\pm$ 4.31	30.46 $\pm$ 3.43
Exposure and image acquisition	63.50 $\pm$ 1.58	127.02 $\pm$ 2.82*
Total procedure	167.07 $\pm$ 13.84	234.05 $\pm$ 11.89*

\*: *P* < 0.05 compared with CMOS, CMOS: complementary metal-oxide semiconductor, PSP: photostimulable phosphor

graphs with CMOS and PSP detectors was 167.07  $\pm$  13.84 s and 234.05  $\pm$  11.89 s, respectively. The mean value of the total time for all imaging procedures with the CMOS detector was significantly lower than the mean value of the total time for imaging procedures with the PSP detector (*P* < 0.05). This difference might be attributable to the statistically significant difference in the overall mean exposure and image acquisition time (*P* < 0.05) between the CMOS (63.50  $\pm$  1.58 s) and PSP (127.02  $\pm$  2.82 s) detectors. However, there were no statistically significant differences between the CMOS and PSP detectors for the overall (all regions taken into consideration) mean detector positioning time (*P* > 0.05) and the overall (all regions taken into consideration) mean tube head and patient positioning time (*P* > 0.05). Nonetheless, statistically significant differences were found in the mean tube head and patient positioning time between the CMOS and PSP detectors for the mandibular premolar (for CMOS: 2.98  $\pm$  0.79 s; for PSP: 3.48  $\pm$  0.73 s, *P* < 0.05) and mandibular molar (for CMOS: 3.04  $\pm$  0.52 s; for PSP: 3.77  $\pm$  2.31 s, *P* < 0.05) regions.

The overall mean patient comfort scores for the CMOS and PSP detectors were 4.57 and 4.48, respectively, without a statistically significant difference (*P* > 0.05). The overall mean nausea reflex scores for CMOS and PSP receptors were 1.27 and 1.25, respectively, without a statistically significant difference (*P* > 0.05).

Considering subjective image quality, intra-rater observer agreement ranged between 0.676 and 0.827 for CMOS and between 0.602 and 0.804 for PSP, suggesting strong and excellent agreement. Inter-rater agreement, calculated by the weighted kappa coefficient, for the average of the scores of the 2 observers with the CMOS and PSP detectors were 0.601 and 0.555, respectively. The intra- and inter-observer agreement kappa coefficient values were found to be higher for the images acquired using the CMOS detector

**Table 2.** Mean scores of 2 observers’ readings to assess anatomical structures and general quality according to the detectors for all regions

Region (overall)		CMOS	PSP
Subjective image quality	Observer 1	3.94 ± 0.51	3.57 ± 0.52*
	Observer 2	4.05 ± 0.42	3.67 ± 0.66*
Periodontal ligament	Observer 1	3.92 ± 0.57	3.35 ± 0.64*
	Observer 2	4.06 ± 0.50	3.52 ± 0.75*
Trabeculation	Observer 1	4.33 ± 0.39	3.80 ± 0.53*
	Observer 2	4.31 ± 0.40	3.85 ± 0.58*
Lamina dura	Observer 1	4.14 ± 0.51	3.63 ± 0.63*
	Observer 2	4.09 ± 0.46	3.53 ± 0.72*
Anatomic landmarks	Observer 1	3.85 ± 0.49	3.57 ± 0.55*
	Observer 2	3.85 ± 0.39	3.49 ± 0.61*
General quality	Observer 1	4.04 ± 0.43	3.58 ± 0.50*
	Observer 2	4.07 ± 0.38	3.61 ± 0.61*

\*:  $P < 0.05$  compared with CMOS, CMOS: complementary metal-oxide semiconductor, PSP: photostimulable phosphor

than for those acquired using the PSP detector.

For both observers, the scores obtained using the CMOS detector were higher than those obtained using the PSP plates in terms of subjective image quality assessment. The mean scores for both observers’ sets of 2 readings to assess the lamina dura, periodontal ligament, trabeculation, anatomical landmarks, and general quality using the CMOS and PSP receptors for all regions are given in Table 2. The performance of both observers in subjectively assessing structures using CMOS images was significantly higher than when using PSP images for all regions ( $P < 0.05$ ).

During the imaging procedures, 1 retake was necessary in 10 patients, 2 retakes in 16 patients, and 3 retakes in 5 patients. Severe cone-cuts and detector and patient motion artifacts were the causes of retakes. The percentage of motion artifacts was 2.4% with the CMOS detector and 1.5% using the PSP detector. The percentage of cone-cuts was 18.3% using the PSP detector and 13.4% using the CMOS detector ( $P < 0.05$ ).

## Discussion

Intraoral imaging, whether using CMOS or PSP detectors, continues to provide the best spatial resolution of any imaging method currently available in routine clinical dental practice. The clinical diagnostic capacity of intraoral radiography is influenced by a number of variables, including central X-ray beam angulation, exposure time,

detector sensitivity, image acquisition, viewing conditions, superimposition of dental and anatomic structures, and lesion location and characteristics. New technological specifications and settings include various real-time solid-state and semi-direct phosphor plate detectors that can better address a variety of specific tasks and imaging that can be conducted with or without cables connected to the detectors. Considering the potential differences between available detectors in terms of clinical effectiveness, the present study compared 2 commonly used CMOS and PSP detectors produced by the same company in terms of clinical time efficacy, patient comfort, and subjective image quality.

Image quality assurance for digital intraoral X-ray imaging is essential for maintaining good diagnostic accuracy. The characteristic features used for the objective evaluation of image quality are pixel value, noise, uniformity, low-contrast resolution, and spatial resolution. The physical performance measurements eliminate variations that may result from the observers or the samples.<sup>28,29</sup> Although this technique provides quantitative results, it is deficient in terms of measures of observer performance.<sup>29</sup> Therefore, in the present study, clinical patient- and observer-related scoring scales were used to obtain more realistic clinical results. The Faculty of General Dental Practice and Public Health England recommended a 2-point grading scale, where images are recorded as either diagnostically acceptable not acceptable in order to help improve personal practice or check if the required diagnostic quality was met.<sup>30</sup> In the present study, by using a 5-point scale, the observers aimed at examining radiographic images in more detail, thus providing a more comprehensive assessment of detector performance in terms of subjective quality. Apart from observer variability, a number of confounding factors in the digital environment add further problems, such as the condition, quality, calibration, and settings of the viewing display; the quality of the graphics card used; and the ambient light level in the room.<sup>28</sup> In the present study, the observers assessed images using the same display monitor. In order to minimize the variances caused by these factors, the observers assessed 2 different detectors made by the same company under the same environmental conditions.

Farrier et al.<sup>31</sup> compared the *in vivo* image quality of CCD and PSP plates by examining a total of 108 digital periapical intraoral images that were obtained from 6 regions. The images were evaluated using a 3-point scale, and the subjective image quality of PSP plates was found to be higher than that of CCD.<sup>31</sup> This result conflicts with

ours, and this discrepancy might be due to the quality of detectors used, the study sample and design, and observer performance variability. Furthermore, Farrier et al.<sup>31</sup> reported a higher number of retakes for CCD than for PSP, which might have been due to the thinner nature of PSP sensors, which enabled easier detector positioning. The authors of that study<sup>31</sup> also reported 35 retakes due to low image quality in 206 periapical radiographs; however, the present study required only 57 retakes in 1,044 periapical radiographs. This might be due to the fact that retakes were only performed in cases of severe cone-cuts (including more than 1 tooth region) and patient and detector motion artifacts. Furthermore, the radiology technician in the present study was highly experienced and had been taking intraoral periapical images since the beginning of the 2000s. The authors of an earlier study reported that higher image quality could be achieved over a much wider exposure range with the PSP storage system than with either films or CCD sensors.<sup>23</sup> In the present study, all intraoral regions were considered when evaluating the subjective image quality and the ability of detectors to demonstrate existing structures; however, the evaluations were not conducted in a specific exposure range.

A recent study compared the image quality between PSP and CMOS systems and evaluated contrast resolution among 4 different exposure times, and reported higher contrast resolution for the PSP system and significantly higher values terms of pixel values for the PSP system than for the CMOS system ( $P < 0.05$ ). However, no subjective image quality assessment was performed by the observers.<sup>32</sup> Aziman et al. compared the subjective image quality of CCD detectors and CMOS detectors using bite-wing radiographs and they found no statistically significant difference between both detectors.<sup>33</sup> In the present study, a CR system using PSP plates and a direct DR system were compared. Aziman et al.<sup>33</sup> compared 2 different DR detectors. Their findings are in contrast with those of the present study, which might be explained by the fact that Aziman et al.<sup>33</sup> only evaluated subjective image quality for bitewing radiography. In the present study, when only bitewing radiographs were taken into account, there was no statistically significant difference in subjective image quality between CMOS and PSP sensor, analogous to the findings of Aziman et al.<sup>33</sup> However, unlike Aziman et al., CMOS was superior when all regions were taken into account in the results presented herein.

In the present study, the image quality scores for the CMOS sensor were in general significantly higher than those of the images produced with the PSP system. More-

over, the kappa coefficient values for intra- and inter-observer agreement were higher for the images acquired using the CMOS system than for those acquired using the PSP system. These findings might be due to the fragility of PSP detectors during clinical use, which may be more pronounced during repeated exposures. Diagnostic tasks are dependent on observer performance and the evaluated structures. Damaged PSP plates have adverse clinical effects on radiographic interpretation. In a study by Thang et al.,<sup>34</sup> an association was found between interpretative results and clinicians' confidence.

Ramamurthy et al.<sup>35</sup> compared 2 PSP detectors in terms of time efficiency for making full-mouth intraoral X-ray surveys (FMSs) *in vitro*. DenOptixw (Kavo/Gendex, Des Plaines, IL, USA) and ScanXw (Air Techniques, Hicksville, NY, USA) systems were compared and 21 FMSs of a DXTRRw Manikin (Dentsply, Des Plaines, IL) were made with each of the systems. The time for each procedural step was measured using a stopwatch, similar to the present study. The steps studied were: 1) plate erasure; 2) packaging; 3) positioning/exposure; 4) unpacking, loading processor, and scanning; and 5) image transfer to a virtual FMS mount. The mean procedure time for DenOptixw was 31.2 minutes, whereas for ScanXw it was 27.1 minutes. Although the mean time for FMS performance was slightly shorter on average with ScanXw than with DenOptixw, the difference did not show statistical significance ( $P > 0.05$ ). The authors of the above-mentioned study compared the FMS image acquisition time using 2 different PSP systems; however, they did not compare different detector types. Due to the different number of images taken in the present study, a comparison of the application time between these studies would be inappropriate. In addition, this study utilized contemporary digital detectors, which facilitated faster image acquisition.

A previous study that evaluated discomfort in connection with bitewing examinations showed that there was no significant difference in the perception of discomfort between conventional films and an ergonomically shaped wired CMOS sensor (Snapshot Instrumentarium Dental, Tuusula, Finland) with rounded corners.<sup>21</sup> In another study,<sup>22</sup> the authors reported that using a receptor holder clearly reduced patient comfort. Without a receptor holder, sensors positioned and held in the mouth with the patients' fingers showed that the phosphor plate was the most comfortable, followed by conventional films and CCD sensors, respectively.<sup>22</sup> A conventional intraoral radiographic film with a holder was found to be the least comfortable. There was a significant difference between

conventional intraoral radiographic films with a holder and conventional intraoral radiographic films positioned and held in the mouth with a finger ( $P < 0.05$ ). Significant differences were also found between the conventional intraoral radiographic films with a holder and other digital sensors held in the mouth with a finger in terms of patient comfort ( $P < 0.05$ ).<sup>22</sup>

In the present study, imaging was performed using standardized paralleling technique equipment with round collimation. The use of rectangular collimation and imaging without equipment could reveal different findings. In the present study, there was a statistically significant difference in the mean tube head positioning time and patient positioning time between the CMOS and PSP receptors for the mandibular premolar and mandibular molar regions. These findings might have been due to difficulties in the preparation and placement of PSP detectors in the mandibular premolar and molar regions.

A study by Kamburoğlu et al.<sup>36</sup> assessed the same teeth under both *in vivo* and *in vitro* conditions for the detection of occlusal caries by using a PSP system. Considering the general difficulties related to obtaining an image in the mandibular third molar region because of the position and alignment of the third molars in the oral cavity, the authors gave useful information in terms of time efficiency and patient comfort. The median time required for image exposure (plate loading, envelope attachment, fixing patient position, and plate exposure) was found to be 1.04 minutes (minimum: 0.50 minutes, maximum: 2.38 minutes), and the median total time required to complete the image acquisition procedure was 1.45 minutes (minimum: 1.21 minutes, maximum: 3.24 minutes). Significant differences were found in both the image exposure time and the total image acquisition time between patients complaining of discomfort and those with no discomfort ( $P < 0.001$ ). The authors assessed 1 PSP image, unlike the present study, which assessed full-mouth series images. The findings of this research are consistent with the study by Kamburoğlu et al.,<sup>36</sup> with similar mean patient comfort scores for CMOS and PSP suggesting similar patient satisfaction for both detectors. Patient discomfort during PSP placement and imaging could be attributable to detector edges, which might irritate the patient's oral mucosae during intraoral detector placement and imaging. Patient discomfort during CMOS placement could occur due to mucosal irritation, as with PSP, and the bulky structure of the CMOS sensor might also trigger the patient's nausea reflex. This phenomenon may explain the higher number of retakes due to motion artifacts with

CMOS detectors and higher number of retakes due to cone-cuts with PSP detectors. Cone-cuts may be caused by various reasons, the most common of which is a lack of alignment between the image receptor with the position indicating device (PID)/radiographic cone. Improper assembly of the receptor holding device and motion of the PID can also cause cone-cuts. In the present study, there were significantly more cone-cuts with PSP detectors than with CMOS detectors. This difference might be due to the sharp edges of the PSP detector causing the patient's head position to change.

Within the limitations of the present clinical study, it can be concluded that the intraoral CMOS and PSP detectors used in this study were similar in terms of patient comfort; however, the CMOS detector was superior to the PSP detector in terms of time effectiveness and subjective image quality in routine dental imaging practice. The present research suggests the active use of solid-state detectors in dental clinics and hospitals where numerous periapical radiographs are routinely taken.

**Conflicts of Interest:** None

## References

1. Hogan R, Goodwin M, Boothman N, Iafolla T, Pretty IA. Further opportunities for digital imaging in dental epidemiology. *J Dent* 2018; 74 Suppl 1: S2-9.
2. Vandenberghe B. The digital patient - imaging science in dentistry. *J Dent* 2018; 74 Suppl 1: S21-6.
3. Mouyen F, Benz C, Sonnabend E, Lodter JP. Presentation and physical evaluation of RadioVisioGraphy. *Oral Surg Oral Med Oral Pathol Oral Radiol Endod* 1989; 68: 238-42.
4. Shetty A, Almeida FT, Ganatra S, Senior A, Pacheco-Pereira C. Evidence on radiation dose reduction using rectangular collimation: a systematic review. *Int Dent J* 2019; 69: 84-97.
5. Lurie AG. Doses, benefits, safety, and risks in oral and maxillofacial diagnostic imaging. *Health Phys* 2019; 116: 163-9.
6. Mol A. Digital imaging. In: Mallya SM, Lam EW. *White and Pharoah's oral radiology: principles and interpretation*. 8th ed. St. Louis: Elsevier; 2018. p. 40-60.
7. Rovaris K, de Faria Vasconcelos K, do Nascimento EH, Oliveira ML, Freitas DQ, Haiter-Neto F. Brazilian young dental practitioners' use and acceptance of digital radiographic examinations. *Imaging Sci Dent* 2016; 46: 239-44.
8. Snel R, Van De Maele E, Politis C, Jacobs R. Digital dental radiology in Belgium: a nationwide survey. *Dentomaxillofac Radiol* 2018; 47: 20180045.
9. Svenson B, Ståhlacke K, Karlsson R, Fält A. Dentists' use of digital radiographic techniques: Part I - intraoral X-ray: a questionnaire study of Swedish dentists. *Acta Odontol Scand* 2018; 76: 111-8.
10. Yeung AW, Tanaka R, Jacobs R, Bornstein MM. Awareness



- and practice of 2D and 3D diagnostic imaging among dentists in Hong Kong. *Br Dent J* 2020; 228: 701-9.
11. Thomas BL, Davies J, Whaites E. Shall I go digital? *Dent Update* 2014; 41: 314-26.
  12. Körner M, Weber CH, Wirth S, Pfeifer KJ, Reiser MF, Treitl M. Advances in digital radiography: physical principles and system overview. *Radiographics* 2007; 27: 675-86.
  13. Jayachandran S. Digital imaging in dentistry: a review. *Contemp Clin Dent* 2017; 8: 193-4.
  14. Cowen AR, Kengyelics SM, Davies AG. Solid-state, flat-panel, digital radiography detectors and their physical imaging characteristics. *Clin Radiol* 2008; 63: 487-98.
  15. Wenzel A, Møystad A. Work flow with digital intraoral radiography: a systematic review. *Acta Odontol Scand* 2010; 68: 106-14.
  16. Sanderink GC, Miles DA. Intraoral detectors. CCD, CMOS, TFT, and other devices. *Dent Clin North Am* 2000; 44: 249-55.
  17. Queiroz PM, Santaella GM, de Castro Lopes SL, Haiter-Neto F, Freitas DQ. Characteristics of radiographic images acquired with CdTe, CCD and CMOS detectors in skull radiography. *Imaging Sci Dent* 2020; 50: 339-46.
  18. Chiu HL, Wei YW, Wang WC, Chen YK. Simple and effective methods to protect the photostimulable phosphor storage plate sensor. *J Dent Sci* 2018; 13: 85-6.
  19. Bahrami G, Hågstrøm C, Wenzel A. Bitewing examination with four digital receptors. *Dentomaxillofac Radiol* 2003; 32: 317-21.
  20. Matzen LH, Christensen J, Wenzel A. Patient discomfort and retakes in periapical examination of mandibular third molars using digital receptors and film. *Oral Surg Oral Med Oral Pathol Oral Radiol Endod* 2009; 107: 566-72.
  21. Jørgensen PM, Wenzel A. Patient discomfort in bitewing examination with film and four digital receptors. *Dentomaxillofac Radiol* 2012; 41: 323-7.
  22. Gonçalves A, Wiezel VG, Gonçalves M, Hebling J, Sannomiya EK. Patient comfort in periapical examination using digital receptors. *Dentomaxillofac Radiol* 2009; 38: 484-8.
  23. Borg E, Gröndahl HG. On the dynamic range of different X-ray photon detectors in intra-oral radiography. A comparison of image quality in film, charge-coupled device and storage phosphor systems. *Dentomaxillofac Radiol* 1996; 25: 82-8.
  24. Şenel B, Kamburoğlu K, Üçok Ö, Yüksel SP, Özen T, Avsever H. Diagnostic accuracy of different imaging modalities in detection of proximal caries. *Dentomaxillofac Radiol* 2010; 39: 501-11.
  25. Anas A, Asaad J, Tarboush K. A comparison of intra-oral digital imaging modalities: charged couple device versus storage phosphor plate. *Int J Health Sci (Qassim)* 2010; 4: 156-67.
  26. Kamburoğlu K, Tsesis I, Kfir A, Kaffe I. Diagnosis of artificially induced external root resorption using conventional intraoral film radiography, CCD, and PSP: an ex vivo study. *Oral Surg Oral Med Oral Pathol Oral Radiol Endod* 2008; 106: 885-91.
  27. Landis JR, Koch GG. The measurement of observer agreement for categorical data. *Biometrics* 1977; 33: 159-74.
  28. Hellén-Halme K, Johansson C, Nilsson M. Comparison of the performance of intraoral X-ray sensors using objective image quality assessment. *Oral Surg Oral Med Oral Pathol Oral Radiol* 2016; 121: e129-37.
  29. Okamura K, Yoshiura K. The missing link in image quality assessment in digital dental radiography. *Oral Radiol* 2020; 36: 313-9.
  30. Bird R, Donnell C. Making the grade. *Br Dent J* 2021; 230: 117.
  31. Farrier SL, Drage NA, Newcombe RG, Hayes SJ, Dummer PM. A comparative study of image quality and radiation exposure for dental radiographs produced using a charge-coupled device and a phosphor plate system. *Int Endod J* 2009; 42: 900-7.
  32. Aydın KC, Demirel O, Özcan M. Comparison of two digital intraoral radiography imaging systems as a function of contrast resolution and exposure time. *Minerva Stomatol* 2020; 69: 148-52.
  33. Aziman C, Hellén-Halme K, Shi XQ. A comparative study on image quality of two digital intraoral sensors. *Dentomaxillofac Radiol* 2019; 48: 20190063.
  34. Thang TS, Kishen A, Moayedi M, Tyrrell PN, Zhao W, Perschbacher SE. The effects of physical photostimulable phosphor plate artifacts on the radiologic interpretation of periapical inflammatory disease. *Oral Surg Oral Med Oral Pathol Oral Radiol* 2020; 129: 621-8.
  35. Ramamurthy R, Canning CF, Scheetz JP, Farman AG. Time and motion study: a comparison of two photostimulable phosphor imaging systems used in dentistry. *Dentomaxillofac Radiol* 2006; 35: 315-8.
  36. Kamburoğlu K, Şenel B, Yüksel SP, Özen T. A comparison of the diagnostic accuracy of in vivo and in vitro photostimulable phosphor digital images in the detection of occlusal caries lesions. *Dentomaxillofac Radiol* 2010; 39: 17-22.