

## Case Report

# Guidewire-Related Complications during Central Venous Catheter Placement: A Case Report and Review of the Literature

**Faisal A. Khasawneh<sup>1</sup> and Roger D. Smalligan<sup>2</sup>**

<sup>1</sup> *Division of Critical Care Medicine, Department of Internal Medicine, Texas Tech University Health Sciences Center, 1400 S. Coulter, Amarillo, TX 79106, USA*

<sup>2</sup> *Department of Internal Medicine, Texas Tech University Health Sciences Center, 1400 S. Coulter, Amarillo, TX 79106, USA*

Correspondence should be addressed to Faisal A. Khasawneh, [faisal.khasawneh@ttuhsc.edu](mailto:faisal.khasawneh@ttuhsc.edu)

Received 2 August 2011; Accepted 22 September 2011

Academic Editors: C. Diez, K. Lenz, and J. Starkopf

Copyright © 2011 F. A. Khasawneh and R. D. Smalligan. This is an open access article distributed under the Creative Commons Attribution License, which permits unrestricted use, distribution, and reproduction in any medium, provided the original work is properly cited.

Seldinger's technique is widely used to place central venous and arterial catheters and is generally considered safe. The technique does have multiple potential risks. Guidewire-related complications are rare but potentially serious. We describe a case of a lost guidewire during central venous catheter insertion followed by a review of the literature of this topic. Measures which can be taken to prevent such complications are explained in detail as well as recommended steps to remedy errors should they occur.

## 1. Introduction

In 1953 Seldinger described a simple, over a guidewire, approach for catheter insertion [1]. It offered considerable advantages over the previously used methods, revolutionizing the field of bedside procedures. The Seldinger technique is widely used in the intensive care unit (ICU) to place central venous catheters (CVCs), hemodialysis (HD) catheters, arterial catheters, and chest tubes. Like any other procedure, it has a number of associated potential risks. Guidewire-related complications in particular are rarely reported; nevertheless, when they do occur, they can be accompanied by significant morbidity and mortality. In this paper, a case of a lost guidewire during central venous catheter (CVC) insertion is reported followed by a review of the literature.

## 2. Case Presentation

A 45-year-old male patient with diabetes mellitus and left-sided nonsmall cell lung cancer was admitted to the ICU with progressive shortness of breath. The patient's acute hypoxemic respiratory failure was attributed to disease progression and possible pneumonia. Failing noninvasive positive pressure ventilation, the patient required intubation and the initiation of mechanical ventilation. A chest X-ray

(Figure 1) was taken shortly afterwards. On the radiograph, he had a well-positioned endotracheal tube, an orogastric tube, a left-sided subclavian CVC, a left-sided chest tube, and multiple superficial leads. There was an additional shadow that could not be easily accounted for. Examining the patient and the bedding offered no explanation for the extra shadow. Sequentially ordered X-rays of the abdomen, pelvis, and right thigh (Figures 2, 3, and 4) revealed a J-shaped guidewire that apparently had been lost but not reported during the left subclavian CVC insertion procedure. With the help of an interventional radiologist, the guidewire was removed successfully without complications.

## 3. Discussion

Although this case ended without significant harm being caused to the patient, guidewire-related complications with accompanying morbidity and mortality do occur during the insertion of central venous catheters. The high frequency of such CVC placement procedures in emergency rooms, operating rooms, and intensive care units makes the likelihood of seeing an occasional complication quite high. To study this topic in depth, the authors searched PubMed for articles using the search terms "guidewire," "J-wire," "central venous

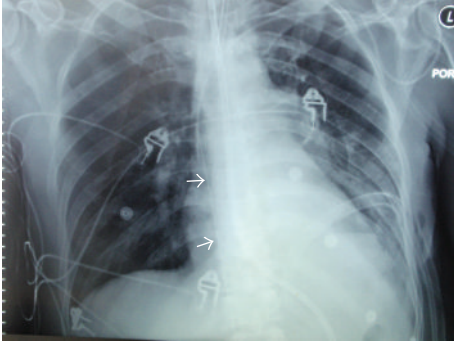


FIGURE 1: Chest X-ray showing an endotracheal tube, an orogastric tube, a left-sided subclavian central venous catheter, a left-sided chest tube, and multiple superficial leads. There is additional shadow (arrow heads) that could not be accounted for.

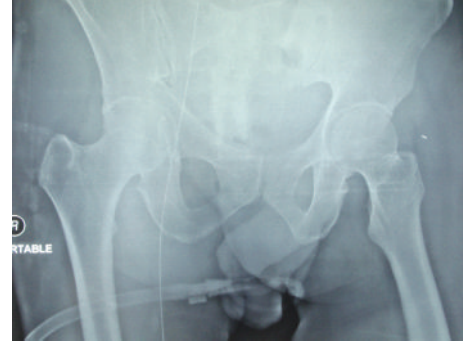

FIGURE 3: Pelvic X-ray showing the guidewire extending into the femoral vein in the right thigh.

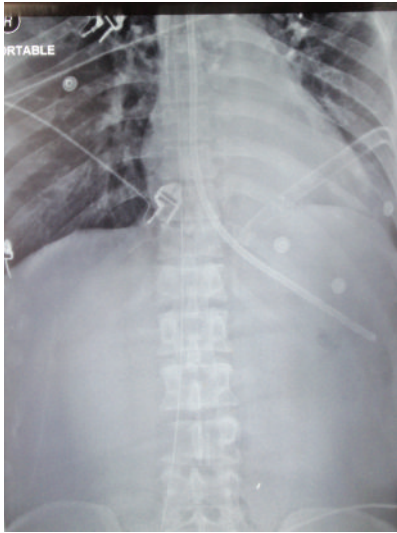


FIGURE 2: Upper abdominal X-ray showing the lost guidewire extending down the inferior vena cava on the right side of the abdomen.

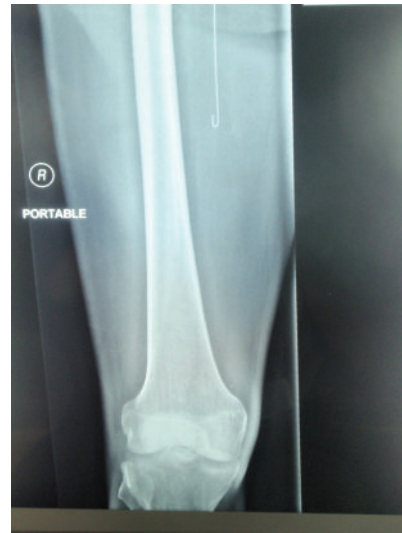

FIGURE 4: Right thigh X-ray showing the J-tip of the lost guidewire medial to the femur.

catheter,” and “complications” in various combinations. Studies and case reports written in English as well as their listed references were reviewed for pertinent data.

The most commonly reported guidewire-related complications are listed in Table 1 and will be discussed below.

Cardiac dysrhythmias, most often premature atrial or ventricular contractions, are occasionally reported during subclavian or internal jugular (IJ) CVC insertion [2]. The arrhythmias are typically short lived, resulting from the guidewire touching the endocardium, and resolve when the tip is pulled back a few centimeters [2].

The most common cardiac conduction abnormalities seen during CVC placement are right bundle branch blocks, new left anterior and posterior fascicular blocks, and rarely asystole [3]. The cause of these conduction problems, as described in the case of cardiac dysrhythmias, is also the overzealous advancement of the guidewire. The ease with which a right bundle branch block can be induced is

probably related to the bundle branch’s superficial position in the right ventricular endocardium, just inferior to the tricuspid valve [3]. Conduction abnormalities are usually transient and may go unnoticed. However, in a patient with an underlying left bundle branch block, the induction of further conduction defects may lead to a life-threatening complete heart block requiring temporary pacing [3]. The mentioned arrhythmias and conduction problems are essentially avoidable during central venous catheterization since placement should not involve entry into the heart by the guidewire or by the subsequently placed catheter [3].

Perforation of central veins or right-sided cardiac chambers can be catastrophic. In clinical practice, it is often difficult to ascertain what caused the venous perforation; the introducer needle, the guidewire, or the dilator. Nevertheless, the literature reports cases of guidewire-related perforation of the great vessels including the brachiocephalic and subclavian veins [4]. This important complication occurs when excessive force is applied against resistance when introducing the guidewire, especially if the straight or angle

TABLE 1: The most commonly reported guidewire-related complications.

(i) Cardiac dysrhythmias
(ii) Cardiac conduction abnormalities
(iii) Perforation of vessels or cardiac chambers
(iv) Kinking, looping, or knotting of the wire
(v) Entanglement of previously placed intravascular devices
(vi) Breakage of the distal tip of the guidewire with subsequent embolization
(vii) Complete loss of the guidewire within the vascular system

tip wire, rather than J tip style wire, is used. In most instances, bleeding from a small penetrating hole in a vein will stop spontaneously by vasospasm or by external compression of the surrounding tissues [4]. However, serious cases of hemothorax, including fatalities, due to the above complication have been reported [4]. Making a timely diagnosis in such cases requires maintaining a high index of suspicion when there is an unexplained drop in hemoglobin or the development of unilateral pleural effusion ipsilateral to a recently placed or attempted central venous catheterization. Treatment of a serious perforation may necessitate the insertion of a chest tube or an emergent thoracotomy [4].

Perforation of the heart may occur at the time of catheter insertion or any time the catheter tip is placed within the heart chambers [4]. There are at least two reported cases in the literature of heart perforation attributed to the guidewire itself. Both of these complications occurred during the insertion of HD catheters: the first during a subclavian approach leading to a life-threatening cardiac tamponade and the second during an IJ approach leading to a fatal tamponade [5, 6]. Cardiac tamponade usually results from perforation of the right atrium, or less frequently, the right ventricle. Tamponade has also been reported after superior vena cava (SVC) perforation within the pericardium [6]. The possibility of tamponade should be considered when a patient collapses during, or shortly after, placement of a CVC. Other diagnoses to consider in that scenario include tension pneumothorax and air embolism. An emergent chest X-ray or bedside echocardiogram followed by pericardiocentesis can be life saving in such situations.

Another occasional guidewire complication is kinking or looping of the wire itself. Applying force to thread a guidewire through the introducer needle despite significant resistance is likely to cause such a problem [7]. Kinking can also result if the dilator is forced in a direction that diverges from the original path of the wire [7]. If a clinician does not recognize this scenario there is potential for cutting through the vein with possible fatal complications [8]. This type of complication can be avoided by intermittently moving the wire gently in and out as the dilator is being advanced through the subcutaneous tissue. Application of increasing force after looping or kinking sometimes results in knot formation. Both intravascular as well as extravascular knotting have been reported [7]. It is almost exclusively described following the subclavian approach which may be

due to the curved path the vein takes as it loops over the first rib to descend into the SVC [7]. This complication should be suspected when the guidewire cannot be pulled out after successful catheter insertion. In this situation, no force should be used to pull the catheter and wire out, and an immediate X-ray should be ordered. Once the diagnosis is established, interventional radiology should be consulted, and sometimes surgical intervention is necessary.

Entanglement of a guidewire with an existing intravascular apparatus is another reported complication of CVC placement. Special attention is needed in patients with inferior vena cava (IVC) filters since there have been numerous reports of entrapment of guidewires in these filters [9]. It results from over advancement of the guidewire leading to hooking of the J-tip to the filter. Interestingly, IVC filter entrapment with straight guidewires has not been reported [9]. This complication should be suspected when the guidewire cannot be retrieved after catheter placement in a patient with an IVC filter already deployed. In such circumstances, no excessive force should be used to free the wire since this could lead to filter dislodgment and cava perforation [10]. X-ray or examination under fluoroscopy should be ordered promptly followed by interventional radiology consultation once the diagnosis is made.

Tip breakage of a guidewire has been blamed on inherent design flaws [11]. Shearing and breakage of the wire usually results from pulling the wire back through the needle after it has passed the bevel [7]. Hence, if a guidewire fails to pass freely from the introducer needle into the vessel, the careful retraction of the wire through the needle is an option, but it is much safer to withdraw the wire and needle as a single unit.

The inadvertent intravascular insertion of the entire guidewire, as in our case, is a completely avoidable complication [12]. Although the loss of a complete guidewire might cause arrhythmias, vascular damage, and thrombosis, it is usually asymptomatic and is often incidentally found on a routine X-ray done up to several months after the procedure [13]. Holding on to the proximal tip of the wire at all times is fundamental in preventing this mistake. If this complication happens, use of interventional radiology techniques is the preferred method for retrieval and removal [12].

The introduction of an excessive length of guidewire during central venous catheterization explains most of the aforementioned complications. Many reasons stand behind this faulty practice including not knowing its dangerous implications, fear of losing vascular access, absence of marks on the guidewire, use of a circular advancer, and concerns over contamination of the proximal end of the wire. Keeping these possibilities in mind and the fact that the upper limit of safe guidewire insertion in an adult patient is about 18 centimeters might help avoid this risky practice [14].

#### 4. Conclusion

During central venous catheterization, guidewire-related complications are uncommon and essentially preventable. Preventive measures include the following.

- (i) Careful selection of catheterization site paying attention to previous attempts and anatomical abnormalities.
- (ii) Being aware of the presence of endovascular devices.
- (iii) Considering the wire to be a delicate instrument with inherent areas of structural weakness [11]. Thus, on encountering any resistance while advancing or retrieving the wire, force should not be used.
- (iv) The wire should not be advanced in the vein more than 18 to 20 centimeters in an adult patient [14].
- (v) Using a J-tip style guidewire is a much safer practice.
- (vi) The integrity of the guidewire needs to be checked after each attempt of threading the introducer needle and at the end of the procedure.
- (vii) The proximal end of the wire should always be held by the operator until the distal tip is completely out of the vessel.

### Consent

Written informed consent was obtained from the patient for publication of this case report and accompanying images. A copy of the written consent is available for review by the editor-in-chief of this journal.

### Conflict of Interests

The authors declare that they have no conflict of interests related to this manuscript.

### Authors' Contributions

F. A. Khasawneh was the attending physician on the case. F. A. Khasawneh made the diagnosis and took the pictures. F. A. Khasawneh and R. D. Smalligan reviewed the literature and wrote the manuscript.

### References

- [1] S. I. Seldinger, "Catheter replacement of the needle in percutaneous arteriography; a new technique," *Acta Radiologica*, vol. 39, no. 5, pp. 368–376, 1953.
- [2] R. K. Stuart, S. A. Shiroka, P. Akerman et al., "Incidence of arrhythmia with central venous catheter insertion and exchange," *Journal of Parenteral and Enteral Nutrition*, vol. 14, no. 2, pp. 152–155, 1990.
- [3] N. T. Eissa and V. Kvetan, "Guide wire as a cause of complete heart block in patients with preexisting left bundle branch block," *Anesthesiology*, vol. 73, no. 4, pp. 772–774, 1990.
- [4] Y. Innami, T. Oyaizu, T. Ouchi, N. Umemura, and T. Koitabashi, "Life-threatening hemothorax resulting from right brachiocephalic vein perforation during right internal jugular vein catheterization," *Journal of Anesthesia*, vol. 23, no. 1, pp. 135–138, 2009.
- [5] F. Cavatorta, S. Campisi, and F. Fiorini, "Fatal pericardial tamponade by a guide wire during jugular catheter insertion," *Nephron*, vol. 79, no. 3, p. 352, 1998.
- [6] P. G. Blake and R. Uldall, "Cardiac perforation by a guide wire during subclavian catheter insertion," *International Journal of Artificial Organs*, vol. 12, no. 2, pp. 111–113, 1989.
- [7] K. Z. Khan, D. Graham, A. Ermenyi, and W. R. Pillay, "Case report: managing a knotted Seldinger wire in the subclavian vein during central venous cannulation," *Canadian Journal of Anesthesia*, vol. 54, no. 5, pp. 375–379, 2007.
- [8] Z. Jankovic, A. Boon, and R. Prasad, "Fatal haemothorax following large-bore percutaneous cannulation before liver transplantation," *British Journal of Anaesthesia*, vol. 95, no. 4, pp. 472–476, 2005.
- [9] F. Y. Vinces, T. V. Robb, K. Alapati et al., "J-tip spring guidewire entrapment by an inferior vena cava filter," *Journal of the American Osteopathic Association*, vol. 104, no. 2, pp. 87–89, 2004.
- [10] S. Nanda and L. Strockoz-Scaff, "Images in clinical medicine. A complication of central venous catheterization," *The New England Journal of Medicine*, vol. 356, no. 21, article e22, 2007.
- [11] E. Monaca, S. Trojan, J. Lynch, M. Doehn, and F. Wappler, "Broken guide wire—a fault of design?" *Canadian Journal of Anesthesia*, vol. 52, no. 8, pp. 801–804, 2005.
- [12] W. Schummer, C. Schummer, E. Gaser, and R. Bartunek, "Loss of the guide wire: mishap or blunder?" *British Journal of Anaesthesia*, vol. 88, no. 1, pp. 144–146, 2002.
- [13] M. Auweiler, S. Kampe, M. Zähringer et al., "The human error: delayed diagnosis of intravascular loss of guidewires for central venous catheterization," *Journal of Clinical Anesthesia*, vol. 17, no. 7, pp. 562–564, 2005.
- [14] R. T. Andrews, D. A. Bova, and A. C. Venbrux, "How much guidewire is too much? Direct measurement of the distance from subclavian and internal jugular vein access sites to the superior vena cava-atrial junction during central venous catheter placement," *Critical Care Medicine*, vol. 28, no. 1, pp. 138–142, 2000.