

Received: 2016.04.23
Accepted: 2016.05.27
Published: 2017.02.08

Magnetic Resonance Imaging (MRI) Evaluation for Anterior Disc Displacement of the Temporomandibular Joint

Authors' Contribution:
Study Design A
Data Collection B
Statistical Analysis C
Data Interpretation D
Manuscript Preparation E
Literature Search F
Funds Collection G

BCDEF 1 **Zhongjun Yang**
BCF 2 **Mingguo Wang**
BCF 2 **Yingwei Ma**
BCF 1 **Qingguo Lai**
CE 3 **Dongdong Tong**
CE 3 **Fenghe Zhang**
ADEG 2 **Lili Dong**

1 Department of Stomatology, The Second Hospital of Shandong University, Jinan, Shandong, P.R. China
2 Department of Stomatology, Jinan Central Hospital Affiliated to Shandong University, Jinan, Shandong, P.R. China
3 Department of Oral and Maxillofacial Surgery, School of Stomatology, Shandong University, Jinan, Shandong, P.R. China

Corresponding Author: Lili Dong, e-mail: dongllsu@163.com

Source of support: This work was supported by Science and Technology Development Plan Project of Shandong Province (2014GGH218038, 2014GSF118145)

Background: Magnetic resonance imaging (MRI) is the criterion standard imaging technique for visualization of the temporomandibular joint (TMJ) region, and is currently considered the optimum modality for comprehensive evaluation in patients with temporomandibular joint disorder (TMD). This study was aimed at finding the value of MRI in pre-clinical diagnosis of TMJ disc displacement.





Material/Methods: Patients primarily diagnosed as having anterior disc displacement by clinical symptoms and X-ray were selected in the present study. MRI was used to evaluate surrounding anatomical structures and position, as well as morphological and signal intensity change between patients and normal controls.

Results: Posterior band position was significantly different between the patient group and control group. At the maximum opened-mouth position, the location of disc intermediate zone returned to normal. At closed-mouth position, the thickness of anterior and middle, but not posterior, band increased. The motion range of the condyle in the anterior disc displacement without reduction (ADDWR) patient group was significantly less than the value in the anterior disc displacement with reduction (ADDR) patient group and the control group. Whether at closed-mouth position or maximum opened-mouth position, the exudate volume in the patient group was greater than in the normal group.

Conclusions: MRI can be successfully used to evaluate multiple morphological changes at different mouth positions of normal volunteers and patients. The disc-condyle relationship can serve as an important indicator in assessing anterior disc displacement, and can be used to distinguish disc displacement with or without reduction.

MeSH Keywords: **Magnetic Resonance Imaging • Mandibular Condyle • Temporomandibular Joint Disc • Temporomandibular Joint Disorders**

Full-text PDF: <http://www.medscimonit.com/abstract/index/idArt/899230>

 2603  5  3  20



Background

Temporomandibular joint disorder (TMD) is a general term for diseases of the temporomandibular joint (TMJ), which affects one-third of adults [1]. The symptoms of TMD generally include pain in the TMJ and masticatory muscles, joint sounds and locking, alteration of mandibular movement, and disc displacement [2]. Anterior disc displacement occurs more frequently than posterior, medial, or lateral dislocation [3]. During mouth-opening, anterior disc displacement can be reduced (anterior disc displacement with reduction, ADDR) or remain displaced (anterior disc displacement without reduction, ADDWR). Anterior disc displacement is a derangement diseases and its diagnostic standard is not clear.

Magnetic resonance imaging (MRI), arthrography, computed tomography (CT), and cone beam computed tomography (CBCT) have been used as advanced imaging modalities for evaluation of TMD. With the rapid development of medical imaging techniques, MRI has become the criterion standard examination of the temporomandibular joint (TMJ) region [4]. Because the signal intensity of bone, cartilage, articular disc, masticatory muscles, and synovial fluid differ, the structure of the TMJ can be clearly displayed. The ability to distinguish characteristics of different soft tissue makes MRI superior to other imaging methods [5]. Without ionizing radiation and invasion, MRI is considered suitable for analyzing the TMJ disc and surrounding anatomical structures in normal and diseased state [6].

TMD comprises collective clinical problems encompassing pain and dysfunction of the masticatory system, TMJ, and associated structures [7]. Mechanical overloading is considered to be a major etiological factor for development of TMD [8]. Excessive and concentrative compressive stress most likely contributes to condylar resorption and disc displacement [9]. Precise TMD diagnosis and treatment necessitates the assessment of structural characteristics by imaging. With the rapid progress made in TMJ imaging techniques, MRI is currently considered the optimum modality in patients with TMD [10]. However, few studies have performed systematic and detailed analysis and comparison of TMJ structure at different states based on MRI.

Patients primarily diagnosed with anterior disc displacement by clinical symptoms and X-ray were selected in the present study. MRI was used to evaluate surrounding anatomical structure and position, as well as morphological and signal intensity change, between patients and normal controls. The study was aimed at finding the value of MRI in pre-clinical diagnosis of TMJ disc displacement.

Material and Methods

Patients selection

The control group consisted of 30 disease-free joints of 15 youth volunteers, and 18 joints of 15 cases served as the patient group. Subjects were selected according to research diagnostic criteria for temporomandibular disorders (RDC/TMD) criteria, which constitute a well-established diagnostic system that has been shown to be reliable for the diagnosis and assessment of TMD. The RDC/TMD procedure includes assessment of the presence or absence of pain and joint sounds, intraoral and extraoral palpation of the masticatory muscles, and measurement of mandibular movement (Axis I). It also requires the collection of information on the patient's general health, pain characteristics, and psychosocial dysfunction (Axis II). In the patient group, all 15 cases were selected with TMD symptoms, such as pain in the TMJ area, restricted mandibular movement, open-locking, difficulty mouth closing, clicking, jaw popping, or clicking, as determined by an experienced clinician. The study was approved by the Ethics Committee of Ji'nan Central Hospital affiliated to Shandong University. For X-ray, standardized lateral transcranial projections with mouth closed and maximal mouth opened were performed in all subjects. X-ray indicated space change and posterior displacement of condylar position, which suggested anterior disc displacement.

Evaluation tools

MRI was performed and analyzed with GE Healthcare's Signa EXCITE high-definition magnetic resonance system, which produces images with high spatial resolution and high signal-to-noise ratio in the tissues. We used a head coil instead of the conventional surface coils. Head coils can scan bilateral temporomandibular joints at the same time to reduce errors. To maintain a comfortable position in the mouth-opening process and reduce artifacts resulting from unconscious movement, a wooden mouth-opener was designed and used.

MR scanning and image analysis

The subjects were asked to remove metal objects on the body, and taught to use the wooden mouth-opener. With head coil on, the subjects lay down on the GE Signa Excite 3.0 T magnetic resonance machine and were sent into the magnetic field. The layer at which condyle and articular disc were most clearly displayed was selected. The middle location of the condyle was set as an intermediate layer, and we adjusted the appropriate echo time, repetition time, scanning range, layer thickness, and spacing. We saved the settings to open the scan, which can complete a TMJ imaging at closed-mouth position. With the head unmoved, the subjects slowly opened the lower

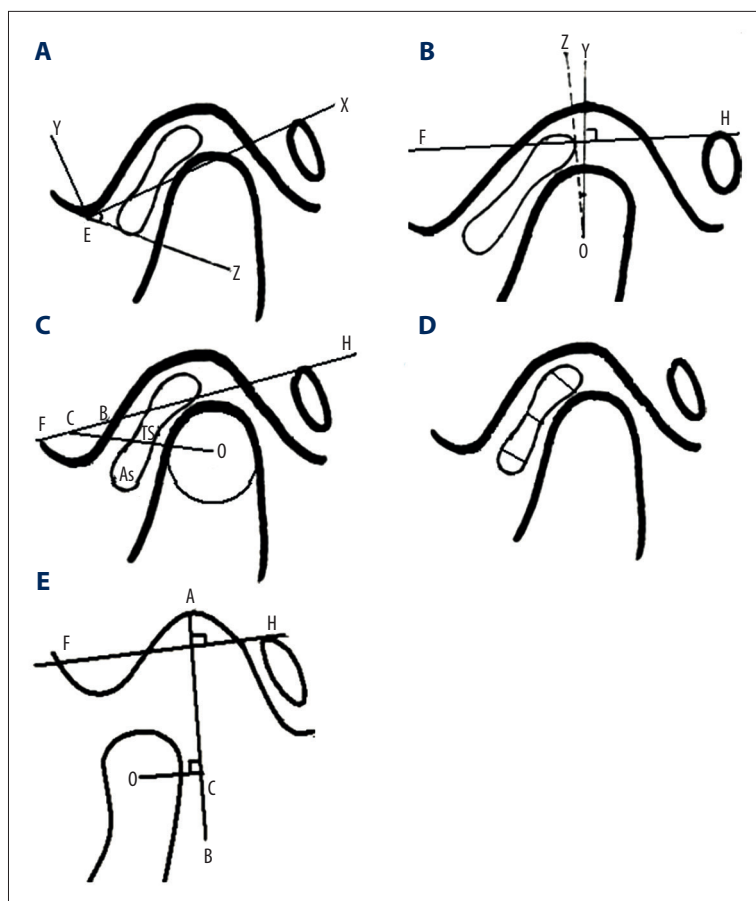


Figure 1. Image analysis. Schematic drawing for measuring anterior band position (A), posterior band position (B), disc-condyle relationship (C), disc thickness (D), and condylar activity (E).

jaw and scanning was performed at the first grid (5 mm), the second grid (15 mm), the third grid (25 mm) and a maximum opened-mouth position. Image analysis included determination of articular disc position at closed-mouth position, disc-condyle relationship during the opening process, measurement of joint disc thickness, and measurement of condylar activity and intra-articular effusion.

(1) Articular disc position at closed-mouth position.

We selected the thickest middle 3-layer display closed as the measurement layer and used the GE Signo Excite 3.0 T tool to measure the angle. As shown in Figure 1A, for the anterior band position, we made a tangent X, which touches the upper edge of the external auditory canal and the mandibular tubercle, and mandibular anterior tubercle to point E. We made the vertical line Y to X at point E, then line Z formed a linking E to the boundary between the anterior band and front end. $\angle XEZ$ was taken as a measure of an angle of anterior band position. Statistical analysis of the data was performed to compare the patient and control groups. For the posterior band position (Figure 1B), we took FH as the ear-orbital plane, made line OY through the condyle center O vertical to FH. OZ forms with z the boundary of the posterior band

and dual-plate area. $\angle YOZ$ was taken as a measure of an angle of posterior band position.

(2) Disc-condyle relationship during opening process.

We selected the plane clearly and completely showing the articular disc and condyle at 5 mm, 25 mm, and maximum opened-mouth position. As shown in Figure 1C, the Frankfort plane FH intersects with the articular tubercle and was recorded as A, B. We set C as the A-B midpoint, which connects the condylar head center O dividing the articular disc into anterior and posterior parts. The anterior portion and the entire disc area were measured and are referred to as AS and TS, respectively. We calculated the AS/TS value during the mouth-opening process.

(3) Measurement of joint disc thickness.

Selecting the plane clearly and completely showing the articular disc at closed- and maximum opened-mouth position, we made a vertical line at the anterior, middle, and posterior band along the longitudinal direction of the disk fiber (Figure 1D), then we measured the length of the 3 vertical line at closed- and maximum opened-mouth position, which represents the joint disc thickness.

Table 1. Articular disc position at closed mouth position.

Group	Anterior band position	Posterior band position
Patient	25.9450±4.17294	33.6111±11.97615
Control	24.1553±3.93304	8.5±3.98056

Table 2. Disk-condyle relationship at certain opened mouth position.

Group	0 mm	5 mm	25 mm	Maximum opened mouth position
Patient	0.5925±0.03689	0.5356±0.04501	0.4147±0.04291	0.3790±0.02634
Control	0.4767±0.03689	0.4270±0.02322	0.3960±0.02811	0.3903±0.02470

(4) Measurement of condylar activity.

We selected the plane clearly and completely showing the condyle at the maximum opened-mouth position, made line AB perpendicular to the Frankfort plane through the glenoid fossa A, and made a line through the condyle center, which is vertical to and crosses with AB at C (Figure 1E). OC length represents condylar activity.

(5) Intra-articular effusion.

Selecting the images which contain the plane of articular tubercle, we looked for a large area of high-density non-linear signal within the anterior chamber.

Statistical analyses

We analyzed the data with the *t* test, chi-square test, and variance using SPSS 13.0 (V1.1) statistical software.

Results

Position of anterior and posterior band of articular disc in the closed-mouth position

A randomization *t* test was performed to compare the patient group and control group. There was no significant difference in anterior band position of the articular disc between the 2 groups (Table 1, *P*=0.143). We found a significant difference in the posterior band position of the articular disc between the 2 groups (*P*=0.000).

Determination of disk-condyle relationship at certain opened-mouth positions

There was a significant difference between the patient group and control group at closed-mouth position and 5-mm

opened-mouth position (Table 2, *P*=0.000), but no significant difference was found at the 25-mm and maximum opened-mouth position (*P*=0.087 and 0.143, respectively).

Measurement of disk band thickness at closed- and maximum opened-mouth position

The thickness of anterior, middle, and posterior disk bands was measured and compared (Figure 2, Table 3). In both groups at closed- and opened-mouth position, there was a significant difference among disk bands, with the maximum thickness at the posterior band and minimum thickness at the middle band. At closed-mouth position, the band thickness of anterior and middle bands was greater in the patient group than that of the control group. At opened-mouth position, the band thickness of anterior and posterior bands was greater in the patient group than in the control group.

Comparison of condyle activity at the maximum opened-mouth position

Magnetic resonance was used to compare the horizontal distance of condylar center and the top wall of the glenoid fossa at maximum opened-mouth position between anterior disc displacement with reduction (ADDR) patients and controls (Figure 3A, Table 4). The results showed no significant difference in condylar activity, but condyle activity of 3 sides TMJ in anterior disc displacement without reduction (ADDWR) patients were significantly less than that of ADDR patients and controls, suggesting the existence of condylar-limited mobility in ADDWR patients and clinical manifestations-limited mouth-opening.

Comparison of exudation

At the closed-mouth position there was grade II high-density signal, showing “inverted triangle” (Figure 3B). Extensive effusion was observed at 1 side joint and distributed around the

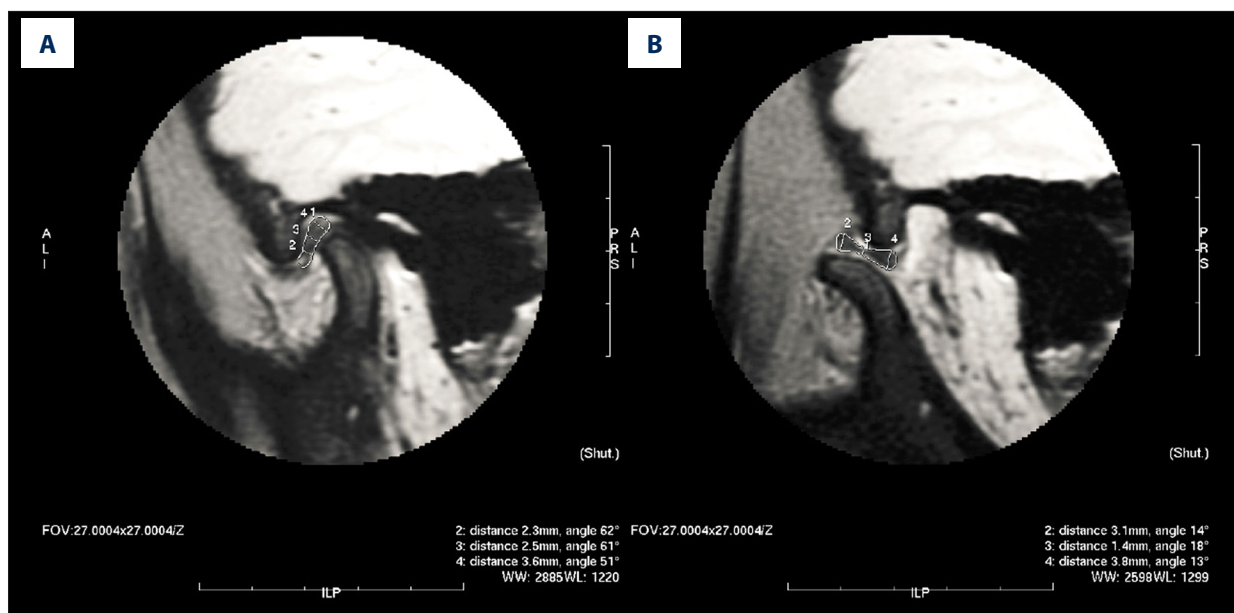


Figure 2. Representative measurement of disk bands thickness of patient group. (A) Closed-mouth position. (B) Maximum opened-mouth position.

Table 3. Measurement of disk bands thickness closed and maximum opened mouth position.

Group		Anterior disk bands	Middle disk bands	Posterior disk bands
Patient	Closed mouth position	2.1611±0.19745	2.3222±0.32998	3.0667±0.28491
	Opened mouth position	2.8167±0.21761	1.7389±0.25237	3.7667 ±0.24734
Control	Closed mouth position	1.9000±0.17995	1.2136±0.12458	2.9318±0.16442
	Opened mouth position	2.6136±0.24358	1.6545±0.21096	3.5136±0.18592

articular disc (Figure 3C). The exudate volume in the patient group was more than in the control group at both closed- and maximum opened-mouth position (Table 5).

Discussion

The temporomandibular joint (TMJ) is a critical load-bearing joint in the human body, with the articular disc acting as a stress absorber during TMJ activity [8,11]. It is important to analyze the joint load distribution and the morphological change of the disc. As prime imaging of choice for the evaluation of the soft tissue and the evaluation method for the amount of joint fluid, MRI has the advantage of showing the soft-tissue components [12,13]. The diagnostic accuracy of MRI for the assessment of the articular disc position and morphology of the disc and in assessing bone changes is 95% and 93%, respectively [14]. MRI has been used to examine the changes of articular disc position [15].

It has been reported there is no difference in the anterior-posterior position of the glenoid fossa and condyle between normal and TMD groups [16]. Many scholars measure the degree of articular disc displacement through the angle or distance. In the traditional standard, the junction of the posterior band of the meniscus and the bilaminar zone should fall within 10 degrees of vertical to be within the 95th percentile of normal [17]. The position of the anterior band in the present study was analyzed using the connection line from the bottom of joint nodules to the upper edge of the external auditory canal as baseline, and position of posterior band was analyzed using the line parallel to the Frankfort plane which passed the condylar center as baseline. The results showed that there was no difference in anterior band position between the patient group and control group, but we found a significant difference in posterior band position between the patient group and control group. The present study used angle measurements to reflect the position change. Therefore, the temporomandibular joint disc displacement is not the entire articular disc moving forward, but with anterior band not obvious and posterior band distinct, which can be explained by attaching structure of the articular

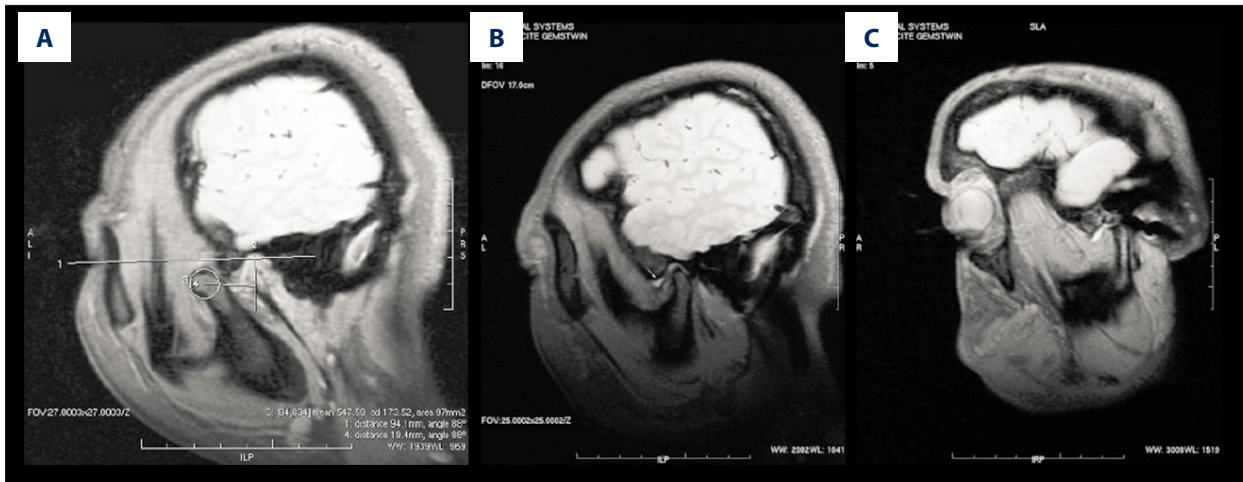


Figure 3. MRI analysis. (A) Condyle activity at the maximum opened-mouth position of ADDR patients. (B) At the closed-mouth position there is grade II high-density signal, showing “inverted triangle”. (C) Extensive effusion was observed at 1 side joint and distributed around the articular disc.

Table 4. Condyle activity at the maximum opened mouth position.

Group	Distance
Patient	10.2733±5.94552
Control	11.3278±4.58717

disc. In addition to the upper muscle fibers of the pterygoideus externus inserting into the articular disc, some masseter and temporalis muscles can be seen among the insertion, most of which come generally from deep muscles. We speculate that when the spasms begin in the masseter muscle, the articular disc is pulled forward but the shift is not obvious because the anterior band-connected tissue is compact and thick. The organizational structure of the bilaminar zone is relatively loose and the connection is weak, resulting in more apparent shift after injury. It could also be the occlusion changes caused by a variety of events, leading to an increased gap between the condyle and glenoid fossa and compensatory change.

These results suggest that at closed-mouth position, anterior displacement occurred in the disc-condyle of ADDR patients. At opened-mouth position of 5 mm, disc-condyle moved forward together and anterior displacement still existed. There was no significant difference of disc-condyle relationship between normal and patient group at opened-mouth position of 25 mm, indicating that the clicking sound had occurred at that time point. At the maximum opened-mouth position, the location of the intermediate zone of the disc returned to normal. These results are consistent with the notion that in ADDR patients, the displaced disc restored the normal disc-condyle relationship in the open-mouth position [18]. This experiment indicates that during the mouth-opening process, the value

Table 5. Comparison of exudation.

Group	With exudation	Without exudation	Total
Patient	11	7	18
Control	4	26	30
Total	15	33	48

AS/TS could be used as an important diagnostic indicator of ADDR and ADDWR.

We showed that the anterior disc displacement of TMJ not only involved positional change, but also shape changes. At closed-mouth position, the thickness of the anterior and middle, but not posterior, band increased. The middle band of the patient group at opened-mouth position was clearly smaller than that at closed-mouth position, which is opposite the condition in the control group, indicating that articular disc shape produced adaptive changes. This experiment also showed that both in the patient and control group, the articular disc area at opened-mouth position was significantly larger than that at closed-mouth position. This observation suggests that the articular disc could change shape with the load and adjust to internal pressure. It follows that when the occlusion changes, the position and shape of articular disc produce consequent adaptations. If it exceeds the limit, a variety of disorders could occur.

Use of condylar position change to determine articular disc displacement can result in false-positive or false-negative diagnoses. In this study, the horizontal distance from condylar center to the top wall of the glenoid fossa was compared using magnetic resonance, and the results showed no significant

difference in the motion range of the condyle both in the patient group and the control group. However, the motion range of the condyle in the ADDWR patient group was significantly less than the value in the ADDR patient group and control group, which was consistent with the fact that range of motion is not limited in ADDR patient because the disc is reduced during condylar translation. This observation indicates that limited mobility of the condyle exists in ADDWR patient, clinically manifested as limited mouth-opening.

A previous study reported the presence of small amounts of exudates in asymptomatic volunteers, but 10% of patients had intra-articular exudates, which exceeded the maximum amount of all the volunteers [19]. Exudates may be present in the normal human articular cavity, but their increase always

indicates inflammation within the joint, which may be due to abnormal disc-condyle relationship [20]. In the present study we found that whether at closed-mouth position or maximum opened-mouth position, the exudates volume in the patient group was more than in the normal group.

Conclusions

We described a series of morphological changes at different mouth positions of normal volunteers and patients, using MRI. We found strong indications that the disc-condyle relationship can serve as an important indicator to judge anterior disc displacement, and can be used to distinguish disc displacement with or without reduction.

References:

- Manfredini D, Guarda-Nardini L, Winocur E et al: Research diagnostic criteria for temporomandibular disorders: A systematic review of axis I epidemiologic findings. *Oral Surg Oral Med Oral Pathol Oral Radiol Endod*, 2011; 112: 453–62
- Westesson PL: Reliability and validity of imaging diagnosis of temporomandibular joint disorder. *Adv Dent Res*, 1993; 7: 137–51
- Hoglund LT, Scott BW: Automobilization intervention and exercise for temporomandibular joint open lock. *J Man Manip Ther*, 2012; 20: 182–91
- Nogami S, Takahashi T, Ariyoshi W et al: Increased levels of interleukin-6 in synovial lavage fluid from patients with mandibular condyle fractures: Correlation with magnetic resonance evidence of joint effusion. *J Oral Maxillofac Surg*, 2013; 71: 1050–58
- Shi J, Xia J, Wei Y et al: Three-dimensional virtual reality simulation of peri-articular tumors using Dextroscope reconstruction and simulated surgery: A preliminary 10-case study. *Med Sci Monit*, 2014; 20: 1043–50
- Ahmad M, Hollender L, Anderson Q et al: Research diagnostic criteria for temporomandibular disorders (RDC/TMD): Development of image analysis criteria and examiner reliability for image analysis. *Oral Surg Oral Med Oral Pathol Oral Radiol Endod*, 2009; 107: 844–60
- Wadhwa S, Kapila S: TMJ disorders: Future innovations in diagnostics and therapeutics. *J Dent Educ*, 2008; 72: 930–47
- Tanaka E, Detamore MS, Mercuri LG: Degenerative disorders of the temporomandibular joint: etiology, diagnosis, and treatment. *J Dent Res*, 2008; 87: 296–307
- Mori H, Horiuchi S, Nishimura S et al: Three-dimensional finite element analysis of cartilaginous tissues in human temporomandibular joint during prolonged clenching. *Arch Oral Biol*, 2010; 55: 879–86
- Stehling C, Vieth V, Bachmann R et al: High-resolution magnetic resonance imaging of the temporomandibular joint: Image quality at 1.5 and 3.0 Tesla in volunteers. *Invest Radiol*, 2007; 42: 428–34
- Tanaka E, Koolstra JH: Biomechanics of the temporomandibular joint. *J Dent Res*, 2008; 87: 989–91
- Berker Y, Franke J, Salomon A et al: MRI-based attenuation correction for hybrid PET/MRI systems: A 4-class tissue segmentation technique using a combined ultrashort-echo-time/Dixon MRI sequence. *J Nucl Med*, 2012; 53: 796–804
- Walde TA, Weiland DE, Leung SB et al: Comparison of CT, MRI, and radiographs in assessing pelvic osteolysis: A cadaveric study. *Clin Orthop Relat Res*, 2005; 437: 138–44
- Liu XM, Zhang SY, Yang C et al: Correlation between disc displacements and locations of disc perforation in the temporomandibular joint. *Dentomaxillofac Radiol*, 2010; 39: 149–56
- Incesu L, Taskaya-Yilmaz N, Ogutcen-Toller M, Uzun E: Relationship of condylar position to disc position and morphology. *Eur J Radiol*, 2004; 51: 269–73
- Sener S, Akgunlu F: Correlation between the condyle position and intra-extraarticular clinical findings of temporomandibular dysfunction. *Eur J Dent*, 2011; 5: 354–60
- Drace JE, Enzmann DR: Defining the normal temporomandibular joint: Closed-, partially open-, and open-mouth MR imaging of asymptomatic subjects. *Radiology*, 1990; 177: 67–71
- Lin WC, Lo CP, Chiang IC et al: The use of pseudo-dynamic magnetic resonance imaging for evaluating the relationship between temporomandibular joint anterior disc displacement and joint pain. *Int J Oral Maxillofac Surg*, 2012; 41: 1501–4
- Zhang S, Liu X, Yang C et al: Intra-articular adhesions of the temporomandibular joint: Relation between arthroscopic findings and clinical symptoms. *BMC Musculoskelet Disord*, 2009; 10: 70
- Guler N, Uckan S, Imirzalioglu P, Acikgozoglul S: Temporomandibular joint internal derangement: relationship between joint pain and MR grading of effusion and total protein concentration in the joint fluid. *Dentomaxillofac Radiol*, 2005; 34: 175–81