

# *Cryptococcus laurentii* endogenous endophthalmitis post COVID-19 infection

Muthugaduru Jagadish Deepa,<sup>1</sup> Chitta Megharaj,<sup>2</sup> Santosh Patil,<sup>3</sup> Padmaja Kumari Rani <sup>4</sup>

<sup>1</sup>Vitreo-Retina Services, Adarsh Super Speciality Eye Hospital, Shimoga, India

<sup>2</sup>Cataract and Refractive Services, Adarsh Super Speciality Eye Hospital, Shimoga, India

<sup>3</sup>Microbiology, Nanjappa Super Speciality Hospital, Shimoga, Karnataka, India

<sup>4</sup>Smt Kanuri Santhamma Centre for Vitreoretinal Diseases, LV Prasad Eye Institute, Hyderabad, Telangana, India

## Correspondence to

Dr Padmaja Kumari Rani; rpk111@gmail.com

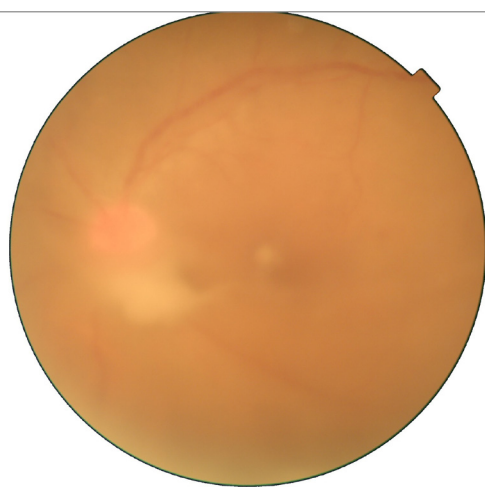
Accepted 30 April 2022

## SUMMARY

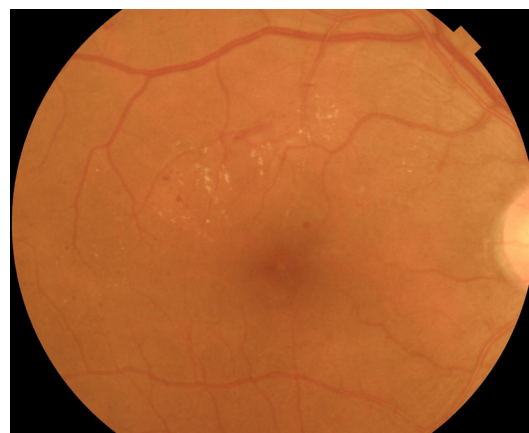
A man in mid-50s presented with progressive blurred vision in his left eye for over 6 weeks. He was a known diabetic with history of COVID-19 pneumonia treated with steroids and remdesivir. He had pyelonephritis and urinary culture grown *Klebsiella*. He was referred as a case of non-resolving vitreous haemorrhage. Visual acuity (VA) was hand movements with fundus showing dense vitritis. He underwent pars plana vitrectomy, vitreous biopsy with intraocular antibiotics (imipenem) suspecting as a case of endogenous bacterial endophthalmitis. Vitreous biopsy did not yield organisms on the smear/culture. The patient's condition worsened with perception of light and fundus showing dense vitritis with discrete yellowish white deposits on the surface of the retina. A repeat vitreous biopsy done along with intravitreal injection of voriconazole (suspecting fungal aetiology) grown fungal colonies and the organism was identified as *Cryptococcus laurentii*. At 4-month follow-up, the VA improved to 6/24.

## BACKGROUND

Post COVID-19, an ocular sequel in the form of bacterial and fungal endophthalmitis has been reported.<sup>1-3</sup> Due to the prolonged hospitalisation, the use of steroids, interleukin 6 inhibitors, prolonged retention of intravenous cannulas has been associated with high incidence of septicaemia and fungemia reported in the post COVID-19



**Figure 1** Fundus photograph of the left eye shows yellow-white ill-defined exudate in vitreous cavity arising from inferior disc margin and extending along inferotemporal arcade.

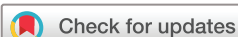

**Figure 2** Fundus photograph of the right eye shows microaneurysms, hard exudates and haemorrhages suggestive of non-proliferative diabetic retinopathy.

status.<sup>4,5</sup> Dilated funduscopy is a safe way to identify an uncommon but sight-threatening condition, such as chorioretinitis/endophthalmitis. Confirming ophthalmic involvement will optimise the care. *Cryptococcus* sp. was previously considered a saprophyte and not a pathogen for humans. However, in favourable circumstances, such as reduced immunity, it appears to be a significant pathogen.<sup>6</sup> Cryptococcosis is a fungal infection caused by two species complexes: *C. neoformans* and *C. gattii*. *Cryptococcus* endophthalmitis is a rare condition diagnosed almost invariably following enucleation or autopsy.<sup>7</sup> Cryptococcal endophthalmitis without systemic involvement has been reported in an immunocompetent patient.<sup>8</sup> The eye can be directly affected by chorioretinitis, or have side effects from meningitis or orbital invasion. We present a rare culture-proven *C. laurentii* endophthalmitis in an immunosuppressed patient with diabetes and post COVID-19 infection. Culture-proven case of *C. laurentii* endophthalmitis has not been reported earlier.

## CASE PRESENTATION

A man in mid-50s presented with a history of 6 weeks of progressive blurred vision in his left eye. The best corrected visual acuity (VA) was 20/50 in the right eye and hand movement vision in the left eye. Medical history indicated that he had been diabetic for 15 years, affected by COVID-19 pneumonia (for which he had been hospitalised). The patient had received systemic steroids (dexamethasone intravenously 4 mg for 3 days, followed



© BMJ Publishing Group Limited 2022. No commercial re-use. See rights and permissions. Published by BMJ.

**To cite:** Deepa MJ, Megharaj C, Patil S, et al. *BMJ Case Rep* 2022;**15**:e246637. doi:10.1136/bcr-2021-246637

by prednisolone orally 20 mg (with 10 mg weekly tapers) for 3 weeks. Five weeks after discharge, the patient noticed a decrease in vision but brought it to the ophthalmologist's attention only a week later. He received steroids and oxygen during his stay. That episode was followed by the development of pyelonephritis and septicaemia. He also recently had a surgical ureteric stent for calculi and has since had his stent removed. Urine culture indicated a growth of *Klebsiella*, which was treated with sensitive antibiotics levofloxacin. The patient had noted a decrease in vision but reported it only a month after his discharge. He was seen by a general ophthalmologist and diagnosed as proliferative diabetic retinopathy (PDR), with vitreous haemorrhage in the left eye and severe non-proliferative diabetic retinopathy (NPDR) in the right eye, and then referred for further management. On further examination, the anterior segment was unremarkable, except for the early signs of cataract in both eyes. The posterior segment showed vitreous cells 3+ in the left eye and normal vitreous in the right eye. The right eye fundus showed microaneurysms, haemorrhages, hard exudates in the posterior pole, suggestive of moderate NPDR. In the left eye, there was a hazy media due to the presence of dense vitritis and a yellow-white lesion about half-disc diameter present on the inferior part of the disc attached to the vessel on the disc (figure 1). Based on the history and examination, the patient was diagnosed with left eye endogenous endophthalmitis probably due to *Klebsiella* as the aetiology and NPDR in the right eye. The patient was subsequently referred for further management.

### INVESTIGATIONS

Blood investigations including complete blood count, renal function tests, blood urea and serum creatinine were within normal limits. Fasting blood sugar was 200 mg/dL and postprandial blood sugar was 250 mg/dL. Initial urine culture grown *Klebsiella* and was treated with sensitive antibiotics levofloxacin. A repeat urine culture and blood culture were sent for and neither grew bacteria nor fungi. HIV screening (TRI-DOT) test came back negative.

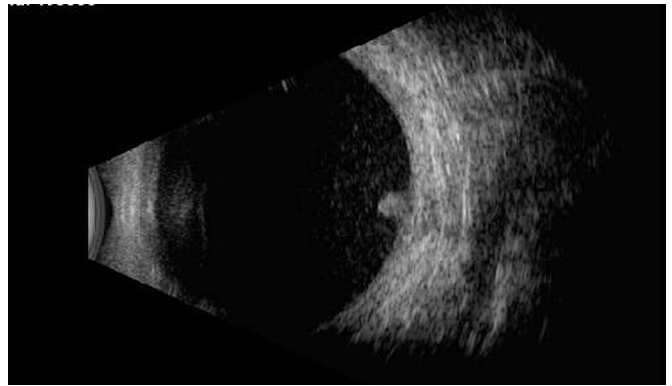
Fundus photograph of the left eye indicates the obscuration of fundus details due to dense vitritis, large yellow-white chorioretinitis lesion with attachment to inferior part of the disc, the vessels were dilated in superior and inferior quadrant (figure 1). Right eye fundus showed microaneurysms, haemorrhages, hard exudates in the posterior pole suggestive of moderate NPDR (figure 2).

Ultrasound B scan of the left eye reveals heterogeneity of vitreous, posterior vitreous detachment and dome-shaped subretinal mass with high internal reflectivity in the region of optic nerve head shadow (figure 3).

The follow-up B scan of the left eye at 1 week post surgery showed increase in echoes in the vitreous cavity and the dome-shaped mass at the optic nerve head had increased diameter with high internal reflectivity (figure 4A,B). Fundus at this visit showed increase in the size of lesion at the disc margin and vitritis had increased, fundus details were obscured (figure 5).

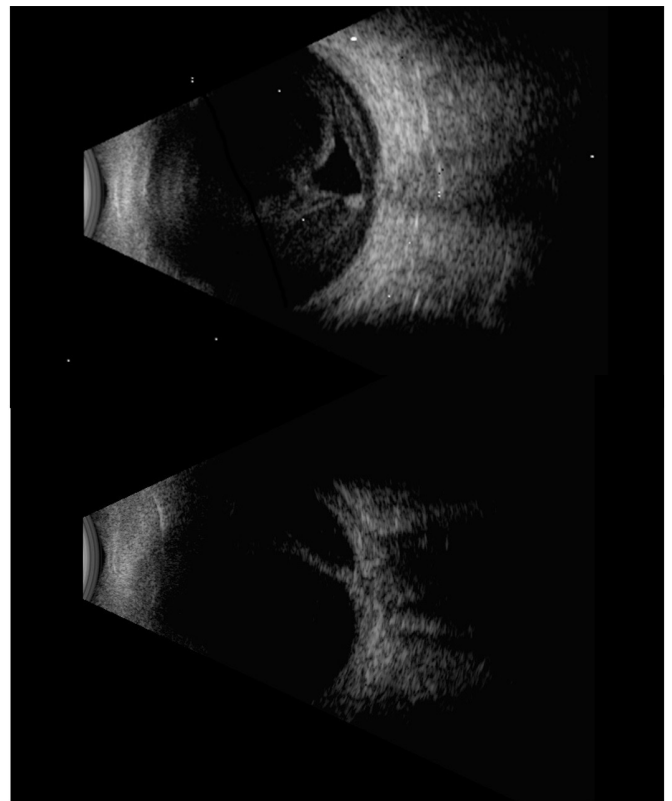
### DIFFERENTIAL DIAGNOSIS

The patient was referred as a case of non-resolving vitreous haemorrhage due to PDR. However, fundus findings of dense vitritis and absence of significant background retinopathy in both eyes ruled out this possibility. In view of the patient's COVID-19 history, immune-mediated neuroretinitis was a possible alternate diagnosis though there were no haemorrhages in the background as is usually seen in such cases. Uncontrolled




**Figure 3** B scan of the left eye shows heterogeneity of vitreous, partial posterior vitreous detachment and oval-shaped mass with high internal reflectivity in the region of optic nerve head shadow.

diabetic status, COVID-19 pneumonia, hospitalisation with steroid and oxygen therapy were significant risk factors in our patient for the development of endogenous endophthalmitis. The patient had a history of COVID-19, a couple of months before presenting with reduced vision. CT of the chest was performed on admission and at discharge, only resolution of the COVID-19 patches in the pulmonary parenchyma was detected. The patient had a pyelonephritis and renal calyx with insertion and removal of the stent 1 month later. The organism may have entered by inhalation or during the urological procedure. A urinary catheter placement might have led to blood stream entry of the organism. The patient was referred for a neurological



**Figure 4** B scan of the left eye shows heterogeneity of vitreous, posterior vitreous detachment and dome-shaped subretinal mass with high internal reflectivity in the region of optic nerve head shadow, echoes have increased compared with earlier scan.



**Figure 5** Postoperative 1-week fundus photograph shows increase in size of fungal granuloma on the disc, other details of fundus not clear due to severe vitritis.

consultation. He was advised to have a lumbar puncture, but the patient did not consent to the procedure because he had no neurologic symptoms. *Klebsiella* organism was retrieved on urine culture, endogenous bacterial endophthalmitis was identified as a high possibility. With the worsening of signs and symptoms following intravitreal antibiotics, the diagnosis was subsequently revised and concluded to be endogenous endophthalmitis due to possible fungal aetiology.

### TREATMENT

The patient underwent three port 23 g pars plana vitrectomy, vitreous biopsy and intraocular antibiotic injection (vancomycin 1 mg in 0.1 mL and imipenem 100 µg in 0.1 mL) within 2 days of presentation. Systemic antibiotic therapy with levofloxacin was continued. The patient was symptomatically better 2 days after treatment. Vision was counting fingers in the left eye, while disc and first-order vessels were hazily seen. Both antibiotics were repeated; however, the culture did not yield any growth. The patient presented 1 week later with a worsening of the symptoms and their vision worsened with the perception of light. Vitritis increased, the exudates were organised in the form of white balls, the lesion on the disc had increased, the diagnosis was revised based on these findings with a high probability of endophthalmitis due to possible fungal aetiology. He underwent repeat vitreous biopsy, complete vitrectomy and intraocular voriconazole injection in the left eye (100 µg in 0.1 mL). Care was taken to obtain the biopsy material, the ball-like lesions on the retinal surface and was directly inoculated into sabourad dextrose agar and blood agar media during surgery in the operation theatre. The smear showed few inflammatory cells, no bacteria or fungus identified on the smear. However, the culture grew fungal colonies on blood agar and sabourad dextrose agar. The organism was identified as *C. laurentii* detected by automated Vitek V.2 compact system based on colorimetric principle. Susceptibility was based on Clinical and Laboratory Standards Institute (CLSI) guidelines M27ARD.

We have attached the antimicrobial susceptibility report with Minimal Inhibitory Concentration (MIC) values (table 1). The organism was susceptible to fluconazole, voriconazole and amphotericin B.

**Table 1** Vitreous aspirate analysis report

Sample: vitreous humour identification of organism: culture showed moderate growth of <i>Cryptococcus laurentii</i> Antimicrobial susceptibility report					
Antimicrobials	Interpretation	MIC value	MIC interpretive criteria		
			Susceptible	Intermediate	Resistant
Fluconazole	Susceptible	2	≤8	16–32	≥64
Micafungin	Susceptible	<0.06	#	#	
Amphotericin B	Susceptible	0.5	#	#	
voriconazole	Susceptible	≤0.12	≤1	2	≥4

Method: performed by automated Vitek V.2 compact system based on colorimetric principle  
Based on CLSI guidelines M27ARD  
# -CLSI not available for these drugs

CLSI, Clinical and Laboratory Standards Institute; MIC, minimal inhibitory concentration.

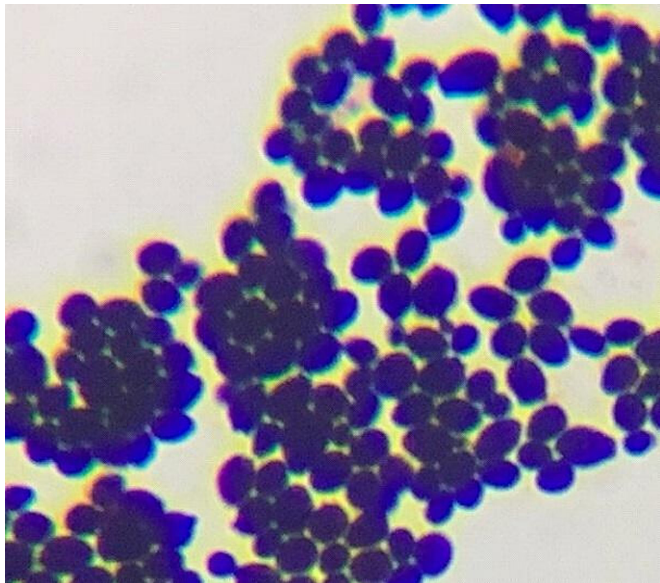
Intravitreal voriconazole injection three doses were given at an interval of 72 hours. The patient was given systemic antifungal therapy, oral fluconazole 200 mg two times per day for a period of 1 month. This therapy was given following baseline liver and renal function tests and physician clearance. A repeat vitreous aspirate was sent for microbiological evaluation. As there were no organisms detected, we continued the medication for 9 weeks and stopped. At 4 months of follow-up, after the medication was discontinued, the infection did not show any recurrence.

### OUTCOME AND FOLLOW-UP

Two days post voriconazole injection, there was improvement in the vision to counting fingers close to face. Disc and first-order vessels were visualised on fundus examination. Microbiology report of repeat vitreous aspirate at 48 hours showed cream coloured, smooth colonies of 1–2 mm in diameter on sabourad's dextrose agar after an incubation of 24 hours (figure 6). The fungal colonies were identified as *C. laurentii* based on automated Vitek V.2 compact system based on colorimetric principle. Susceptibility was based on the guidelines of the CLSI M27ARD. Gram stain of the smear of the colonies revealed gram positive spherical budding yeast cells (figure 7). Macroscopically, 50–100 white-cream colonies grew, with mucoid to butyrous consistency, which darkened with age. The reverse was colourless. Microscopically, contrasted budding encapsulated spherical and



**Figure 6** Growth of fungal colonies on Sabourad Dextrose Agar.



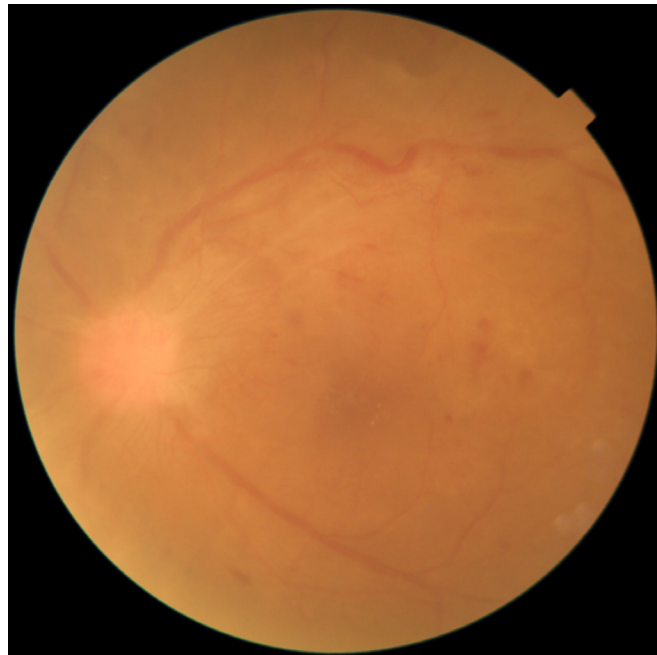
**Figure 7** Gram stained the smear of the colonies show gram-positive spherical budding yeast cells high magnification.

ellipsoidal yeast cells with thickened cell walls of approximately 5 µm in diameter were observed, which was morphologically consistent with their identification as *Cryptococcus* sp. Biochemical identification of the culture was made using a VITEK V.2 (bioMérieux) by noting the utilisation of lactose and melibiose, which confirmed the species as *C. laurentii*. MIC values were also evaluated by VITEK V.2. MIC for amphotericin B was 0.5–1 µg/mL, and that of fluconazole was 3.5 µg/mL, according to the broth microdilution method of the CLSI guidelines M27ARD. Vitreous culture antibiotic susceptibility report (table 1) showed that the organism was susceptible to voriconazole, fluconazole and amphotericin B antifungal agents.

Systemic fluconazole was used with consent from a nephrologist. Intravitreal voriconazole was used in the dose of 0.1 mg/0.1 mL. Use of intravitreal voriconazole was reported earlier with favourable results in *Cryptococcus* sp. We decided to combined use of intravitreal voriconazole and systemic fluconazole. The intravitreal injections of voriconazole were repeated every 3 days and the patient was continued on oral fluconazole 200 mg two times per day and reviewed at weekly interval patient received four doses of intravitreal voriconazole. At the last follow-up of 2 months, VA in the left eye improved to 6/24 and there was complete resolution of disc granuloma and vitritis (figure 8). Left eye fundus showed diffuse epiretinal membrane, diffuse cystoid macular oedema confirmed by optical coherence tomography of the left eye (figure 9).

## DISCUSSION

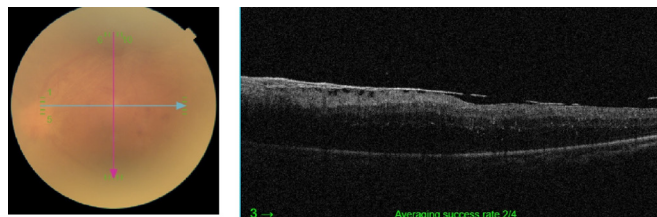
Post COVID-19, various ophthalmic manifestations have been described. Prolonged hospital stay, long-term intravenous cannulas make patients infected with COVID-19 susceptible to endophthalmitis.<sup>1–4</sup> In addition, a large proportion of these patients may have pre-existing comorbidities such as diabetes mellitus.<sup>5</sup> A sustained and substantial reduction in peripheral lymphocytes, mainly CD4 and CD8 T cells has been observed in patients with COVID-19. High-dose intravenous corticosteroids as part of COVID-19 management can contribute to systemic immunosuppression.<sup>1,2</sup> As a result, opportunistic infections in these patients are common. Our patient was given dexamethasone intravenously 4 mg for 3 days, followed by prednisolone



**Figure 8** At the last follow-up fundus photograph shows few dot hemorrhages and complete resolution of disc granuloma with epiretinal membrane at the macula.

orally 20 mg (with 10 mg weekly tapers) for 3 weeks. Candidemia in patients with COVID-19 following prolonged intravenous therapy has been reported.<sup>5–7</sup> Few case reports of cryptococcal endogenous endophthalmitis have been discussed in the literature but most of them had a bad prognosis in terms of vision and clinical outcome,<sup>6,7</sup> *Cryptococcosis* is a systemic fungal infection caused by a nonmycelial, encapsulated, saprophytic yeast fungus *C. neoformans*. Humans are exposed to *Cryptococcus* by inhalation, which leads to an initial pulmonary infection that can be asymptomatic, subacute or disseminated.<sup>8–10</sup>

Clinical, pathological correlation from previous reports suggests ocular cryptococcosis is a primarily choral disease with retina and vitreous being secondarily infected.<sup>11</sup> In our case, though the source of infection was not obvious. The patient had post COVID-19 status and he had also undergone urinary stent surgery for renal calculi a month ago. *C. laurentii* was first reported as a cause of endophthalmitis in 1995,<sup>12</sup> no cases have been reported since then. The case showed a 60-year-old woman presenting with chronic uveitis photograph, which did not respond to topical steroids and later progressed to endophthalmitis with combined retinal detachment. The patient underwent vitreous biopsy, buckling procedure and vitrectomy with oil insertion. Based on microbiological evaluation, a definitive diagnosis of *C. laurentii* was made. Vision did not show



**Figure 9** Left eye optical coherence tomography shows epiretinal membrane nasal to macula with thickened retina and internal limiting membrane folds.

improvement at the end of treatment. The patient was put on systemic fluconazole for 5 months and repeat aqueous tap and vitreous tap was negative for fungus.

Our case was also proven case of *C. laurentii*. Use of intravitreal voriconazole was reported earlier with favourable results in *Cryptococcus* sp.<sup>13 14</sup> We treated our case with immediate pars plana vitrectomy and intravitreal voriconazole two times per week based on documented evidence of cryptococcal neoforams to intravitreal voriconazole,<sup>13 14</sup> for 2 weeks and systemic fluconazole, which was continued for 3 months. Silicone oil usage is reported in the management of fungal endophthalmitis; however, the safety dosage and efficacy of the drugs such as voriconazole has not been established in silicone filled eyes.<sup>15 16</sup> Silicone oil tamponade was not considered in our patient as the vitrectomy on the periphery was not complete due to media haze and due to the absence of any retinal breaks during the surgery. Our patient improved significantly and vision improved to 6/24. Our case showed a yield of *C. laurentii* on culture. This may be due to the immediate inoculation of the vitreous sample in culture media in the operating theatre. Our case is the first case of *C. laurentii* treated with intravitreal voriconazole and also to recover good vision. Our case describes clinical features, imaging and evidence-based management of *C. laurentii* endophthalmitis in a post COVID-19 recovered patient. Early diagnosis and rapid intervention have helped to achieve favourable anatomical and visual outcomes.

### Learning points

- ▶ Following the COVID-19 pandemic, fungemia and fungal endophthalmitis are increasing, a high clinical suspicion index is required.
- ▶ Immediate inoculation of the vitreous aspirate in the culture media during surgery may improve the yield of the culture positivity of fungal organisms, as seen in the present case.
- ▶ Pars plana vitrectomy along with intravitreal voriconazole and systemic fluconazole therapy resulted in favourable anatomical and visual outcomes.

**Contributors** MJD: planning, conduct and reporting of the work. SP: microbiological assesment and reporting of the organism. CM: review of the literature and compilation of data. PKR: Concept, editing and revision of manuscript and gurantor.

**Funding** The authors have not declared a specific grant for this research from any funding agency in the public, commercial or not-for-profit sectors.

**Competing interests** None declared.

**Patient consent for publication** Consent obtained directly from patient(s)

**Provenance and peer review** Not commissioned; externally peer reviewed.

Case reports provide a valuable learning resource for the scientific community and can indicate areas of interest for future research. They should not be used in isolation to guide treatment choices or public health policy.

### ORCID iD

Padmaja Kumari Rani <http://orcid.org/0000-0001-7069-8238>

### REFERENCES

- 1 Shah KK, Venkatramani D. A case series of presumed fungal endogenous endophthalmitis in post COVID-19 patients. *Indian J Ophthalmol* 2021;69:1322–5.
- 2 Goyal M, Murthy S, Annum S. Retinal manifestations in patients following COVID-19 infection: a consecutive case series. *Indian J Ophthalmol* 2021;69:1275–82.
- 3 Bilgic A, Sudhalkar A, Gonzalez-Cortes JH, et al. Endogenous endophthalmitis in the setting of COVID-19 infection. *Retina* 2021;41:1709–14.
- 4 Nucci M, Barreiros G, Guimarães LF, et al. Increased incidence of candidemia in a tertiary care hospital with the COVID-19 pandemic. *Mycoses* 2021;64:152–6.
- 5 Cataldo MA, Tetaj N, Selli M, Marchioni L, et al. Incidence of bacterial and fungal bloodstream infections in COVID-19 patients in intensive care: An alarming “collateral effect”. *J Glob Antimicrob Resist* 2020;23:290–1.
- 6 Sheu SJ, Chen YC, Kuo NW, et al. Endogenous cryptococcal endophthalmitis. *Ophthalmology* 1998;105:377–81.
- 7 Crump JR, Elnor SG, Elnor VM, et al. Cryptococcal endophthalmitis: case report and review. *Clin Infect Dis* 1992;14:1069–73.
- 8 Amphornphruet A, Silpa-Archa S, Preble JM, et al. Endogenous Cryptococcal Endophthalmitis in Immunocompetent Host: Case Report and Review of Multimodal Imaging Findings and Treatment. *Ocul Immunol Inflamm* 2018;26:518–22.
- 9 Bisseru B, Bajaj A, Carruthers RH, et al. Pulmonary and bilateral retinochoroidal cryptococcosis. *Br J Ophthalmol* 1983;67:157–61.
- 10 Alzahrani YA, Aziz HA, Shrestha NK, et al. Cryptococcal iridociliary granuloma. *Surv Ophthalmol* 2016;61:498–501.
- 11 Shields JA, Wright DM, Augsburger JJ, et al. Cryptococcal chorioretinitis. *Am J Ophthalmol* 1980;89:210–8.
- 12 Custis PH, Haller JA, de Juan E. An unusual case of cryptococcal endophthalmitis. *Retina* 1995;15:300–4.
- 13 Vela JJ, Diaz-Cascasosa J, Sanchez F, et al. Management of endogenous cryptococcal endophthalmitis with voriconazole. *Can J Ophthalmol* 2009;44:e61–2.
- 14 Kernt M, Neubauer AS, De Kaspar HM, et al. Intravitreal voriconazole: in vitro safety-profile for fungal endophthalmitis. *Retina* 2009;29:362–70.
- 15 Leung EH, Stout JT. Antibiotics and antifungals in silicone oil. *Int J Retina Vitreous* 2019;5:50.
- 16 Chee YE, Elliott D. The role of vitrectomy in the management of fungal endophthalmitis. *Semin Ophthalmol* 2017;32:29–35.

Copyright 2022 BMJ Publishing Group. All rights reserved. For permission to reuse any of this content visit <https://www.bmj.com/company/products-services/rights-and-licensing/permissions/> BMJ Case Report Fellows may re-use this article for personal use and teaching without any further permission.

Become a Fellow of BMJ Case Reports today and you can:

- ▶ Submit as many cases as you like
- ▶ Enjoy fast sympathetic peer review and rapid publication of accepted articles
- ▶ Access all the published articles
- ▶ Re-use any of the published material for personal use and teaching without further permission

### Customer Service

If you have any further queries about your subscription, please contact our customer services team on +44 (0) 207111 1105 or via email at [support@bmj.com](mailto:support@bmj.com).

Visit [casereports.bmj.com](http://casereports.bmj.com) for more articles like this and to become a Fellow