

Research

Open Access

The versatility of the free osteocutaneous fibula flap in the reconstruction of extremities after sarcoma resection

Alexander D Bach*¹, Jürgen Kopp¹, G Björn Stark² and Raymund E Horch¹

Address: ¹Department of Plastic and Hand Surgery, University of Erlangen, Erlangen Germany and ²Department of Plastic and Hand Surgery, University of Freiburg, Freiburg Germany

Email: Alexander D Bach* - Alexander.Bach@chir.imed.uni-erlangen.de; Jürgen Kopp - Juergen.Kopp@chir.imed.uni-erlangen.de; G Björn Stark - Stark@ch11.ukl.uni-freiburg.de; Raymund E Horch - Raymund.Horch@chir.imed.uni-erlangen.de

* Corresponding author

Published: 01 July 2004

Received: 12 February 2004

World Journal of Surgical Oncology 2004, **2**:22 doi:10.1186/1477-7819-2-22

Accepted: 01 July 2004

This article is available from: <http://www.wjso.com/content/2/1/22>

© 2004 Bach et al; licensee BioMed Central Ltd. This is an Open Access article: verbatim copying and redistribution of this article are permitted in all media for any purpose, provided this notice is preserved along with the article's original URL.

Abstract

Background: An understanding of the biology of bone and soft-tissue sarcomas, knowledge of adjuvant therapies and refinement in techniques of reconstructive surgery have allowed limb-sparing and limb salvage surgery to become a reality in the management of malignant tumors of the extremities. Functional limb salvage following radical resection has become a possibility in many resectable tumors by the use of alloplastic prostheses, homograft or autogenous bone for skeletal reconstitution combined with vascularized soft tissue coverage. Although the free fibula flap has been well described for reconstructions of the mandible and oral cavity, it has not been widely presented as an ideal tool to preserve extremities and to circumvent amputation.

Patients and methods: We describe the complex surgical reconstruction in four patients with primary sarcomas of the extremities. The sarcomas (Ewing's sarcoma, osteosarcoma and epitheloid sarcoma) were resected radically and the massive bone and soft tissue defect was replaced by vascularized free fibula transfer.

Results: We present our experience with versatility of this osteocutaneous flap to allow reconstruction and salvage of extremity sarcomas. There were no operative or postoperative complication and all the four patients had good limb function. The flap was found to be versatile as it could be used for either upper limb or lower limb and for large defects. The results were better in upper limb than in lower limb.

Conclusions: Free fibular graft was found to be effective for salvaging limb function where a massive bone defect resulted from wide tumor resection in the extremities.

Introduction

Common malignant tumors of the musculoskeletal system in children and young adults include Ewing's sarcoma and the osteosarcoma, osteosarcoma being the most frequent malignant neoplasm followed by Ewing's

sarcoma. The osteosarcoma generally involves the metaphysis of long tubular bones especially the distal femur or proximal tibia, whereas Ewing's sarcoma occurs with almost equal frequency in flat bones and diaphyses of tubular bones and may occasionally arise in soft tissues

[1-3]. Epitheloid sarcoma is rare. It occurs nearly three times more often in males compared to females, with the peak incidence between 20 and 29 years of age. Finger, hand, wrist and forearm are preferably affected in this type of malignant tumor [4,5].

Early recognition and surgical treatment seem to offer the best chance for long term survival for these patients [2-6]. Limb-sparing resection in combination with adjuvant or neoadjuvant irradiation and/or chemotherapy is nowadays recommended as the treatment of choice in resectable soft tissue and bone sarcomas of the extremities [7,8]. By this approach survival rates comparable to those after amputation and a better quality of life can be achieved [3]. Important prerequisites to be considered in limb salvage surgery are local tumor control with disease free surgical margins (R0-Resection) and coverage of the surgical defect with vascularized tissue [8-10]. Without complex reconstruction using free flaps, radical resection may not be compatible with limb conservation. Moreover microvascular reconstruction has advantage of wound closure with vascularized tissue in one stage and the use of a distant donor site does not alter the function of an already compromised limb [7,9,11].

In the reconstruction of extensive long bone defects especially in combination with soft tissue loss, vascularized bone transfer is preferable, especially when the treatment protocol includes adjuvant irradiation and chemotherapy. For the reconstruction of larger bony defects, revascularized iliac crest or fibula are the first choice. The fibula has certain advantages compared to the crest; It is a straight cortical bone, its length is almost always sufficient to reconstruct large defects, and soft tissue reconstruction is possible by including a skin island [12-14]. Fibula transfer has been used extensively to bridge defects in the long bones of both the upper and lower limbs.

We demonstrate the versatility of the free osteocutaneous fibula flap in the reconstruction of extremities following sarcoma resection, presenting reconstructive procedures of all long bones of the extremities.

Patients and methods

We describe here our initial experience with the treatment of bone tumors occurring in the extremities, which were treated after resection with a vascularized osteocutaneous fibular graft in four patients. All patients suffered from malignant tumors (Ewing-sarcoma, osteosarcoma and epitheloid sarcoma). The age of the patients at the time of surgery ranged from 13 to 34 years. The follow-up periods after bone transplantation ranged from 9 to 17 month. The affected bone sites were tibia, femur, humerus and the radius. After clinical examination imaging studies were carried out to assess tumor mass, soft tissue involvement

and infiltration of adjacent tissues. Conventional X-rays, soft tissue magnetic resonance imaging (MRI), computed tomographic (CT) scan and angiography of the recipient site as well as of the lower leg fibular donor site were conducted. Radical tumor resection including all compartmental structures was performed after histological verification of the malignancy. Temporary intermittent wound closure was achieved by intraoperative application of continuous vacuum sealing (VAC). After complete resection of the tumor (R0) within the afflicted compartments, the reconstruction was subsequently done in a second step.

Operative technique and technique of free fibular transfer

Stage I – Debridement

A preoperative angiogram was carried out to assess the anatomical variation of the vessels at the donor and recipient site. The recipient vessels may be displaced by previous surgery and scar formation and must be preserved during radical resection of the tumor. The scar tissue was debrided and vessels dissected free.

Stage II – Fibula osteocutaneous flap harvesting and transplantation

A tourniquet was applied to the leg while harvesting the fibula. Whenever possible, the graft was harvested by incorporating the superficial skin flap to provide soft tissue coverage and to allow postoperative monitoring of the microvascular flap. However, skin paddles wider than 8 cm usually required skin grafting of the donor site. An elliptical skin paddle, with its central axis along the posterior border of the fibular head and beginning 10 cm below the fibular head, was incised and harvested subfascially up to the septum between the soleus and peroneus muscles. The skin perforators were identified. All skin perforators were dissected up to their origin and all muscle branches were clipped or ligated. The plane of dissection was between the peroneus longus and soleus and 2 – 3 mm of muscle sleeve around the fibula was included to incorporate the peroneal vascular pedicle. The interosseus membrane was divided and proximal and distal osteotomies were performed. The vascular pedicle was finally separated from the posterior tibial muscle and dissected up to the level of the posterior tibial artery. After these procedures were completed, the blood supply of the flap was solely from its vascular pedicle. The tourniquet was then released and the pedicle was ligated and separated when the recipient site was ready. Bony fixation was then achieved according to the situation of the recipient bones by impelling the end of the fibula into the medullary cavity of the recipient bone, if possible additional screw fixation were performed following microsurgical vessel anastomosis. Postoperative monitoring was easily performed by inspecting the microcirculation of the skin paddle.

Case – 1

A young female patient was referred to our department with the diagnosis of an epitheloid sarcoma (G I-II), stage IIb in the left forearm. The tumor had been incompletely resected (R2) elsewhere with macroscopically tumor infiltrated margins. An MRI-scan revealed a mass in the dorsal aspect of the distal forearm including the extensor and flexor muscle compartments. The distal radius, extensor carpi radialis tendon and the extensor pollicis longus muscle tendons were embedded in the tumor-mass (figure 1a). A staging workup (MRI, CT, Positron Emission Tomography) revealed no evidence of metastatic disease. Patient had earlier received chemotherapy, consisting of vincristin, actinomycin and ifosfamide, and an external radiation. With these findings, the tumor together with a distal segment of the radius, suspicious adjacent musculature and the radial artery was resected. Stabilization was achieved by a wrist bridging external fixation device (Figure 1b) and temporary wound closure was performed by continuous vacuum sealing with a negative pressure wound closure system (V.A.C.[®], KCI). Histopathological examination confirmed the diagnosis of grade I-II epitheloid sarcoma with surgical margins being free of tumor. In a second reconstructive step, the bone defect between radius segments was bridged by vascularized osteocutaneous free fibula transfer (Figure 1b). For stabilization step osteotomies, with lag screws for each osteotomy line and a rigid external fixation device were applied. Resected tendons were reconstructed. The skin island of the free fibula flap permitted tension free soft tissue coverage. All wounds and the donor site healed primarily. The postoperative period was uneventful. X-rays and bone scans confirmed good healing of the fractures and normal perfusion of the flap. The external fixation device could be removed three months after surgery (Figure 1c). After a period of several months the patient is still disease free (Figure 1d) and the functional evaluation is showing good results with very good preservation of rotation of the forearm.

Case – 2

A young male patient presented with Ewing's sarcoma of the left humerus. X-Ray showed a 3.5 × 2.5 cm osteoblastic hyperdensity in the proximal humerus shaft (Figure 2a). This finding was verified by MRI-scan (Figure 2b) and a biopsy of the tumor confirmed the diagnosis of Ewing's sarcoma Grade IIb. Neoadjuvant chemotherapy, consisting of vincristin, actinomycin and cyclophosphamide, and an external radiation with a dose of 54 Gy was administered. After 5 months a wide resection of a proximal segment of the humerus, excluding the humerus head and surrounding tissue was performed. An osteocutaneous fibula flap was used to bridge the 21 cm bony defect (Figure 2c,2d). The bone transplant was fixed by telescoping the fibula into the marrow cavity. Bone union occurred within 4 months of the procedure. There were no postop-

erative complications, and a bone scan demonstrated full vascularization of the fibula graft. After 12 months the X-ray revealed a hypertrophy of the transplanted fibula (Figure 2e). Nineteen month later the patient has full range of motion at elbow and shoulder joints and is pain free. There is no evidence of a local tumor recurrence or metastases.

Case – 3

A male patient presented with the diagnosis of an osteosarcoma. An X-Ray showed osteolytic and osteoblastic lesions of the proximal right tibia (Figure 3a). An MRI and bone scan revealed a tumor (5.5 cm in length) with diffuse infiltration into the proximal tibia shaft (Figure 3b). There was no evidence of metastasis. After neoadjuvant chemotherapy using ifosfamide and cisplatin a 21 cm segment of the tibial shaft was resected along with the surrounding muscles (Figure 3c). A 23 cm pedicled vascularized fibula with a 15 cm wide skin island from the left lower leg was harvested for reconstruction. The fibula was dowelled into the recipient tibia (Figure 3d). Split-skin grafts were used in addition to the skin paddle to provide coverage of the residual soft tissue defect. Recovery was uneventful, all operative sites and skin grafts healed primarily and no morbidity at the donor site was observed. The patient underwent postoperative adjuvant chemotherapy. An X-Ray obtained 8 month after the procedure revealed a bone union of the recipient bone and the vascularized fibula. The patient was walking unaided with a good gait.

Case – 4

Five years after a wide resection of an Ewing's sarcoma of the right femur, a young man presented with chronic osteomyelitis and non union of an allogenic bone graft at both docking sites. The allograft had been used to bridge a 20-cm bony defect of the femur (Figure 4a,4b). Stabilization had been achieved by an external fixation device. The patient had undergone postoperative chemotherapy and radiation therapy. The allograft did not show any integration and a non-union at the proximal and distal end and a varus deformity of the leg had occurred (Figure 4a,4b). With these findings the allograft was removed, a radical debridement was performed, and the femur was fixed with a dynamic condylar screw and a plate. An osteocutaneous free fibula flap, harvested from the left lower extremity, was used to bridge the bone defect (Figure 4c,4d,4e). Bony union occurred within 16 weeks, which was confirmed clinically and radiologically, when fibula hypertrophy was noted. At present there is no evidence of an osteomyelitis, local recurrence or metastases.

Discussion

The mainstay of the curative treatment of nearly every primary tumor of the musculoskeletal system is adequate

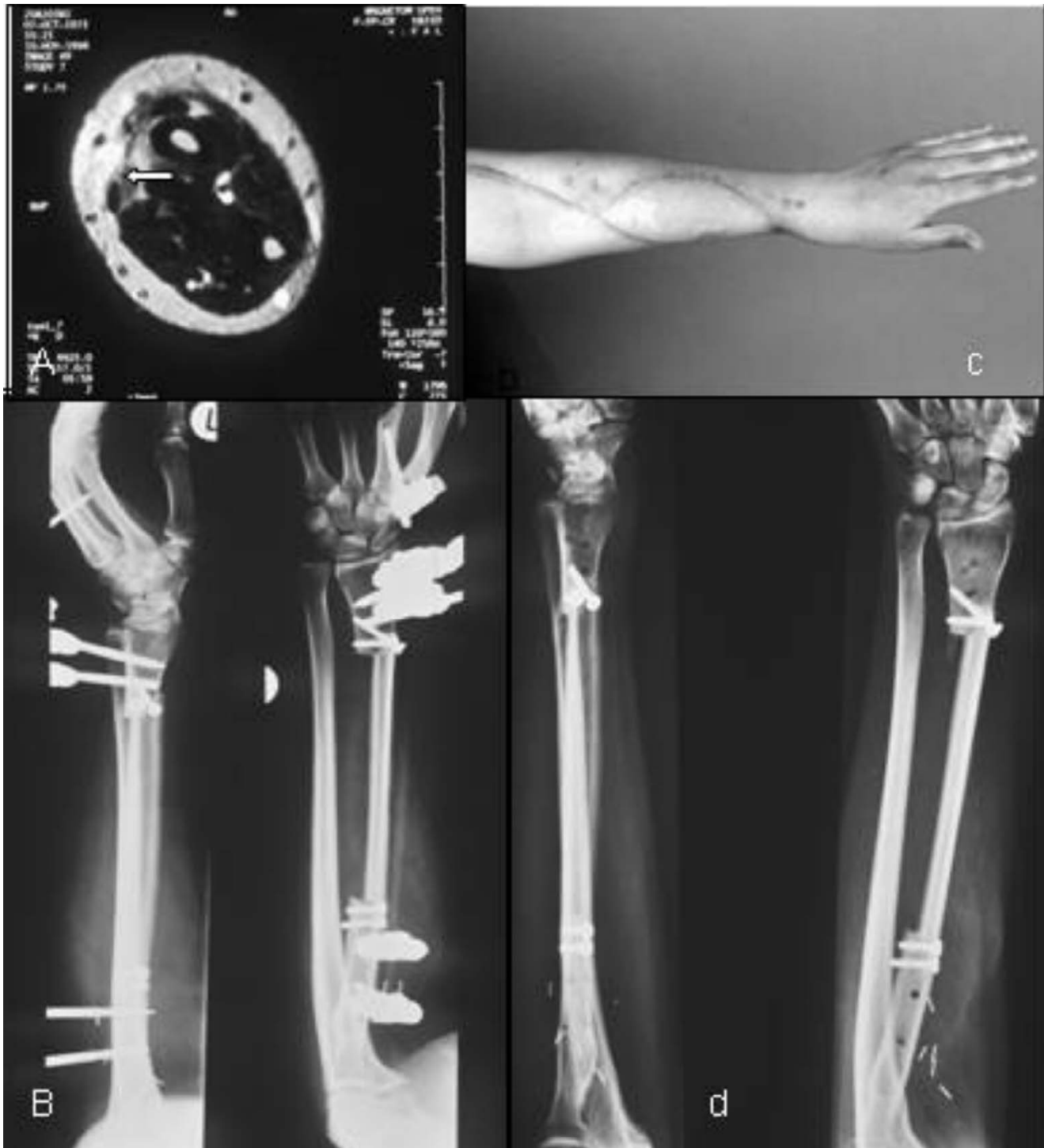

Figure 1

Case 1 epithelioid sarcoma in young female A Preoperative T1- weighted MRI-scan showing a tumor (white arrow) with diffuse infiltration into the ventral and dorsal part of the forearm-musculature including the extensor and flexor muscle compartment, the distal radius, the tendon of the extensor carpi radialis and the extensor pollicis longus muscle. The tendons are embedded in the tumor-mass. B Postoperative bone X-ray showing the free fibular graft inserted between radius fragments after removing the rigid external fixation device for stabilization (4 month after operation). C Postoperative result 6 month after grafting the free fibula. D Postoperative conventional bone X-ray showing the free fibular graft inserted between radius fragments.

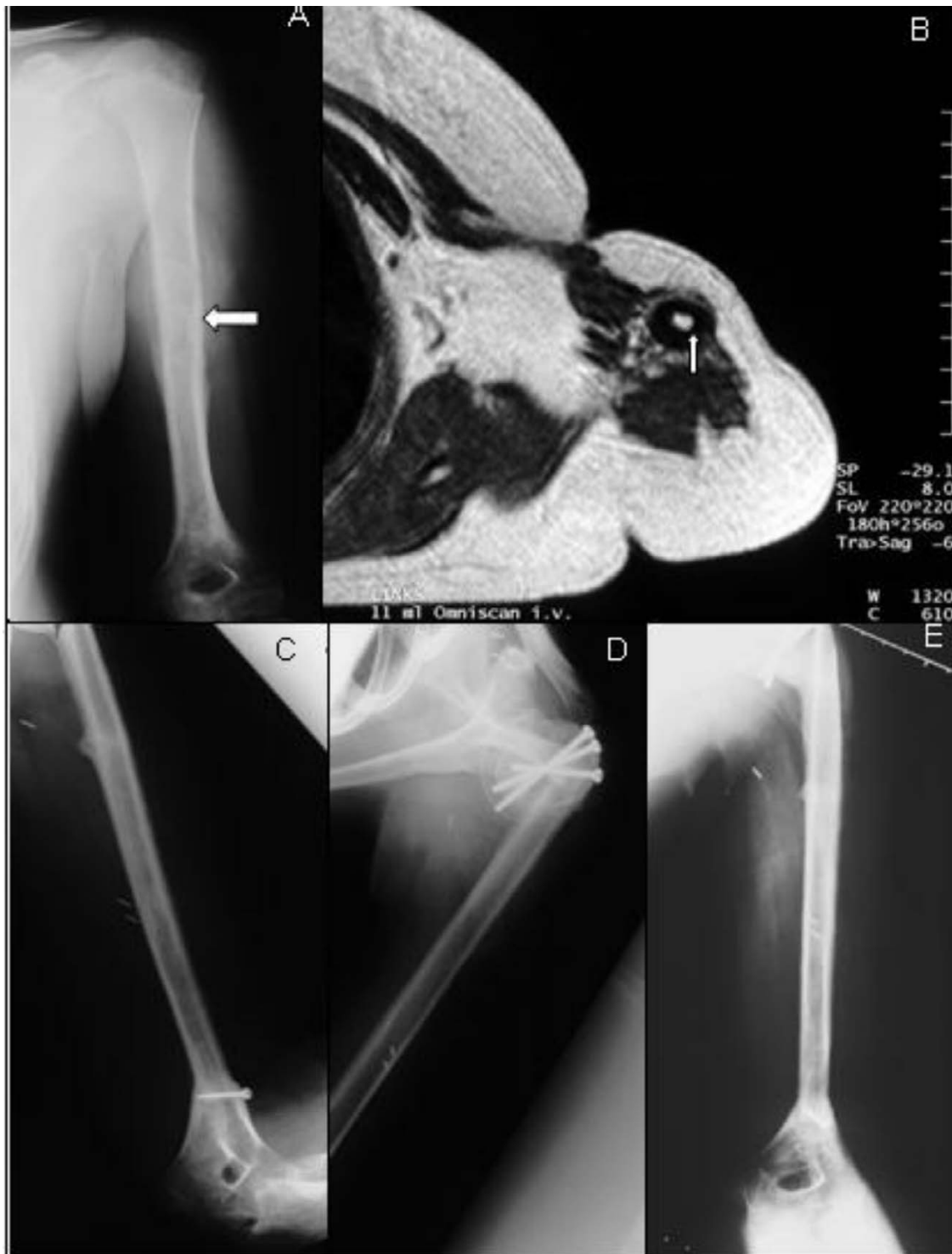

Figure 2

Case 2 Ewing's sarcoma of the humerus in young male A Preoperative conventional bone X-ray of the humerus showing the Ewing's sarcoma (arrow). B Preoperative T1- weighted MRI-scan showing the sarcoma (white arrow) with diffuse infiltration into the soft tissue. C Postoperative bone X-ray showing the free fibular transplant inserted between humerus fragments (4 weeks after operation). D Postoperative conventional bone X-ray showing the free fibular graft inserted between humerus fragments (4 weeks after operation). E Postoperative result 12 months after grafting the free fibula showing the hypertrophy of the bone transplant.

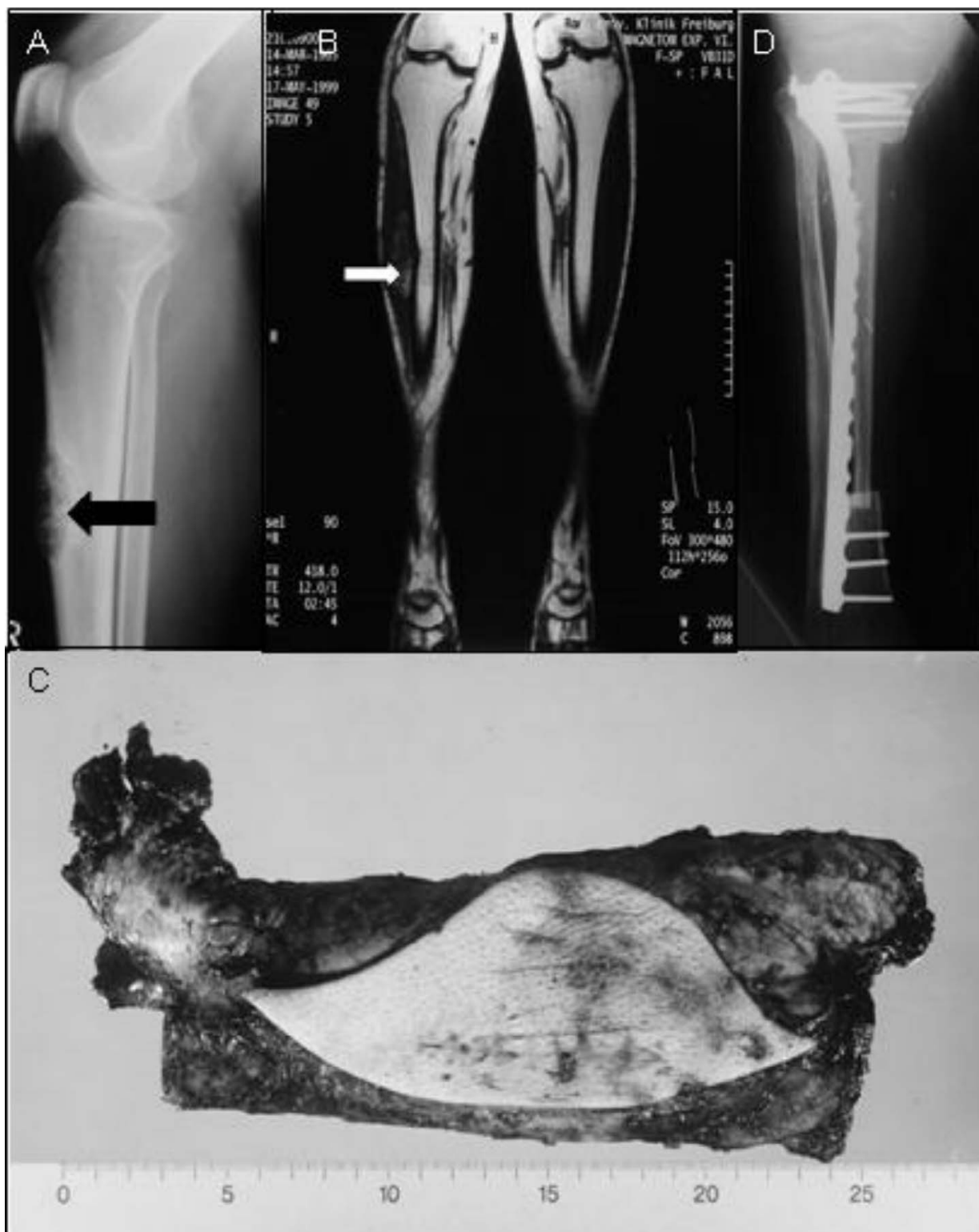


Figure 3
Case 3 osteosarcoma of the tibia A Preoperative bone X-ray showing the osteosarcoma of the tibia (arrow) B Preoperative T1-weighted MRI-scan showing the osteosarcoma (white arrow) with diffuse infiltration into the soft tissue. C Resected tibia with tumor and skin paddle. D Postoperative conventional bone X-ray showing the free fibular graft inserted between tibia fragments (4 weeks after operation).

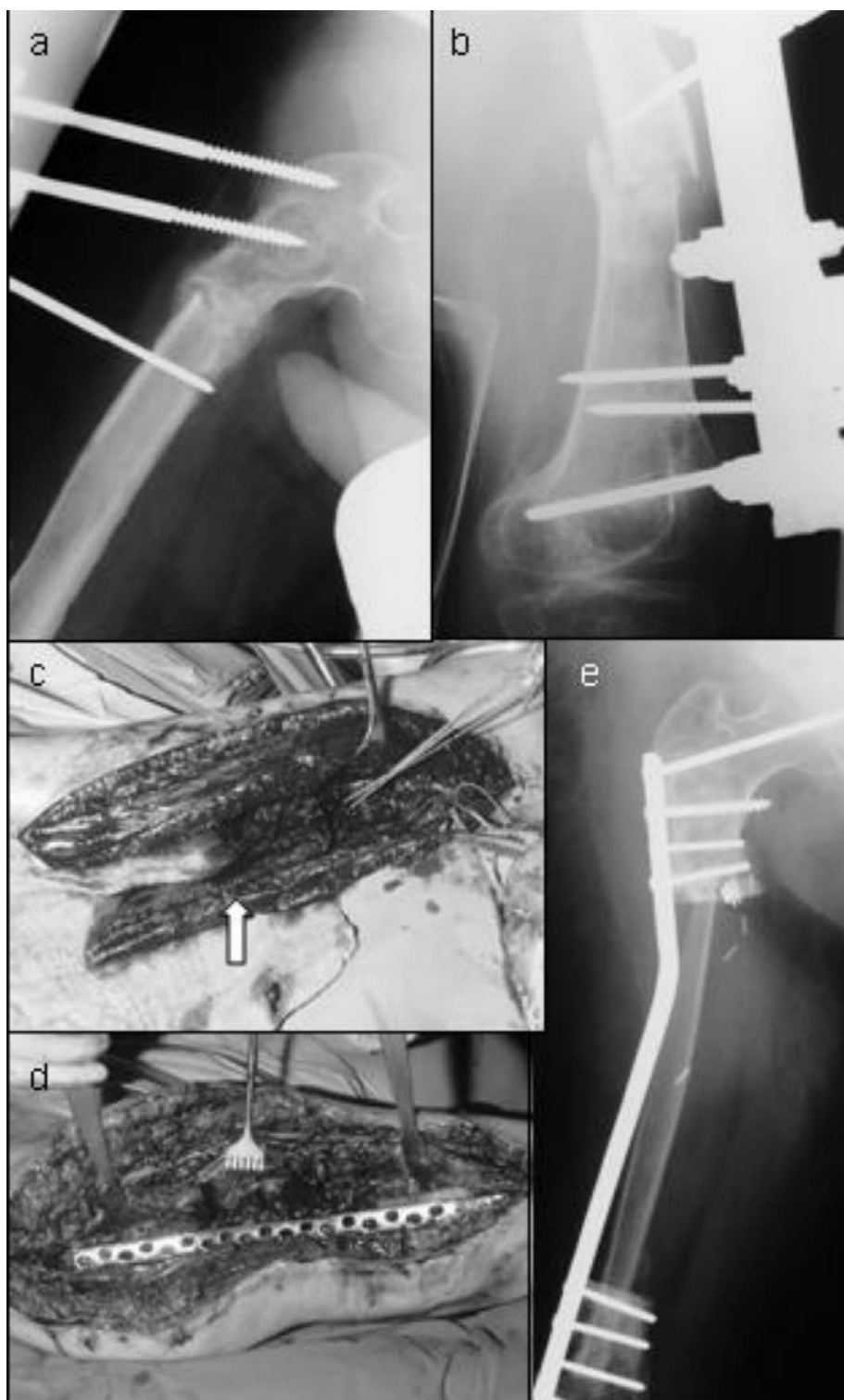

Figure 4
Case 4 chronic osteomyelitis and non union in Ewing's sarcoma A Preoperative conventional bone X-ray showing the inserted allograft with pseudarthrosis at the proximal and distal end 2 years after resection of the Ewing's sarcoma. B Preoperative X-ray showing the inserted allograft with pseudarthrosis. C Harvesting of the free fibular graft. D Placement of the fibular bone graft and fixation of the femur fragments with a plate E Postoperative bone X-ray 4 weeks after grafting the free fibula between the femur fragments

surgical resection, as a good local control of primary seems to offer the best chance for long time survival in these patient [5,15]. Besides, early functional rehabilitation depends on sufficient primary surgery [2,3,8,10]. Radiation and chemotherapy are important adjuvant in the overall management of these tumors. The integration of reconstructive procedures into the oncological treatment is mandatory for soft tissue defects with exposure of bones, joints, tendons and neurovascular bundles [10,16]. Combined orthopedic and plastic surgical management is essential both, at operation and rehabilitation. Adequate surgery represents early radical resection of the primary tumor while maintaining the highest possible level of quality of life. Therefore limb-sparing resection of sarcomas and immediate bony and soft-tissue reconstruction plays a key role in the multidisciplinary treatment of bone and soft tissue sarcomas of the extremities [9,10,17,18]. Several reconstructive procedures for bone defects following wide tumor resection in the extremities have been attempted. There are nonvascularized cancellous and cortical autografts, allografts, bone transport procedures and prosthetic replacements [16,19-24]. Conventional cancellous graft reconstructions are suitable for situations with limited bone defects which are surrounded by adequate soft tissue coverage. The disadvantage of the procedure is the time required to obtain revascularization between the bone graft and the recipient site, moreover stress fractures and nonunion of the bone segments often occurs [24]. Cadaveric bone allografts have been employed in recent years for limb reconstruction [6,21]. However the healing mechanism of bone allografts is characterized by limited revascularization and in most cases restricted within a few millimeters of the bone surface. Reconstruction procedures by bone transport, like the Ilizarov technique include the disadvantage that it takes a long time (month to years) to compensate long bone defects which usually arise after adequate tumor resection. Moreover it has been described that this method comprises a high complication rate in patients with bone sarcomas [25]. All these techniques are further compromised by the frequently necessary irradiation. Another option for reconstructing a long bone defect is free vascularized bone transfer [18,26-32]. The healing mechanisms of a vascularized bone autograft are distinctly different from the other procedures. Revascularization occurs as a surgical event immediately upon restoration of physiologic blood flow at the completion of the vascular anastomosis. This circumstance retains osteoblastic and osteoclastic potential for primary bone healing as a simple fracture and to enhance early bone remodelling, which leads to a faster incorporation of the graft [28]. The free fibula flap is now a well-recognized source of vascularized bone [33-35] and has important advantages over other donor sites. The fibula is a long and straight tubular bone which is not difficult to harvest, the

anatomy is predictable and its size and shape allow intramedullary dowelling of femoral, tibial and humeral defects [12]. Donor site morbidity is minimal up to a graft length of 20 cm. Vascularized free fibular grafting has been used successfully to treat bone defects associated with trauma, osteomyelitis and bone-non-union [13,20,21]. In the four presented patients after resection of malignant sarcomas of the extremities, the free osteocutaneous fibular graft produced a rapid bone union and adequate soft tissue coverage. Although bone transfers to the lower extremity showed significantly more hypertrophy than those in the upper extremity [30,31], the small diameter of the fibula limits its capacity to bear certain weight. Though sufficient hypertrophy of the grafted fibula can often be expected in the case of children, in adults this bone graft seems to be more suitable for reconstruction of the upper extremities [14]. In our cases bone union of the recipient bone with the fibular graft was observed within 5 month. Moreover the method of using an osteocutaneous free fibula flap with a composite skin flap is effective for vascular monitoring as well as closing the resulting skin and soft tissue defect which frequently results from tumor resection. Although the follow-up period has been relatively short, there has been no local recurrence or distant metastasis in any of the presented patients.

Conclusion

The compound free microvascular fibular flap seems to be suitable to minimize the number of surgical procedures and to maintain as much functional capability as possible for the patient. Moreover our results illustrate the versatility of this osteocutaneous flap in the reconstruction of extremities after sarcoma resection since most long bones of the extremities could be bridged. We emphasize that the vascularized fibula graft should be considered a reconstructive option for salvaging limb function where a massive bone defect results from wide resection of malignant tumor in the extremities as it may leads to an improvement of the quality of life for the patients.

Competing interests

None declared.

Authors' contributions

AB participated in the operations and drafted the manuscript.

JK participated in the operations.

BS participated in the operations.

RH participated in the operations and participated in the manuscript design and coordination. All authors read and approved the final manuscript.

Acknowledgement

Patient's permission was obtained for publication of their case details.

References

- Vlasak R, Sim FH: **Ewing's sarcoma**. *Orthop Clin North Am* 1996, **27**:591-603.
- Yaw KM: **Pediatric bone tumors**. *Semin Surg Oncol* 1999, **16**:173-183.
- Arndt CAS, Crist WM: **Common musculoskeletal tumors of childhood and adolescence**. *New Eng J Med* 1999, **341**:342-352.
- Roitzsch E, Irmscher J: **Epithelial sarcoma. Three case reports with a review of literature**. *Zentralblatt für Allgemeine Pathologie und Pathologische Anatomie* 1976, **120**:417-27.
- Nigst H: **Soft tissue tumors of the hand**. *Orthopade* 1988, **17**:209-222.
- Bach AD, Walgenbach KJ, Horch RE: **Hemangiosarcoma of the left hand in a patient with the rare combination of Maffucci's an Stewart Treves syndrome**. *Vasa* 2000, **29**:71-73.
- Terek RM: **Tumors of the elbow and forearm**. *Hand Clin* 1994, **10**:543-551.
- Drake DB: **Reconstruction for limb-sparing procedures in soft tissue sarcomas of the extremities**. *Clin Plast Surg* 1995, **22**:123-128.
- Rosenthal HG, Terek RM, Lane JM: **Management of extremity soft-tissue sarcomas**. *Clin Orthop* 1993, **289**:66-72.
- Stein HU, Büttemeyer R, Vogt P, Hussmann J, Hebebrand D: **Limb salvage and reconstructive procedures in soft tissue sarcomas of the extremities**. *Recent results Cancer Res* 1995, **138**:31-39.
- Horch RE, Stark GB: **The rectus abdominis free flap as an emergency procedure in extensive upper extremity soft tissue defects**. *Plast Reconstr Surg* 1999, **103**:1421-1428.
- Harrison DH: **The osteocutaneous free fibular graft**. *J Bone Joint Surg Br* 1986, **68**:804-810.
- Newington DP, Sykes PJ: **The versatility of the free fibula flap in the management of traumatic long bone defects**. *Injury* 1991, **22**:275-281.
- Minami A, Kutsumi K, Takeda N, Kaneda K: **Vascularized fibular graft for bone reconstruction of the extremities after tumor resection in limb-saving procedures**. *Microsurgery* 1995, **16**:56-64.
- Abouafia AJ, Malawer MM: **Surgical management of pelvic and extremity osteosarcoma**. *Cancer* 1993, **71**:3358-3366.
- Choong PF, Sim FH: **Limb-sparing surgery for bone tumors: new developments**. *Semin Surg Oncol* 1997, **13**:64-69.
- Nichter LS, Menendez LR: **Reconstructive considerations for limb salvage surgery**. *Orthop Clin North Am* 1993, **24**:511-521.
- Wexler AM, Eilber FR, Miller TA: **Therapeutic and functional results of limb salvage to treat sarcomas of the forearm and the hand**. *J Hand Surg [Am]* 1988, **13**:292-296.
- Aberg M, Rydholm A, Holmberg J, Wieslander JB: **Reconstruction with a free vascularized fibular graft for malignant bone tumor**. *Acta Orthop Scand* 1988, **59**:430-437.
- Mankin HJ, Doppelt SH, Sullivan TR, Tomford WW: **Osteoarticular and intercalary allograft transplantation in the management of malignant tumors of bone**. *Cancer* 1982, **50**:613-630.
- Mankin HJ, Gebhardt MC, Tomford W: **The use of frozen cadaveric allografts in the management of patients with bone tumors of the extremities**. *Orthop Clin North Am* 1987, **18**:275-289.
- Enneking WF, Spanier SS, Malawer MM: **The effects of the anatomic setting on the results of surgical procedures for soft parts sarcoma of the thigh**. *Cancer* 1981, **47**:1005-1012.
- Guggenheim JJ Jr: **The Ilizarov method. Orthopedic and soft tissue applications**. *Clinics Plast Surg* 1998, **25**:567-578.
- Enneking WF, Morris JL: **Human autologous cortical bone transplants**. *Clin Orthop* 1972, **87**:28-35.
- Ozaki T, Nakatsuka Y, Kunisada T, Kawai A, Danura T, Naito N, Inoue H: **High complication rate of reconstruction using Ilizarov bone transport method in patients with bone sarcomas**. *Arch Orthop Trauma Surg* 1998, **118**:136-139.
- Gidumal R, Wood MB, Sim FH, Shives TF: **Vascularized boned transfer for limb salvage and reconstruction after resection of aggressive bone tumor**. *J Reconstr Microsurg* 1987, **3**:183-188.
- Minami A, Ogino T, Sakuma T, Itoga H, Usui M: **Free vascularized fibular graft for the treatment of a congenital pseudarthrosis of the tibia**. *Microsurgery* 1987, **8**:111-116.
- Ozaki T, Hillmann A, Wuisman P, Winkelmann W: **Reconstruction of tibia by ipsilateral vascularized fibula and allograft**. *Acta Orthop Scand* 1997, **68**:298-301.
- van Twisk R, Pavlov PV, Sonneveld J: **Reconstruction of bone and soft tissue defects with free fibula transfer**. *Ann Plast Surg* 1988, **21**:555-558.
- El Gammal TA, El-Sayed A, Kotb MM: **Hypertrophy after free vascularized fibular transfer to the lower limb**. *Microsurgery* 2002, **23**:367-370.
- Tu YK, Yen CY, Yeh WL, Wang IC, Wang KC, Ueng WN: **Reconstruction of posttraumatic long bone defect with free vascularized bone graft: good outcome in 48 patients with 6 year's follow up**. *Acta Orthop Scand* 2001, **72**:359-364.
- Ceruso M, Falcone C, Innocenti M, Delcroix L, Capanna R, Manfrini M: **Skeletal reconstruction with free vascularized fibula graft associated to bone allograft after resection of malignant bone tumor of limbs**. *Handchir Mikrochir Plast Chir* 2001, **33**:277-282.
- Kaplan I, Ada S, Ozerkan F, Bora A, Ademoglu Y: **Reconstruction of soft tissue and bone defects in lower extremity with free flaps**. *Microsurgery* 1998, **18**:176-181.
- Hidalgo DA, Disa JJ, Cordeiro PG, HU QY: **A review of 716 consecutive free flaps for oncologic surgical defects: refinement in donor-site selection and technique**. *Plast Reconstr Surg* 1998, **102**:722-732.
- Gilbert A: **Vascularised transfer of the fibular shaft**. *Int J Microsurg* 1979, **1**:100-106.

Publish with **BioMed Central** and every scientist can read your work free of charge

"BioMed Central will be the most significant development for disseminating the results of biomedical research in our lifetime."

Sir Paul Nurse, Cancer Research UK

Your research papers will be:

- available free of charge to the entire biomedical community
- peer reviewed and published immediately upon acceptance
- cited in PubMed and archived on PubMed Central
- yours — you keep the copyright

Submit your manuscript here:
http://www.biomedcentral.com/info/publishing_adv.asp

